

The relationship of copper concentrations in feed and plasma to developmental orthopedic disease in foals

Alparslan Coskun¹, Ozgur Ozdemir^{2*}, Muharrem Erol³,
and Hayrettin Kirbiyik⁴

¹Department of Internal Medicine, Faculty of Veterinary Medicine, Cumhuriyet University, Sivas, Turkey

²Department of Pathology, Faculty of Veterinary Medicine, Selcuk University, Konya, Turkey

³Department of Surgery, Faculty of Veterinary Medicine, Erciyes University, Kayseri, Turkey

⁴Gemlik Military Veterinary School, Gemlik, Bursa, Turkey

COSKUN, A., O. OZDEMIR, M. EROL, H. KIRBIYIK: The relationship of copper concentrations in feed and plasma to developmental orthopedic disease in foals. Vet. arhiv 86, 287-294, 2016.

ABSTRACT

The study group consisted of ten foals, 3-6 months old, 6 male and 4 female, KWPN breed, with developmental orthopedic disease (DOD). The control group consisted of eight healthy foals. On clinical examination, lameness, swelling of joints, and pain were observed in all foals. Clinical, radiographic, and pathological findings in ten foals indicated DOD. Serum Cu concentrations in foals with DOD were significantly lower than in the control group (0.094 ± 0.011 mg/kg vs. 0.932 ± 0.068 mg/kg, respectively; $P < 0.05$). Serum Zn levels (1.828 ± 0.180 mg/kg vs. 0.9257 ± 0.052 mg/kg, respectively, $P > 0.05$), serum Ca levels (187.836 ± 7.921 µg/dL vs. 150.912 ± 5.271 µg/dL, respectively, $P > 0.05$), and serum P levels (247.339 ± 10.729 µg/dL vs. 190.470 ± 5.775 µg/dL, respectively, $P > 0.05$) were observed both in foals with DOD and in healthy foals. There were no statistically significant differences between the DOD group and the control group with respect to serum levels of Ca, P and Zn. We concluded that DOD is associated with reduced serum levels of Cu in foals. Copper is an important trace element for growing foals.

Key words: foals, copper, minerals, trace elements, developmental orthopedic disease

Introduction

The term “developmental orthopedic disease” (DOD) was first defined in 1986. DOD encompasses all orthopedic disorders observed in growing and developing young horses that cause a disturbance in the conversion of cartilage to weight-bearing bone

*Corresponding author:

Assoc. Prof. Dr. Ozgur Ozdemir, Department of Pathology, Faculty of Veterinary Medicine, Selcuk University, 42079 Konya, Turkey, Phone: +90 33 2223 2734; Fax: +90 33 2241 0063; E-mail: oozdemir@selcuk.edu.tr

(McILWRAITH, 2004). DOD includes osteochondritis dissecans (OCD), subchondral cystic lesions, angular limb deformities, physitis, flexural deformities, cuboidal bone abnormalities, juvenile osteoarthritis, and cervical vertebral malformation (McILWRAITH, 2004; SIRIN and ALKAN, 2010). DOD is a common cause of pain and lameness in horses participating in sports, and it limits their performance (KANE et al., 2003; LEPEULE et al., 2008).

The etiopathogenesis of DOD has been discussed in literature for over 20 years (McILWRAITH, 2004; LEPEULE et al., 2011). The initial lesion appears during endochondral ossification. However, the etiologic profiles of DOD are complex and are not well known. The factors most frequently noticed are genetic predisposition, body size, growth rate, nutritional excesses or imbalances, certain exercise modalities, trauma, and metabolic dysfunctions (McILWRAITH, 2004; LEPEULE et al., 2008, 2009 and 2011).

Various mineral imbalances, such as: high calcium (Ca), high phosphorus (P), low copper (Cu), and high zinc (Zn) levels, have been blamed for causing OCD. The minerals horses require in small amounts are known as micro minerals. These nutrients play an important role in the bio-chemical systems of horses and affect numerous metabolic functions. The Ca/P ratio is unbalanced in the diets commonly used in traditional horse breeding (HARRIS et al., 2006). Deficiencies of essential trace elements, such as Cu, Zn, and manganese (Mn), induce developmental musculoskeletal abnormalities, and create harmful reproductive effects in domestic animals. It was reported that common skeletal abnormalities such as DOD have been seen in horses with trace element imbalances (OKAMURA et al., 1998). Cu is an essential element for the special functions of enzymes involved in the synthesis and repair of elastic tissue, mobilization of iron stores, conservation of the integrity of mitochondria, and detoxification of superoxides. Zinc participates as a component of many metalloenzymes and relates largely to the functions of these enzymes (DILL and REBHUN, 1985; JEFFCOTT, 2005).

This study aimed to research the relationship between the occurrence of DOD and serum levels of minerals and trace elements in foals.

Materials and methods

Ten Royal Dutch Warmblood Studbook (KWPN) foals, 170-240 kg body weight and 3-6 months old, were selected based on clinical findings, radiographic findings, and the ages of the foals. All sick foals, of which 6 were male and 4 female, were subjected to clinical and radiographic examinations, and two foals were examined at necropsy, when routine histopathological investigations were performed. All foals were three to six months old and had skeletal abnormalities in more than one limb. Eight healthy foals of similar age, gender, and body mass were included as a control group. Blood samples, taken from the *vena jugularis* of the foals, were collected in glass tubes for the study

of trace elements. The tubes were centrifuged after blood clotting, and the serum was harvested and stored at -20 °C until analysis. The serum samples and feed samples were analyzed for Cu, Zn, Fe, Ca, P, and Mg using inductively coupled plasma-atomic emission spectrometry (ICP-AES, Vista model, Varian, Australia).

Statistical analysis. Data are expressed as means \pm SE. The level of statistical significance was set at $P < 0.05$. A statistical software program (SPSS 10.0) was used for statistical analysis. Comparisons of values between the two groups were analyzed with an independent sample t test.

Results

Clinical and radiographic findings: Lameness, lateral or sternal recumbence, flexural deformities and swelling of joints (Fig. 1a), pain, and sensitivity were observed. Radiographic findings included subchondral bone cysts, osteoarthritis, and physitis in all foals (Fig. 1b).

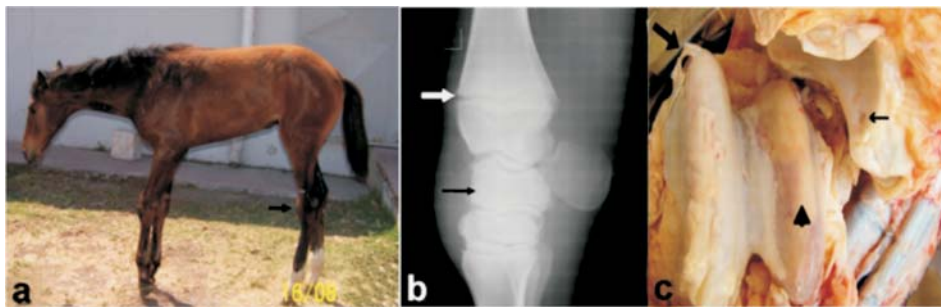


Fig. 1. Clinical, radiography, and pathological findings in foals with developmental orthopedic disease. a. Lameness, swelling of joints (carpal and hook joints), and flexural deformities are seen in this foal. b. Increased synovial fluid, severe osteoarthritis (black arrow), and physitis (white arrow) can be seen on a representative radiographic image of the front leg of a foal (Carpal joint). c. Cartilage of articular surface has completely degenerated; the joint flaps and crater-like degeneration (thin arrow) of the tarsal joint are shown on necropsy.

Necropsy findings. Degeneration of articular cartilage was found to varying degrees on necropsy; this especially involved the hip, knee, shoulder, and elbow joints, and the joints of the front and back feet. Where lesions were observed in the joints, the cartilage had completely disappeared in some areas, causing visualization of bone overlap (Fig. 1c). In some places, the articular cartilage surface had broken down and was distributed in the joint fluid. Histopathologically, erosion and thinning of the articular surfaces, and necrosis of the articular cartilage, which was extensive in some areas, were observed. Pathological findings in joints were associated with osteochondritis dissecans.

Laboratory findings. Concentration of trace elements and minerals in serum are shown in Table 1, and amounts of trace elements and minerals in the feed are shown in Table 2. In the feed samples, all levels, except Cu concentrations, were within the limits set by the National Research Council (NRC). Serum Cu levels in foals with DOD were significantly lower than those in the control group. Serum Zn concentration in foals with DOD was higher than in the control group, but this was not significant (Table 1).

Table 1. Serum trace elements and minerals in foals with DOD (Mean \pm SEM)

Parameters	Foals with DOD (n = 10)	Healthy Foals (n = 8)
Cu (mg/kg)	0.094 \pm 0.011	0.932 \pm 0.068*
Zn (mg/kg)	1.828 \pm 0.180	0.9257 \pm 0.052
Se (mg/kg)	0.1815 \pm 0.031	0.1439 \pm 0.044
Fe (mg/kg)	1.164 \pm 0.278	1.252 \pm 0.171
B (mg/kg)	0.213 \pm 0.009	0.190 \pm 0.007
Cr (mg/kg)	0.068 \pm 0.007	0.058 \pm 0.005
Ca (mg/kg)	187.836 \pm 7.921	150.912 \pm 5.271
P (mg/kg)	247.339 \pm 10.729	190.470 \pm 5.775
Mg (mg/kg)	89.38 \pm 71.610	68.775 \pm 4.001

Values are expressed as means \pm standard error. *P<0.05 compared with the healthy foals

Table 2. Amount of trace elements and minerals in the feed

Parameters	Hay	Dried herb	Pellets	Oat
Cu (mg/kg)	0.4	1.3	5.4	1.3
Zn (mg/kg)	13.3	22.9	54.72	12.64
Fe (mg/kg)	13.3	17.7	112.5	10.4
Ca (mg/kg)	587	1052	5246	421.3
P (mg/kg)	32.11	1229	4045	1269
Mg (mg/kg)	127.2	454.8	1895	555.2

Discussion

DOD is a syndrome characterized by various lesions in young horses. DOD is seen between 1 and 24 months of age, depending on the site and region (JEFFCOTT, 2005; LEPEULE et al., 2008). Osteochondrosis is one of the most significant skeletal problems in foals with DOD. The most obvious sign of DOD is excessive swelling in the shoulder, elbow, knee and fetlock joints. This condition is often associated with OCD. Growth-plate abnormalities, such as enlargement and pain from palpation of the affected physes are the first evident findings. In the current study, swelling, pain, recumbence, and high temperature on clinical examination were encountered. Radiological and pathological

findings in this study indicated that the foals had DOD lesions, including osteochondral fragmentation, subchondral bone cysts, and physitis. These findings indicate that there were severe lesions in the limbs in foals with DOD.

Several predisposing factors have been identified in horses, including rapid growth, nutritional excesses or imbalances, and trauma of the cartilage (OKAMURA et al., 1998). Various mineral imbalances, including Ca, P, Cu, and Zn, have been identified as causative factors of OCD (McILWRAITH, 2004). Ca and P make up approximately 70 percent of the mineral content of the body, and 50 percent of the mineral content of the skeleton, and they are required for normal bone development (ALDRED, 1998). An excess of P will cause inhibition of Ca absorption, leading to problems in bone development (MARSHALL, 2007). If either Ca or P is deficient, it will cause impaired endochondral ossification and decreased bone mineralization, resulting in a wide range of skeletal disorders. These disorders are findings in common with DOD, such as lameness, decreased bone-density, and fractures (ALDRED, 1998). Although the Ca and P requirements of weaned, growing horses has been a frequent topic of study, there is little information regarding the requirements of suckling foals. Each kilogram of mare's milk typically contains approximately 1.2 g of Ca and 0.725 g of P in the first four weeks of lactation. If the foal consumes 15 kg of milk per day, it will take in 18 g of Ca and 10.9 g of P daily (NRC, 1989; ALDRED, 1998). It is assumed that this is sufficient to meet the requirements of the suckling foal, but there is little in the way of research data to confirm this. In this study, foals received approximately 18 g of Ca and 11 g of P each day. We observed that in addition to mare's milk, foals are fed an uncertain amount of oats, pellets, or hay. Even if the total amount of dietary Ca is adequate, excessive P could cause inhibited absorption of Ca, relative Ca deficiency, and bone developmental problems (ALDRED, 1998; LEPEULE et al., 2009). The most suitable ratio of Ca/P is in the range of 1.2:1 to 2:1. A dietary Ca/P ratio of less than 1:1 (i.e., where P intake is higher than Ca intake) may be harmful, especially when fed to growing horses (ALDRED, 1998). We estimated that the Ca/P ratio is approximately 1.65:1 in the diets of foals. This ratio was estimated based on the proportion of the foal's mother and mare's milk consumed. Since the foals were fed by their mothers, the actual consumption of the foals could not be determined precisely. This ratio is an acceptable level for growing foals. Serum Ca and P in the foals with evidence of DOD were determined to be within normal reference ranges (NRC, 1989; ALDRED, 1998). Serum Ca and P concentration in foals with DOD did not differ from the control group, statistically (Table 1).

Deficiencies of essential trace elements, such as Cu, Zn, and Mn, are known to create developmental musculoskeletal abnormalities and to have harmful effects on reproduction in domestic animals. It has been reported that common skeletal abnormalities, such as DOD, are seen as a result of nutritional imbalances in trace elements (OKAMURA et al., 1998). The concentrations of Cu, Zn, and Fe in mare's milk significantly decreases over the first sixteen weeks of lactation. The required minerals for a neonatal foal are obtained

from body reserves (i.e., the liver), mare's milk and concentrate, forages, and creep feed. Research indicates that neonatal foals have particularly low serum Cu concentrations, but values reach normal adult horse levels at about 28 days (OTT and ASQUITH, 1994; KAVAZIS et al., 2002). Zn, Fe, and possibly Cd excesses in the diet may decrease with Cu absorption and utilization, leading to secondary Cu deficiency (MARSHALL, 2007). In the current study, Zn and Fe concentrations in the diets (Table 2) of foals were within the normal range according to the NRC.

Previous studies have shown a correlation between low levels of copper in diets and the incidence of DOD. An epidemiological study in Kentucky found that low Cu levels were the most prominent factor on stallion farms that have high incidences of DOD (GABEL et al., 1987). Experimentally, it has been shown that low-Cu levels in diets increase the incidence of OCD, physisitis, and angular and flexural limb deformities (HURTIG et al., 1993; ALDRED, 1998). This is thought to be the result of a deficiency of lysyl oxidase, which is the Cu-dependent enzyme essential to the maturation of cartilage and bone. Cu deficiency may result in a softening of articular cartilage and predisposition to fractures in the growth plates (HARRIS et al., 2006). The NRC (1989) suggested that all horses should receive 40 ppm Zn and 10 ppm Cu in their diet. The average six-month-old thoroughbred foal weanling, with 215 kg of body weight and consuming 6 kg of feed, would require 240 mg of Zn and 60 mg of Cu per day. However, it is suggested that foals should receive 400 mg of Zn and 150 mg of Cu each day (NRC, 1989). When young horses consume these or lesser amounts, there is a strong chance they will develop DOD (HUNTINGTON et al., 1996). Supplemental feeds contain a concentration of approximately 100 ppm Zn and 40 ppm Cu. Mare's milk contains around 2.5 mg/kg of Zn and 0.45 mg/kg of Cu (equivalent to approximately 25 ppm Zn and 4.5 ppm Cu of dry matter) in the first four weeks postpartum (NRC, 1989). The foal must rely on its body stores of these two minerals until it begins to eat significant amounts of pasture or creep feed (HARRIS et al., 2006). In this study, Cu concentrations in the feed rations for foals were <5 mg/kg. Serum Cu concentrations in foals with DOD were significantly lower than in the control group (0.094 ± 0.011 mg/kg, 0.932 ± 0.068 mg/kg, respectively; $P < 0.05$). Cu concentrations of 25 to 50 mg/kg are recommended in feed rations for growing foals (OTT and ASQUITH, 1994; NRC, 1989; ALDRED, 1998; KAVAZIS et al., 2002). Mare's milk Cu concentration is inadequate for foals in the growing period. Low serum Cu concentration in foals with DOD was associated with low Cu concentration in the diet and milk. Therefore, a diet with increased Cu concentration is crucial for preventing DOD in foals.

In summary, clinical, radiographic, and pathological findings in foals were associated with DOD. We concluded that DOD is associated with a deficiency in Cu in foals, and highlight the importance of Cu as a trace element for growing foals.

Conflict of Interests

The authors declare that there is no conflict of interests regarding the publication of this article.

Acknowledgements

The authors thank Prof. Dr. G. Sonmez, Associate Prof N. Celimli and Vet Med Serhan Durmaz for helpful comments.

References

- ALDRED, J. (1998): Developmental Orthopaedic Disease in Horses. Department of Animal Science University of Sydney, RIRDC Publication No. 97/79, Better Printing, Quenabeyan, Australia.
- DILL, S. G., W. C. REBHUN (1985): White muscle disease in foals. *Comp. Cont. Ed.* 7, S627.
- GABEL, A. A., D. A. KNIGHT, S. M. REED, J. A. PULTZ, J. D. POWERS, L. R. BRAMLAGE, W. J. TYZNIK (1987): Comparison of incidence and severity of developmental orthopedic disease on 17 farms before and after adjustment of ration. *AAEP Proceedings* 33, 163-170.
- HARRIS, P. A., M. COENEN, D. FRAPE, L. B. JEFFCOTT, H. MEYER (2006): Equine nutrition and metabolic diseases. In: *The Equine Manual* (Higgins A. J., J. R. Synder, Eds.), Saunders, Philadelphia, USA, pp. 179-185.
- HUNTINGTON, P. J., S. G. JACKSON, E. OWENS, J. D. PAGAN (1996): Feeding the foal, weanling and yearling. In: *Equine Stud Medicine, Proceedings of the Post Graduate Foundation in Veterinary Science, University of Sydney*, 267, 339-351.
- HURTIG, M., S. L. GREEN, H. DOBSON, Y. MIKUNI-TAKAGAKI, J. CHOI (1993): Correlative study of defective cartilage and bone growth in foals fed a low copper diet. *Equine Vet. J. Suppl.*, 16, 66-73.
- JEFFCOTT, L. (2005): Developmental diseases affecting growing horses. In: *The Growing Horse: Nutrition and Prevention of Growth Disorders* (Juliand V., W. Martin-Rosset, Eds.), Wageningen Academic Publishers, Netherland, pp. 231-245.
- KANE, A. J., R. D. PARK, C. W. McILWRAITH, N. W. RANTANEN, J. P. MOREHEAD, L. R. BRAMLAGE (2003): Radiographic changes in Thoroughbred yearlings. Part 1: prevalence at the time of the yearling sales. *Equine Vet. J.* 35, 354-365.
- KAVAZIS, A. N., J. KIVIPELTO, E. A. OTT (2002): Supplementation of broodmares with copper, zinc, iron, manganese, cobalt, iodine, and selenium. *J. Equine Vet. Sci.* 22, 460-464.
- LEPEULE, J., N. BAREILLE, J. P. VALETTE, H. SEEGER, S. JACQUET, J. M. DENOIX, C. ROBERT (2008): Developmental orthopaedic disease in limbs of foals: between-breed variations in the prevalence, location and severity at weaning. *Animal* 2, 284-291.
- LEPEULE, J., N. BAREILLE, C. ROBERT, P. EZANNO, J. P. VALETTE, S. JACQUET, G. BLANCHARD J. M. DENOIX, H. SEEGER (2009): Association of growth, feeding practices and exercise conditions with the prevalence of developmental orthopedic disease in limbs of French foals at weaning. *Prev. Vet. Med.* 89, 167-177.

- LEPEULE, J., H. SEEGER, V. RONDEAUE, C. ROBERT, J. M. DENOIX, N. BAREILLE (2011): Risk factors for the presence and extent of developmental orthopaedic disease in the limbs of young horses: Insights from a count model. *Prev. Vet. Med.* 101, 96-106.
- MARSHALL, M. (2007): Developmental orthopaedic disease in thoroughbred foals an epidemiological comparison between a stud in Ireland and a stud in Australia, Thesis PhD, The University of Sydney, Australia.
- McILWRAITH, C. W. (2004): Developmental orthopaedic disease: problems of limbs in young horses. *J. Equine Vet. Sci.* 24, 475-479.
- NRC (1989): Nutrient Requirements of Horses. 5th rev. ed. National Research Council, National Academy Press, Washington DC, USA.
- OKAMURA, M., M. ASANO, M. TAGAMI, K. TSUKIYAMA, T. FUJINAGA (1998): Serum copper and ceruloplasmin activity at the early growing stage in foals. *Can. J. Vet. Res.* 62, 122-126.
- OTT, E. A., R. L. ASQUITH (1994): Trace mineral supplementation of broodmares. *J. Equine Vet. Sci.* 14, 93-100.
- SIRIN, O., Z. ALKAN (2010): Developmental orthopaedic diseases in foals. *Kafkas Univ. Vet. Fak. Derg.* 16, 887-892.

Received: 3 March 2015

Accepted: 22 March 2016

COSKUN, A., O. OZDEMIR, M. EROL, H. KIRBIYIK: Utjecaj odnosa koncentracija bakra u hrani i plazmi na razvojnu ortopedsku bolest u ždrjebadi. Vet. arhiv 86, 287-294, 2016.

SAŽETAK

Pokusna skupina sastojala se od 10 ždrjebadi s razvojnom ortopedskom bolešću, šest muške i četiri ženske, u dobi od tri do šest mjeseci, pasmine kraljevski nizozemski toplokrvjak. Kontrolna skupina sastojala se od šest zdrave ždrjebadi. Sva je ždrjebad bila klinički pregledana na hromost, otekline zglobova i bol. Klinički, radiografski i patološki nalazi upućivali su na razvojnu ortopedsku bolest. Koncentracija bakra u ždrjebadi s razvojnom bolešću bila je značajno manja nego u ždrjebadi kontrolne skupine ($0,094 \pm 0,011$ mg/kg u odnosu na $0,932 \pm 0,068$ mg/kg; $P < 0,05$). Serumske razine cinka iznosile su $1,828 \pm 0,180$ mg/kg u pokusne skupine u odnosu na $0,9257 \pm 0,052$ mg/kg u kontrolne skupine, $P > 0,05$, dok su serumske razine kalcija iznosile $187,836 \pm 7,921$ µg/dL u odnosu na $150,912 \pm 5,271$ µg/dL u kontrolne skupine, $P > 0,05$, te razine fosfora $247,339 \pm 10,729$ µg/dL u pokusne u odnosu na $190,470 \pm 5,775$ µg/dL u kontrolne skupine, $P > 0,05$. Nisu ustanovljene statistički značajne razlike između istraživane i kontrolne skupine s obzirom na razine Ca, P i Zn. Zaključuje se da je razvojna ortopedska bolest u ždrjebadi povezana s razinom Cu u serumu. Bakar je važan element za rast ždrjebadi.

Ključne riječi: ždrijebe, bakar, minerali, elementi u tragovima, razvojna ortopedska bolest
