

Department of Reproductive Medicine and Gynecologic Endocrinology,
Maribor Teaching Hospital, Maribor, Slovenia

IMPROVED FERTILIZATION RATE AND A BIRTH AFTER INTRACYTOPLASMIC SPERM INJECTION OF TOTALLY IMMOTILE SPERM, PRESELECTED BY THE HYPO-OSMOTIC SWELLING TEST

POBOLJŠANA STOPA OPLODNJE I POROD INJICIRANJEM POTPUNO NEPOKRETNIH SPERMATOZOIDA ODABRANIH HIPOOSMOTSKIM TESTOM NABREKNUĆA U CITOPLAZMU JAJNE STANICE

Mojca Čížek Sajko, Borut Kovačič, Veljko Vlasisavljević

Original paper

Key words: complete asthenozoospermia, ICSI, HOS test, pregnancy

SUMMARY. *In vitro* fertilization procedures can be applied to aid infertile couples with complete asthenozoospermia, i.e. with absence of even a single motile sperm in ejaculate. However, the probability of conception with intracytoplasmic injection of sperm (ICSI), selected at random from an immotile sperm sample, is quite slight. In couples, in which the male partner's ejaculate contained only immotile sperm, the hypo-osmotic swelling (HOS) test was used to select viable sperm for the ICSI procedure. **Material and methods.** Complete asthenozoospermia as the major cause of infertility was diagnosed in 4 couples, of which two male partners had a special form of complete immotility, a sperm stump defect. Out of the total of 10 hormone-stimulated ICSI cycles, in 6 cycles the sperm for ICSI were chosen randomly, without a HOS test. In 4 cycles, the washed semen samples were incubated in a hypo-osmotic solution and only HOS-positive sperm (i.e. sperm with swollen tail) were used for ICSI. **Results.** Of 6 ICSI cycles without selection of viable sperm using the HOS test, total fertilization failure was noted in 3. Only a total of 20.7% (6/29) oocytes were fertilized. In all 4 ICSI cycles with performed HOS test prior to sperm injection, embryos for transfer were obtained. An 81.8% (18/22) fertilization rate was registered and one twin pregnancy which resulted in a birth of a healthy singleton. **Conclusion.** We can confirm that also in cases of complete asthenozoospermia, even in those, combined with stump defect, good fertilization rate and pregnancies can be achieved after selecting the viable sperm by HOS test prior to the ICSI procedure.

Izvorni članak

Ključne riječi: potpuna astenozoospermija, ICSI, HOS test, trudnoća

SAŽETAK. Oplođnja izvan tijela može se upotrijebiti u liječenju neplodnosti uzrokovane potpunom nepokretljivošću spermatozoida. Naravno, vjerojatnost za začeće nakon oplođnje spermatozoidom koji je slučajno odabran za injiciranje u citoplazmu jajne stanice (ICSI), prilično je nesigurna. U parova, u kojih u ejakulatu nalazimo samo nepokretne spermatozoide, hipoosmotički test nabreknuća repa spermatozoida [hypo-osmotic swelling (HOS) test], upotrebljen je za selekciju vitalnih spermatozoida za ICSI. **Materijal i metode.** Potpuni izostanak pokretljivosti spermatozoida dijagnosticiran je kao glavni uzrok neplodnosti u 4 para. Među njima, kod dvojice muškaraca ustanovljen je poseban oblik potpune nepokretljivosti uzrokovan defektom ostatka repa. Od 10 hormonima stimuliranih ICSI ciklusa, u 6 ciklusa su spermatozoidi za ICSI izabirani nasumce bez HOS testa. U 4 pacijenta oprani spermatozoidi su inkubirani u hipoosmotičkoj otopini i samo HOS pozitivni spermatozoidi (spermatozoidi s nabrekli repom), upotrebljeni su za ICSI. **Rezultati.** Od 6 ICSI ciklusa bez učinjene selekcije spermatozoida HOS testom, potpuni izostanak oplođnje zabilježen je u 3 ciklusa. U preostala 3 ciklusa samo 20,7% (6/29) jajnih stanica je oplođeno. U sva 4 ICSI ciklusa u kojima je pred njihovim injiciranjem za odabir spermatozoida upotrijebljen HOS test, stvoreni su zamci primjereni za prijenos u maternicu. Zabilježena je stopa oplođnje jajnih stanica od 81,8% (18/22), a nakon prijenosa zametka zabilježena je implantacija dva zametka i rođenje jednog zdravog djeteta. **Zaključak.** U slučajevima potpune nepokretljivosti spermatozoida, čak i u pacijenata gdje je uzrok neplodnosti nedostatak struktura repa spermatozoida, možemo očekivati dobru stopu oplođnje i trudnoće nakon selekcije spermatozoida HOS testom.

Introduction

Intracytoplasmic sperm injection (ICSI) is the most successful method of assisted reproduction in cases of severe male factor infertility.¹ The ICSI procedure allows fertilization and pregnancy also in those infertile couples, in which the male partner's semen contains only immotile sperm.² However, in this type of infertility the problem lies in differentiating between viable and non-viable sperm, as all sperm are immotile. Sperm viability

is usually established with tests based on dye exclusion (eosin Y, Hoechst 33258).^{3,4} This method, however, is suitable for diagnostic purposes only, owing to the possible toxic effects of these stains on the cells.

A characteristic of the intact cell membrane is its ability to permit the transport of molecules selectively. When sperm are exposed to hypo-osmotic conditions, water will diffuse over the plasma membrane into the cell and the tail of the sperm will start to swell.⁵ The hypo-osmotic

swelling test (HOS test) developed by Jeyendran *et al.*⁵ for diagnostic assessment of functional integrity of the sperm plasma membrane preserves sperm viability. The test is less invasive than supravital staining. Desmet *et al.*⁶ were the first to suggest the use of the HOS test to select viable immotile sperm for ICSI. The selected sperm were used for injection into one-day-old oocytes, which had not fertilized after the classic IVF procedure. Therefore the fertilization rate was low, amounting to 36%. The percentage of embryos suitable for embryo transfer or freezing amounted to 26% with respect to all injected oocytes. No pregnancies were reported. Casper *et al.*⁷ applied the method successfully in 8 ICSI cycles resulting in 3 pregnancies. The method of sperm selection with the HOS test has been applied successfully many times.^{8–10}

In our report we present the success of treating complete asthenozoospermia in 4 couples with the classic ICSI procedure, in which the sperm for injection were chosen randomly, and with an ICSI procedure, in which live sperm were chosen by means of the HOS test. In 2 couples out of 4 treated, the partner had a special form of complete sperm immotility, a sperm stump defect. A statistical analysis of the relationship between fertilization rate and use of HOS test was done with the program Statistica by StatSoft, with Yates' corrected chi-square test. Values of $P < 0.05$ were considered statistically significant.

Case presentation

In all of our 4 patients, a preliminary diagnostic analysis of the ejaculate was carried out. Asthenozoospermia with totally immotile spermatozoa (0% motility) was assessed as the main cause of infertility in all cases. Morphologic analysis according to strict Kruger's criteria¹¹ showed 3% and 4% of normal sperm forms in two men. In the remaining two men, irregularities in sperm tails in the sense of sperm stump defect were diagnosed.

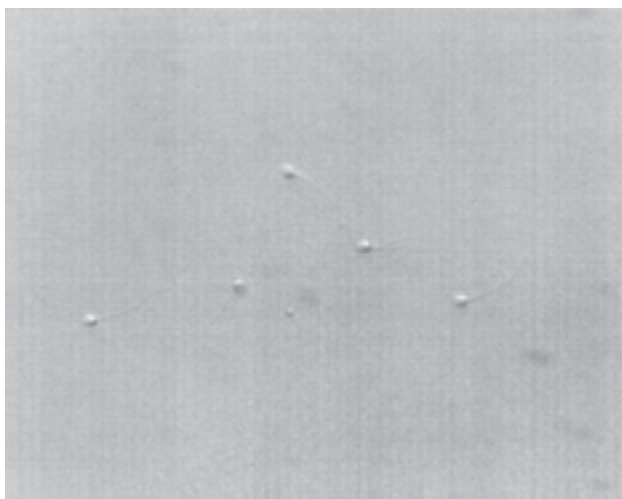


Figure 1. HOS-positive sperm selected for ICSI procedure in polyvinylpyrrolidone in a man with totally immotile spermatozoa; infertile couple D
Slika 1. HOS pozitivni spermij izabran za ICSI postupak u polivinilpirolidonu u muškarca s potpuno nepokretnim spermatozoidima; neplodni brak D

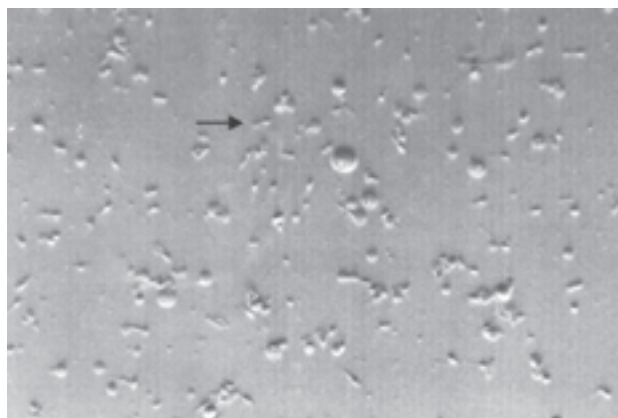


Figure 2. Sperm with stump defect in the hypo-osmotic solution. The arrow points to a viable sperm with swollen tail in a man with totally immotile spermatozoa combined with stump defect; infertile couple C

Slika 2. Spermij s defektom okrajka u hipoosmotskoj otopini. Strelica pokazuje spermija sposobnog za život s nabreknutim repom u muškarca s potpuno nepokretnim spermatozoidima u kombinaciji s defektom okrajka; neplodni brak C

All spermatozoa had very shortened tails and most of them also had a large cytoplasmic droplet around the neck.

The couples were prepared for the ICSI procedure. Ovulation was stimulated with recombinant FSH after GnRh inhibition with the agonist goserelin (Zoladex depot). In all 4 couples, 10 hormonally stimulated cycles were performed and 51 metaphase II oocytes were obtained. In the first 6 cycles with a total number of 29 metaphase II oocytes, the spermatozoa for ICSI were randomly selected without a HOS test. In the last 4 cycles with a total number of 22 metaphase II oocytes, the vital sperms were selected with the HOS test. The ICSI procedure was carried out according to standard protocol.¹²

The semen sample was rinsed in SPM medium (MediCult, Denmark) and the sediment resuspended in fresh medium. The sperm suspension was transferred to a hypo-osmotic solution (25mM sodium citrate and 75mM fructose in distilled water) and incubated at 37°C and an atmosphere with 5% CO₂ for 15 minutes. After incubation, using a finely drawn glass pipette, the sperm were transferred to a petri dish and covered with paraffin oil. In viable sperm, tail swelling was evaluated on an invert microscope IMT-2 (Olympus) equipped with micromanipulators (Narishige MO-188). HOS-positive sperm, i.e. sperm with swollen tail, were drawn into an injection pipette (Hunter, UK) and transferred to a drop of polyvinylpyrrolidone (PVP – Medicult) (Figure 1). In case of stump defect, selection of HOS-treated spermatozoa was more difficult. Since most shortened sperm tails were surrounded by a cytoplasmic droplet, only those spermatozoa were selected which showed a swelling only in the distal segment of the tail (Figure 2). The injection pipette was drawn over the tail of each sperm in order to damage the plasma membrane. Thus immobilized spermatozoa were then used for ICSI.

Table 1. Results of *in vitro* fertilization procedure with ICSI in infertile couples, in which the male partner's semen contained only immotile sperm, with selection of viable sperm the HOS test and without selection

Tablica 1. Rezultati postupka fertilizacije *in vitro* neplodnih brakova u kojima je sjeme muškog partnera sadržavalo samo nepokretne spermije. Selekcija viabilnih spermija HOS testom i bez selekcije

Infertile couple Neplodni brak	Cycle N ^o	HOS test	N ^o MII oocytes	N ^o fertilized oocytes*	N ^o embryos	N ^o embryos for ET	Pregnancy Trudnoća	Sperm pathology Patologija spermija
A	1	no	3	0	–	–	–	Complete immotility
B	1	no	6	3	3	3	no	Complete immotility, 'stump' defect
	2	no	2	0	–	–	–	
	3	no	6	2	2	2	no	
	4	no	3	1	1	0	–	
C	1	no	9	0	–	–	–	Complete immotility, 'stump' defect
	2	yes	4	3	3	3	no	
	3	yes	5	2	2	2	no	
D	1	yes	6	6	6	3	no	Complete immotility
	2	yes	7	7	7	2	yes	

* $P < 0.0001$ (Relationship between number of fertilized oocytes and use of HOS test – Usporedba broja oplodjenih oocita i uporabe HOS testa)

Oocytes were cultivated according to a 5-day-cultivation protocol in two sequential media. After injection they were transferred to BlastAssist System Medium 1 (M1) (MediCult). On the first day after puncture, fertilization was evaluated and the oocytes were transferred into fresh medium. On day 3, the embryos were placed in BlastAssist System Medium 2 (M2) (MediCult). On day 5, embryotransfer was carried out. Fourteen days after embryotransfer, pregnancy was assessed by determining serum beta human chorionic gonadotrophin (β -hCG).

Results

Characteristics and outcome of all 10 stimulated cycles are shown on Table 1. Of 6 ICSI cycles without a HOS test, total fertilization failure was noted in 3 cases. In the remaining 3, only 20.7% (6/29) oocytes were fertilized. Six embryos were obtained, but embryotransfer was done only in 2 cases. In the third patient we did not decide on embryotransfer owing to the very poor result of morphologic evaluation of the embryo. Neither of the cycles with embryotransfer resulted in pregnancy.

In 4 ICSI cycles with the HOS test, the fertilization rate was as high as 81.8% (18/22). Of 18 embryos obtained, 2 embryos per embryotransfer were chosen in 2 cases and 3 embryos were chosen in the remaining 2 cases. Pregnancy was assessed in one patient and US confirmed two gestation sacs with heartbeats. Tween pregnancy resulted in a delivery of a healthy boy, with a weight of 3629 g and length of 51 cm.

Statistical analysis showed that in cycles with the HOS test the fertilization rate was significantly higher ($\chi^2=16.4$, $p < 0.0001$) than in cycles without the HOS test.

Discussion

In some asthenozoospermics all sperm in the ejaculate are immotile. There is only a small percentage (0.2% to 0.5% infertile men) of necrozoospermia, i.e. all spermatozoa are dead.¹³ The cause for complete sperm immotility may also lie in ultrastructural irregularities of the sperm tail, including the immotile-cilia syndrome,

manifested as axoneme defects.¹⁴ Sperm immotility can also be caused by disturbances in enzyme function, such as decreased activity of the enzyme protein-carboxyl methylase.¹⁵ Besides, male genital tract infections can weaken the functioning of accessory sexual glands (epididymis, prostate and seminal vesicles), thus having a direct impact on decreasing sperm motility.¹⁶ In our investigated patients, inflammation was excluded as a possible cause of asthenozoospermia.

A special form of complete sperm immotility is that occurring in sperm with stunted tails. Baccetti *et al.*¹⁷ described two categories of stunted tails: the »short tail« and the »stump« defect. Both defects have the complete absence of the axoneme or the presence of an extremely short and abnormally organized axoneme in the short segments of the stunted tails in common.¹⁷ Table 1 shows that in the male partners of our four infertile couples, the sperm irregularities were expressed differently. In couples A and D, the male partners had spermatozoa with normally shaped tails, in couples B and C, however, the spermatozoa exhibited a stump defect. In all cases all spermatozoa were immotile. Performing the HOS test prior to the ICSI procedure is apparently also possible and reasonable in semen samples with exclusively stump tails, since the fertilization rate in couple C, in which the HOS test was used to select viable spermatozoa for ICSI, was higher (75.0% and 40.0%) as compared to the cycle in the same couple in which the HOS test was not applied (0.0%).

In cases of complete asthenozoospermia, when only immotile spermatozoa are found in the ejaculate, the fertilization rate after ICSI of sperm, selected at random from among immotile spermatozoa in the sample, is generally very low.⁷ The reason is probably the injection of a non-viable sperm, as it cannot be distinguished from a viable immotile sperm. Besides, in samples with complete asthenozoospermia, sperm viability is usually quite low (<50%).⁷ With a HOS test, viable sperm for injection can be selected from among immotile sperm, thus increasing the success of the ICSI procedure.

The male partner of our pregnant woman had a high percentage of viable sperm (63%). By the injection of

sperm, selected with the HOS test, all oocytes were fertilized. The cleavage rate (100%) as well as the blastulation rate (85.7%) was high also. Equally high fertilization and cleavage rates had been noted in the couple already at the time of the first IVF procedure, when the HOS test was also used to select viable sperm. However, the percentage of embryos developing to a blastocyst was lower (50%). Casper *et al.*⁷ report a 43% fertilization rate (but they had a similar one in couples in which the male partners had motile sperm). The cleavage rate was 39%. Poor results – a 36% fertilization rate and a 26% cleavage rate – are reported by Desmet *et al.*⁶ When deliberating the success of ICSI, other factors beside sperm viability must also be considered: the woman's age, oocyte quality, trained personnel. Several authors also report on pregnancy or birth after using the HOS test to select viable sperm prior to the ICSI procedure.^{7–10} As opposed to our own case, early preimplantation embryos were transferred to the uterus in all these cases.

Conclusion

We can say that a successful ICSI procedure depends largely on the selection of viable sperm from among immotile sperm in the semen sample, since in this case the fertilization rate is much higher than in case of random selection of sperm for ICSI from among immotile sperm. The HOS test is an effective method, even in semen samples with exclusively stump tails.

Acknowledgment. The authors wish to thank Marijana Gajšek-Marchetti, translator from the Medical Research Department, for her contribution in preparing the manuscript.

References

1. Palermo G, Joris H, Devroey P, Van Steirteghem AC. Pregnancies after intracytoplasmic sperm injection of single spermatozoa into an oocyte. *Lancet* 1992;340:17–8.
2. Palermo GD, Cohen J, Alikani M, Adler A, Rosenwaks Z. Intracytoplasmic sperm injection: A novel treatment for all forms of male factor infertility. *Fertil Steril* 1995;63:1231–40.
3. Eliasson R. Supravital staining of human spermatozoa. *Fertil Steril* 1977;28:1257.
4. Hong CY, Huang JJ, Wu P, Lo SJ, Wei YH. Fluorescence supravital stain of human sperm: correlation with sperm motility

measured by a transmembrane migration method. *Andrologia* 1988;20(6):516–20.

5. Jeyendran RS, Van der Ven HH, Perez-Pelaez M, Crabo BG, Zaneveld LJD. Development of an assay to assess the functional integrity of the human sperm membrane and its relationship to other semen characteristics. *J Reprod Fertil* 1984;70:219–28.

6. Desmet B, Joris H, Nagy Z et al. Selection of vital immotile spermatozoa for intracytoplasmic injection by the hypoosmotic swelling test. 10th Annual Meeting of ESHRE, June 1994, *Hum Reprod*;9(Suppl.4):24.

7. Casper RF, Meriano JS, Jarvi KA, Cowan L, Lucato ML. The hypo-osmotic swelling test for selection of viable sperm for intracytoplasmic sperm injection in men with complete asthenozoospermia. *Fertil Steril* 1996;65(5):972–6.

8. Ved S, Montag M, Schmutzler A et al. Pregnancy following intracytoplasmic sperm injection of immotile spermatozoa selected by the hypo-osmotic swelling-test: a case report. *Andrologia* 1997;29:241–2.

9. Wang CW, Lai YM, Wang ML, Lee JD, Soong YK. Pregnancy after intracytoplasmic injection of immotile sperm. *J Reprod Med* 1997;42(7):448–50.

10. Westlander G, Barry M, Petrucco O, Norman R. Different fertilization rates between immotile testicular spermatozoa and immotile ejaculated spermatozoa for ICSI in men with Kartagener's syndrome: case reports. *Hum Reprod* 2003;18(6):1286–8.

11. Kruger TF, Menkveld R, Stander FS et al. Sperm morphologic features as a prognostic factor in in-vitro fertilization. *Fertil Steril* 1986;46:1118–23.

12. Kovačić B, Vlasisavljević V, Reljić M, Gavrić Lovrec V. Clinical outcome of day 2 versus day 5 transfer in cycles with one or two developed embryos. *Fertil Steril* 2002;77(3):529–36.

13. Tournaye H, Liu J, Nagy Z et al. The use of testicular sperm for intracytoplasmic sperm injection in patients with necrozoospermia. *Fertil Steril* 1996;66(2):331–4.

14. Pedersen H, Rebbe H. Absence of arms in the axoneme of immotile human spermatozoa. *Biol Reprod* 1975;12:541–4.

15. Gagnon C, Sherins RJ, Phillips DM, Bardin CW. Deficiency of protein-carboxyl methylase in immotile spermatozoa of infertile men. *N Engl J Med* 1982;306(14):821–5.

16. Comhaire FH, Mahmoud AMA, Depuydt CE, Zalata AA, Christophe AB. Mechanisms and effects of male genital tract infection on sperm quality and fertilizing potential: the andrologist's viewpoint. *Hum Reprod Update* 1999;5(5):393–8.

17. Baccetti B, Burrini AG, Capitani S et al. Notulae seminologicae. 2. The 'short tail' and 'stump' defect in human spermatozoa. *Andrologia* 1993;25:331–5.

Članak primljen: 16. 09. 2004.; prihvaćen: 15. 11. 2004.

Address for correspondence: Mojca Čížek Sajko, B.S., Department of Reproductive Medicine and Gynecologic Endocrinology, Maribor Teaching Hospital, Ljubljanska 5, SI-2000 Maribor, Slovenia; e-mail: mojca.cs@sb-mb.si