

INCIDENCE OF SQUAMOUS METAPLASIA IN TRANSITIONAL CELL CARCINOMA OF URINARY BLADDER

Drinko Baličević¹, Irena Novosel² and Ahmed Pirkić¹

¹Ljudevit Jurak Clinical Department of Pathology, Sestre milosrdnice University Hospital, Zagreb, Croatia

²Department of Pathology, Dr Ivo Pedišić County Hospital, Sisak, Croatia

SUMMARY – Squamous metaplasia in transitional cell carcinoma of urinary bladder is considered as an adverse prognostic factor. Those patients have weaker response on therapy and lower survival rate. The aim of our study was to determine the incidence of squamous metaplasia in bioptic material according to histologic grade and growth pattern.

In our study we used pathohistological data of 1781 patients operated for urinary bladder cancer in Department of Urology of Sestre milosrdnice University Hospital during the period from 1989 to 2000

Squamous metaplasia was found in 5.7% of patients. According to growth pattern, this phenomenon is more frequent in patients with solid growth pattern. In papillary cancers, the higher incidence of squamous metaplasia was determined in G1 and G2 histologic grade, while in solid growth pattern, the most cases with squamous metaplasia or over 90% were of G3 histologic grade.

Muscle layer invasion were present in high percentage of both, papillary and solid urothelial cancers with squamous metaplasia, which imply the high malignant potential of cancers with foci of squamous metaplasia.

Key words: *bladder, transitional cell carcinoma, squamous metaplasia*

Introduction

Transitional cell urothelial carcinoma of the bladder is the most frequent malignant disease of lower urologic system.^{1,2} Urothelial carcinomas can have different pathohistological grade and they can show exophytic papillary pattern of growth, endophytic solid growth pattern or as well they can have combination of those two growth patterns.³

The major established prognostic factors are grade and stage, although some studies deals with hydronephrosis, anemia, size, expression of blood group substances, expression of epidermal growth factor receptor, mutation of p53 and upregulation of Rb and other oncogene expression.⁴

In recent literature focal appearance of squamous metaplasia in urothelial cancers is considered to be adverse prognostic factor.^{5,6} These cancers show more aggressive behavior and are treated as more malignant in relation to urothelial cancer without this phenomenon. The treatment

response on radiotherapy of those patients is weaker and therefore the survival rate of patients is lower.⁷⁻¹⁰

Materials and methods

The study is based on bioptic material of 1781 urinary bladder cancers collected in data base of Ljudevit Jurak Department of Pathology, Sestre milosrdnice Hospital University during the period from 1989-2000. The aim of our survey was to analyse the incidence of squamous metaplasia in urothelial carcinoma of bladder according to these two most frequent growth patterns and histologic grade. The latter was evaluated according to criteria established by WHO in 1973.¹¹

Urothelial carcinoma that showed only papillary and only solid growth pattern in the moment of diagnosis were included in our survey.

Results

Among 1781 urothelial bladder cancers there were 102 or 5.7% with squamous metaplasia (Figure 1).

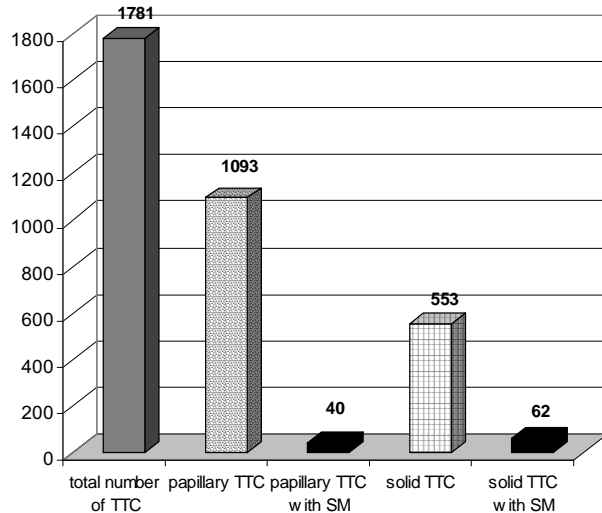


Figure 1. Incidence of squamous metaplasia (SM) in transitional cell cancers (TTC) of urinary bladder according to growth pattern

Our survey revealed 1093 or 61.4% cancer with papillary growth pattern. Among them there were 40 or 3.7% with squamous metaplasia. Solid pattern of growth was present in 553 or 31% of cancer. Squamous metaplasia was present in 62 of them or 11.2% (Figure 2).

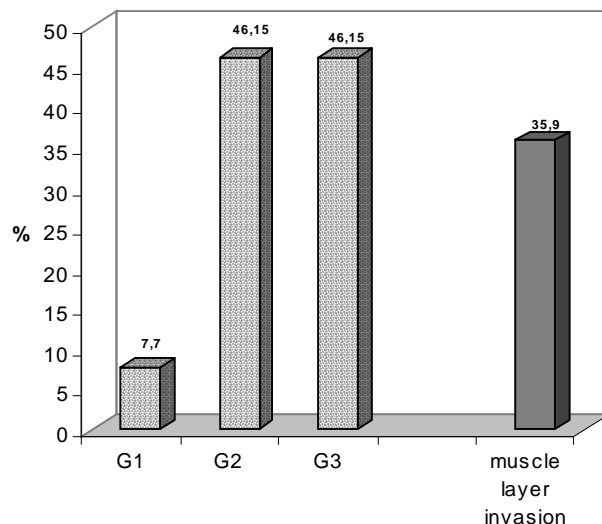


Figure 2. Incidence of squamous metaplasia (SM) in papillary transitional cell cancers (TTC) of urinary bladder according to histologic grade

In the moment of pathohistological evaluation of biptic material, there were 135 carcinoma (7,6%) with combination of both elementary growth patterns. That group of carcinomas as not included in our survey.

Among cancers with papillary growth pattern, foci of squamous metaplasia were distinguished in 18 cases with G2 histologic grade and 18 cases of G3, which means that squamous metaplasia was found out in 46.1% in each of previously mentioned grades. Only 7.7% of pathohistologically examined cancers were of G1 histologic grade. Invasion to muscular layer was determined in 14 cases or 35.9% of all tumors (Figure 3).

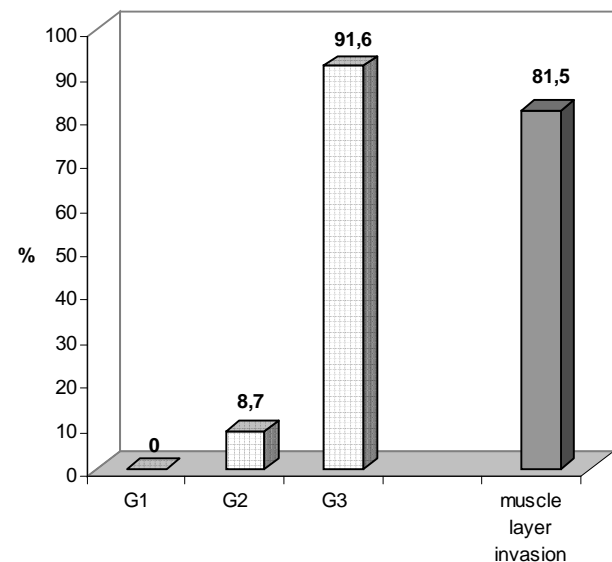


Figure 3. Incidence of squamous metaplasia (SM) in solid transitional cell cancers (TTC) of urinary bladder according to histologic grade

The squamous metaplasia in cancers with solid growth pattern was determined in 58 cases of G3 histologic grade or 91,6% of biptic material, and 5 cases of G2 or 8.7%. Muscular invasion could be seen in 52 cancers of solid growth pattern with foci of squamous metaplasia or in 81.5%.

Discussion

Foci of squamous metaplasia were discovered in 5.7% of patients with transitional cell carcinoma.

In order to comment such an incidence properly, the fact that there was not possible to examine pathohistolog-

ically the total tumor mass but only the cystoscopically taken scant biopsy must be taken into consideration. It specially concerns the papillary cancers of G1 and G2 histologic grade in which muscular layer was not present in bioptic material and therefore the exact invasion could not be revealed.

Interestingly, there was no transitional cell carcinoma of solid growth pattern of G1 histologic grade with foci of squamous metaplasia. In the same time there were 7.7% of papillary cancers with this phenomenon. This obvious difference in appearance of foci of squamous metaplasia in G1 urothelial bladder cancers of solid and papillary growth pattern imply possible different biological malignant potential of those two groups of cancers.

In addition to the previous statements, the fact that 91.6% of patients with solid transitional cell carcinoma with foci of squamous metaplasia had G3 histologic grade of tumor at the time of establishing the diagnosis must not be omitted. More than three quarters of these patients had invasion in muscular layer which suggest highly aggressive character of tumors with this histologic grade and growth pattern.

In spite of objective lack of muscular layer in part of bioptic material with papillary cancers, we found out that 35.9% of those cancers had muscular invasion.

Conclusion

Among 1781 biopsies of urothelial cancers during the period from 1989-2000 there were in total 102 or 5.7 % transitional cell carcinomas with foci of squamous metaplasia.

In studied material there were 61.4% cancers with papillary and 31% with solid growth pattern.

According to growth pattern, higher incidence of foci of squamous metaplasia was in solid transitional cell carcinoma than in those of papillary growth pattern, 11.2% and 3.7%, respectively.

According to histologic grading, the incidence of squamous metaplasia was 7.7% in G1 and 46.1% in G2 histologic grade of papillary cancers. In cancers of solid growth pattern, 91.6% of patients with foci of squamous metaplasia had G3.

According to our survey, the finding of squamous metaplasia in bioptic material of transitional cell carcinoma strongly imply simultaneous invasion of muscular layer, especially concerning urothelial cancers of solid growth pattern. Therefore squamous cell metaplasia could be considered as adverse prognostic factor which could be considered- by both pathologist and clinician- as more malignant cancer behavior.

Sažetak

UČESTALOST PLOČASTE METAPLAZIJE U KARCINOMA PRIJELAZNOG EPITELA MOKRAĆNOG MJEHURA

D. Baličević¹, I. Novosel² and A. Prkić³

Pločasta metaplazija u karcinomima urotela mokraćnog mjehura smatra se jednim od važnih, prognostički lošijih znakova ove bolesti. Bolesnici s karcinomima urotela koji sadrže žarišta pločaste metaplazije, slabije reagiraju na terapiju, i imaju značajno kraće preživljavanje. Cilj istraživanja bio je utvrditi učestalost pločaste metaplazije u karcinomima urotela mokraćnog mjehura s obzirom na histološki gradus i način rasta.

U radu je pregledana 1771 biopsija karcinoma mokraćnog mjehura pacijenata operiranih na Klinici za urologiju Kliničke bolnice «Sestre milosrdnice».

Pločasta metaplazija nađena je u 102 (5,7%) bolesnika. Ova promjena je češće bila zastupljena u karcinomima solidnog načina rasta, osim kod papilarnih karcinoma urotela G1 i G2 stupnja diferenciranosti.

Invazija u mišićni sloj stijenk e mokraćnog mjehura nađena je u visokom postotku u istraživanih karcinoma i papilarnog i solidnog načina rasta, što nedvosmisleno govori o značajnim visokim malignim potencijalima karcinoma urotela s ovom promjenom.