

Vitamin C pretreatment protects from nickel-induced acute nephrotoxicity in mice

Imed-Eddine Kadi and Faouzi Dahdouh

Department of Biochemistry and Microbiology, Faculty of Sciences,
Mohamed Boudiaf M'Sila University, Algeria

[Received in December 2015; CrossChecked in December 2015; Accepted in July 2016]

Nickel is an abundant carcinogenic and nephrotoxic metal whose activity leads to renal impairment. Previous studies have shown a protective effect of simultaneous vitamin C administration on acute and chronic nickel toxicity. However, very little research relating to the effect of vitamin C pretreatment in preventing nickel-induced acute nephrotoxicity is available. Therefore, the present study aimed to determine the efficiency of vitamin C (VC) pretreatment in preventing acute renal toxicity of nickel. Mice were pretreated orally with vitamin C (16.6 mg kg⁻¹ body weight, b.w.) for seven consecutive days, prior to intraperitoneal (i.p.) administration of nickel chloride at different doses (3, 5, and 10 mg Ni kg⁻¹ b.w.) for an exposure period of 24 hours. Thereafter, animals were killed and kidney tissue and blood samples were taken for histological examination and biochemical marker analyses. Vitamin C pretreatment alone did not alter the levels of serum kidney markers (creatinine, urea, and uric acid). However, treatment with Ni alone showed a significant increase in the levels of serum creatinine, urea, and uric acid with marked necrotic epithelial cells and infiltration by inflammatory cells in kidney sections as compared to the control group. Pretreatment with vitamin C and treatment with Ni at all doses tested for 24 hours showed a significant decrease in the levels of serum creatinine, urea, and uric acid, as well as an improvement in histological changes compared to those previously seen in the group treated with Ni alone. It is concluded that vitamin C pretreatment effectively improved renal function and tissue damage caused by nickel.

KEY WORDS: *creatinine; histopathology; kidney dysfunction; urea; uric acid*

Nickel is a ubiquitous environmental pollutant used extensively in industry for various commercial processes including: production of steel, metal alloys, batteries, coins, magnets, paints, and medical implants (1, 2). Humans are exposed to nickel by ingesting contaminated foodstuffs or inhaling cigarette smoke (3). Nickel is transported by blood and is retained by various tissues or excreted, mainly through urine, making thus the kidney the target organ of nickel toxicity and carcinogenicity (4-8). Several reports have evidenced that nickel is able to cause harmful effects to human and animal health, which increase organ cancer and injury risk (9, 10). Nickel is a well-known cytotoxic metal that may affect various cell lines including kidney cells. It may generate reactive oxygen species, which leads to lipid peroxidation and oxidation of DNA and proteins and results in cell apoptosis and nephrotoxicity (11, 12). Recently, antioxidant supplements have received much attention due to their antioxidant activity and a free radical-scavenging ability to quench reactive oxygen species (ROS) that induce oxidative tissue injuries and cellular damage (13). Vitamin C (ascorbic acid or ascorbate) is a natural substance abundant in fresh fruits and vegetables (14). It is also a powerful water-soluble antioxidant and a free radical

scavenger that acts as a reducing agent, donating electrons to ROS free radicals, making these more stable and less reactive (15). Additionally, vitamin C contributes to the restoration of depleted vitamin E and intracellular glutathione levels. This helps to actively fight oxidative stress-mediated cellular damage that leads to cell death (16). An *in vitro* study (17) showed that nickel-induced oxidative stress, mediated via an increased expression of JMJD1A and the related hypoxia-response genes GLUT1 and HIF-1 α in human embryonic kidney cells, was greatly reversed by ascorbate. In experimental animals, simultaneous administration of vitamin C with nickel reduced oxidative damage to the biological system by boosting the antioxidant protective system to prevent lipid peroxidation and oxidative stress in the liver (18) and the lung (19). Furthermore, vitamin C at a single (250 mg kg⁻¹ b.w.) and multiple doses (500 mg kg⁻¹ b.w.) administered to mice one hour prior to cisplatin i.p. injection showed an improvement of the antioxidant status of cells, functional markers and kidney histopathological changes (20). Similarly, Karabulut-Bulan et al. (21) have demonstrated that vitamin C given to rats (250 mg kg⁻¹ a day) one hour prior to cadmium administration consecutively over eight days attenuated cadmium-induced kidney oxidative injury. It was also reported that vitamin C pretreatment protected against long-term exposure to lead-induced histopathological

Correspondence to: Faouzi Dahdouh, Department of Biochemistry and Microbiology, Faculty of Sciences, Mohamed Boudiaf M'Sila University, 28000, Algeria. E-mail: faouzidahdouh@gmail.com

changes in the kidney of rats (22). To our knowledge, there is no data showing the protective effect of vitamin C pretreatment in preventing renal impairment following exposure to different doses of nickel. Therefore, the current study was designed to investigate the beneficial effect of vitamin C pretreatment against Ni-induced nephrotoxicity in male mice.

MATERIALS AND METHODS

Animals

Forty-eight male Swiss albino mice with a mean of 27.31 ± 0.17 g (Animal Unit of "Pasteur" Institute of Algiers, Algeria) were used in this study. The animals were cared for in compliance with the guidelines of the Institutional Animal Ethical Committee Research (AFRO. No 478, 2009), as approved by the Faculty of Sciences at Annaba University, and the study was conducted in accordance with the "Guide for the Care and Use of Laboratory Animals". Mice were acclimatised to our laboratory conditions for two weeks and were thereafter weighted and divided into six equal groups. Normal mice chow (Oneb, Béjaïa, Algeria) and water were provided ad libitum throughout the period of the study.

Chemicals

Ni as nickel chloride, NiCl_2 , and vitamin C (L-ascorbic acid: $\text{C}_6\text{H}_8\text{O}_6$) and all other chemicals used in the experiment were purchased from Sigma Chemical Inc. (St. Louis, MO, USA).

Experimental procedure

The acclimatised animals were weighted and randomly divided into six experimental groups of six animals each. Group I (control group): mice had free access to standard diet and water ad libitum. Group II (VC): mice were treated orally with vitamin C at a dose of 16.6 g kg^{-1} of b.w. for seven consecutive days. Groups III (Ni3), IV (Ni5), and V (Ni10): NiCl_2 was injected i.p. at doses of 3, 5, and 10 mg Ni per kg of b.w., respectively. Animals in these groups were killed 24 h after Ni injection. Groups VI (Ni3+VC), VII (Ni5+VC), and VIII (Ni10+VC): mice were pretreated with vitamin C for seven consecutive days. On day 8, the animals received i.p. 3, 5, and 10 mg of Ni per kg b.w., respectively, over 24 h. Animals were killed after being anaesthetised with chloroform. Blood was collected into lithium heparin blood tubes and placed immediately into an ice bath until centrifugation at $3,000 \text{ g}$ for 10 min at $+4^\circ\text{C}$ (Hettich Mikro 185 microliter centrifuge).

Serum samples were extracted and analysed for nephritic markers (creatinine, urea, and uric acid). The kidney was removed and processed immediately for histological examination.

Vitamin C and nickel chloride doses were chosen according to the protocol established by Dhir et al. (23) and Chen et al. (24), respectively.

Determination of nickel concentration

The concentration of Ni in renal tissue was determined as previously described (25). Briefly, 1 g of fresh tissue was homogenised in cold KCl using a tissue homogeniser (SCIOGEX D160). Then, the homogenate was added to 3 ml of mixed acid solution ($\text{HClO}_4/\text{HNO}_3$, 1:3, v/v). After that, the samples were digested using microwave heating, and Ni concentration was determined using a Perkin-Elmer model 5100 PC Flame Atomic Absorption Spectrophotometer (FAAS).

Biochemical assays

Serum biochemical markers: creatinine, urea, and uric acid were measured as functional markers for nephrotoxicity. They were assessed using commercially available diagnostic kits (Spinreact, Spain, ref: Creatinine-1001111, urea-1001329, and uric acid-1001011), according to the enzymatic colorimetric method and using a spectrophotometer (Jenway 6505, Jenway LTD, UK).

Histopathological evaluation

Removed kidney samples were fixed for 48 h in 10 % formalin-saline (5-6 μm thick) and dehydrated by passing successfully in different mixtures of ethyl alcohol-water, cleaned in xylene, and embedded in paraffin. Sections of the tissue (5-6 μm thick) were prepared using a rotary microtome and were stained with haematoxylin and eosin (H&E) dye, which was mounted in a neutral deparaffinated xylene medium for microscopic examinations. Microscopic images were taken by a digital camera (Leica MC190-HD, Germany) mounted on a Leica DM-1000 microscope with $40\times$ of objective lens.

Statistical analysis

Data were analysed using the GraphpadPrism statistical program (software version 6.0). All results are given as means \pm SE. Comparison between group means of each parameter separately was tested by one-way ANOVA repeated measures, followed by the Protected Least Significant Difference Fisher's test (PLSD Fisher) and the level of significance was set at $p < 0.05$.

RESULTS

Clinical signs of toxicity

At the end of the experiment, vitamin C treated mice were healthy and their behavioural patterns were comparable to controls. However, in the nickel treated groups, several

clinical signs such as reduced activity, weakness, and reduced food and water intake were observed within 24 h of Ni injection. These clinical signs were almost absent in animals pretreated with vitamin C followed by Ni injection.

Ni concentration in the kidney

As seen in Figure 1, exposure to nickel at various doses (3, 5, and 10 mg kg⁻¹ b.w.) significantly increased its concentration in the kidney as compared to that seen in control mice (respectively, $p < 0.01$, $p < 0.001$, $p < 0.001$). But when nickel and vitamin C pretreated and nickel only groups were compared, a significant decrease ($p < 0.001$ Ni3; $p < 0.01$ Ni5 and Ni10) of Ni level in the kidney was observed.

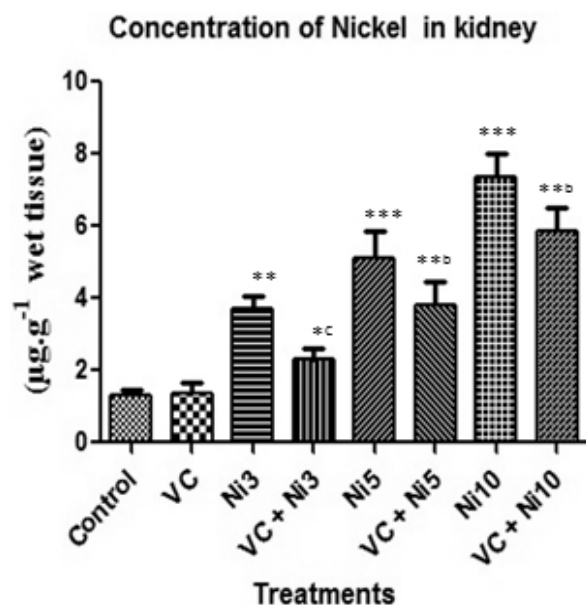


Figure 1 Vitamin C pretreatment reduced tissue Ni concentration in the kidney, after 24 h of i.p. administration of NiCl₂

Effect of treatments on functional kidney markers

Treatment of mice with 3, 5, and 10 mg kg⁻¹ b.w. of nickel chloride for 24 hours caused a significant increase ($p < 0.01$) in the levels of serum nephritic markers (urea, uric acid and creatinine) when compared with control group. Similarly, vitamin C pretreatment prior to Ni administration showed a significant increase ($p < 0.05$) in the above mentioned parameters when compared with those seen in controls. But when compared with Ni3, Ni5, and Ni10 treated groups, a significant decrease (respectively, $p < 0.05$; $p < 0.01$; $p < 0.001$) was noticed (Fig. 2).

Kidney histopathological changes

H&E kidney stained sections showed a normal structure of the renal cortex and medulla of control mice and the mice treated with vitamin C alone (Fig. 3A and B). Ni treatment resulted in kidney histopathological changes as indicated by tubular degeneration and necrosis and infiltration by

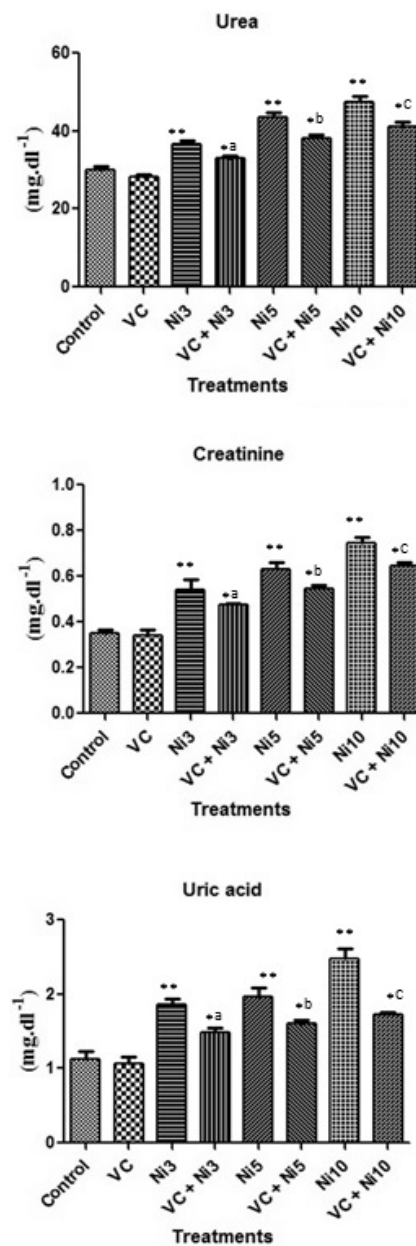


Figure 2 Vitamin C pretreatment improves kidney functional markers upon Ni toxicity.

Results are mean±S.E. One-way ANOVA and Protected Least Significant Difference Fisher's test. ($n=6$ for all groups). * $p < 0.05$, ** $p < 0.01$, *** $p < 0.001$: VC; N3; VC+Ni3; Ni5; VC+Ni5; Ni10; VC+Ni10 versus Control. ^a $p < 0.05$, ^b $p < 0.01$, ^c $p < 0.001$: VC+Ni3 versus Ni3; VC+Ni5 versus Ni5; VC+Ni10 versus Ni10

inflammatory cells (fig. 3C, D, and E). The severity of tissue alterations increased commensurate to the increase in nickel doses. On the contrary, kidney histology was somewhat dependently regained in the combined treatments following the decrease in Ni doses (Fig. 4F, G, and H).

DISCUSSION

The study provides evidence that pretreatment of mice with vitamin C is nephroprotective against acute toxicity

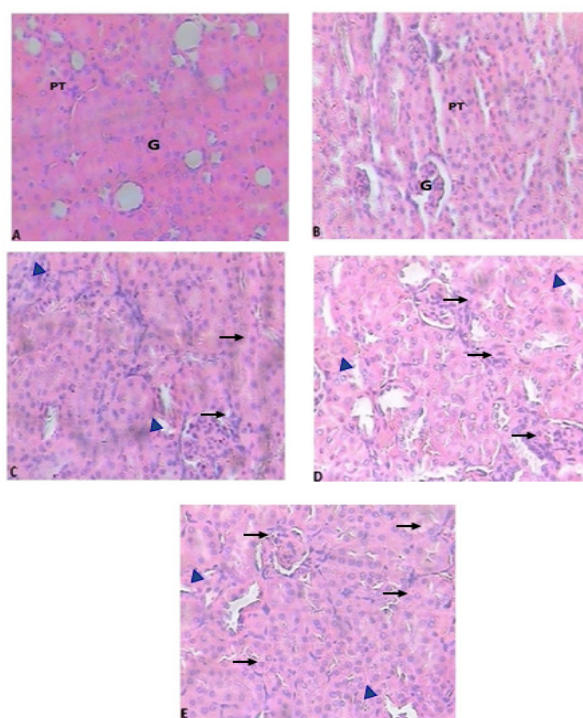


Figure 3 Hematoxylin and eosin-stained sections of the kidneys from control mice (A), vitamin C treatment (B) and Ni treated mice: 3 mg Ni kg⁻¹ b.w. (C); 5 mg Ni kg⁻¹ b.w. (D); and 10 mg Ni kg⁻¹ b.w. (E) (x400).

(A) and (B) Kidney sections from control mice and those that received vitamin C alone by oral gavage in a dose of 16.6 mg kg⁻¹ b.w. for seven consecutive days show a normal structure of glomeruli ‘‘G’’ and medulla, with no proximal tubular ‘‘PT’’ necrosis.

(C), (D), and (E) Kidney sections from mice that received 3, 5, and 10 mg kg⁻¹ b.w., i.p., of Ni and that were killed at 24 h after Ni injection show up to 40 %, 60 %, and 80 %, respectively, the presence of renal tubular degeneration and necrosis (black arrow) and infiltration by inflammatory cells (blue arrow head)

of nickel at all tested doses (3, 5, and 10 mg kg⁻¹ b.w.) through a substantial decrease in the concentration of serum urea, uric acid, and creatinine and the concentration of Ni in renal tissue. Furthermore, the expressed histologic damage scores were lower, showing minimal tubular generation, necrosis, and infiltration by inflammatory cells that were induced by nickel treatment. The nephrotoxic effect of Ni is observed in a significant increase in the serum level of urea and creatinine, which may result in a decrease in reabsorption at renal epithelium and disruption of glomerular filtration rate. This increases the risk of renal failure (26). The measurements of creatinine, urea, and uric acid are considered a tool in the clinical diagnosis of renal dysfunction following acute and chronic oxidative kidney injury (27, 28). The increased level of Ni in the kidney that was observed after Ni treatment could be explained by high affinity of metallothionein, a metal binding protein for Ni (29). The adverse effects of Ni on kidney function are potentially related to oxidative stress and overproduction of free radicals that can cause oxidation of biomolecules

(lipids, proteins, DNA), eventually leading to renal cell death (30). Vitamin C pretreatment prior to Ni administration reversed kidney function by normalising the increased renal parameters and histopathological changes, as well as by reducing Ni accumulation in the kidney compared to mice that received Ni alone. This is in line with what was previously reported on the simultaneous administration of vitamin C supplementation to rodents against nickel-induced renal oxidative damage (31, 32). In parallel, oral administration of a single dose of vitamin C (150–350 mg kg⁻¹ b.w., i.p.) to rats, six hours prior to acute administration of cisplatin (6 mg kg⁻¹ b.w., i.p.), for four consecutive days showed remarkable protection against kidney damage induced by cisplatin (33). Also, Shaban El-Neweshy and Said El-Sayed (22) have investigated the nephroprotective effect of vitamin C (20 mg kg⁻¹ b.w., oral route) pretreatment against renal histopathological changes following oral administration of lead to rats, 30 min after vitamin C administration.

These results suggested that vitamin C could strongly enhance the cellular antioxidant capacity to counteract ROS-mediated free radical reactions before they reached their cellular targets. As reported, vitamin C reduces the absorption of dietary nickel in intestine (34), suggesting

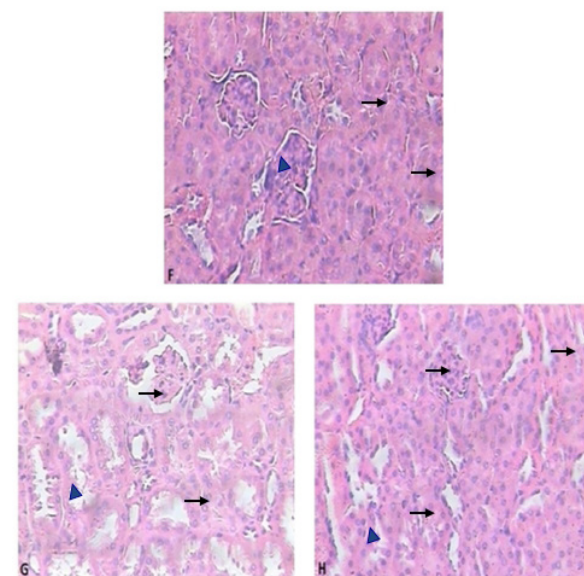


Figure 4 Hematoxylin and eosin-stained sections of mice kidney after combined treatments (Ni+VC) (x400).

(F), (G), and (H) Kidney sections from the mice pretreated with a single dose (16.6 mg kg⁻¹ b.w.) of vitamin C for seven consecutive days prior to the injection, i.p., of 3, 5, and 10 mg kg⁻¹ b.w. of Ni and killed 24 h after Ni treatment show mild tubular degeneration and necrosis with presence of some inflammatory cells.

Treatment groups VC: Mice received vitamin C by oral gavage in a dose of 16.6 mg kg⁻¹ b.w. per day for seven consecutive days. **Ni3, Ni5, and Ni10:** NiCl₂ was injected intraperitoneally at doses of 3, 5, and 10 mg kg⁻¹ b.w. respectively, and the mice were killed 24 h after Ni injection. **VC+Ni3, VC+Ni5 and VC+Ni10:** Mice were pretreated with vitamin C (16.6 mg kg⁻¹ b.w.) for seven consecutive days. On day 8, Ni was injected intraperitoneally at 3, 5, and 10 mg kg⁻¹ respectively, and the animals were killed 24 h after Ni injection

that vitamin C may act as a chelating agent of nickel leading to a lower cellular uptake of nickel, protecting consequently against kidney oxidative injury.

In conclusion, pretreatment with vitamin C effectively ameliorated kidney dysfunction by decreasing the serum functional kidney markers (urea, creatinine, and uric acid) and the concentration of Ni in the kidney of mice caused by acute administration of various doses (3, 5, and 10 mg/kg¹) of nickel. Thus, administration of vitamin C prior to nickel treatment provides an efficient protection against Ni-induced acute nephrotoxicity in mice. Further studies need to ascertain the protective effect of pretreatment with more doses of vitamin C against Ni-induced kidney oxidative stress, and therefore these should focus on the nephroprotective effect of vitamin C in a dose dependent manner.

Acknowledgements

The authors would like to thank Dr. Boudjellal Amel and Mr. Benkhaled Abedarahimof Mohamed Boudiaf, M'Sila University for their technical assistance.

Conflict of interest

All authors have declared that no competing interests exist.

REFERENCES

- De Brouwere K, Buekers J, Cornelis C, Schlekot CE, Oller AR. Assessment of indirect human exposure to environmental sources of nickel: oral exposure and risk characterization for systemic effects. *Sci Total Environ* 2011;419:25-36. doi: 10.1016/j.scitotenv.2011.12.049
- Feilzer AJ, Kleverlaan CJ, Prahl C, Muris J. Systemische reacties op de mondtoegepaste metaallegeringen [Systemic reactions to orally applied metal alloys, in Dutch]. *Ned Tijdschr Tandheelkd* 2013;120:335-41. doi: 10.5177/ntvt.2013.06.13126
- Edelman DA, Rogglit VL. The accumulation of nickel in human lungs. *Environ Health Perspect* 1989;81:221-4. PMID: 2759060
- Severa J, Vyskocil A, Fiala Z, Cizkova M. Distribution of nickel in body fluids and organs of rats chronically exposed to nickel sulphate. *Hum Exp Toxicol* 1995;14:955-8. doi: 10.1177/096032719501401204
- Sarkar B. Nickel in blood and kidney. In: Brown SS, Sunderman FW Jr, editors. *Nickel toxicology*. New York (NY): Academic Press; 1980. p. 81-4.
- Arena VC, Sussman NB, Redmond CK, Costantino JP, Trauth JM. Using alternative comparison populations to assess occupation-related mortality risk results for the high nickel alloys workers cohort. *J Occup Environ Med* 1998;40:907-16. PMID: 9800177
- Sunderman FW Jr, Maenza RM, Hopfer SM, Mitchell JM, Allpass PR, Damjanov I. Induction of renal cancers in rats by intrarenal injection of nickel subsulfide. *J Environ Pathol Toxicol* 1979;2:1511-27. PMID: 528855
- Minigaliyeva IA, Katsnelson BA, Privalova LI, Gurvich VB, Panov VG, Varaksin AN, Makeyev OH, Sutunkova MP, Loginova NV, Kireyeva EP, Grigoryeva EV, Slyshkina TV, Ganebnykh EV, Grebenkina SV. Toxicodynamic and toxicokinetic descriptors of combined chromium (VI) and nickel toxicity. *Int J Toxicol* 2014;33:498-505. doi: 10.1177/1091581814555915
- Heim HE, Bates HK, Rush RE, Oller AR. Oral carcinogenicity study with nickel sulfate hexahydrate in Fischer 344 rats. *Toxicol Appl Pharmacol* 2007;224:126-37. doi: 10.1016/j.taap.2007.06.024
- Chen CY, Lin TK, Chang YC, Wang YF, Shyu HW, Lin KH, Chou MC. Nickel(II)-induced oxidative stress, apoptosis, G2/M arrest, and genotoxicity in normal rat kidney cells. *J Toxicol Environ Health A* 2010;73:529-39. doi: 10.1080/15287390903421250
- Wang YF, Shyu HW, Chang YC, Tseng WC, Huang YL, Lin KH, Chou MC, Liu HL, Chen CY. Nickel (II)-induced cytotoxicity and apoptosis in human proximal tubule cells through a ROS- and mitochondria-mediated pathway. *Toxicol Appl Pharmacol* 2012;259:177-86. doi: 10.1016/j.taap.2011.12.022
- Chakrabarti SK, Bai C. Role of oxidative stress in nickel chloride-induced cell injury in rat renal cortical slices. *Biochem Pharmacol* 1999;58:1501-10. doi: 10.1016/S0006-2952(99)00232-4
- Valko M, Leibfritz D, Moncol J, Cronin MT, Mazur M, Telser J. Free radicals and antioxidants in normal physiological functions and human disease. *Int J Biochem Cell Biol* 2007;39:44-84. doi: 10.1016/j.biocel.2006.07.001
- Ariharan VN, Kalirajan K, Meena Devi VN, Prasad NP. An exotic fruit which forms the new natural source for vitamin-C. *Rasayan J Chem* 2012;5:356-9.
- Cathcart RF. Vitamin C: the nontoxic, nonrate-limited, antioxidant free radical scavenger. *Med Hypotheses* 1985;18:61-77. doi: 10.1016/0306-9877(85)90121-5
- Guaiquil VH, Vera JC, Golde DW. Mechanism of vitamin C inhibition of cell death induced by oxidative stress in glutathione-depleted (HL60) cells. *J Biol Chem* 2001;276:40955-61. doi: 10.1074/jbc.M106878200
- Guo X, Lu J, Wang Y, Gui Y, Duan X, Cai Z. Ascorbate antagonizes nickel ion to regulate JMJD1A expression in kidney cancer cells. *Acta Biochim Biophys Sin (Shanghai)* 2012;44:330-8. doi: 10.1093/abbs/gms004
- Das KK, Das SN. Studies on the role of ascorbic acid on nickel induced hepatic nucleic acid concentrations in rats. *J Basic Clin Physiol Pharmacol* 2004;14:185-95. doi: 10.1515/JBCPP.2004.15.3-4.185
- Gupta AD, Patil AM, Ambekar JG, Das SN, Dhundasi SA, Das KK. L-ascorbic acid protects the antioxidant defense system in nickel-exposed albino rat lung tissue. *J Basic Clin Physiol Pharmacol* 2006;17:87-100. doi: 10.1515/JBCPP.2006.17.2.87
- Ajith TA, Abhishek G, Roshny D, Sudheesh NP. Co-supplementation of single and multi doses of vitamins C and E ameliorates cisplatin-induced acute renal failure in mice. *Exp Toxicol Pathol* 2009;61:565-71. doi: 10.1016/j.etp.2008.12.002
- Karabulut-Bulan O, Bolkent S, Yanardag R, Bilgin-Sokmen B. The role of vitamin C, vitamin E, and selenium on cadmium-induced renal toxicity of rats. *Drug Chem Toxicol* 2008;31:413-26. doi: 10.1080/01480540802383200

22. Shaban El-Neweshy M, Said El-Sayed Y. Influence of vitamin C supplementation on lead-induced histopathological alterations in male rats. *Exp Toxicol Pathol* 2011;63:221-7. doi: 10.1016/j.etp.2009.12.003
23. Dhir H, Agarwal K, Sharma A, Talukder G. Modifying role of *Phyllanthus emblica* and ascorbic acid against nickel clastogenicity in mice. *Cancer Lett* 1991;59:9-18. PMID: 1878862
24. Chen CY, Huang YL, Lin TH. Effects of vitamin A pretreatment on nickel-induced lipid peroxidation and concentration of essential metals in liver, kidney and lung of mice. *Arch Toxicol* 1998;72:381-6. doi: 10.1007/s002040050517
25. Horak E, Sunderman FW Jr. Nephrotoxicity of nickel carbonyl in rats. *Ann Clin Lab Sci* 1980;10:425-31. PMID: 7425533
26. Vyskocil A, Viau C, Cizková M. Chronic nephrotoxicity of soluble nickel in rats. *Hum Exp Toxicol* 1994;13:689-93. PMID: 7826687
27. Nabavi SF, Nabavi SM, Moghaddam AH, Naqinezhad A, Bigdellou R, Mohammadzadeh S. Protective effects of *Allium paradoxum* against gentamicin-induced nephrotoxicity in mice. *Food Funct* 2012;3:28-9. doi: 10.1039/c1fo10173k
28. Sultana S, Verma K, Khan R. Nephroprotective efficacy of chrysin against cisplatin-induced toxicity via attenuation of oxidative stress. *J Pharm Pharmacol* 2012;64:872-81. doi: 10.1111/j.2042-7158.2012.01470.x
29. Novelli ELB, Hernandez RT, Novelli Filho JL VB, Barbosa LL. Differential/combined effect of water contamination with cadmium and nickel on tissues of rats. *Environ Pollut* 1998;103:295-300. doi: 10.1016/S0269-7491(98)00109-2
30. Amudha K, Pari L. Beneficial role of naringin, a flavanoid on nickel induced nephrotoxicity in rats. *Chem Biol Interact* 2011;193:57-64. doi: 10.1016/j.cbi.2011.05.003
31. Chatterjee K, Chakarborty D, Majumdar K, Bhattacharyya A, Chatterjee GC. Biochemical studies on nickel toxicity in weanling rats - influence of vitamin C supplementation. *Int J Vitam Nutr Res* 1979;49:264-75. PMID: 231018
32. Das KK, Buchner V. Effect of nickel exposure on peripheral tissues: role of oxidative stress in toxicity and possible protection by ascorbic acid. *Rev Environ Health* 2007;22:157-73. doi: 10.1515/REVEH.2007.22.2.157
33. Fatima S, Arivarasu NA, Mahmood R. Vitamin C attenuates cisplatin-induced alterations in renal brush border membrane enzymes and phosphate transport. *Hum Exp Toxicol* 2007;26:419-26. PMID: 17623766
34. Solomons NW, Fernando V, Shuler TR, Nielsen FH. Bioavailability of nickel in man: effects of foods and chemically defined dietary constituents on the absorption of inorganic nickel. *J Nutr* 1982;112:39-50. PMID: 6798174

Prethodna terapija vitaminom C štiti od niklom izazvane nefrotoksičnosti u miševa

Nikal je sveprisutan kancerogeni i nefrotoksični metal čije djelovanje dovodi do oštećenja bubrežne funkcije. Rezultati prethodnih istraživanja dokazali su zaštitni učinak istodobne terapije vitaminom C na akutnu i kroničnu toksičnost izazvanu niklom. Međutim, vrlo je malo istraživanja o učinku prethodne terapije vitaminom C radi sprječavanja niklom izazvane akutne nefrotoksičnosti. Stoga se ovim ispitivanjem nastojala utvrditi učinkovitost prethodne terapije vitaminom C (VC) u sprječavanju akutne bubrežne toksičnosti izazvane niklom. Prije intraperitonealnog (IP) ubrizgavanja različitih doza (3, 5 i 10 mg Ni kg⁻¹ tjelesne težine) nikal klorida u razdoblju izlaganja od 24 sata, miševi su sedam dana uzastopce dobivali oralnu terapiju vitaminom C (16,6 mg kg⁻¹ tjelesne težine). Nakon toga životinje su usmrćene, a bubrežno tkivo i uzorci krvi uzeti su radi histološke obrade i analize biokemijskih markera. U miševa koji su dobivali samo terapiju vitaminom C, serumske razine bubrežnih markera (kreatinin, urea i mokraćna kiselina) nisu bile promijenjene. Međutim, tretiranje samo niklom dovelo je do značajnog povećanja razina kreatinina, ureje i mokraćne kiseline te do značajnog broja nekrotičnih epitelnih stanica i infiltracije upalnih stanica u presjecima bubrega u usporedbi s kontrolnom skupinom. Prethodna terapija vitaminom C i tretiranje niklom u svim navedenim dozama tijekom 24 sata doveli su do značajnog smanjenja razina kreatinina, ureje i mokraćne kiseline u serumu te do poboljšanja histoloških promjena u usporedbi sa skupinom koja je tretirana samo niklom. Zaključuje se da prethodna terapija vitaminom C učinkovito poboljšava bubrežnu funkciju i oštećenje tkiva uzrokovano niklom.

KLJUČNE RIJEČI: bubrežna disfunkcija; histopatologija; kreatinin; mokraćna kiselina; urea