

Occurrence of intersex in wild freshwater fish in Slovenian rivers: a histological evaluation

Milka Vrecl¹ and Vlasta Jenčič²

Institute of Preclinical Sciences¹, Institute of Pathology, Wild Animals, Fish and Bees², Veterinary Faculty, University of Ljubljana, Ljubljana, Slovenia

[Received in October 2015; CrossChecked in October 2015; Accepted in July 2016]

The aim of this preliminary research was to establish if there are intersex occurrences in wild freshwater fish in Slovenian rivers and streams. In the first study we evaluated all fish species of both sexes obtained from the river Ljubljana from its source to mouth. In the second study we focused on the rainbow trout (*Oncorhynchus mykiss*) and brown trout (*Salmo trutta m. fario*) males from 30 rivers and streams in different parts of Slovenia. The male gonads were histologically assessed for the presence of oocytes to determine the frequency and degree of intersex. Oocytes were found in the testicular tissue of a single grayling (*Thymallus thymallus*) and in the adipose tissue adjacent to the testis of a single common barbel (*Barbus barbus*), both from the Ljubljana. Several cyst-like structures that resemble degenerated presumptive oocytes were also present in several trout testes. This preliminary report is the first of its kind in Slovenia. To gain a better insight into the intersex issue in Slovenia, we plan to regularly biomonitor freshwater pollution by histologically examining fish gonads and, if possible, by determining vitellogenin plasma levels in fish.

KEY WORDS: gonads; histology; intersex; oocytes; wild freshwater fish

Many contaminants/chemicals present in wastewater effluents are capable of disrupting the endocrine system and are therefore referred to as hormonal/endocrine disruptors. They can act as oestrogens, androgens, anti-androgens, and progestogens, but their oestrogenic potential has received most attention (cf. 1). Chemicals considered to be endocrine disruptors include widespread persistent environmental pollutants such as polychlorinated biphenyls (PCBs), polybrominated biphenyls (PBBs), dioxins, plastics (e.g., bisphenol A), plasticizers (phthalates), some pesticides (methoxychlor, chlorpyrifos, dichlorodiphenyl trichloroethane), fungicides (notably, Vinclozolin), and pharmaceutical agents such as diethylstilbestrol (cf. 2). Freshwater and marine fish are well-suited for monitoring the effects of endocrine disruptors because they are continuously exposed to pollutants throughout their lives. Their endocrine system is similar to that of the higher vertebrates, as they also quickly reach sexual maturity and produce large numbers of progeny over short time (3).

Several studies have reported that wildlife, including fish, can be feminised, masculinised, or reproductively suppressed by endocrine disruptors (4). The first reports of intersex fish, i.e., fish with gonads containing male and female tissue, and/or feminised reproductive ducts, came from the UK in the early 1980s (cf. 1) and uncovered the

link between river water pollution and intersex in male fish (5-11). Followed a number of male fish feminisation reports from several national ecotoxicological studies (summarised in Table 1). In 1999, the EU Community Programme of Research on Environmental Hormones and Endocrine Disruptors (COMPREHEND) was launched to assess the evidence for endocrine disruption in the aquatic environment in Europe as a result of effluent discharge (12). Evidence of sexual disruption or feminisation mainly relied on the findings of vitellogenin, a female egg protein in the blood of male fish, and the presence of oocytes and/or female reproductive ducts in otherwise male gonads (13-20). Alternatively, the programme examined the incidence of sperm and testicular abnormalities (21). Only a few studies investigated the masculinisation of females (22, 23).

Gonad histology is a very useful tool to study reproductive health in fish. It is routinely used for to verify the sex, document intersex, tumours, parasites, and other abnormalities (24), and evaluate the effects of endocrine disrupting chemicals with different modes of action in small fish that are used as model organisms (25). Different systems have also been developed to assess the degree of intersex, which can range from mild to severe, depending on the number, maturity, and distribution of oocytes within the otherwise normal testicular tissue (6, 26, 27).

Considering that there is no previous knowledge about the intersex condition in wild freshwater fish in Slovenian rivers, the aim of this preliminary research was to check

Correspondence to: Vlasta Jenčič, Institute of Pathology, Wild Animals, Fish and Bees, Veterinary Faculty, University of Ljubljana, Gerbičeva 60, 1000 Ljubljana, Slovenia; E-mail: vlasta.jenicic@vf.uni-lj.si

Table 1 Studies reporting intersex (testicular oocytes) occurrence in different fish species

Fish species (scientific name)	Country	Reference
Roach (<i>Rutilus rutilus</i>)	UK	Jobling et al, 1998 (8); Nolan et al., 2001 (28); Gross-Sorkin et al., 2006 (33); Beresford et al., 2004 (34)
Flounder (<i>Platichthys flesus</i>)	UK	Allen et al., 1999 (35)
Gudgeon (<i>Gobio gobio</i>)	UK	Van Aarle et al., 2001 (36)
<i>Platichthys flesus</i> , <i>Zoarces viviparus</i>	UK	Stentiford et al., 2003 (37)
Flatfish (<i>Limanda limanda</i>)	UK	Stentiford and Feist, 2005 (38)
Brown trout (<i>Salmo trutta</i>)	Ireland	Kelly et al., 2010 (14)
Roach (<i>Rutilus rutilus</i>)	Denmark	Bjerregaard et al., 2006 (27)
Brown trout (<i>Salmo trutta</i>)	Denmark	Bjerregaard et al., 2006 (39)
Whitefish (<i>Coregonus lavaretus</i> spp.)	Switzerland	Bernet et al., 2008 (40)
Eelpout (<i>Zoarces viviparus</i>)		
Stickleback (<i>Gasterosteus aculeatus</i>)	Germany	Gercken and Sordyl, 2002 (41)
Perch (<i>Perca fluviatilis</i>)		
Carp (<i>Cyprinus carpio</i>)	Netherlands	Gimeno et al., 1996 (42)
Cyprinids	Italy	Viganò et al., 2001 (43)
Carp (<i>Cyprinus carpio</i>)	Spain	Lavado et al., 2004 (44)
Red mullet (<i>Mullus barbatus</i>)	Mediterranean	Martin-Skilton et al., 2006 (45)
Catfish (<i>Clarias gariepinus</i>)	South Africa	Barnhoorn et al, 2004 (46)
Mozambique tilapia (<i>Oreochromis mossambicus</i>)	South Africa	Barnhoorn et al, 2010 (47)
Smallmouth bass (<i>Micropterus dolomieu</i>)	USA	Blazer et al., 2007 (32)
Sturgeon (<i>Scaphirhynchus platyrhynchus</i>)	USA	Harshbarger et al., 2000 (48)
Black basses (<i>Micropterus</i> spp.)	USA	Hinck et al., 2009 (49)
White suckers (<i>Catostomus commersoni</i>)	USA	Vajda et al., 2008 (50)
Seven fish species, including carp (<i>Cyprinus carpio</i>) and goldfish (<i>Carassius auratus</i>)	Canada	Kavanagh et al., 2004 (51)
Flounder (<i>Pleuronectes yokohamae</i>)	Japan	Hashimoto et al., 2000 (52)

for its presence using histological tools and see if it is necessary to study the issue any further.

MATERIAL AND METHODS

Sampling

This research was conducted in two parts. The first study targeted different fish species in the river Ljubljana, and the second study focused on the rainbow trout (*Oncorhynchus mykiss*) and the brown trout (*Salmo trutta* m. *fario*) from 30 rivers and streams across Slovenia.

The Ljubljana river fish samples of both sexes (n=56, see Table 2) were collected from local fishermen between July and November 2008 and were caught either by sport fishing or electrofishing at fifteen sites that were likely to be exposed to contamination and covered the entire length of the Ljubljana from the source to its mouth.

The second study included only male rainbow (n=136) and brown trout (n=107), collected by electrofishing in 30 Slovene rivers and streams where fish were sampled for virus surveillance over the winter of January to March 2011.

All the fish were killed with an overdose of 2-phenoxyethanol (Sigma-Aldrich; St. Louis, MO, USA) and transported to the laboratory in a cooler. The gonads

(male and female) were removed and dissected, and the sex was determined macroscopically, except in two cases that were excluded due to improper tissue sampling. The gonads were then fixed in a 10 % buffered formalin solution until histological analysis.

Histological analysis

After fixation, the gonads were dehydrated and two tissue slices (thickness <1 cm) that originated from two areas of the same gonad embedded in paraffin. Subsequently, a series of 12 five-micrometre histological slides were cut from each fish (six from each gonad tissue slice) at 50-µm intervals and stained with haematoxylin and eosin (H&E) for analysis.

For the histological examination we used a Nikon Microphot FXA microscope equipped with a DS-Fi1 camera and NIS-Elements imaging software, NIS Elements D.32 (Nikon instruments Europe B.V., Badhoevedorp, the Netherlands).

Figure 1 shows normal testis histology at various stages of spermatogenesis. The testes were in the resting phase or in the initial (1A and 1B) or active phase of spermatogenesis (1C and 1D). This is in agreement with the spawning season of the sampled fish in the Slovenian rivers. The testes slides were examined for the presence of oocytes to determine the

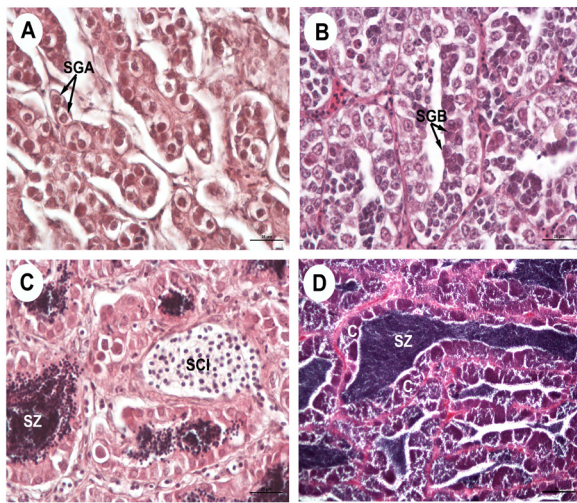


Figure 1 Histological cross section of testes. (A) Resting testis containing type A spermatogonium (SGA); (B) testis in the initial phase of spermatogenesis characterized by cysts with multiplying type B spermatogonium (SGB); (C) testis lobules with different spermatogenic cells, including primary spermatocytes (SCI) and spermatozoa (SZ); and (D) a spawning testis containing spermatozoa (SZ) and cysts (C) close to the lobule wall containing spermatids during spermiogenesis. H&E staining; scale bar 25 μ m (A, B, C) and 100 μ m (D)

frequency and degree of intersex. The degree of intersex was assessed according to a modified version of the intersex scoring described by Jobling et al. (6). This modified scoring ranges from 0 (normal male testis) to 5 (>30 oocytes per section) (see Table 3). Then we calculated the average score for 12 slides per fish. The oocytes at different developmental stages in the testes tissue were identified by comparing them with the oocytes found in the ovaries of female fish from the first (Ljubljana) study as previously described by Blazer (24). Most of the analysed ovaries were maturing

and had oocytes present at different stages of development (Figure 2).

RESULTS AND DISCUSSION

Histological findings of intersex

We found no histological signs of masculinisation/intersex in the ovary of the female fish from the Ljubljana study. As for the male fish, we found intersex in one fish only: a single grayling (*Thymallus thymallus*) collected from the Ljubljana. It had four oocytes in the late primary/previtellogenic stage that were scattered randomly throughout the otherwise normal testicular tissue (multifocal intersex) (Figure 3). This particular case of intersex was scored 1 (milder form of intersex; ≤ 2 oocytes per slide). However, we also found single late primary and previtellogenic oocytes in the adipose tissue adjacent to the testis of one common barbel (*Barbus barbus*) but not in the testis itself (Figure 4).

In the second study, which focused only on rainbow and brown trout, we found no typical signs of intersex. However, we found cyst-like structures encircled by a layer of fibroblast-like cells in three fish (Figure 5). Two samples had only one cyst-like structure in each (5A), while one sample had numerous cyst-like structures (5B). Nolan et al. (28) propose that cyst-like structures such as these are presumptive degenerate oocytes. In their study, however, the cyst-like structures were located adjacent to the testicular tissue from an intersex gonad. As these structures also resemble granulomatous or parasitic encystations in non-intersex fish (28), we could not positively identify them as the intersex condition.

Table 2 Fish species collected from the river Ljubljana (July–November 2008) and their length (mean \pm SD)

Fish species (scientific name)	Length (cm)	Male:female ratio (%)
Grayling (<i>Thymallus thymallus</i>)	32.43 \pm 4.20 (n=14)	36:64
Chub (<i>Squalius cephalus</i>)	31.00 \pm 6.16 (n=13)	77:23
Nase (<i>Chondrostoma nasus</i>)	41.63 \pm 3.25 (n=8)	50:50
Common barbel (<i>Barbus barbus</i>)	43.50 \pm 8.64 (n=8)	38:63
Vimba (<i>Vimba vimba</i>)	31.43 \pm 1.99 (n=7)	71:29
Common bream (<i>Abramis brama</i>)	42.25 \pm 7.54 (n=4)	50:50
Roach (<i>Rutilus rutilus</i>)	23.00 (n=1)	100:0
Danube roach (<i>Rutilus virgo</i>)	32.00 (n=1)	100:0

Mild to severe intersex condition has been extensively reported worldwide (see Table 1). A recent review of 48 studies conducted in 24 countries reports intersex findings in at least 37 fish species from 17 families (29). The salmonid species, to which grayling belongs, have also been reported as more sensitive to oestrogenic exposure than the cyprinid fish (30).

We believe that our finding of intersex in the fish is related to the exposure to environmental pollutants with endocrine disruption/oestrogenic potential because the analysed fish belong to the gonochoristic (fixed-sex) species (31). Regarding the optimal timing of the survey, Blazer et

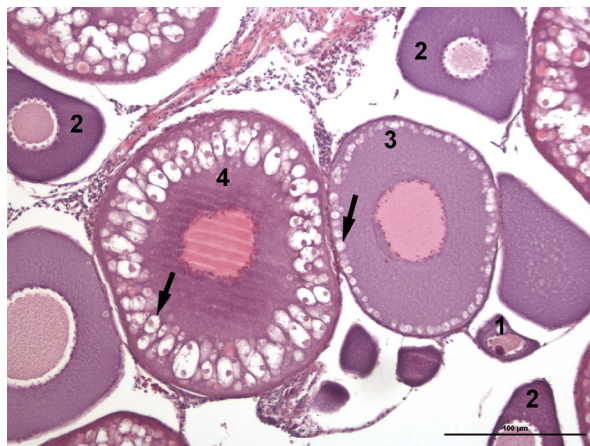


Figure 2 Histological cross section of a maturing ovary. Four different oocyte stages are marked; 1 - early primary oocyte; 2 - late primary oocyte; 3- previtellogenic oocyte; 4 - early vitellogenic oocyte. Arrows point to cortical alveoli. H&E staining; scale bar 100 µm

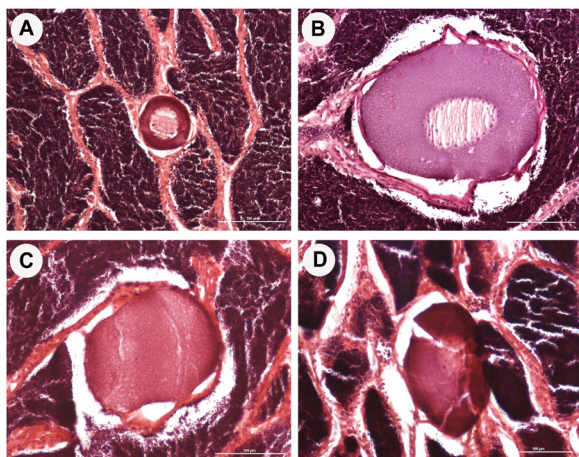


Figure 3 Testis of an adult male grayling (*Thymallus thymallus*) from the river Ljubljanica. Identified late primary oocyte (A) and previtellogenic oocytes (B, C, D) that were randomly scattered within apparently normal testicular tissue. H&E staining; scale bar 100 µm

Table 3 The intersex index scoring system used in this study, which is a modified version of the intersex index scoring system adjusted to milder degrees of intersex (6)

Score 0	normal male testis
Score 1	≤2 oocytes per section
Score 2	3-10 oocytes per section
Score 3	11-20 oocytes per section
Score 4	21-30 oocytes per section
Score 5	>30 oocytes per section

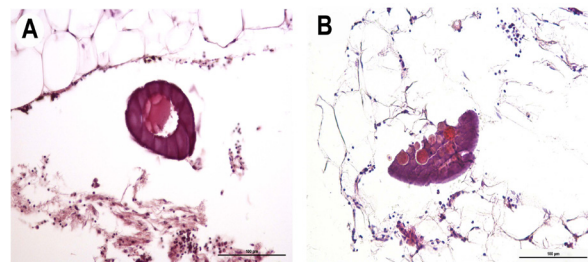


Figure 4 Histological cross section of a male common barbel (*Barbus barbus*) from the river Ljubljanica. Identified late primary oocyte (A) and previtellogenic oocyte (B) located in the adipose tissue adjacent to the testis. H&E staining; scale bar 100 µm

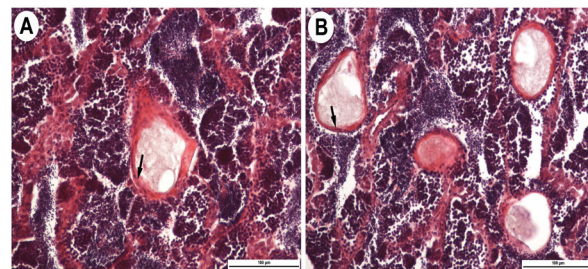


Figure 5 Cyst-like structures in the brown trout (*Salmo trutta m. fario*) testis. (A) Individual cyst-like structures probably representing presumptive degenerate oocytes encircled by a layer of fibroblast-like cells (arrows). (B) Cyst-like structures were numerous but observed only in one sample. H&E staining; scale bar 100 µm

al. (32) reported the highest prevalence of intersex during the pre-spawn season and decreased incidence in the post-spawn period.

This preliminary report is the first of its kind in Slovenia. To gain a better insight into the intersex issue in Slovenia, we plan to regularly biomonitor freshwater pollution by histologically examining fish gonads and, if possible, by determining vitellogenin plasma levels in fish.

Acknowledgements

The authors thank the fishermen of the Fishing Society Vrhnika. This study was financially supported by the Department for Environmental Protection, the City of Ljubljana, and the Slovenian Research Agency programme P4-0053.

REFERENCES

- Sumpter JP. Endocrine disrupters in the aquatic environment: An overview. *Acta Hydrochim Hydrobiol* 2005;33:9-16. doi: 10.1002/ahch.200400555
- Diamanti-Kandarakis E, Bourguignon JP, Giudice LC, Hauser R, Prins GS, Soto AM, Zoeller RT, Gore AC. Endocrine-disrupting chemicals: an Endocrine Society scientific statement. *Endocr Rev* 2009;30:293-342. doi: 10.1210/er.2009-0002
- Castano A, Bols N, Braunbeck T, Dierickx P, Halder M, Isomaa B, Kawahara K, Lee LE, Mothersill C, Pärt P, Repetto G, Sintès JR, Ruffi H, Smith R, Wood C, Segner H; ECVAM Workshop 47. The use of fish cells in ecotoxicology. The report and recommendations of ECVAM Workshop 47. *Altern Lab Anim* 2003;31:317-51. PMID: 15612875
- Matthiessen P. Historical perspective on endocrine disruption in wildlife. *Pure Appl Chem* 2003;75:2197-206. doi: 10.1351/pac200375112197
- Harries JE, Sheahan DA, Matthiessen P, Neall P, Rycroft R, Tylor T, Jobling S, Routledge EJ, Sumpter JP. A survey of estrogenic activity in United Kingdom inland waters. *Environ Toxicol Chem* 1996;15:1993-2002. doi: 10.1002/etc.5620151118
- Jobling S. Review of suggested testing methods for endocrine-disrupting chemicals. *Pure Appl Chem* 1998;70:1805-27. doi: 10.1351/pac199870091805
- Jobling S, Coey S, Whitmore JG, Kime DE, Van Look KJW, McAllister BG, Beresford N, Henshaw AC, Brighty G, Tyler CR, Sumpter JP. Wild intersex roach (*Rutilus rutilus*) have reduced fertility. *Biol Reprod* 2002;67:515-24. doi: 10.1095/biolreprod67.2.515
- Jobling S, Nolan M, Tyler CR, Brighty G, Sumpter JP. Widespread sexual disruption in wild fish. *Environ Sci Technol* 1998;32:2498-506. doi: 10.1021/es9710870
- Jobling S, Tyler CR. Endocrine disruption, parasites and pollutants in wild freshwater fish. *Parasitology* 2003;126:S103-8. doi: 10.1017/S0031182003003652
- Sumpter JP. Feminized responses in fish to environmental estrogens. *Toxicol Lett* 1995;82-3:737-42. doi: 10.1016/0378-4274(95)03517-6
- Sumpter JP. Xenoendocrine disrupters - environmental impacts. *Toxicol Lett* 1998;103: 337-42. doi: 10.1016/S0378-4274(98)00328-2
- Community programme of research on endocrine disrupters and environmental hormones (COMPREHEND) 1999 [displayed 5 August 2015]. Available at <https://ec.europa.eu/research/endocrine/pdf/env4-ct98-0798.pdf>.
- Burkhardt-Holm P, Segner H, Burki R, Peter A, Schubert S, Suter MJF, Borsuk ME. Estrogenic endocrine disruption in Switzerland: Assessment of fish exposure and effects. *Chimia* 2008;62:376-82. doi: 10.2533/chimia.2008.376
- Kelly MA, Reid AM, Quinn-Hosey KM, Fogarty AM, Roche JJ, Brougham CA. Investigation of the estrogenic risk to feral male brown trout (*Salmo trutta*) in the Shannon International River Basin District of Ireland. *Ecotoxicol Environ Saf* 2010;73:1658-65. doi: 10.1016/j.ecoenv.2010.08.018
- Lye CM, Frid CLJ, Gill ME, McCormick D. Abnormalities in the reproductive health of flounder *Platichthys flesus* exposed to effluent from a sewage treatment works. *Mar Pollut Bull* 1997;34:34-41. doi: 10.1016/S0025-326X(96)00061-6
- Sepulveda MS, Johnson WE, Higman JC, Denslow ND, Schoeb TR, Gross TS. An evaluation of biomarkers of reproductive function and potential contaminant effects in Florida largemouth bass (*Micropterus salmoides floridanus*) sampled from the St. Johns River. *Sci Total Environ* 2002;289:133-44. PMID: 12049390
- Simpson MG, Parry M, Kleinkauf A, Swarbreck D, Walker P, Leah RT. Pathology of the liver, kidney and gonad of flounder (*Platichthys flesus*) from a UK estuary impacted by endocrine disrupting chemicals. *Mar Environ Res* 2000;50:283-7. doi: 10.1016/S0141-1136(00)00089-1
- Sole M, Raldua D, Piferrer F, Barcelo D, Porte C. Feminization of wild carp, *Cyprinus carpio*, in a polluted environment: plasma steroid hormones, gonadal morphology and xenobiotic metabolizing system. *Comp Biochem Physiol C* 2003;136:145-56. doi: 10.1016/S1532-0456(03)00192-3
- Tetreault GR, Bennett CJ, Shires K, Knight B, Servos MR, McMaster ME. Intersex and reproductive impairment of wild fish exposed to multiple municipal wastewater discharges. *Aquat Toxicol* 2011;104:278-90. doi: 10.1016/j.aquatox.2011.05.008
- Vajda AM, Barber LB, Gray JL, Lopez EM, Bolden AM, Schoenfuss HL, Norris DO. Demasculinization of male fish by wastewater treatment plant effluent. *Aquat Toxicol* 2011;103:213-21. doi: 10.1016/j.aquatox.2011.02.007
- Gill ME, Spiropoulos J, Moss C. Testicular structure and sperm production in flounders from a polluted estuary: a preliminary study. *J Exp Mar Biol Ecol* 2002;281:41-51. doi:10.1016/S0022-0981(02)00396-9
- Chiang G, Barra R, Diaz-Jaramillo M, Rivas M, Bahamonde P, Munkittrick KR. Estrogenicity and intersex in juvenile rainbow trout (*Oncorhynchus mykiss*) exposed to *Pine/Eucalyptus* pulp and paper production effluent in Chile. *Aquat Toxicol* 2015;164:126-34. doi: 10.1016/j.aquatox.2015.04.025
- Woodling JD, Lopez EM, Maldonado TA, Norris DO, Vajda AM. Intersex and other reproductive disruption of fish in wastewater effluent dominated Colorado streams. *Comp Biochem Phys C* 2006;144:10-5. doi: 10.1016/j.cbpc.2006.04.019
- Blazer VS. Histopathological assessment of gonadal tissue in wild fishes. *Fish Physiol Biochem* 2002;26:85-101. doi: 10.1023/A:1023332216713
- Leino RL, Jensen KM, Ankley GT. Gonadal histology and characteristic histopathology associated with endocrine disruption in the adult fathead minnow (*Pimephales promelas*). *Environ Toxicol Pharmacol* 2005;19:85-98. doi: 10.1016/j.etap.2004.05.010
- Bateman KS, Stentiford GD, Feist SW. A ranking system for the evaluation of intersex condition in European flounder (*Platichthys flesus*). *Environ Toxicol Chem* 2004;23:2831-6. doi: 10.1897/03-541.1
- Bjerregaard LB, Korsgaard B, Bjerregaard P. Intersex in wild roach (*Rutilus rutilus*) from Danish sewage effluent-receiving streams. *Ecotoxicol Environ Saf* 2006;64:321-8. doi: 10.1016/j.ecoenv.2005.05.018
- Nolan M, Jobling S, Brighty G, Sumpter JP, Tyler CR. A histological description of intersexuality in the roach. *J Fish Biol* 2001;58:160-78. doi: 10.1111/j.1095-8649.2001.tb00505.x
- Bahamonde PA, Munkittrick KR, Martyniuk CJ. Intersex in teleost fish: are we distinguishing endocrine disruption from

- natural phenomena? Gen Comp Endocrinol 2013;192:25-35. doi: 10.1016/j.ygcen.2013.04.005
30. Tyler CR, Spary C, Gibson R, Santos EM, Shears J, Hill EM. Accounting for differences in estrogenic responses in rainbow trout (*Oncorhynchus mykiss*: Salmonidae) and roach (*Rutilus rutilus*: Cyprinidae) exposed to effluents from wastewater treatment works. Environ Sci Technol 2005;39:2599-607. doi: 10.1021/es0488939
 31. Ospina-Alvarez N, Piferrer F. Temperature-dependent sex determination in fish revisited: prevalence, a single sex ratio response pattern, and possible effects of climate change. PLoS One 2008;3:e2837. doi: 10.1371/journal.pone.0002837
 32. Blazer VS, Iwanowicz LR, Iwanowicz DD, Smith DR, Young JA, Hedrick JD, Foster SW, Reeser SJ. Intersex (testicular oocytes) in smallmouth bass from the Potomac River and selected nearby drainages. J Aquat Anim Health 2007;19:242-53. doi: 10.1577/H07-031.1
 33. Gross-Sorokin MY, Roast SD, Brighty GC. Assessment of feminization of male fish in English rivers by the environment agency of England and Wales. Environ Health Perspect 2006;114(Suppl 1):147-51. doi: 10.1289/ehp.8068
 34. Beresford N, Jobling S, Williams R, Sumpter JP. Endocrine disruption in juvenile roach from English rivers: a preliminary study. J Fish Biol 2004;64:580-6. doi: 10.1111/j.0022-1112.2004.00311.x
 35. Allen Y, Matthiessen P, Scott AP, Haworth S, Feist S, Thain JE. The extent of oestrogenic contamination in the UK estuarine and marine environments - further surveys of flounder. Sci Total Environ 1999;233:5-20. doi: 10.1016/S0048-9697(99)00175-8
 36. van Aerle R, Nolan M, Jobling S, Christiansen LB, Sumpter JP, Tyler CR. Sexual disruption in a second species of wild cyprinid fish (the Gudgeon, *Gobio gobio*) in United Kingdom freshwaters. Environ Toxicol Chem 2001;20:2841-7. doi: 10.1002/etc.5620201225
 37. Stentiford GD, Longshaw M, Lyons BP, Jones G, Green M, Feist SW. Histopathological biomarkers in estuarine fish species for the assessment of biological effects of contaminants. Mar Environ Res 2003;55:137-59. doi: 10.1016/S0141-1136(02)00212-X
 38. Stentiford GD, Feist SW. First reported cases of intersex (ovotestis) in the flatfish species dab *Limanda limanda*: Dogger Bank, North Sea. Mar Ecol Prog Ser 2005;301:307-10. doi: 10.3354/meps301307
 39. Bjerregaard LB, Madsen AH, Korsgaard B, Bjerregaard P. Gonad histology and vitellogenin concentrations in brown trout (*Salmo trutta*) from Danish streams impacted by sewage effluent. Ecotoxicology 2006;15:315-27. doi:10.1007/s10646-006-0061-9
 40. Bernet D, Liedtke A, Bittner D, Eggen RIL, Kipfer S, Kung C, Largiader CR, Suter Marc JF, Wahli T, Segner H. Gonadal malformations in whitefish from Lake Thun: Defining the case and evaluating the role of EDCs. Chimia 2008;62:383-8. doi: 10.2533/chimia.2008.383
 41. Gercken J, Sordyl H. Intersex in feral marine and freshwater fish from northeastern Germany. Mar Environ Res 2002;54:651-5. doi: 10.1016/S0141-1136(02)00156-3
 42. Gimeno S, Gerritsen A, Bowmer T, Komen H. Feminization of male carp. Nature 1996;384:221-2. doi: 10.1038/384221a0
 43. Vigano L, Arillo A, Bottero S, Massari A, Mandich A. First observation of intersex cyprinids in the Po River (Italy). Sci Total Environ 2001;269:189-94. doi: 10.1016/S0048-9697(00)00821-4
 44. Lavado R, Thibaut R, Raldua D, Martin R, Porte C. First evidence of endocrine disruption in feral carp from the Ebro River. Toxicol Appl Pharm 2004;196:247-57. doi: 10.1016/j.taap.2003.12.012
 45. Martin-Skilton R, Lavado R, Thibaut R, Minier C, Porte C. Evidence of endocrine alteration in the red mullet, *Mullus barbatus* from the NW Mediterranean. Environ Pollut 2006;141:60-8. doi: 10.1016/j.envpol.2005.08.016
 46. Barnhoorn IE, Bornman MS, Pieterse GM, van Vuren JH. Histological evidence of intersex in feral sharpooth catfish (*Clarias gariepinus*) from an estrogen-polluted water source in Gauteng, South Africa. Environ Toxicol 2004;19:603-8. doi: 10.1002/tox.20068
 47. Barnhoorn IE, van Dyk JC, Pieterse GM, Bornman MS. Intersex in feral indigenous freshwater *Oreochromis mossambicus*, from various parts in the Luvuvhu River, Limpopo Province, South Africa. Ecotoxicol Environ Saf 2010;73:1537-42. doi: 10.1016/j.ecoenv.2010.07.026
 48. Harshbarger JC, Coffey MJ, Young MY. Intersexes in Mississippi River shovelnose sturgeon sampled below Saint Louis, Missouri, USA. Mar Environ Res 2000;50:247-50. doi: 10.1016/S0141-1136(00)00055-6
 49. Hinck JE, Blazer VS, Schmitt CJ, Papoulias DM, Tillitt DE. Widespread occurrence of intersex in black basses (*Micropterus* spp.) from US rivers, 1995-2004. Aquat Toxicol 2009;95:60-70. doi: 10.1016/j.aquatox.2009.08.001
 50. Vajda AM, Barber LB, Gray JL, Lopez EM, Woodling JD, Norris DO. Reproductive disruption in fish downstream from an Estrogenic wastewater effluent. Environ Sci Technol 2008;42:3407-14. doi: 10.1021/es0720661
 51. Kavanagh RJ, Balch GC, Kiparissis Y, Niimi AJ, Sherry J, Tinson C, Metcalfe CD. Endocrine disruption and altered gonadal development in white perch (*Morone americana*) from the lower Great Lakes region. Environ Health Perspect 2004;112:898-902. doi: 10.1289/ehp.6514
 52. Hashimoto S, Bessho H, Hara A, Nakamura M, Iguchi T, Fujita K. Elevated serum vitellogenin levels and gonadal abnormalities in wild male flounder (*Pleuronectes yokohamae*) from Tokyo Bay, Japan. Mar Environ Res 2000;49:37-53. doi: 10.1016/S0141-1136(99)00047-1

Pojav interseksulanosti pri sladkovodnih ribah v slovenskih rekah: histološka ocena

V naši raziskavi smo v izbranih slovenskih rekah ugotavljali pojav feminizacije rib. V prvi del raziskave so bile vključene ribe različnih vrst in obeh spolov, izlovljene na različnih lokacijah iz reke Ljubljanice, od njenega izvira do izliva. V drugem delu raziskave smo se osredotočili samo na samce šarenke (*Oncorhynchus mykiss*) in potočne postrvi (*Salmo trutta m. fario*) iz izbranih rek in potokov po vsej Sloveniji. Prisotnost in pogostnost jajčnih celic v testisih ter stopnjo interseksulanosti smo ugotavljali s histološko analizo. Prisotnost jajčnih celic smo ugotovili v tkivu moda lipana (*Thymallus thymallus*) ter še v maščobnem tkivu v neposredni bližina moda mrene (*Barbus barbus*). Poleg tega smo v posameznih primerih ugotovili še cistam podobne tvorbe, ki so domnevno degenerirane jajčne celice. Z opravljeno študijo smo dobili prvi vpogled o pojavnosti interseksualnosti pri ribah v slovenskih vodotokih.

KLJUČNE BESEDE: *sladkovodne ribe; interseksualnost; gonade; oociti; cistam podobne tvorbe; histologija*