

Cristhiane Leão de Queiroz<sup>1</sup>, Andrea Sayuri Silveira Dias Terada<sup>2</sup>, Thais Uenoyama Dezem, Lais Gomes de Araújo<sup>1</sup>, Rodrigo Galo<sup>3</sup>, Christiano Oliveira-Santos<sup>1</sup>, Ricardo Henrique Alves da Silva<sup>1</sup>

## Određivanje spola odrasloga čovjeka na temelju prikaza maksilarnih sinusa na panoramskoj rendgenskoj snimci

### Sex Determination of Adult Human Maxillary Sinuses on Panoramic Radiographs

<sup>1</sup> Zavod za dentalnu medicinu, javno zdravstvo i forenzičnu dentalnu medicinu Stomatološkog fakulteta Sveučilišta Ribeirao Preto, Sao Paulo, Brazil

Department of Stomatology, Public Health and Forensic Dentistry, School of Dentistry of Ribeirao Preto, University of Sao Paulo, Ribeirao Preto, Sao Paulo, Brazil

<sup>2</sup> Zavod za patologiju i sudsku medicinu Stomatološkog fakulteta Sveučilišta Ribeirao Preto, Sao Paulo, Brazil

Department of Pathology and Legal Medicine, School of Medicine of Ribeirao Preto, University of Sao Paulo, Ribeirao Preto, Sao Paulo, Brazil

<sup>3</sup> Zavod za dentalnu medicinu Saveznog sveučilišta Jequitinhonha i Mucuri Vallys, Diamantina, Minas Gerais, Brazil

Department of Dentistry, Federal University of Jequitinhonha and Mucuri Vallys, Diamantina, Minas Gerais, Brazil

#### Sažetak

**Svrha** ovog istraživanja bila je procijeniti dimenzije maksilarnih sinusa odraslih ljudi na ortopantomogramu i mogućnost primjene tog pokazatelja u određivanju spola u forenzične svrhe. **Materijal i postupci:** Uzorak su činila 64 ortopantomograma pojedinaca starijih od 20 godina (32 muškarca i 32 žene) iz baze podataka s kompletnom trajnom denticijom (ili bez umnjaka). Jedan ispitivač mjerio je širinu i visinu desnih i lijevih gornjih sinusa softverom Image J 1.47v (National Institutes of Health, Bethesda, SAD). Mjerenja su ponovljena kako bi se izračunala ponovljivost ispitivača. U analizi rezultata korišteni su hi-kvadrat test, kappa, ANOVA i Studentov t-test, uz razinu značajnosti postavljenu na  $p \leq 0,05$ . Vrijednost kappa kretala se u rasponu od 0,38 do 0,96. **Rezultati:** Ženama je prosječna visina i širina lijevog maksilarnog sinusa iznosila 28,7856 mm, odnosno 44,6178 mm. Za desni maksilarni sinus visina je bila 27,7163 milimetra, a širina 45,1850 milimetara. Muškarcima je bila izmjerena prosječna visina i širina lijevog maksilarnog sinusa od 30,9981 milimetar, odnosno 48,7753 milimetra. Za desni maksilarni sinus visina je bila 30,7403 milimetra, a širina 48,5753 milimetra. Utvrđena je statistički značajna razlika u visini i širini maksilarnih sinusa između muškaraca i žena. **Zaključak:** Može se zaključiti da visina i širina maksilarnih sinusa na ortopantomogramu može poslužiti u određivanju spola odraslih osoba.

**Zaprimljen:** 11. svibnja 2016.

**Prihvaćen:** 5. srpnja 2016.

#### Adresa za dopisivanje

Ricardo Henrique Alves da Silva  
University of Sao Paulo  
School of Dentistry of Ribeirao Preto  
Department of Stomatology, Public Health and Forensic Dentistry  
Sao Paulo, Brazil  
ricardohenrique@usp.br

#### Ključne riječi

maksilarni sinus; maksilarna kost; panoramska rendgenska snimka; forenzična dentalna medicina; forenzična medicina; određivanje spola pomoću kostiju

#### Uvod

Postupak identifikacije temelji se na korištenju statističkih parametara povezanih s kvalitativnom i kvantitativnom analizom obilježja kao što su vrsta, spol, dob, visina i rasa (1). Određivanje spola na odraslom kosturu često je prvi korak u tom procesu identifikacije, a uključuje metode procjene dobi i konstitucije. Pouzdanost ovisi o skeletnim ostatcima i stupnju inherentnog spolnog dimorfizma u populaciji (2).

Lubanja i zdjelica, anatomske su dijelovi koji imaju veći spolni dimorfizam s točnošću većom od 92 posto (3), tako da se nalaz autopsije može nadopuniti slikovnim testovima. Među takve strukture ubrajaju se maksilarni sinusi, šupljine koje se nalaze u gornjoj čeljusti ograničene dnom orbite, hodnicima nosa i alveolarnim grebenom, a u neposrednoj su blizini korijena stražnjih zuba i tubera gornje čeljusti te u odnosu s *fossa infratemporalis* i *pterygomaxillaris* (4).

#### Introduction

The human identification process is based on the use of statistical parameters associated with qualitative and quantitative features of data such as species, sex, age, height and racial group (1). The forensic dentistry is closely related to human identification in situations where other means are not indicated or are not applicable (2).

Sex determination in adult skeletons is often the first step in this identification process, associated with the age and stature estimation methods. Different methods can be used to sex determination (3) and the reliability of the sex determination depends on the skeletal remains and the degree of inherent sexual dimorphism in the population (4).

The skull, as well as the pelvis, is the anatomical portion that presents more sexual dimorphism providing an accuracy of above 92% (5), which favors one necropsy of their an-

U forenzičnoj dentalnoj medicini jedna od najčešće korištenih rendgenskih tehnika jest ortopantomogram koji prikazuje maksilofacijalni kompleks (5). No nema istraživanja u kojima se rendgenske dentalne snimke upotrebljavaju za određivanje spola i ljudska se identifikacija obavlja na temelju maksilarnih sinusa (6,7).

Svrha ovog istraživanja bila je analizirati dimenzije lijevo- i desnoga maksilarnog sinusa odraslih osoba na ortopantomogramu i utvrditi mogućnost njihove primjene u određivanju spola.

## Materijali i metode

Projekt je odobrilo Etičko povjerenstvo Stomatološkog fakulteta Ribeirão Preto Sveučilišta u Sao Paulu pod brojem 27717714.2.0000.5419.

Odabrana su 32 muškarca i 32 žene starijih od 20 godina. Kriterij za sudjelovanje bila je potpuna ozubljenost, s tim da je mogao nedostajati treći kutnjak. Rendgenske snimke trebale su pokazati potpuno razvijene lijeve i desne maksilarne sinuse uz prihvatljivu definiciju, gustoću, kontrast i jasnoću. S druge strane, odbačene su rendgenske snimke maksilarnih sinusa s patološkim nalazima ili malformacijama te one s vidljivim artefaktima.

Najprije su uklonjene identifikacijske oznake i svi su uzorci randomizirani kako bi se osiguralo da istraživanje bude *sljepo*. Isti istraživač dva puta je analizirao sve uzorke.

Kako bi se standardizirao stupanj distorzije, na ortopantomogramskom uređaju (Veraviewepocs 2D<sup>®</sup>, J Morita MFG. CORP., Kyoto, Japan) koji se upotrebljava u FORP-USP klinici za radiologiju, snimljena je panoramska rendgenska snimka lubanje koja pripada toj ustanovi. Pritom su ortodontske žice duge 10 milimetara postavljene u blizinu li-

atomical structures that can be complemented with imaging tests. These structures include the maxillary sinuses, which are cavities contained within the maxillary bone, delimited by the orbital floor, wall of the nasal passages and alveolar ridge, with close proximity to the posterior teeth roots and the maxillary tuberosity associated with the infratemporal and pterygomaxillary fossa (6).

Panoramic radiography is one of the most commonly used imaging techniques in forensic dentistry which provides an overview of the maxillofacial complex (7). However, there is lack of research in which dental radiographs with maxillary sinus dimensions measurement are used in order to determine gender in the course of individual human identification (8,9).

The purpose of this study was to analyze right and left maxillary sinuses dimensions of adult subjects on panoramic radiographs and their possible application in the sex determination.

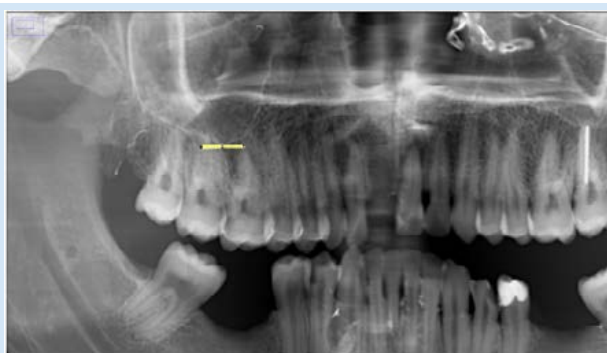## Materials and Methods

The research project was approved by the Ribeirão Preto Dentistry College – University of São Paulo- Ethics Research Committee (FORP- USP) under CAAE n<sup>o</sup> 27717714.2.0000.5419.

32 men and 32 women, aged 20 years or older, were selected. The inclusion criteria were the presence of all teeth. However, the subjects who were missing the third molar were also included. Their panoramic radiographs were subsequently evaluated. The included radiographs should present images of completely formed right and left maxillary sinuses, acceptable definition with adequate density, contrast and clarity. On the other hand, the radiographic images of maxillary sinuses bearing pathologies or malformation, or the images with errors in the radiograph processing were excluded.

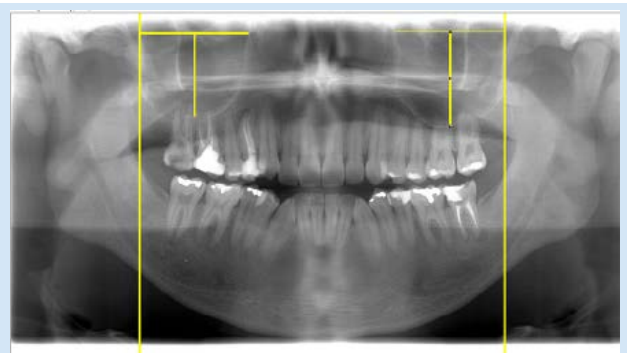
Firstly, the removal of identification and the randomization of all samples were performed, in order to ensure the study to be blind. Also, the same observer carried out two analyses of all samples.

To standardize the level of distortion of the panoramic radiograph a device (Veraviewepocs 2D<sup>®</sup>, J MORITA, MFG.



**Slika 1.** Poboljšani prikaz panoramske rendgenske snimke lubanje, s naglaskom na *ravnu liniju* iznad jedne ortodontske žice (10 mm)

**Figure 1** Enhanced image of a panoramic radiograph of the skull, highlighting the “straight line” over one of the orthodontic wires (10mm).



**Slika 2.** Jedan od korištenih ortopantomograma na kojemu se vidi kako su mjerene širina i visina maksilarnih sinusa

**Figure 2** Image of one of the panoramic radiographs used, showing how the width and the height of maxillary sinuses were measured.

jevoga i desnoga maksilarnog sinusa te lubanje – jedna horizontalno i druga vertikalno. Ta snimka služila je za kalibraciju programa za obradu Image J 1.47v (National Institute of Health, Bethesda, SAD). Isti program korišten je u analizi svih uzoraka u ovom istraživanju.

Tijekom istraživanja korišten je programski alat *ravna linija*. Najprije su izmjerene ortodontske žice na ortopantomogramskim snimkama (slika 1.), a zatim i maksilarni sinusi na svim uzorcima. U tu svrhu povučene su dvije paralelne vertikalne linije kako bi se označile distalne granice maksilarnog sinusa. Nakon toga povučene su horizontalne linije okomito na vertikalne prolazeći preko dna orbite od distalne do mezialne granice sinusa kako bi se dobila širina. Za određivanje visine spojena je sredina horizontalnih linija (slika 2.).

Dimenzijske vrijednosti maksilarnih sinusa dobivene mjerenjima ubačene su u Excelovu proračunsku tablicu (Windows 7<sup>®</sup>, Microsoft, Albuquerque, SAD). Za analizu tih podataka korišteni su hi-kvadrat test i analiza kappa, pri čemu je ova druga služila za procjenu varijabilnosti ispitivača. Osim toga, korištena je analiza varijance (ANOVA) i Studentov t-test za procjenu razlika između skupina. Razina značajnosti u statističkoj analizi postavljena je na 5 posto ( $p \leq 0,05$ ).

## Rezultati

Rezultati analize hi-kvadrat testom pokazali su za širinu ženskoga lijevog i desnog maksilarnog sinusa vrijednost od 0,387 i 0,513, a za muškarce 0,237, odnosno 0,355. Za visinu ženskoga lijevog i desnog maksilarnog sinusa vrijednosti su iznosile 0,346 i 0,157, a za muškarce 0,230 i 0,255. Ti podatci pokazali su podudarnost između analiza.

CORP, Kyoto, Japan) was used at FORP- USP radiology clinic, and a panoramic radiograph of a skull, that belongs to the clinic, was taken. 10-mm long orthodontic wires were set near the right and left maxillary sinuses of this skull, one horizontally and one vertically. This image made the calibration of the image processing program possible - Image J 1.47v (National Institute of Health, Bethesda, EUA). The same program was used for the analysis of all samples in this study.

During the course of this study, the “straight line” of the program was used. First, the measurements of the panoramic radiograph orthodontic wires were performed (Figure 1), and then the same procedure was repeated for the maxillary sinuses of all samples. Thus, two vertical lines, parallel to the left lateral extremity of the limiting rectangle of the panoramic radiograph image, were created to be “dragged” to the distal limits of each maxillary sinus. After that, horizontal lines, perpendicular to the horizontal ones, were drawn, passing over the floors of the orbits of the distal limit until the mesial limit of each sinus to obtain its width. For the height, the center of each horizontal line, until the floor of each maxillary sinus, was used (Figure 2).

The dimension values of the maxillary sinuses related to the analysis were fed to an Excel spreadsheet (Windows 7<sup>®</sup>, Microsoft, Albuquerque, USA). To assess these data, chi square test and Kappa analysis were used, the latter to assess intra-observer variability. In addition, ANOVA test and T student were used to evaluate the differences between groups. The significance level considered in the statistical analysis was 5% ( $p \leq 0.05$ ).

## Results

The evaluation of the intra-observer data obtained by means of chi square test showed that the width of female left and right maxillary sinus were 0.387 and 0.513 respectively, whereas for the male left and right maxillary sinus they were 0.237 and 0.355. For the height of female left and right maxillary sinus, the values were 0.346 and 0.157 respectively,

**Tablica 1.** Analiza kappa podudarnosti visine i širine obaju maksilarnih sinusa žena i muškaraca ( $p \leq 0,05$ ).

**Table 1** Kappa concordance analysis between female and male subjects for height and width of both maxillary sinuses ( $p \leq 0.05$ ).

Maksilarni sinusi • Maxillary sinuses	Žene • Female	Muškarci • Male
Visina lijevog sinusa • Left sinus height	0.969	0.712
Širina lijevog sinusa • Left sinus width	0.783	0.762
Visina desnog sinusa • Right sinus height	0.757	0.945
Širina desnog sinusa • Right sinus width	0.389	0.664

**Tablica 2.** Prosječne vrijednosti i standardne devijacije izmjerenih vrijednosti (visina i širina) za oba maksilarna sinusa kod žena i muškaraca. Studentov t-test ( $p \leq 0,05$ ).

**Table 2** Means and standard deviation measurements (height and width) of both maxillary sinuses for female and male subjects. T- Student ( $p \leq 0.05$ ).

Maksilarni sinusi • Maxillary sinuses	Prosječna vrijednost ± standardna devijacija (mm) • Mean ± Standard Deviation (mm)	
	Žene • Female	Muškarci • Male
Visina lijevog sinusa • Left sinus height	28.7856 ± 3.3929 <sup>aA</sup>	30.9981 ± 3.3866 <sup>aB</sup>
Širina lijevog sinusa • Left sinus width	44.6178 ± 4.6260 <sup>bA</sup>	48.7753 ± 4.2472 <sup>bB</sup>
Visina desnog sinusa • Right sinus height	27.7163 ± 3.9220 <sup>aA</sup>	30.7403 ± 3.5968 <sup>aB</sup>
Širina desnog sinusa • Right sinus width	45.1850 ± 2.8309 <sup>bA</sup>	48.5753 ± 4.4971 <sup>bB</sup>

Različita mala slova upućuju na statistički značajne razlike između redaka • Different lowercase letters indicate statistically significant differences between lines  
Različita velika slova upućuju na statistički značajne razlike između stupaca • Different Uppercase letters indicate statistically significant differences between columns

Analizom kappa utvrđena je značajna korelacija između muških i ženskih ortopantomograma s vrijednostima između 0,60 i 0,80 (značajna korelacija) (8), kako je prikazano u tablici 1.

Kad je riječ o razlikama između dimenzija desne i lijeve strane, nisu ustanovljene statistički značajne razlike u visini ili širini ni za jedan spol. S druge strane, postojale su razlike između prosječnih dimenzija maksilarnih sinusa za oba spola, kao što se vidi u tablici 2.

## Rasprava

Maksilarni sinusi odabrani su u ovom istraživanju zato što imaju obilježja koja ih čine pogodnima za identifikaciju ljudskih ostataka (9), primjerice za određivanje spola.

Ortopantomogram je dvodimenzionalna slika. Iako se na njoj anatomske strukture preklapaju (10), ipak je moguća vizualizacija svih zuba, čeljusti i nekih kosti lica jednom ekspozicijom (11). Zato se često primjenjuje u različitim granama dentalne medicine (12), što nas je ponukalo da ih odaberemo za ovo istraživanje.

Analiza sinusa lubanje kompjutoriziranom tomografijom (CT) česta je tema u literaturi, jer ima dobru rezoluciju i eliminira preklapanje objekata presječnim snimkama (13) te tako omogućuje trodimenzionalne informacije (14), pa se zadovoljavajuće može procijeniti anatomija sinusa i njihovih čestih varijacija (13). No unatoč informacijama koje pruža ova vrsta slika, visoka cijena opreme može se smatrati ograničenjem u primjeni te tehnike u forenzične svrhe, posebno u Brazilu gdje većina zavoda za sudsku medicinu nema dovoljno novca (15).

Maksilarni sinus anatomska je struktura koju je teško analizirati ako rendgensku snimku tumači manje iskusan kliničar (16). U ovom istraživanju ponovljivost ispitivača bila je konstantna u većini analiza, osim za desni ženski sinus.

Širina i visina maksilarnih sinusa može se, u kombinaciji s drugim kostima, koristiti za određivanje spola ako kostur nije potpun (17). Zna se da maksilarni sinusi anatomske variraju ovisno o spolu, a to se može vidjeti i u ovom istraživanju u kojemu su prosječne vrijednosti širine i visine muških maksilarnih sinusa bile veće od vrijednosti ženskih.

Za razliku od otkrića Osmana i suradnika (18) da je visina lijevog sinusa najbolji parametar za razlikovanje spolova, ovo je istraživanje pokazalo da su relevantne i visina i širina obaju sinusa.

Teke i suradnici (17) također su istaknuli da je prosječna visina muškoga maksilarnog sinusa bila veća u usporedbi sa ženskim, što je u skladu s rezultatima ovog istraživanja. No za razliku od naših nalaza, u drugim istraživanjima (18 – 20) ustanovljeno je da prosječna širina maksilarnih sinusa ne pokazuje statistički značajnu razliku između muškaraca [(24,04 ± 4,71 mm (19); 21,8 ± 3,4 mm (20) i 25,15 ± 4,2 mm (18)] i žena [(22,85 ± 3,6 mm (18), 23,9 ± 4,38 mm (19) i 21,6 ± 3,7 mm (20)].

Također nisu postojale bitne razlike između Južnoafrikanaca i Europljana, kad je riječ o širini gornjih sinusa u oba

whereas for the height of male left and right maxillary sinus, they were 0.230 and 0.255. The data showed a high compatibility between the analyses. A significant correlation between male and female panoramic radiographs was observed by means of Kappa analysis, between 0.60 and 0.80 (substantial correlation) (10), as shown in Table 1.

Regarding the differences between right and left dimensions, no statistical difference was found in height or in width, for both sexes. On the other hand, there were differences between the mean values of the maxillary sinuses dimensions evaluated for both sexes, as shown in Table 2.

## Discussion

The maxillary sinuses were chosen for this study due to the fact that they present features suggesting that they can be used to identify human remains (11), helping, for example, to determine sex.

Panoramic radiographs are two-dimensional images and, even though anatomic structures overlap (12), they allow the visualization of all teeth, the maxilla, jaws and some facial bones in a single exposure (13). Therefore, they are often used in several dental specialties (14), which motivated us to use them in our study.

Recent literature highlights excellent diagnostic accuracy of Computed Tomography due to its broad availability and high special resolution. The analysis of facial sinuses by means of Computed Tomography (CT scan) is often present in the literature. Computed Tomography is a highly effective technique because it eliminates the overlapping of structures by creating sectional images (15), providing tridimensional information (16), which allows a satisfactory assessment of the anatomy of the sinuses and their frequent variations (15). However, in spite of the high-definition of this kind of image, the high cost to acquire such equipment may be considered a limitation for this technique to be used in the forensic field, particularly in Brazil where most Medical Examiner Offices lack resources (17).

The maxillary sinus is the anatomic structure that can be difficult to analyze when its radiographic image is interpreted by a less trained professional (18). In this study, the intra-observer variability analysis was substantial in most analyses, except in the analysis of the right female sinus, which was in fair agreement.

The width and height of maxillary sinuses can be used with other bones to determine sex when the skeleton is not complete (19). It is known that maxillary sinuses present anatomic variables between sexes, and this could be seen in the present study, in which the mean width and height values for both male maxillary sinuses were greater than the values for both female maxillary sinuses.

Unlike the facts pointed out by Uthman et al., (20) who observed that the height of the left sinus was the best variable to discriminate between sexes, the present study showed that both the height and the width of both sinuses were relevant for the differentiation between sexes.

Teke et al., (19) also found that the mean height of male maxillary sinuses is bigger than the female ones, which is

spola. No mjerenja dubine, visine i volumena maksilarnih sinusa pokazala su znatne razlike među spolovima (21).

U skladu s rezultatima ovog istraživanja, Jasim i Al-Taei (22), koji su se također koristili ozubljenom skupinom kao uzorkom, dobili su sljedeće prosječne vrijednosti širine i visine desnog i lijevog maksilarnog sinusa: za muškarce  $24,07 \pm 0,62$  mm;  $24,67 \pm 0,63$  mm i  $39,68 \pm 0,61$ mm;  $39,50 \pm 0,63$  mm, a za žene  $22,38 \pm 0,95$  mm;  $22,26 \pm 0,94$  mm i  $36,55 \pm 1,26$  mm i  $36,67 \pm 1,06$  mm. Autori nisu pronašli značajnu razliku između lijevoga i desnoga sinusa, ali su ustanovili da su maksilarni sinusi muškaraca bili širi, dublji i većega volumena od ženskih (22).

U istraživanju Masrija i suradnika (23) veličina svih varijabli maksilarnih sinusa (širina, dubina, visina i volumen) bila je veća kod muškaraca negoli kod žena, ali razlike su bile statistički značajne samo za visinu i širinu. Ti rezultati slažu se s rezultatima Kawarija i suradnika (24) koji su također zaključili da muškarci imaju šire sinuse.

U istraživanjima u kojima su korištene CT snimke dobivene su veće vrijednosti za visinu negoli za širinu u oba spola, što je suprotno rezultatima ovog istraživanja u kojemu su širine bile veće od visina (tablica 2.). To je posljedica razlika u rendgenskim pretragama – CT daje trodimenzionalnu sliku (14), a ortopantomogram je dvodimenzionalan (10). No rezultati su se podudarali u veličini – maksilarni sinusi muškaraca bili su veći od ženskih.

U istraživanju s ortopantomogramima na kojima su mjerenja provedena ručno, prosječna visina lijevoga i desnoga maksilarnog sinusa za muškarce iznosila je  $43,59 \pm 6,46$  milimetara, odnosno  $44,34 \pm 9,54$  milimetra, a za žene  $38,95 \pm 7,18$  milimetara, odnosno  $40,61 \pm 7,47$  milimetara. Širina sinusa muškaraca iznosila je  $38,95 \pm 7,18$  milimetara, odnosno  $40,61 \pm 7,47$  milimetara, a žena  $46,02 \pm 6,49$  milimetara, odnosno  $48,73 \pm 6,85$  milimetara. To istraživanje pokazalo je značajnu razliku između spolova, osim za varijablu širine lijevog sinusa (12). Vrijednosti koje su dobili navedeni autori slične su onima u ovom istraživanju kad je riječ o širini sinusa za oba spola. No kad je riječ o visini vrijednosti, bitno se razlikuju. Oba istraživanja pokazala su da je širina veća negoli visina u oba spola, te je istaknuta snažna korelacija između istraživanja koja se koriste istom rendgenskom metodom.

Razlike između istraživanja mogu biti posljedica razlika u veličini uzoraka, kriterijima, metodama mjerenja, korištenim referentnim točkama ili vrsti analize (25). Nadalje, razlike mogu nastati zbog nekoliko čimbenika, a ponajprije zbog razlika u ispitnim skupinama, kao što su boja kože, konstitucija, veličina kostura, okolišni čimbenici, pneumatizacija sinusa u različitim dobnim i spolnim skupinama (26), te ozubljenost ili bezubost (27).

U ovom istraživanju nisu kontrolirani podrijetlo i konstitucija jer smo se koristili ortopantomogramima koji su bili dostupni u FORP-USP bazi podataka, a čini je vrlo mješovita brazilska populacija (28). Kad je riječ o promjenama zbog gubitka zuba, u ovo istraživanje uključeni su ozubljeni pojedinci s trećim kutnjakom ili bez njega, kako bi se izbjegle takve varijacije.

Može se zaključiti da je osoba s maksilarnim sinusima višima od 31 milimetar i širima od 48 milimetara muškarac, a

in agreement with the present study. However, some studies, which are not in agreement with our findings (20-22), found that data related to the mean width of maxillary sinuses showed no statistical difference for males ( $24.04 \pm 4.71$  mm (19);  $21.8 \pm 3.4$  mm (22) and  $25.15 \pm 4.2$  mm (20)) compared to females ( $22.85 \pm 3.6$  mm; (20)  $23.9 \pm 4.38$  mm (21) and  $21.6 \pm 3.7$  mm (22)).

Also, there was no evident difference between South Africans and Europeans regarding the width of maxillary sinuses for both sexes. However, measurements of depth, height and volume of maxillary sinuses showed significant differences between sexes (23).

In agreement with the data of the present study, Jasim & Al-Taei (24), who also used a dentulous group as sample, obtained the following mean values for the width and height of the right and left maxillary sinuses: for male subjects,  $24.07 \pm 0.62$  mm;  $24.67 \pm 0.63$  mm and  $39.68 \pm 0.61$  mm;  $39.50 \pm 0.63$  mm respectively, and for the female ones they were  $22.38 \pm 0.95$  mm;  $22.26 \pm 0.94$  mm and  $36.55 \pm 1.26$  mm e  $36.67 \pm 1.06$  mm. The authors did not find any significant differences between right and left sinuses, but they could see that male maxillary sinuses are wider, deeper, and higher and have more volume than the female ones (24).

In the Masri et al., (25) study, the sizes of all maxillary sinuses variables (width, depth, height and volume) were larger in male samples than in the female ones, but only the height and width showed significant differences. These findings agree with those of Kawari et al., (26) who also found that men have wider sinuses.

In the CT scan studies, it was possible to observe that the height values were greater than the width values, for both sexes, which disagrees with the data obtained from this study where the width measurements were greater than the height measurements (Table 2). This is due to the difference between the radiographic examinations used; CT scan provides tridimensional images (16), whereas panoramic radiographs provide two-dimensional ones (12). However, there was agreement regarding male individuals having larger maxillary sinuses than female individuals.

In a study with panoramic radiographs, that used manual technique to obtain the measurements, the mean height of male right and left maxillary sinuses was  $43.59 \pm 6.46$  mm;  $44.34 \pm 9.54$  mm respectively, and for women,  $38.95 \pm 7.18$  mm;  $40.61 \pm 7.47$  mm respectively. The width of the sinuses for men was  $38.95 \pm 7.18$  mm;  $40.61 \pm 7.47$  mm respectively, and for women,  $46.02 \pm 6.49$  mm;  $48.73 \pm 6.85$  mm respectively. This study showed significant difference between sexes, except for the left width variable (14). The data obtained by those authors showed values that are similar to data in the present study regarding the width of the sinuses for both sexes. However, regarding the height, the values were rather different. Both studies showed that the width was larger than the height for both sexes, stressing a strong correlation between studies that used the same radiographic examinations.

The differences between the studies may be explained by the fact that researchers used different sample sizes, inclusion criteria, measurement methods, regions or reference points or different kinds of analyses (27). Moreover, differences can

u slučaju visine manje od 27 milimetara te širine manje od 44 milimetra vjerojatno riječ o ženi. No ako se vrijednosti visine kreću između 27 i 31 milimetar, a širine između 44 i 48 milimetara, nemoguće je pouzdano odrediti spol.

Drugi relevantan nalaz ovog istraživanja jest da se spol može odrediti čak ako je lubanja fragmentirana dok god postoji jedan maksilarni sinus, s obzirom na to da ne postoji statistički značajna razlika između lijevoga i desnoga sinusa istog pojedinca.

Prema našim rezultatima, panoramske rendgenske snimke mogu biti korisne. No postoje neka ograničenja za njihovo korištenje u forenzičnom području, poput nedostatka opreme u većini laboratorija i nemogućnosti da se postmortalni ostatci postave u statički ili sjedeći položaj zbog mrtvačke ukočenosti (29). Također valja istaknuti da rendgenske snimke često nisu obrađene ili fiksirane, što ograničava njihovu primjenu (30).

## Zaključak

Dimenzije maksilarnih sinusa na panoramskim rendgenskim snimkama mogu poslužiti za određivanje spola odraslih ljudi jer su kod muškaraca zabilježene veće prosječne vrijednosti visine i širine sinusa negoli kod žena, bez značajne razliku između lijeve i desne strane u oba spola.

## Sukob interesa

Nije ga bilo.

appear due to several factors, but especially the difference in group ancestry, such as stature, size of skeleton, body build, environmental factors, pneumatization process of sinuses in different age and sex groups (28), as well as presence or absence of teeth (29).

In the present study, ancestry and body build were not controlled since we used panoramic radiographs that were available in the School of Dentistry of Ribeirao Preto database, comprising Brazilian population, which is very mixed (30). To avoid biases such as alterations due to tooth loss, fully dentate individuals with the third molar and those who were missing it, were included in this study.

Thus, it is possible to infer that subjects with maxillary sinuses higher than 31mm and wider than 48mm are male, whereas when they are less than 27mm high and less than 44mm wide, it is likely that the subject is female. However, when the values are between 27mm and 31mm for height, and 44mm and 48mm for width, it is impossible to determine the sex.

Another relevant finding of this study is that it is possible to determine sex even if the skull is fragmented as long as there is one maxillary sinus, since there is no statistical difference between left and right sinuses of the same individual.

According to our findings, panoramic radiographs can be very useful. However, there are some limitations to use them in the forensic area, such as lack of equipment in most forensic laboratories, and the difficulty to put the remains in a static or sitting position, due to rigor mortis (31). It is also noteworthy, as is often the case, that radiographs are not filed, processed or fixed, which limits their application (32).

## Conclusion

Maxillary sinuses dimensions in panoramic radiographic images, such as height and width, can be used to determine sex in adults, since men have greater mean values of height and width, for both sinuses than women. There were no significant differences between right and left maxillary sinuses for both sexes.

## Conflict of interest

None declared.

### Abstract

The purpose of this study was to evaluate dimensions of adult human maxillary sinuses on panoramic radiographs and their possible application on the sex determination for forensic purposes. The sample comprised 64 database panoramic radiographs from individuals aged 20 years or older (32 male and 32 female subjects), with complete permanent dentition (or absence of third molars). One examiner measured the width and height of the right and left maxillary sinuses using the software Image J 1.47v (National Institutes of Health, Bethesda, USA). Measurements were repeated to calculate intra-observer agreement. Chi-Square test, Kappa, ANOVA and T-Student were used for results analysis for  $p \leq 0.05$ . Intra-observer agreement with correlation Kappa ranged between 0.38 and 0.96. For female subjects, the mean height and width of the left maxillary sinus were 28.7856mm and 44.6178mm, respectively. And right maxillary sinus was 27.7163mm for height and 45.1850mm for width. Male subjects were found to have the mean height and width of the left maxillary sinus 30.9981mm and 48.7753mm, respectively. And right maxillary sinus was 30.7403mm for height and 48.5753mm for width. There was a statistically significant difference in the height and width of maxillary sinuses between males and females. It can be concluded that maxillary sinuses height and width on panoramic radiographs can be used to determine the gender of adult human subjects.

Received: May 11, 2016

Accepted: July 5, 2016

### Address for correspondence

Ricardo Henrique Alves da Silva  
University of Sao Paulo  
School of Dentistry of Ribeirao Preto  
Department of Stomatology, Public Health and Forensic Dentistry  
Sao Paulo, Brazil.  
ricardohenrique@usp.br

### Key words

Maxillary Sinus; Maxillary Bone; Panoramic Radiography; Forensic Dentistry; Forensic Medicine; Sex Determination by Skeleton

## References

1. Vanrell JP. *Odontologia Legal e Antropologia Forense*. 1st ed. Rio de Janeiro: Guanabara Koogan, 2001.
2. Silva RF, Franco A, Picoli FF, Nunes FG, Estrela C. Dental Identification Through Endodontic Radiographic Records: a Case Report. *Acta stomatol Croat*. 2014;48(2):147-150.
3. Staka G, Bimbashi V, Disha M, Dragidella F. Sexual Dimorphism in the Permanent Mandibular Canines: A study in Albanian Population of Kosovo. *Acta stomatol Croat*. 2013;47(1):39-44.
4. Scheuer L. Application of osteology to forensic medicine. *Clin Anat*. 2002 Jun;15(4):297-312.
5. Saini V, Srivastava R, Rai RK, Shamal SN, Singh TB, Tripathi SK. *J Forensic Sci*. 2011 Jan;56 Suppl 1:S13-6.
6. Parks ET. Cone beam computed tomography for the nasal cavity and paranasal sinuses. *Dent Clin North Am*. 2014 Jul;58(3):627-51.
7. Schulze R, Krummenauer F, Schalldac F, d'Hooedt B. Precision and accuracy of measurements in digital panoramic radiography. *Dentomaxillofac Radiol*. 2000 Jan;29(1):52-6.
8. Perrella A, Rocha SS, Cavalcanti RGP. Quantitative analyses of maxillary sinus using computed tomography. *J Appl Oral Sci* 2003; 11:229-233.
9. Fernandes CL. Forensic ethnic identification of crania: the role of the maxillary sinus - a new approach. *Am J Forensic Med Pathol*. 2004 Dec;25(4):302-13.
10. Landis JR, Koch GG. The measurement of observer agreement for categorical data. *Biometrics*. 1977 Mar;33(1):159-74.
11. Kinsui MM, Guilherme A, Yamashita HK. Variações anatômicas e sinusopatias: estudo por tomografia computadorizada. *Rev Bras Otorrinolaringol* 2002;68:645-652.
12. Yeo DK, Freer TJ, Brockhurst PJ. Distortions in panoramic radiographs. *Aust Orthod J*. 2002 Nov;18(2):92-8.
13. Mincer HH, Chaudhry J, Blankenship JA, Turner EW. Postmortem dental radiography. *J Forensic Sci*. 2008 Mar;53(2):405-7.
14. Musse JO, Marques JAM, Oliveira RN. Contribuição da análise do seio maxilar para a identificação humana. *Saúde, Ética & Justiça*. 2009;14:65-76.
15. Cameriere R, Ferrante L, Mirtella D, Rollo FU, Cingolani M. Frontal sinuses for identification: quality of classifications, possible error and potential corrections. *J Forensic Sci*. 2005 Jul;50(4):770-3.
16. Reichs KJ. Quantified comparison of frontal sinus patterns by means of computed tomography. *Forensic Sci Int*. 1993 Oct;61(2-3):141-68.
17. Musse JO, Marques JAM, Vilas Boas CDF, Sousa RSV, Oliveira Marques JAM, Vilas Boas CDF, et al. Importância pericial das radiografias panorâmicas e da análise odontológica para identificação humana: relato de caso. *Rev Odontol UNESP, Araraquara*. 2011;40:108-111.
18. Antoniazzi MCC, Carvalho PL, Koide CH. Importância do conhecimento da anatomia radiográfica para interpretação de patologias ósseas. *RGO*. 2008;56:195-199.
19. Teke HY, Duran S, Canturk N, Canturk G. Determination of gender by measuring the size of maxillary sinuses in computerized tomography scans. *Surg Radiol Anat*. 2007 Feb;29(1):9-13.
20. Uthman AT, Al-Rawi NH, Al-Naaimi AS, Al-Timimi JF. Evaluation of Maxillary Sinus Dimensions in Gender Determination Using Helical CT Scanning. *J Forensic Sci*. 2011 Mar;56(2):403-8.
21. Jehan M, Bhadkaria V, Trivedi A, Sharma SK. Sexual Dimorphism of Bizygomatic distance & Maxillary sinus using CT Scan. *IOSR-JD-MS*. 2014;13:91-95.
22. Baweja S, Dixit A, Baweja S. Study of age related changes of maxillary air sinus from its anteroposterior, transverse and vertical dimensions using Computerized Tomographic (CT) scan. *IJBR*. 2013;04:21-25.
23. Fernandes CL. Volumetric analysis of maxillary sinuses of Zulu and European crania by helical, multislice computed tomography. *J Laryngol Otol*. 2004 Nov;118(11):877-81.
24. Jasim HH, Al-Taei JA. Computed tomographic measurement of maxillary sinus volume and dimension in correlation to the age and gender (comparative study among individuals with dentate and edentulous maxilla). *J Bagh College Dentistry*. 2013; 25:87-93.
25. Masri AA, Yusof A, Hassan R. A Three Dimensional Computed Tomography (3D-CT): A Study of Maxillary Sinus in Malays. *CJBAS*. 2013;01:125-134.
26. Kawarai Y, Fukushima K, Ogawa T, Nishizaki K, Gunduz M, Fujimoto M, et al. Volume quantification of healthy paranasal cavity by three-dimensional CT imaging. *Acta Otolaryngol Suppl*. 1999;540:45-9.
27. Virapongse C, Sarwar M, Bhimani S, Sasaki C, Shapiro R. Computed tomography of temporal bone pneumatization: 1. Normal pattern and morphology. *AJR Am J Roentgenol*. 1985 Sep;145(3):473-81.
28. Sharan A, Madjar D. Maxillary sinus pneumatization following extractions: a radiographic study. *Int J Oral Maxillofac Implants*. 2008 Jan-Feb;23(1):48-56.
29. Harorh A, Bacutoglu O. The composition of vertical height and width of maxillary sinus by means of Water's view radiograms taken from dentate and edentulous cases. *Ann Dent*. 1995 Summer-Fall;54(1-2):47-9.
30. Francisco RA, Velloso APS, Silveira TCP, Secchieri JM, Guimaraes MA. Evolução dos casos de Antropologia Forense no Centro de Medicina Legal (CEMEL) da Faculdade de Medicina de Ribeirão Preto USP de 1999 a 2010. *Revista da Faculdade de Medicina de Ribeirão Preto e do Hospital das Clínicas da FMRP Universidade de São Paulo*. 2011;44: 251-258.
31. Mincer HH, Chaudhry J, Blankenship JA, Turner EW. Postmortem dental radiography. *J Forensic Sci*. 2008 Mar;53(2):405-7.
32. Silva RF, Pereira SDR, Mendes SDSC, Marinho DEA, Júnior ED. Radiografias odontológicas: fonte de informação para identificação humana. *Int J Oral Maxillofac Implants*. 2008 Jan-Feb;23(1):48-56.