

Fotios Tzerbos¹, Fotios Bountaniotis¹, Nadia Theologie-Lygidakis¹, Dimitrios Fakitsas², Ioannis Fakitsas²

Komplikacije zigomatičnih implantata: Kliničko iskustvo s prikazom četiriju slučajeva

Complications of Zygomatic Implants: Our Clinical Experience with 4 Cases

¹ Zavod za oralnu i maksilofacijalnu kirurgiju Stomatološkog fakulteta Državnoga kapodistrijskog sveučilišta, Atena, Grčka
Department of Oral & Maxillofacial Surgery (Head: Professor Iatrou I.), Dental School of Athens, National and Kapodistrian University of Athens, Greece

² Privatna ordinacija, Atena, Grčka
Private practice, Athens, Greece

Sažetak

Zigomatični implantati koriste se već gotovo dvadeset godina kao alternativa presađivanju kosti pri rehabilitaciji bezube i atropične maksile i pritom su postignuti zadovoljavajući klinički rezultati. Ipak, pacijentima liječenima tom tehnikom mogu se razviti ozbiljne komplikacije koje mogu ugroziti protećki rad. Četiri takva slučaja opisana su u ovom izvještaju – prvi s kožnom fistulom u zigomatično-orbitalnom području uzrokovanom aseptičnom nekrozom na apikalnom kraju implantata koja je liječena kirurškim uklanjanjem toga dijela; u drugom slučaju to je bio gubitak implantata zbog neuspjele osteointegracije pa je cijeli usadak uklonjen, a u trećem i četvrtom slučaju riječ je o periimplantitisu i djelomičnom uklanjanju implantata. Sve komplikacije liječene su bez ugrožavanja restauracije koja je ostala funkcionalna nakon odgovarajućih prilagodbi.

Zaprimljen: 12. ožujka 2016.

Prihvaćen: 24. svibnja 2016.

Adresa za dopisivanje

Fotios Bountaniotis
Arch. Makariou kai Makedonias street,
18 900, Salamis, Greece
tel: +30 6942892491/ +30
2104652749
faks: +30 2107461266
fboudaniotis@yahoo.gr

Ključne riječi

zigoma; zubni implantati; oralna fistula; periimplantitis; bezuba čeljust; gornja čeljust; atrofija

Uvod

Opsežna resorpcija, uz lošu kvalitetu kosti, u kombinaciji s povećanom pneumatizacijom maksilarnih sinusa često omogućuje postavljanje klasičnih zubnih implantata u stražnjoj maksili. Za povećanje volumena potporne kosti postoje razne tehnike augmentacije, poput podizanja dna sinusa i koštanog nasadivanja. Tim se postupcima traže alternative, a jedna od njih, posebno u slučaju atrofične maksile, jest korištenje zigomatičnih implantata. Taj implantat koji je uveden u protetsku rehabilitaciju pacijenata s opsežnim defektima maksile zbog resekcija tumora, trauma ili prirodnih defekata, koristi se i za pacijente s bezubom atrofičnom maksilom jer omogućuje rehabilitaciju sa zadovoljavajućom funkcijom i poboljšanom estetikom (1-5). No postavljanje zigomatičnih implantata nije bez rizika jer zahvaća osjetljive anatomske strukture, poput orbite i zato je obvezno kirurško iskustvo (6). U literaturi su opisane mnogobrojne komplikacije, među kojima je najčešći sinusitis (7). Svrha ovog članka bila je izvijestiti o komplikacijama u četirima kliničkim slučajevima i o njihovoj terapiji nakon postavljanja zigomatičnih implantata te dati pregled raspoložive literature o toj temi.

Introduction

Excessive bone resorption combined with poor bone quality and increased maxillary sinus pneumatization often making it impossible to place conventional dental implants in the posterior maxilla. Various bone augmentation techniques, such as sinus floor elevation and onlay bone grafting, have been described in order to increase the volume of load-bearing bone. Nevertheless, efforts have been made to pursue alternatives to grafting procedures and one of these, especially in the atrophic maxilla, is the use of zygomatic implants. This implant which was initially introduced for the prosthetic rehabilitation of patients with extensive defects of the maxilla caused by tumor resections, trauma or congenital defects was also used in patients with edentulous atrophic maxilla, enabling rehabilitation with sufficient function and improved esthetics (1-5). However, the placement of zygomatic implant is not deprived of risks, since it may involve delicate anatomical structures such as the orbit, and therefore surgical experience is required (6). Additionally, many complications have been reported in the literature, with sinusitis being the most common (7).

Prikaz slučaja

Slučaj 1

U našu kliniku došla je žena u dobi od 37 godina s generaliziranim paradontitisom. Opsežnom kliničkom i radiografskom procjenom ustanovljena je resorpcija alveolarne kosti, što je bila nepovoljna prognoza za sve zube u gornjoj čeljusti. Pacijentica je, osim što je bila pušačica, bila zdrava i vrlo zahtjevna. Iznimno je preferirala trenutačnu rehabilitaciju bez postupka presađivanja i zato je kao najbolja terapija odabran zigomatični implantat. Nakon vađenja gornjih zuba postavljena su dva zigomatična implantata, svaki na svojoj strani u kombinaciji s klasičnim implantatima u prednjem dijelu maksile te je izrađena i prilagođena imedijatna protetička restauracija. Nakon jedne godine pacijentica je došla na kontrolu s kožnom fistulom u lijevom zigomatično-orbitalnom području zbog aseptičke nekroze oko apikalnog dijela lijevoga zigomatičnog implantata (slika 1.). Kako bi se taj problem riješio, a da se pritom ne ugrozi restauracija, nakon uklonjenja fistuloznog kanala odrezan je apikalni dio implantata koji je virio iz zigomatične kosti, a preostali dio implantata i restauracija zadržani su, te su ostali funkcionalni bez potrebe za daljnjim intervencijama (slike 2.a, 2.b, 2.c i 3). Deset godina nakon kirurškog zahvata nije bilo ni znakova ni simptoma infekcije u zigomatičnom području.

Slučaj 2

U našu kliniku je radi rehabilitacije došla 57-godišnja pacijentica s bezubom atrofičnom maksilom. Imala je dobro kontroliran dijabetes tipa 2 liječen metforminom, a drugih zdravstvenih tegoba nije imala. Zbog obostrane uznapredovane resorpcije stražnjeg dijela maksile, odabrana je terapija s dvama zigomatičnim implantatima u kombinaciji s klasičnim implantatima sprijeda. Slijedila je izrada imedijatne restauracije na klasičnim implantatima. Četiri mjeseca nakon kirurškoga zahvata, kliničkim pregledom otkriveno je da se desni zigomatični implantat nije integrirao u kost. Učinjen je mali rez oko pokrovnog vijka implantata te je cijeli zigomatični usadak uklonjen zubnim kliještima (slika 4.). Pacijentica nije htjela nadomjestiti uklonjeni implantat novim jer je to smatrala velikim zahvatom. Preostali implantati uspješno su osteointegrirani te je postavljena trajna restauracija koja je dosegala do desnog područja pretkutnjaka kako bi se smanjio učinak neravnoteže (slika 5.a, b). Pacijentica dolazi na kontrole i do danas nije uočen nikakav daljnji problem, a restauracija je ostala funkcionalna.

Slučaj 3

Pacijent bez zdravstvenih problema u dobi od 45 godina s generaliziranim uznapredovanim paradontitisom liječen je

The aim of this paper is to report and discuss the complications and their treatment after zygomatic implant surgery in 4 cases and to review the contemporary literature on this subject.

Cases report

Case 1

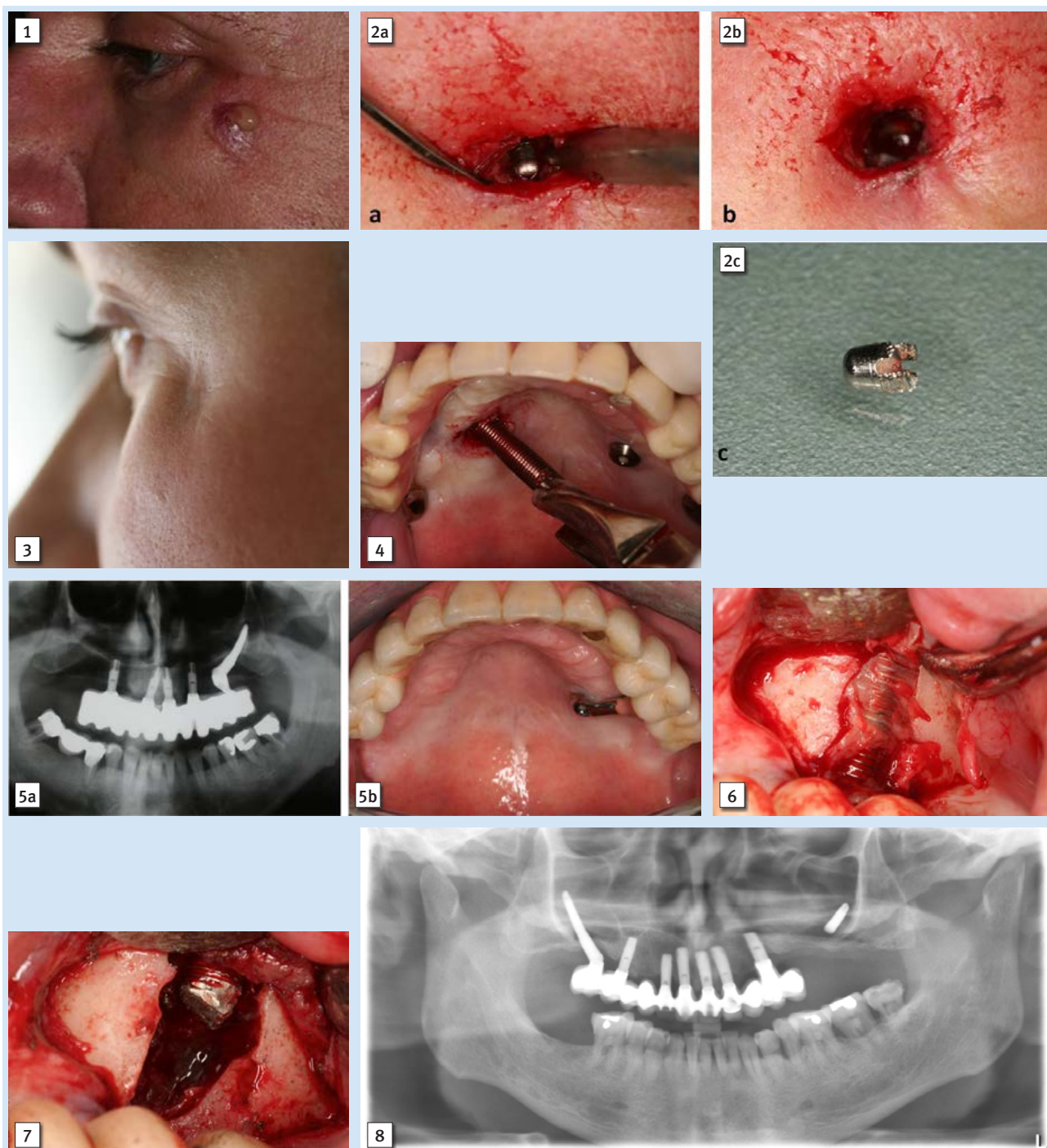
A 37-year-old female patient with generalized periodontitis presented to our clinic. A comprehensive clinical and radiographic evaluation revealed advanced alveolar bone resorption rendering the prognosis of all upper teeth unfavorable. Apart from smoking, the patient was otherwise healthy and very demanding. She strongly preferred an immediate rehabilitation without grafting procedures; therefore zygomatic implants were considered the best treatment for her. Following the extractions of the upper teeth, two zygomatic implants were placed, one on each side, in combination with four conventional implants in the anterior maxilla and an immediate prosthetic restoration was fabricated and adjusted. After one year, the patient presented with a cutaneous fistula in the left zygomatic-orbital area because of aseptic necrosis in the apical part of the left zygomatic implant (Figure 1). In order to deal with this complication without compromising the prosthetic restoration, after the removal of the fistula canal, the apical part of the implant which extruded exteriorly to the zygomatic bone was cut off and removed while the remaining implant and the restoration were retained and were functional with no need for further intervention (Figure 2a, b, c, Figure 3). Ten years after surgery, there were no signs and symptoms of infection in the zygomatic area.

Case 2

A 57-year-old female patient with edentulous atrophic maxilla was referred to our clinic for rehabilitation. She had a well-controlled, type-2 diabetes mellitus, treated with metformin, without other health problems or medications. Because of the bilateral advanced bone resorption in the posterior maxilla, the use of two zygomatic implants in combination with conventional implants anteriorly was the treatment of choice followed by fabrication of an immediate restoration supported by the conventional implants only. Four months after surgery, clinical examination of the implants revealed that the right zygomatic one had failed to osseointegrate. A small incision around the implant's cover screw was performed and the zygomatic implant was removed using dental forceps (Figure 4). The patient did not wish to replace the missing implant with a new one because she considered it a major procedure. However, the remaining implants were successfully osseointegrated and therefore, a permanent restoration extending to the premolar area on the right side, in order to reduce the cantilever effect, was placed (Figure 5a,b). The patient has been followed up for 7 years. So far, no further problem has occurred and the restoration has remained functional.

Case 3

A 45-year-old male smoker, with no health problems but with generalized advanced periodontitis was treated with two



Slika 1. Zagnojena koštana fistula u lijevom zigomatično-orbitanom području

Figure 1 Cutaneous fistula with suppuration in the left zygomatic-orbital area.

Slika 2. a) Prikaz apikalnog dijela implantata, b) Kirurško područje nakon uklanjanja, c) Uklonjeni dio implantata

Figure 2 a) Exposure of the apical part of the implant, b) Surgical site after its removal, c) the implant part that was removed.

Slika 3. Lijevo zigomatično-orbitarno područje 6 mjeseci postoperativno

Figure 3 The left zygomatic-orbital area, 6 months postoperatively.

Slika 4. Uklanjanje desnoga zigomatičnog implantata kliještima za zube

Figure 4 Removal of the right zygomatic implant with the dental forceps.

Slika 5a,b. Radiogram i klinička slika s konačnom restauracijom

Figure 5a,b Radiographic and clinical image with the final restoration.

Slika 6. Uznapredovana resorpcija kosti oko zigomatičnog implantata zbog periimplantitisa

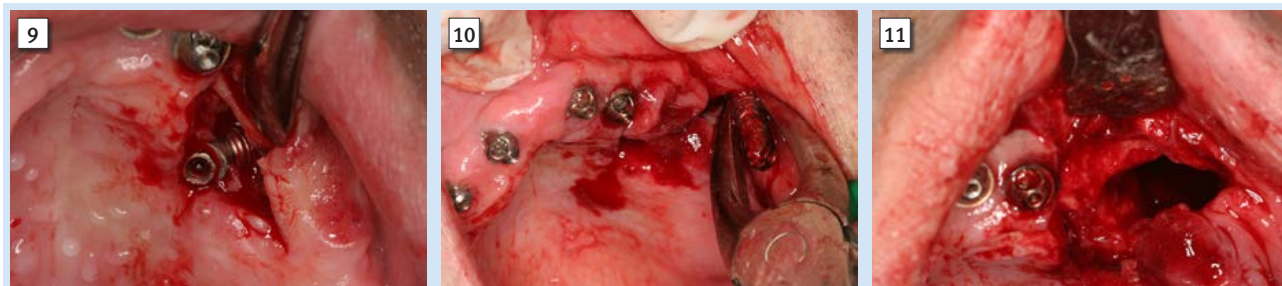Figure 6 Advanced bone resorption around zygomatic implant because of periimplantitis.

Slika 7. Uklanjanje kontaminiranog dijela implantata bez probijanja membrane sinusa

Figure 7 Removal of the contaminated implant part without penetrating the sinus membrane.

Slika 8. Panoramski radiogram s prikazom preostalog dijela zigomatičnog implantata integriranog u zigomatičnoj kosti nakon potrebne prilagodbe restauracije

Figure 8 Panoramic radiograph, showing the rest of the implant remaining integrated in zygomatic bone, after making the necessary modifications of the restoration.



Slika 9. Podignuti režanj s prikazom izloženih navoja implantata

Figure 9 Flap elevation revealing the exposed implant threads.

Slika 10. Uklanjanje implantata kliještima za zube

Figure 10 Removal of the implant using dental forceps.

Slika 11. Kirurško područje s otvorenom sinusnom šupljinom nakon uklanjanja implantata

Figure 11 Surgical site, with the sinus cavity being exposed, after the removal of the implant.

s dvama zigomatičnim implantatima – svaki s jedne strane, te šest standardnih implantata srijeda. Pet godina nakon zahvata, kliničkim pregledom ustanovljen je periimplantitis lijevoga zigomatičnog imlantata s velikim gubitkom kosti, što je onemogućilo nekiruršku terapiju. No nakon podizanja reznja i procjene štete, odlučeno je odrezati i ukloniti kontaminirani dio implantata, a ostaviti dio integriran u zigomatičnu kosti (slika 6., 7.). Nadalje, fiksni rad modificiran je rezanjem i uklanjanjem dijela u području kutnjaka koji je bio poduprt lijevim zigomatičnim implantatom, a u svrhu zadržavanja funkcije (slika 8.). Pet godina postoperativno restauracija je bila funkcionalna, a dio zigomatičnog implantata usidren u zigomatičnoj kosti bio je asimptomatičan.

Slučaj 4

Muškarac u dobi od 52 godine, inače zdrav, liječen je u našoj klinici i dobio je fiksnu protetičku restauraciju na dva zigomatična implantata i pet klasičnih u prednjoj maksili. Nakon gotovo dvije godine došao je na pregled zbog uznapredovanog oblika periimplantitisa lijevoga zigomatičnog implantata, opsežne resorpcije kosti i oroantralne fistule. Ta komplikacija riješena je potpunim uklanjanjem zigomatičnog implantata (9, 10, 11). U petogodišnjem kontrolnom razdoblju nije bilo znakova patologije sinusa.

Rasprava

Tijekom 15 godina u našoj klinici desetero je pacijenta (6 muškaraca i 4 žene u dobi od 37 do 72 godine) liječeno zigomatičnim implantatima na objema stranama u kombinaciji s klasičnim implantatima u prednjoj maksili. Komplikacije su se pojavile kod četiri pacijenta, te su dva zigomatična implantata potpuno uklonjena, jedan je prerezan i djelomično uklonjen, a jednom je uklonjen apikalni dio uz zadržavanje funkcije. Ukupno su tri od dvadeset zigomatičnih implantata izgubljena, što iznosi stupanj preživljavanja od 85 posto. Stupanj preživljavanja zigomatičnih implantata, prema stajalištima različitih autora, kreće se od 82 do 100 posto (1). Iz sustavnog pregleda 25 istraživanja sa srednjim vremenom kontrole od 42,2 mjeseca (raspon 0 – 144 mjeseca) i ukupno 1541 zigomatičnim implantatom, Goiato i suradnici izraču-

zygomatic implants, one on each side, and six conventional implants anteriorly. Five years after surgery, clinical examination revealed advanced periimplantitis of the left zygomatic implant with severe bone loss that rendered non-surgical treatment unfeasible. Thus, after flap elevation and evaluation of the damage, it was decided to cut off and remove the contaminated part of the implant and leave intact the part which was integrated in the zygomatic bone (Figure 6, 7). Moreover, the fixed prosthetic restoration was modified with the sectioning and removal of the molar area which was supported by the left zygomatic implant in order to remain functional (Figure 8). Five years after surgery, the restoration remained functional and the part of the zygomatic implant which had been left anchored in the zygomatic bone remained asymptomatic.

Case 4

A 52-year-old healthy male patient was treated in our clinic with a fixed restoration supported by two zygomatic implants and five conventional implants in the anterior maxilla. After almost two years, the patient presented with advanced periimplantitis of the left zygomatic implant, extensive bone resorption and oroantral fistula formation. This complication was treated with the complete removal of the zygomatic implant (Figure 9, 10, 11). There were no signs of sinus pathology in a five year follow-up period.

Discussion

In a 15-year period, ten patients (six men and four women, age range: 37-72 years) were treated in our clinic with two zygomatic implants, one on each side, in combination with conventional implants in the anterior maxilla. Complications occurred in four patients, two of the zygomatic implants were completely removed, one was sectioned and partially removed and one was treated with removal of its apical part but it remained functional. In conclusion, 3 out of 20 zygomatic implants were lost, resulting in a survival rate of 85%.

The success rate for zygomatic implants obtained by different authors varies between 82% and 100% (1). From the systematic review of 25 studies with a mean follow-up of 42.2 months (range 0–144 months) and a total of 1541 zygomatic implants, Goiato et al. found a survival rate of 97.86% after

nali su stupanj preživljavanja od 97,86 posto nakon 36 mjeseci (8). Ta vrijednost ostala je sve do zadnje točke kontrole. Chrcanovic i Abreu pregledali su 42 istraživanja, uključujući 1145 i 2402 zygomatična implantata. Od toga je njih 56 proglašeno neuspješnima, te je kumulativni stupanj uspjeha tijekom 12 godina bio 96,7 posto (6).

Ti preliminarni podaci pokazuju da je tehnika zygomatičnih implantata predvidiva, a klinički rezultati zadovoljavajući. U usporedbi s velikim transplantiranjem kosti, još uvijek je manje invazivna i može se koristiti u slučaju kada se koštano transplantiranje iz objektivnog razloga ne može obaviti (4). Ipak, taj je postupak povezan s ozbiljnim komplikacijama koje mogu, iako rijetko, ugroziti plan terapije. Glavna komplikacija zygomatičnog implantata je sinusitis koji se može razviti čak nekoliko godina nakon njihova postavljanja (7). Navedena incidencija sinusitisa nakon postavljanja zygomatičnog implantata kreće se od 0 do 26,6 posto (9, 10). Druge komplikacije uključuju oroantralnu fistulu, orbitalnu penetraciju i ozljedu, privremeni osjetilni deficit i vestibularnu kortikalnu fenestraciju (5, 6, 10, 11). Postoperativno mogu se pojaviti periorbitalni i supkonjunktivalni hematom ili edem, potkožni malarni enfizem, umjereno krvarenje iz nosa od jednog do tri dana, intraoralni problemi s mekim tkivima (upala gingive, dehiscijencija rane) i neuspješno implantiranje (5, 6, 10). Kod pacijenata s naglašenim obraznim konkavitetima bočnih dijelova maksilarnih sinusa korištenje originalne tehnike intrasinusnim putem rezultira pretjeranim nepčanim virenjem glave implantata, što rezultira glomaznim zubnim mostom s palatalne strane te uzrokuje nelagodnu i probleme s oralnom higijenom i govorom (4, 5).

Ograničena intraoperativna vidljivost, složenost anatomskih struktura i zamršenost zygomatičnog zavoja čine taj postupak klinički zahtjevnim, te je potrebno obavijestiti pacijente o mogućim komplikacijama. Čini se da se tijekom postupka postavljanja implantata često nailazi na zygomatično-facijalni živac, pa su moguće njegove ozljede. Isto se odnosi i na infraorbitalni živac. Zbog inervacije pokrovnoga mekog tkiva opisani su i poremećaji osjeta pokrovne kože nakon postavljanja implantata u zygomatičnu kost (6, 11).

U ovom članku opisane su četiri jednostavne komplikacije – slučaj s kožnom fistulom u lijevom zygomatično-orbitalnom području, slučaj neuspjele osteointegracije i dva slučaja perinplantitisa, od kojih je jedan bio zajedno s oroantralnom fistulom. Prema našim spoznajama postoji samo jedan opisani slučaj obostrane kožne fistule nakon postavljanja implantata, a to su učinili Garcia i njegovi suradnici (12). Perinplantitis i stvaranje oroantralne fistule češće su komplikacije. Sustavno pregledavajući literaturu i radove već spomenutih Chrcanovica i Abreua, pronašli smo 48 slučajeva infekcije mekog tkiva oko implantata i 17 slučajeva formiranja oroantralnih fistula, od ukupno opisana 2402 zygomatična implantata (6).

U vezi s našim prvim opisanim slučajem, pretpostavlja se da je nekroza kosti bila uzrokovana ili prevelikim zakretnim momentom ili pregrijavanjem apikalnog dijela osteotoma tijekom postupka bušenja jer velika dubina osteotomije za zygomatični implantat onemogućuje primjerenu irigaciju za hlađenje apikalnog dijela, što može rezultirati aseptičkom

36 months (8). This value remained constant up to the last follow-up period. Chrcanovic and Abreu reviewed 42 studies including 1,145 patients and 2402 zygomatic implants. A total of 56 zygomatic implants were reported as failures and the cumulative success rate (CSR) over a 12-year period was 96.7% (6).

The preliminary data show that the zygomatic implant technique is predictable with satisfactory clinical outcomes. Compared with major bone grafting, it is still a less invasive technique and can be used in cases where bone grafts cannot be harvested for some reason (4). Nevertheless, the procedure is associated with serious complications which, although rare, may jeopardize the treatment plan.

The main complication of zygomatic implants is sinusitis which may develop even several years after their placement (7). The reported incidence of sinusitis after zygomatic implant placement ranges from 0% to 26.6% (9, 10). Other complications include oroantral fistula formation, orbital penetration and injury, temporary sensory nerve deficits and vestibular cortical fenestration (5, 6, 10, 11). Postoperatively, periorbital and subconjunctival hematoma or edema, subcutaneous malar emphysema, moderate nasal bleeding for 1–3 days, intraoral soft tissue problems (gingival inflammation, wound dehiscence) and implant failure may occur (5,6,10). In patients with pronounced buccal concavities on the lateral aspect of the maxillary sinus, the use of the original technique with an intra-sinus path results in excessive palatal emergence of the implant head leading in a bulky dental bridge at the palatal aspect, which causes discomfort and problems with oral hygiene and speech (4, 5).

Limited intraoperative visibility, complexity of anatomical structures and intricacies of zygomatic curve render this procedure a clinically demanding task, hence, patients have to be informed of possible complications. It seems that during the clinical procedure of implant placement zygomatic-facial nerve is encountered frequently; therefore its injury is possible. The same applies to infraorbital nerve. Due to reflection of the soft tissue over it, sensitivity disorders of the malar skin following implant placement in the zygomatic bone have been reported (6, 11).

In the present paper, four rather minor complications have been reported: a case with a cutaneous fistula in the left zygomatic-orbital area, a case with failure of osseointegration and two cases of periimplantitis, one of these combined with oroantral fistula formation. To the best of our knowledge, there is only one case of bilateral cutaneous fistula after zygomatic implants placement reported by Garcia et al. (12). On the other hand, periimplantitis and oroantral fistula formation are more common complications. From the systematic review of Chrcanovic and Abreu which was mentioned before, 48 cases of soft tissue infection around the implants and 17 cases of formation of oroantral fistulas in a total of 2402 zygomatic implants were found (6).

As far as first case is concerned, it is assumed that bone necrosis caused either by overtorquing or overheating in the apical area of the osteotomy during the drilling procedure due to big depth of the osteotomy for a zygomatic implant, can possibly make irrigation inadequate for cooling at its api-

nekrozom zbog pregrijavanja. Na temelju vremena nastanka komplikacije, prevelik zakretni moment (tork) vjerojatnije je objašnjenje za tu komplikaciju. Kod drugog opisanog slučaja mnogo čimbenika može biti odgovorno za neuspjeh osteointegracije zubnih implantata i može se samo nagađati jesu li uzroci neuspjeha povezani s implantatom ili lokalnim čimbenicima. U trećem slučaju zigomatični implantat postavljen je pod velikim kutom zbog anatomije područja. Ta činjenica, u kombinaciji s nepčanim mjestom izlaska glave implantata, uzrokovala je probleme s oralnom higijenom i rezultirala periimplantitisom koji je uzrok neuspjeha. U četvrtom slučaju implantat je izgubljen zbog uznapredovalog periimplantitisa koji je potaknuo stvaranje oroantalne fistule. Terapija je provedena lokalno, te su dva zahvaćena zigomatična implantata cijela uklonjena, a dva razrezana i djelomično uklonjena. Svi pacijenti postoperativno su bili pod antibiotskom terapijom (tablica 1.). Saniranje komplikacija uzrokovanih zigomatičnim implantatima multidisciplinarni je zadatak. Protetičar, koji je odgovoran za rehabilitaciju, mora surađivati s kirurgom radi pronalazjenja rješenja koje će pacijentu eliminirati znakove i simptome, a istodobno neće narušavati funkciju restauracije.

cal part, thus resulting in aseptic heat necrosis. Based on the time the complication occurred, overtorquing is a more reasonable explanation for this complication. Regarding the second case, many factors can be responsible for failure of osseointegration in dental implants, therefore it can only be speculated that implant-related or local factors were the cause of failure. In the third case, the zygomatic implant was placed at a large inclination angle due to the anatomy of the area. This fact in combination with palatal emergence of the implant head caused problems with oral hygiene resulting in periimplantitis which is the cause of failure. The fourth implant was lost because of an advanced periimplantitis which led to oroantonal fistula formation.

The treatment was localized, two of the involved zygomatic implants were completely removed and two were sectioned and partially removed. Moreover, all patients were treated with postoperative antibiotic treatment (Table 1). The management of zygomatic implants complications is a multidisciplinary task. The prosthodontist, who is responsible for the prosthetic restoration, should cooperate with the surgeon in order to find the solution that best meets the patient's needs: preventing the patient from exhibiting any signs and symptoms and, simultaneously, without compromising the function of the restoration.

Tablica 1. Komplikacije zigomatičnih implantata u četirima slučajevima i njihova terapija
Table 1 Complications of zygomatic implants in the 4 cases and their treatment.

	Broj postavljenih implantata • Number of implants placed	Komplikacije • Complication	Terapija • Treatment	Kontrola • Follow up
Slučaj 1 • Case 1	2 zigomatična implantata i 4 klasična implantata • 2 zygomatic and 4 conventional implants	Aseptička nekroza nakon 1 godine • Aseptic necrosis after 1 year	Uklanjanje apikalnog dijela implantata • Removal of the apical part	10 godina • 10 years
Slučaj 2 • Case 2	2 zigomatična implantata i 4 klasična implantata • 2 zygomatic and 4 conventional implants	Neuspjela osteointegracija nakon 4 mjeseca • Failure of osseointegration / 4 months	Popuno uklanjanje zigomatičnog implantata • Complete removal of the zygomatic implant	7 godina • 7 years
Slučaj 3 • Case 3	2 zigomatična implantata i 6 klasičnih implantata • 2 zygomatic and 6 conventional implants	Periimplantitis nakon 4 godine • Periimplantitis after 4 years	Djelomično uklanjanje zigomatičnog implantata • Partial removal of the zygomatic implant	5 godina • 5 years
Slučaj 4 • Case 4	2 zigomatična implantata i 5 klasičnih implantata • 2 zygomatic and 5 conventional implants	Periimplantitis nakon 2 godine • Periimplantitis after 2 years	Popuno uklanjanje zigomatičnog implantata • Complete removal of the zygomatic implant	5 godina • 5 years

Zaključak

Korištenje zigomatičnih implantata u rehabilitaciji bezubih atrofičnih maksila dobra je alteranativa koštanom presađivanju. Među mogućim komplikacijama zigomatičnih implantata, od kojih je sinusitis najčešći, ostale mogu biti teške za rješavanje i katkad rezultirati gubitkom implantata, pa zato primjena usadaka mora biti selektivna. Četiri opisana slučaja s komplikacijama uspješno su izliječena bez ugrožavanja protetičke restauracije.

Sukob interesa

Autori nisu bili u sukobu interesa u vezi s ovim istraživanjem.

Conclusions

The use of zygomatic implant in the rehabilitation of the edentulous atrophic maxilla has been considered a viable alternative to bone grafting. However, complications of zygomatic implants, with sinusitis being the most common, can be difficult to treat or can result in loss of the implant; therefore, it should be selectively applied. The four cases reported here, which developed complications, were treated successfully without compromising the prosthetic restoration.

Conflict of interest

The authors report no conflicts of interest related to this study.

Abstract

Zygomatic implants have been used for rehabilitation of the edentulous atrophic maxilla as an alternative to bone grafting for almost two decades resulting in satisfactory clinical outcomes. However, the patients with edentulous atrophic maxilla treated using this technique may present serious complications that could put the prosthetic restoration at risk. Four cases are reported in this paper, one case with a cutaneous fistula in the left zygomatic-orbital area caused by aseptic necrosis at the apical part of the implant, which was treated with the surgical removal of this part, a second case with loss of the right zygomatic implant due to failure of osseointegration and two cases of periimplantitis that resulted in partial and complete removal of the implant, respectively. All patients who had complications were treated without compromising the restoration which remained functional after appropriately modified treatment.

Received: March 12, 2016

Accepted: May 24, 2016

Address for correspondence

Fotios Bountaniotis
Arch. Makariou kai Makedonias Street,
18 900, Salamis, Greece
Phone: +30 6942892491/ +30
2104652749
Fax: +30 2107461266
fboudaniotis@yahoo.gr

Key words

Zygoma; Dental Implants; Oral Fistula;
Peri-Implantitis; Jaw, Edentulous; Maxilla; Atrophy

References

1. Galan-Gil S, Penarrocha-Diago M, Balaguer-Martinez J, Marti-Bowen E. Rehabilitation of severely resorbed maxillae with zygomatic implants: an update. *Med Oral Patol Oral Cir Bucal*. 2007 May 1;12(3):E216-20.
2. Sudhakar J, Ali SA, Karthikeyan S. Zygomatic Implants - A Review. *JIADS*. 2011;2:24-8.
3. Chrcanovic BR, Pedrosa AR, Custodio ALN. Zygomatic implants: a critical review of the surgical techniques. *Oral Maxillofac Surg*. 2013 Mar;17(1):1-9.
4. Aparicio C, Manresa C, Francisco K, Claros P, Alandez J, Gonzalez-Martin O et al. Zygomatic implants: indications, techniques and outcomes, and the Zygomatic Success Code. *Periodontol* 2000. 2014 Oct;66(1):41-58.
5. Prithviraj DR, Vashisht R, Bhalla HK. From maxilla to zygoma: A review on zygomatic implants. *J Dent Implant*. 2014;4:44-7.
6. Chrcanovic BR, Abreu MHN. Survival and complications of zygomatic implants: a systematic review. *Oral Maxillofac Surg*. 2013 Jun;17(2):81-93.
7. Esposito M, Worthington HV. Interventions for replacing missing teeth: dental implants in zygomatic bone for the rehabilitation of the severely deficient edentulous maxilla. *Cochrane Database Syst Rev*. 2013 Sep 5;(9):CD004151.
8. Goiato MC, Pellizzer EP, Moreno A, Gennari-Filho H, dos Santos DM, Santiago Jr. JF et al. Implants in the zygomatic bone for maxillary prosthetic rehabilitation: a systematic review. *Int J Oral Maxillofac Surg*. 2014 Jun;43(6):748-57.
9. Davo R, Malevez C, Pons O. Immediately loaded zygomatic implants: a 5-year prospective study. *Eur J Oral Implantol*. 2013 Spring;6(1):39-47.
10. Fernandez H, Gomez-Delgado A, Trujillo-Saldarriaga S, Varon-Cardona D, Castro-Nunez J. Zygomatic implants for the management of the severely atrophied maxilla: a retrospective analysis of 244 implants. *J Oral Maxillofac Surg*. 2014 May;72(5):887-91.
11. Ishak, MI; Abdul Kadir, MR. Treatment Options for Severely Atrophic Maxillae. In: Ishak, MI; Abdul Kadir, MR - editors. *Biomechanics in Dentistry: Evaluation of Different Surgical Approaches to Treat Atrophic Maxilla Patients*. New York: Springer; 2013. p. 9-26.
12. Garcia Garcia B, Ruiz Masera JJ, Insert Last Name IF, Zafra Camacho FM: Bilateral Cutaneous Fistula After the Placement of Zygomatic Implants. *Int J Oral Maxillofac Implants*. 2016 Mar-Apr;31(2):e11-4.