

# Treatment of Severe Acquired Haemophilia A with Immunosuppressive Agent: A Case Report of One Patient

Željka Škunca<sup>1</sup> and Ana Planinc Peraica<sup>2</sup>

<sup>1</sup> General Hospital Zadar, Department of Hematology, Zadar, Croatia

<sup>2</sup> Clinical Hospital »Mercur«, Clinic of Internal Medicine, Department of Hematology, Zagreb, Croatia

## ABSTRACT

Acquired haemophilia A (AHA) is a rare hemorrhagic disease caused by an autoantibody against coagulation factor VIII. Nonhaemophiliac patients develop autoantibodies (inhibitors) directed against the factor VIII circulating coagulation protein. Disease is associated with an increased morbidity and mortality. Inhibitors against FVIII induce acute and life-threatening hemorrhagic diathesis because of abnormal blood clotting. FVIII inhibitors demonstrate bleeding disorders and prolonged activated partial thromboplastin time and a normal prothrombin time. AHA should be considered in the differential diagnosis particularly in postpartum women and in the elderly patients with bleeding tendency. Treatment of acute hemorrhage is focused in the control of the acute bleeding episode and the long term suppression of the autoantibody. In congenital hemophilia A with inhibitors, in which using repetitive infusions of high dose FVIII concentrates is effective for inhibitor eradication. This report present one patient treated with immunosuppressive regimens. The most effective first-line treatment for the eradication of factor VIII autoantibodies is the combination of steroids and cyclophosphamide.

**Key words:** Acquired haemophilia A, Factor VIII inhibitors, treatment

## Introduction

Acquired haemophilia A (AHA) is a very rare bleeding disorder, characterized by the spontaneous development of autoantibodies against coagulation factor VIII (FVIII) in non-haemophiliac patients. Patients with no history of bleeding sometimes suddenly present with severe ecchymosis or muscle hematoma. The clinical manifestation is characterised by spontaneous haemorrhagic complications and a severe and often life-threatening bleeding. The incidence is about 1.5 cases million/year, with a high mortality rate, and it can be fatal in 15–20% of the patients.<sup>1</sup> AHA has a biphasic age distribution, exhibiting a small peak from age 20 to 30 years and a large peak at age 60 years and older. The disease is often present in patients older than 60 years of age, and the incidence is the same in both genders.<sup>6</sup> No underlying disorder can be identified in about 50% of the cases. The morbidity and mortality rates may be underestimated due to the high median age at the time of diagnosis.<sup>1–4</sup>

It is well known that approximately 50% of patients with AHA have or have had immune system disorders,

such as autoimmune diseases and lymphoproliferative disorders. This fact, as well as knowledge that autoantibodies play a central role in AHA pathogenesis, indicates that modulation of the immune system or the autoimmune mechanism that generates autoantibodies is involved in AHA.<sup>22</sup> The disease is associated with autoimmune diseases, like systemic lupus erythematosus, rheumatoid arthritis, in pregnancy, drug associated (penicillin, sulphonamides, and chloramphenicol, methyldopa, after interferon- $\alpha$  therapy), with graft-versus-host disease, erythema multiform, drug allergic reactions, asthma, chronic obstructive pulmonary disease, solid tumours (prostate, lung, colon, pancreas, head, neck, breast, melanoma, kidney)<sup>4–8</sup> and hematologic malignancies (chronic lymphocytic leukaemia, non-Hodgkin lymphoma, multiple myeloma, Waldenstrom macroglobulinaemia, monoclonal gammopathies).<sup>1,2,9,10,12–16,22</sup>

Clinical manifestations include severe and massive bleeding which is responsible for their relatively high mortality rate. The most commonly affected organ is the skin,

especially at the site of injection or contusion. Intramuscular and gastrointestinal/intraabdominal bleeding are often involved. AHA is associated with postdelivery or excessive bleeding during surgery. Persistent bleeding after surgical procedures or catheter insertion may be the earliest symptom of AHA. Bleeding can range from mild to life-threatening.<sup>22,23</sup> Bleeding sites with AHA differ from congenital haemophilia A and include deep muscle and retroperitoneal area, gastrointestinal, lung, urogenital and intracranial bleeding.<sup>1,3,4</sup>

The diagnosis of AHA is based on isolated prolongation of activated partial thromboplastin time (APTT) which does not normalize after the addition of normal plasma and identification of a reduced FVIII level with evidence of FVIII inhibitor activity (titrated using the Bethesda assay).<sup>3,7,8,12,22</sup>

Nonhaemophiliac patients develop autoantibodies (inhibitors) directed against the circulating coagulation FVIII.<sup>7,8,10</sup> These inhibitors induce acute and life-threatening hemorrhagic diathesis due to abnormal blood clotting.

FVIII is a cofactor for activated factor IX (FIXa) that forms the Xase (tenase) complex in the presence of Ca<sup>2+</sup> and phospholipids and is essential for the intrinsic coagulation system responsible for blood clotting. FVIII deficiency causes dysfunction of the intrinsic system and reduces thrombin generation, resulting in a bleeding disorder.<sup>22</sup> FVIII is mainly synthesized in the liver as a 2,351 amino acid and 330-kDa single-chain precursor glycoprotein with a functional domain structure. After proteolytic processing, circulating mature FVIII protein is composed of a heterodimer of a heavy and a light chain.<sup>22</sup>

The FVIII inhibitors in AHA are polyclonal autoantibodies, mostly IgG4 autoantibodies and less frequently IgG1 and IgG2 autoantibodies. In congenital haemophilia A inhibitors are polyclonal alloantibodies, bind to the A2, A3 or C2 domains. Anti-C2 antibodies interfere with the binding of FVIII to phospholipids and VWF, A2 and A3 inhibitors block the binding of FVIII to factor X (FX) and FIXa, respectively, and obstruct the formation of the Xase complex.<sup>21,22</sup>

In approximately 50% of AHA patients, especially elderly patients, autoantibody development against factor VIII is idiopathic,<sup>14</sup> indicating that the acquired inhibitors develop via an autoimmune mechanism. The underlying conditions are observed in the remaining 50% of patients.<sup>22</sup>

The treatment involves two aspects – the treatment of acute bleeding episodes and the eradication of antibodies.

Bleeding episodes in AHA are often severe and life threatening and presents with severe anemia. The treatment is focused on the control of the acute bleeding episode with bypassing agents, like recombinant activated FVII (rFVIIa, NovoSeven) and activated prothrombin complex concentrate (aPCC, FEIBA). Activated prothrombin complex concentrates (APCC) containing factors II (prothrombin), VII, IX, and X or recombinant activated factor VII are commonly administered and have shown to be benefi-

cial in treating patients with AHA as well as congenital hemophilia A patients with inhibitors.<sup>13,14,22,23</sup> In patients with low titers of inhibitors, 1-deamino-8-D-arginine vasopressin (DDAVP) or FVIII concentrate can help. Desmopressin stimulates the release of FVIII and VWF from endothelial cells and can provide a transient rise in FVIII:C levels to therapeutic levels may also be effective in AHA patients with low titers of inhibitors or an FVIII:C level >5%.<sup>22</sup> While desmopressin has the advantages of being of low cost and safety, it does not entirely increase FVIII:C level to a therapeutic level and becomes less efficacious with repetitive administration.<sup>22,23</sup>

The first-line treatment includes the recombinant activated FVII (rFVIIa) and aPCC until haemostasis is achieved.<sup>3,9,10</sup> The European Acquired Haemophilia Registry (EACH2) shows that the treatment rFVIIa consists of a bolus injection range 84.7–102.9 µg/Kg every 2–6 hours during 24–72 h.<sup>14,16,17</sup> The dosage of this agent is based largely on experience in the treatment of congenital haemophilia A and inhibitors. No data on the duration of the treatment are available. Depending on the site, type and severity of the bleeding, the treatment lasting from 24–72 h may be appropriate. rFVIIa is generally well tolerated, severe thrombotic complications may occur, such as myocardial infarction, arterial and venous thrombosis, pulmonary embolism and stroke. Further treatment after haemostasis is necessary to prevent re-bleeding in some cases.<sup>4,13,17</sup>

AHA patients have been treated with FVIII and cyclophosphamide for approximately 30 years.<sup>5,11,15</sup> The usual treatment involves administration of prednisolone at a dose of 1mg/kg combined with cyclophosphamide 50–100 mg/day orally.<sup>15</sup> Various immunosuppressive regimens, reduced the inhibitor titers to undetectable levels in 68% of the patients with low-titer inhibitors (less than 5BU/mL).<sup>5,7,19,22</sup> In high titer patients this may require several months. EACH2 results of the study suggest that steroids alone give up to 48% CR. Steroids combined with cyclophosphamide resulted in more patients achieving a stable CR (70%).<sup>8,20,21,23</sup> Azathioprine or cyclosporine have also been tested, with good responses.<sup>15</sup> There is no evidence that one immunosuppressive therapy is clinically superior to all others in treating AHA or that a certain therapy should be chosen depending on inhibitor titer or the hemorrhagic status.<sup>22</sup> These treatments are associated with serious side effects, especially in older patients.

High doses of immunoglobulin have been used with success, but the effect was incomplete and needed combination with other medications. Drugs needed to inhibit the production of FVIII inhibitors have proved to be more effective and safe.<sup>6,22</sup>

The anti CD20 monoclonal antibody, rituximab, has shown very good results given either as monotherapy or in combination with immunosuppressive regimens in patients who do not respond to standard immunosuppressive therapy.<sup>8,9,10,16</sup> Rituximab, an anti-CD20 monoclonal antibody against CD20, depletes CD20+ cells by antibody-dependent cellular toxicity, including apoptosis and com-

plement mediated lysis. Rituximab has been shown to be effective in autoantibody-mediated disease, with little toxicity. The autoantibodies rapidly resolved in patients, but the alloantibody that developed after the recombinant FVIII treatment persisted for months. Rituximab has been used without or with other immunosuppressive agents.<sup>2,9,11,13,15,18,19,22</sup>

The patient's age is an important risk factor. 50% of the patients with AHA were older than 65 years. Death is mainly caused by infection, a common complication of long-term immunosuppression or it is the result of extended bleeding. Elderly age and comorbidities of patients increase the risk of tromboembolism. Rapid elimination of the inhibitor might prevent this complication.<sup>2,4,11,17</sup> The meta analysis showed an overall mortality rate of up to 16% for various treatment regimens, and patients in whom the inhibitor could not be eliminated had a mortality rate of 42%. The complications were associated with infections related to chemotherapy-induced neutropenia, particularly in elderly patients.<sup>5,15</sup> Most patients die within 1–2 years of diagnosis, from comorbid conditions rather than bleeding, which is a rare cause of death in this condition.<sup>5</sup>

We are going to report one case with AHA with haematuria and intramuscular hematoma, successfully treated with hFVIIa, cyclophosphamide and corticosteroids.

The aim of this study is to describe our experience in treating a patient with AHA using European Acquired Haemophilia Registry (EACH2). The bleeding was controlled during treatment with rFVIIa, and no subsequent bleeding episodes occurred. The inhibitor levels with immunosuppressive agent decreased to undetectable levels within a median of 6 weeks. During the long term follow-up the patient hasn't had episodes of reduced FVIII activity and bleeding.

### Case Report

A 77 year-old man presented with a rapid early haematuria and muscle hematomas of the lower limbs. Cystoscopy analysis did not give the cause of bleeding, and after cystoscopy haematuria persisted. The patient had a history of chronic obstructive pulmonary disease (COPD), and had a history of arterial hypertension and atrial fibrillation. Initial laboratory evaluations showed severe anaemia, with a haemoglobin level of 6.8 g/dL, a hematocrit of 19.6%, and a normal platelet count. His prothrombin time (PT) and international normalized ratio (INR) were within normal reference ranges. His prolonged APTT was 2.16 (normal values <1.2), the FVIII level was 15%, the FVIII inhibitor level was 98 Bethesda Units (BU)/mL, and FIX, FXI, XII were within normal ranges measured at the local laboratory. The routine renal and liver function tests were all within normal limits. The rheumatoid factor, C-reactive protein and complement factor C<sub>3</sub> and C<sub>4</sub> were within normal ranges. The antinuclear antibody and the anti-DNA antibody were negative. The Lupus anticoagulant test was negative. The serum levels of all tumour markers were within normal limits. The

total body computed tomography (CT) scan of the thorax, neck and abdomen were normal, without pathologic formations.

The patient was initially treated with 2 units of packed red blood cells and 6 units of fresh frozen plasma without response. The patient was treated immediately with intravenous prednisone (1mg/Kg/day) and rFVIIa (NovoSeven, NovoNordisk) at 90 µg/Kg every 4 hours for the first four days, when the bleeding stopped. Cyclophosphamide was administered orally (100mg/day). After one week the patient was stable and had no further bleeding episodes. His APTT, and FVIII inhibitor normalized at week 6. These parameters were evaluated monthly in the first twelve months, then every 3 months. Cyclophosphamide was stopped 6 weeks after the eradication of the FVIII inhibitor. He had no subsequent bleeding events the following year and he was in complete remission. The patient is very well with good response. The patient's characteristics are summarized in Table 1. Fig 1. shows APTT and circulating FVIII inhibitors in acute phase bleeding and Fig. 2. shows APTT and FVIII concentrate.

**TABLE 1**  
PATIENT DATA

Sex	M
Age	79
Medical history	COPD Hypertension Atrial Fibrillation Adenoma prostate Diathesis uric
Bleeding site	Haematuria, muscle hematoma
Initial haemoglobin	6.8
Initial haematocrit	19.6
APTT	81
FVIII: concentrate	1.68
Bethesda units	9.8
Treatment	rFVIIa Prednisone Cyclophosphamide
Follow –up	No
Relapse	No
Alive	Yes

POPD= chronic obstructive pulmonary disease, APTT= activated partial tromboplastin time

### Discussion

The acquired haemophilia A is a potentially life threatening bleeding disorder in patients without a previous personal or family history of bleeding caused by the immune-mediated development of acquired FVIII autoantibodies.<sup>8,15–19,22,23</sup>

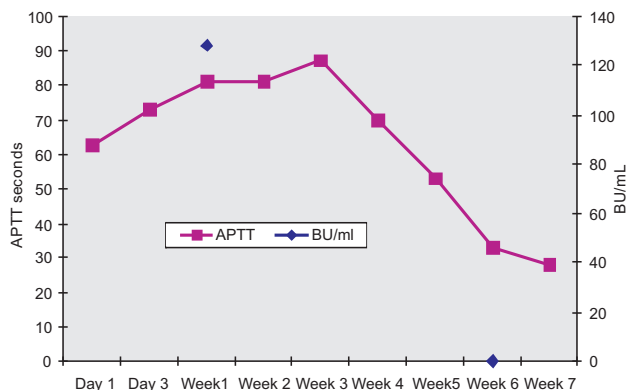


Fig. 1. This figure shows APTT (Normal value APTT: 26–36 s, FVIII 70–150 %), and FVIII inhibitors in Bethesda units (BU/ml) in acute phase bleeding and return to normal levels after 6 weeks of follow-up.

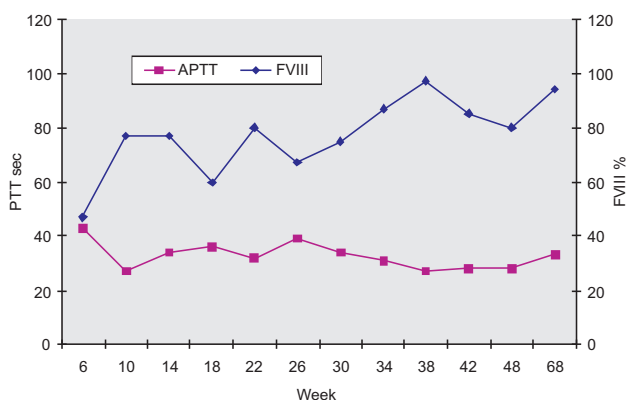


Fig. 2. This figure shows APTT and FVIII concentrate, returning to normal levels after 6 weeks. (Normal value APTT: 26–36 s, FVIII 70–150 %).

Our patient was 77 years old. The median age of patients at diagnosis of AHA was 78 and 74 years in the two largest cohort studies, with more than 80% of patients older than 65 years.<sup>17</sup> The patient had a severe bleeding tendency with high inhibitor titters and critical bleeding at presentation. The underlying disease known to be associated with FVIII inhibitor was identified in this patient.<sup>14,17</sup>

In the acute phase, it is necessary to stop the bleeding. The treatment of acute bleeding episodes consists of infusion preparations with FVIII bypassing activity, and of the first line haemostatic treatment to reduce the risk of thrombotic complications. The treatment of bleeding with FVIII concentrates is usually taken into consideration

only for patients with low-titre inhibitor levels (<5BU/ml). The European Acquired Haemophilia Registry (EACH2) shows that the majority of patients have high-titre inhibitors, such as rhFVIIa or APCC. prothrombin complex concentrate. Plasmapheresis for a rapid reduction of the inhibitor would probably be unsafe in hemodynamically unstable patients.<sup>15,16,17,18</sup>

Our patient had high FVIII inhibitor titters of 98 BU/ml. The bleeding was controlled with rFVIIa (90µg/kg every 4 hours) during 4 days, and no subsequent bleeding episodes occurred. The inhibitor levels decreased to undetectable levels within a median of 6 weeks. In our patient, cancer or autoimmune disease was excluded. Immunosuppression with cyclophosphamide and prednisone until remission was effective, and it was administered for long-term reduction of the inhibitor of the titer.<sup>3,9,14</sup> During the long term follow-up of the patient, he has not had a single episode of reduced FVIII activity and bleeding.

Our treatment approach has already been successfully implemented by other institutions. Our finding shows that treatment with rhFVIIa and immunosuppression agents, such as corticosteroids and cyclophosphamide, is very safe and effective in the treatment of acute haemorrhage and in the cure for patients with high titters FVIII inhibitors. Collins P. et al.(2013) in a large study indicates an equal number of patients receiving prednisone and prednisone and cyclophosphamide and have a median age that matched our patient with very good results. Other authors have similar results.<sup>8,17,19,21,23</sup>

Rituximab (Mabthera) was a very effective treatment as a single agent, and it was for patients with low inhibitor titters. Rituximab, a monoclonal antibody that targets the CD20 antigen, is a potential candidate to substitute the current immunosuppression. Rituximab alone may not be enough to treat patients with high inhibitor levels. Stasi et al. (2004.) found that rituximab and cyclophosphamide were required to achieve a full and durable response in those patients with inhibitor levels higher than 100 BU/mL. A combination of rituximab and steroids was no more effective than rituximab alone.<sup>8</sup>

In conclusion, acquired haemophilia A is a rare disorder. Any acute or recent onset of bleeding symptoms in a patient with no previous history of bleeding, especially in elderly or post-partum patients, and an unexplained isolated prolonged APTT suggest the diagnosis of AHA, and a prompt further investigation is indicated.<sup>3,4,18</sup>

The pathogenic antibody involved in AHA should be identified and quantified. The pathogenic antibody can be removed from the patient's plasma with immunosuppressive therapy, and that is the crucial way of effective treatment.<sup>3,22,23</sup>

## REFERENCES

1. ALVARADO Y, YAO X, JUMPER C, HARDWICKE F, D'UNHANA N, COBOS E, Clin Appl Thromb Hemost, 13 (2007) 443. DOI: 10.1177/1076029607303777. — 2. FRANCHINI M, LIPPI G, Crit Rev Oncol Hematol, 63 (2007) 47. DOI: <http://dx.doi.org/10.1016/j.critrevonc.2006.11.004>. — 3. TUFANO A, COPPOLA A, GUIDA A, CIMINO E, DE GREGORIO AM, CERBONE AM, DI MINNO G, Curr Gerontol Geriatr Res (2010). DOI: 10.1155/2010/927503. — 4. SHETTY S, BHAVE M, GHOSH K, Autoimmun Rev, 10 (2011) 311. DOI: 10.1016/j.autrev.2010.11.005. — 5. ZEITLER H, ULRICH-MERZENICH G, HESS L, KONSEK E, UNKRIG C, WALGER P, VETTER H, BRACKMANN HH, Blood, 105 (2005) 2287. DOI: <http://dx.doi.org/10.1182/blood-2004-05-1811>. — 6. WY AU, LEE V, KHO B, LING AS, CHAND, CHAN EY, et al., Hong Kong Med J, 17 (2011) 189. — 7. KAIN S, COPELAND TS, LEAHY MF, Br J Haematol, 119 (2002) 578. DOI: 10.1046/j.1365-2141.2002.03835\_5.x. — 8. COLLINS P, BAUDO F, KNOEHL P, LÉVESQUE H, NEMES L, PELLEGRINI F, et al., Blood, 120 (2012) 47. DOI: 10.1182/blood-2012-02-409185. — 9. O'SHAUGHNESSY D, MAKRIS M, LILLICRAP D, eds. Practical hemostasis and thrombosis: MACLEAN RM, MAKRIS M. Hemophilia A and B. (Wiley-Blackwell Publishing, Oxford, 2008). — 10. BAUDO F, COLLINS P, HUTH-KÜHNE A, LÉVESQUE H, MARCO P, NEMES L, PELLEGRINI F, TENGBORN L, KNOEHL P, EACH2 REGISTRY CONTRIBUTORS, Blood, 120 (2012) 39. DOI: 10.1182/blood-2012-02-408930. — 11. STASI R, BRUNETTI M, STIPA E, AMADORI S, Blood, 103 (2004) 4424. DOI: <http://dx.doi.org/10.1182/blood-2003-11-4075>. — 12. DELGADO J, JIMENEZ-YUSTE V, HERNANDEZ-NAVARRO F, VILLAR A, Br J Haematol, 121 (2003) 21. DOI: 10.1046/j.1365-2141.2003.04162.x. — 13. FRANCHINI M, Hematology, 11 (2006) 119. DOI: <http://dx.doi.org/10.1080/10245330600574185>. — 14. COLLINS P, BAUDO F, HUTH-KÜHNE A, INGERSLEV J, KESSLER CM, CASTELLANO MME, et al., BMC Res Notes, 3 (2010) 161. DOI: 10.1186/1756-0500-3-161. — 15. GIANGRANDE P, World Federation of Hemophilia, 38 (2012) 1. — 16. HUTH-KÜHNE A, BAUDO F, COLLINS P, INGERSLEV J, KESSLER CM, LÉVESQUE H, et al., Haematologica, 94 (2009) 566. DOI: 10.3324/haematol.2008.001743. — 17. Di CAPUA M, COPPOLA A, NARDO A, CIMINO E, Di MINNO MN, TUFANO A, et al., Blood Transfus, 19 (2014) 1. DOI: 10.2450/2014.0047-14. — 18. FEDERICI AB, BUDDE U, TIEDE A, Management of patients with acquired Von Willebrand syndrome and acquired hemophilia. In: Hematology Education (The education program for the annual congress of the European Hematology Association, Italy, 2014). — 19. DROBIECKI A, PASIARSKI M, HUS I, SOKOŁOWSKA B, WAŃTEK M, Blood Coagul Fibrinolysis, 24 (2013) 874. DOI: 10.1097/MBC.0b013e3283283646635. — 20. ESCOBAR MA, Cancer, 118 (2012) 312. DOI: 10.1002/encr.26304. — 21. ABT NB, STREIFF MB, GOCKE CB, KICKLER TS, LANZKRON SM, Case Rep Hematol, (2014) 1. DOI: 10.1155/2014/484563. — 22. SAKURAI Y, TAKEDA T, J Immunol Res, (2014) 1. DOI: 10.1155/2014/320674. — 23. PETER W COLLINS PW, CHALMERS E, HART D, JENNINGS I, LIESNER R, RANGARAJAN S, et al., British Journal of Haematology, 162 (2013) 758. DOI: 10.1111/bjh.12463.

Ž. Škunca

General Hospital Zadar, Department of Hematology, Bože Peričića 5, 23 000 Zadar, Croatia  
e-mail: [zeljka.skunca@zd.t-com.hr](mailto:zeljka.skunca@zd.t-com.hr)

## LIJEČENJE TEŠKE STEČENE HEMOFILIJE A S IMUNOSUPRESIVNIM LIJEKOVIMA: PRIKAZ SLUČAJA KOD JEDNOG BOLESNIKA

### SAŽETAK

Stečena hemofilija A je autoimuno oboljenje uzrokovano neobičnim poremećajem faktora zgrušavanja uzrokovano autoantitijelima na FVIII kod bolesnika koji nemaju hemofiliju. Dolazi do pojave antitijela (inhibitora) protiv FVIII. Antitijela protiv faktora VIII mogu izazvati akutna i po život opasna krvarenja zbog poremećenih faktora zgrušavanja krvi. Inhibitori FVIII mogu produžiti parcijalno tromboplastinsko vrijeme i normalno protrombinski vrijeme. Na AHA treba misliti u diferencijalnoj dijagnostici osobito nakon poroda kod žena i u starijih bolesnika kod kojih postoji sklonost ka krvarenju. Liječenje akutnog krvarenja je usmjereno na kontrolu akutne epizode krvarenja i suzbijanje autoantitijela. Kod hemofilije A s inhibitorima, pomaže davanje faktora VIII u visokim dozama. Mnoge imunosupresivne kombinacije su opisane. Kortikosteroidi u kombinaciji s ciklofosamidom daju rezultate s značajno postignutom kompletnom remisijom, koja se definira nepostojanjem inhibitora i prisutnim FVIII iznad 70 IU/dL. Takve terapijske opcije su povezane s ozbiljnim nuspojavama, posebno kod starijih bolesnika. Ovaj rad opisuje jednog bolesnika liječenog imunosupresivnom terapijom.