

HISTOLOGICAL AND BIOCHEMICAL  
ALTERATIONS IN RAT'S LIVER AND KIDNEY  
INDUCED BY THORIUM NITRATE

JAI RAJ BEHARI, S. K. TANDON, A. K. MATHUR  
and SATYA V. CHANDRA

*Industrial Toxicology Research Centre, Lucknow, India*

*(Received for publication May 14, 1975)*

The histopathological and biochemical alterations in rat's liver and kidney induced by daily intraperitoneal administration of thorium nitrate were studied. The activity of alkaline phosphatase and adenosine triphosphatase was found to be inhibited at various intervals and the pathomorphological changes were found to be related to the duration of treatment. The results indicate that the effect of thorium is cumulative and that the biochemical alterations occur prior to histological changes.

Thorium is an important element with wide industrial applications (1, 2) besides its growing use as an atomic reactor fuel (1, 3). During the extraction of thorium, the manufacture of its compounds and their useful industrial applications, a number of workers are exposed to their toxic effects. The salts of this metal are associated with chemical as well as radiological hazards (1). Sufficient evidence exists on the toxicity of thorotrast (thorium dioxide) to human beings. A colloidal solution of this material invariably used for angiography (4) has been shown to produce hepatic cirrhosis, tumours, neoplasms, fibrosis and atrophy of the liver, spleen and lymph nodes as its late manifestations (5-7). The late clinical picture of thorotrastosis is characterized by anaemia and infections, haemorrhages and carcinoma of vital organs ultimately leading to death (8, 9). Since very little is known about the morphological or biochemical alterations due to thorium or its soluble salts especially at the early stages of intoxication, it was considered worthwhile investigating these in some of the vital organs of the experimental animals and interrelating them, if possible. The study was undertaken with a view to understand the mechanism of action of tho-

rium on tissues. The liver and kidney were chosen for the study as the former is mainly responsible for the metabolism of the intoxicants and the latter for their excretion.

### MATERIALS AND METHODS

Forty-two male albino rats of I. T. R. C. colony weighing  $150 \pm 5$  gm were given 10 mg Th/kg as  $\text{Th}(\text{NO}_3)_4 \cdot 4\text{H}_2\text{O}$  dissolved in 1 ml of normal saline, intraperitoneally daily for 120 days. The pH of the solution was raised from 2.5 to 5.5 with sodium acetate before making up the final volume. A separate set of 18 control animals received an equal volume of normal saline having the same pH. The dose used in the experiment is one fifth of the tolerated intraperitoneal dose for rats. The animals were weighed every week and the dose adjusted accordingly. They were maintained on standard diet and received water ad libitum. Seven animals from the experimental group and three from the control group were sacrificed by decapitation 48 hours after the last injection, at specified intervals. The rest was allowed to excrete most of the unbound metal from the system. The liver and kidney were removed and divided for histopathological and biochemical studies.

A portion of tissues was fixed in Lillies neutral buffer formalin for at least a week. After routine processing, the tissues were embedded in paraffin and  $5 \mu$  sections were cut and stained with haematoxylin - eosin for histopathological examination.

For biochemical estimations, a part of the freshly separated tissues was washed free of adhering material and homogenised (10%, W/V) in ice cold isotonic sucrose (0.25 M) by Potter Elvehjem homogenizer. The activity of alkaline phosphatase was determined by the method of *Wooton* (10) and that of adenosine triphosphatase as described by *Seth* and *Tangri* (11). The total protein content of tissue homogenates was determined in trichloroacetic acid precipitate employing the procedure of *Lowry* et al. (12). The »T« test described by *Fisher* (13) was employed to calculate statistical significance between control and experimental values. P values below 0.05 were taken as significant.

Adenosine triphosphate (ATP) disodium salt was obtained from V. P. Chest Institute, Delhi (India) and all other chemicals used were either British Drug House or E. Merck (Analytical/Guaranteed Reagent) grade. Klett Summersons' photoelectric colorimeter and Weswox microtome were used.

### RESULTS

Among thorium injected rats the mortality was low up to 60 days. Then it started increasing so that the number of animals in this group was not sufficient to get significant results of biochemical estimations beyond 60 days. Therefore in the over sixty days period only histopathological investigations were carried out. It was not possible to

establish the cause of death by autopsy. The remaining animals showed an appreciable loss of hair after 70 days, appeared sick and had yellowish fur.

#### *Gross examination*

The abdomen of the experimental animals when exposed showed white granular depositions probably due to the formation of poorly soluble thorium complexes. Most of the organs were found coalescent. The liver and kidney were markedly congested.

#### *Microscopic examination*

The histological pattern of the liver of the control animals and of those treated with thorium nitrate for 15 days presented normal architecture. The liver sections of rats after 30 days of treatment showed marked congestion of the central veins and adjacent sinusoids. After 60 days, the liver sections revealed marked congestion and dilatation of sinusoids around central veins. The capsule was slightly thickened, areas of focal necrosis and degeneration of subcapsular hepatocytes were observed. Small necrotic areas, mainly periportal, were seen throughout the section. These comprised degenerated hepatocytes and mononuclear cells. Increased cellularity around portal tracts and bile duct prolife-

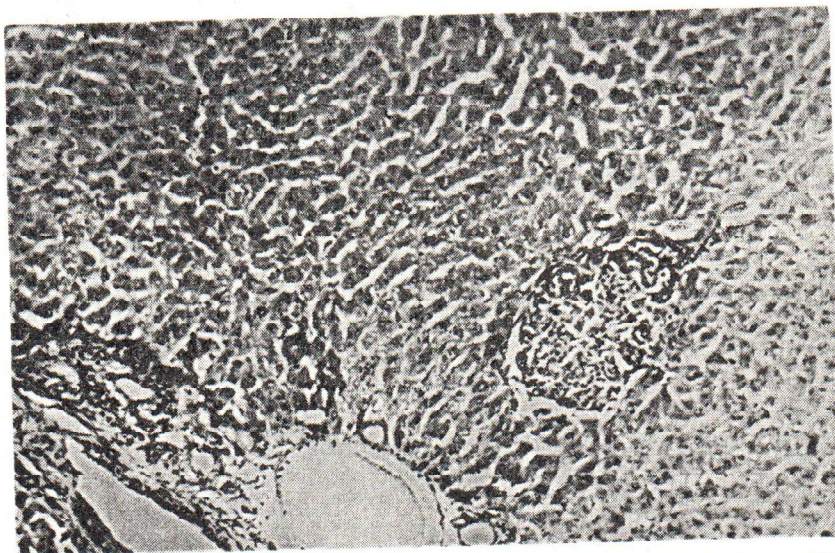


Fig. 1. Section of the liver of a rat treated with  $\text{Th}(\text{NO}_3)_4 \cdot 4\text{H}_2\text{O}$  (10 mg Th/kg) daily for 60 days showing periportal necrosis, increased cellularity around portal tract and bile duct proliferation. Hematoxylin-eosin  $\times 195$

ration were also seen at this time of the experiment (Fig. 1). The extent of damage after 90 days increased further which was evident from fairly large necrotic and marked cellularity around portal tracts. Kupffer cell hyperplasia was also seen. After 120 days of the experiment, the picture of the liver section was almost similar as seen at 90 days except that fatty change was observed in hepatocytes around necrotic areas (Fig. 2).

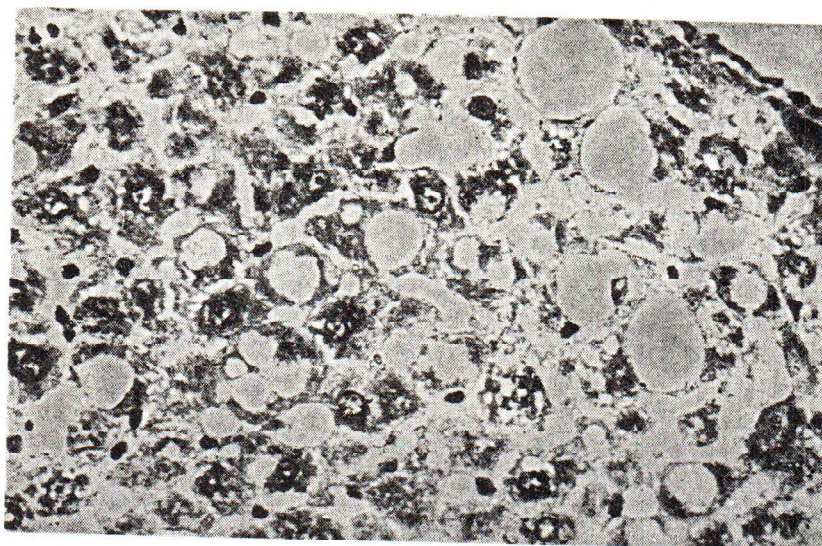


Fig. 2. Section of the liver of a rat treated with  $\text{Th}(\text{NO}_3)_4 \cdot 4\text{H}_2\text{O}$  (10 mg Th/kg) daily for 90 days showing fatty change in hepatocytes. Hematoxylin — eosin  $\times 780$

The histology of the kidney in control and experimental animals at 15 days was found to be normal. The kidney sections of rats treated with thorium nitrate for 30 days showed a marked congestion. At 60 days, the congestion was still present and there was degeneration and necrosis of the tubular epithelium of proximal convoluted tubules in the focal areas (Fig. 3). At 90 days, the degeneration of the tubular epithelium was more pronounced and some of the tubules were completely necrotic. After 120 days, the cytoplasm of the epithelial cells of tubules was markedly vacuolated and the degeneration of the cells was even more obvious (Fig. 4). PAS staining of the section revealed the thickening of the Bowman's capsule and the basement membrane of the capillaries of the glomerular tuft.

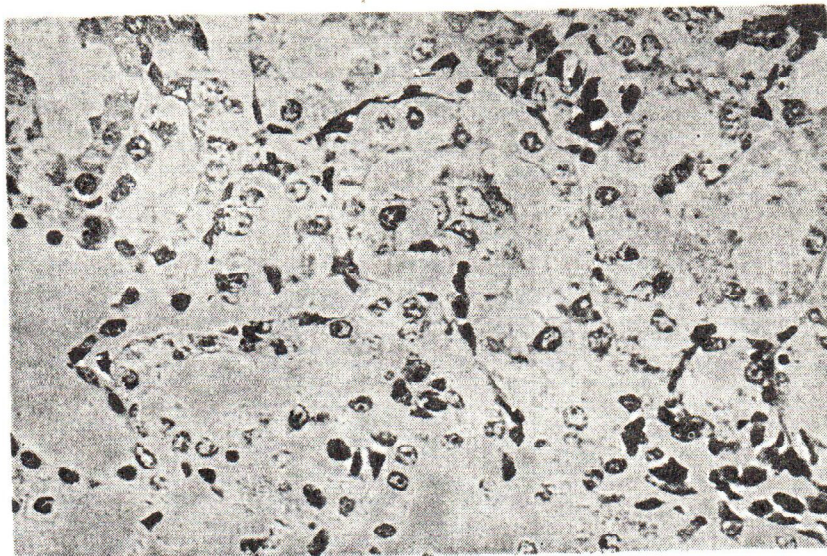


Fig. 3. Section of the kidney of a rat treated with  $\text{Th}(\text{NO}_3)_4 \cdot 4\text{H}_2\text{O}$  (10 mg Th/kg) daily for 60 days showing necrosis of tubular epithelium. Hematoxylin — eosin  $\times 780$

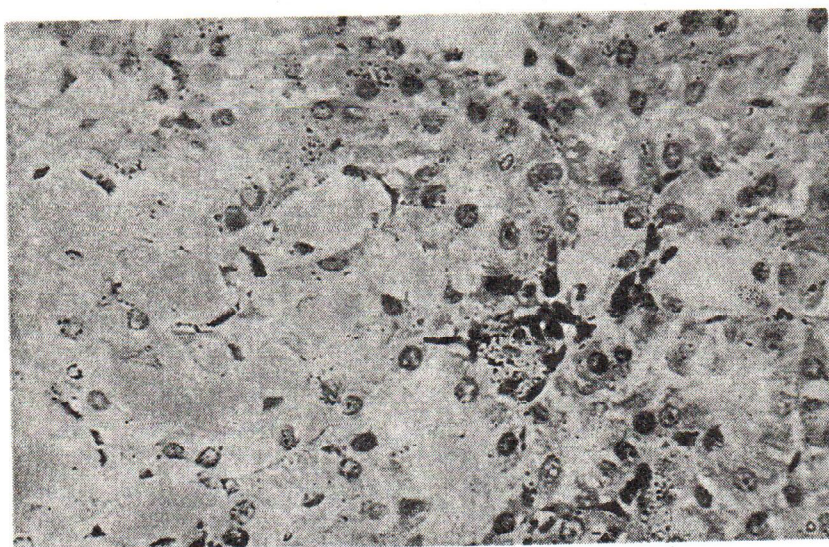


Fig. 4. Section of the kidney of a rat treated with  $\text{Th}(\text{NO}_3)_4 \cdot 4\text{H}_2\text{O}$  (10 mg Th/kg) daily for 120 days, showing markedly vacuolated and necrotic epithelium of the tubules. Hematoxylin — eosin  $\times 780$ .

The enzymatic alterations observed up to 60 days of daily intraperitoneal administration of thorium nitrate are summarized in Table 1. The activity of alkaline phosphatase and adenosine triphosphatase was found to be significantly inhibited both in the liver and kidney at various intervals.

Table 1  
Enzyme activities in the liver and kidney of rats after daily intraperitoneal administration of 10 mg Th/kg as  $Th(NO_3)_4 \cdot 4H_2O$

Enzyme	Organ	Control	15 days	30 days	45 days	60 days
Alkaline phosphatase (in moles of phenol liberated/mg protein/ minute)	Liver	5.98±0.18	4.81±0.36 <sup>b</sup>	5.20±0.62	4.78±0.26 <sup>a</sup>	5.13±0.36 <sup>c</sup>
	Kidney	326.58±1.94	243.52±4.46 <sup>a</sup>	275.49±2.35 <sup>a</sup>	269.6 ±4.12 <sup>a</sup>	230.02±2.21 <sup>a</sup>
Adenosine triphosphatase (in moles of Pi liberated/mg protein/ minute)	Liver	65.85±1.43	61.15±0.85	53.70±0.80 <sup>a</sup>	62.49±0.31	50.99±1.54 <sup>a</sup>
	Kidney	110.64±0.82	83.68±1.01 <sup>a</sup>	88.22±2.15 <sup>a</sup>	93.18±3.36 <sup>a</sup>	130.34±4.34 <sup>a</sup>

Values represent the mean ± standard error of 8 rats in control group and 5 in experimental group.

<sup>a</sup>P < 0.001; <sup>b</sup>P < 0.01; <sup>c</sup>P < 0.02.

## DISCUSSION

The interest in the problem of the toxicology of thorium and its compounds arises from the dual nature of their biological effects on entry into the body. The early effects are mainly due to their chemical toxicity and the late ones are the result of their radiotoxic properties. The late effects of thorium predominantly as thorium dioxide, a chemically inert substance in human beings as well as in experimental animals, are well documented as being mainly due to radioactivity of the metal (14). The administration of thorium nitrate to our experimental animals resulted in the inhibition of adenosine triphosphatase and alkaline phosphatase in the liver and kidney of rats as early as 15 days, when no histological changes could be detected under light microscope. This seems reasonable in view of the biochemical alterations occurring prior to histopathological changes (15, 16). Thereafter, these enzymatic alterations were followed by marked degenerative changes in hepatic and renal parenchyma. The toxic effects of thorium thus appear to be cumulative rather than immediate. The pathological changes characterized by congestion and necrosis of the two organs, observed after 30 days of daily administration of the metal, which developed progressively into more pronounced lesions in the two organs with the period of treatment support the above conclusion. The present study, therefore, clearly indicates that the early chemical toxicity of thorium nitrate induces enzymatic alterations in the cell and significant histological damage in affected organs at later stages. However, there appears to be no definite relationship between the degree of biochemical alterations and the extent of tissue injury.

## ACKNOWLEDGEMENT

Authors are indebted to the Director of the Industrial Toxicology Research Centre, Lucknow, India, for encouragement and to Messrs Surendra Singh and I. Ansari for technical assistance. Photomicrography by Mr. Musleh Ahmed is gratefully acknowledged.

## References

1. Albert, R. E.: Thorium: Its Industrial Hygiene Aspects, Academic press, London, 1966.
2. Durham, T. E.: Chem. Abst., 81 (1974) 286.
3. Zurzoli, G. B.: Nucl. Technol., 20 (1973) 109.
4. Betz, H., Matlar-Vehar, H.: Biol. Abst., 52 (1971) 69372.
5. Wegener, K., Zahnert, R.: Arch. Abt. A. Pathol. Anat., 351 (1970) 316.
6. Boyd, J. T., Longlands, A. O., Maccabe, J. J.: Brit. Med. J., 2 (1968) 517.
7. Saragoca, A., Maria, H. T., Borros, F. B., Horta, J. D.: Am. J. Gastroenterol., 57 (1972) 301.
8. Bastrup, M. P., Bjorn, N. J.: Acta Med. Scand., 189 (1971) 355.

9. *Bastrup, M. P., Kai, N., Mose, C. B.*: Acta Med. Scand., 189 (1971) 349.
10. *Wooton, I. D. P.*: Microanalysis in Medical Biochemistry, 4th Ed. J. & A. Churchill Ltd., London, 1964, p. 107.
11. *Seth, P. K., Tangri, K. K.*: J. Pharm. Pharmacol., 18 (1966) 831.
12. *Lowry, O. D., Rosebrough, N. J., Farr, A. L., Randall, R. J.*: J. Biol. Chem., 193 (1951) 265.
13. *Fisher, R. A.*: Statistical Methods for Research Workers, Ed. Oliver and Boyd., 11th Ed., London, 1950.
14. *Kurlyandskaya, E. B.*: The toxicology of radioactive substances, Ed. by Letavet & Kurlandskaya, Vol. 4, Pergamon Press Ltd., 1970, p. 1.
15. *Singh, J., Husain, R., Tandon, S. K., Seth, P. K., Chandra, S. V.*: Environ. Physiol. Biochem., 4 (1974) 16.
16. *Johnson, A. D., Gomes, W. R., Vandemark, N. L.*: The testis, Vol. 3, Academic Press, New York, London, 1970, p. 418.

### Sažetak

#### HISTOLOŠKE I BIOKEMIJSKE PROMJENE U JETRI I BUBREZIMA ŠTAKORA IZAZVANE TORIJEVIM NITRATOM

Toksikološka svojstva torija slabo su istražena, iako torij postaje sve važniji element u industriji. Njegova se upotreba širi, pa se upotrebljava i u medicinskoj dijagnostici (torijev dioksid — thorostrast).

U ovom su radu istraživani učinci torijevih soli na bubrege i jetru štakora kojima je torijev nitrat injiciran intraperitonealno u dozi od 10 mg/kg svakog dana kroz 120 dana. Kontrolnim je životinjama injicirana fiziološka otopina na jednak način.

U prvih 60 dana pokusa samo je nekoliko štakora uginulo, a nakon toga vremena smrtnost se povećala. Tek nakon 30 dana uočene su histološke promjene jetre u obliku kongestije vena i sinusoida i taj je nalaz postajao sve izrazitiji tijekom vremena. U kasnijoj su fazi nađena degenerativna i nekrotična žarišta. Slične su promjene nađene i u bubrežnom parenhimu. Ovim je promjenama prethodilo smanjenje aktivnosti alkalne fosfataze i adenozin trifosfataze u jetri i u još većoj mjeri u bubregu.

*Istraživački centar za industrijsku toksikologiju, Lucknow, Indija*

*Primljeno 14. V 1975.*