

EFFECT OF MANGANESE ON THE MORPHOLOGY OF THE RABBIT ADRENAL CORTEX

SATYA V. CHANDRA and ZAKA IMAM

Industrial Toxicology Research Centre, Lucknow, India

(Received for publication June 24, 1974)

Manganese chloride (2.5 mg/kg) was administered intravenously daily to rabbits and morphological alterations in the adrenal cortex were studied at different time intervals up to 90 days. An increase in the cholesterol content, as demonstrated histochemically, and marked degenerative changes in the zona glomerulosa and zona fasciculata were observed after a period of 60 days. The damaging effect of manganese chloride on the adrenal cortex was even more marked at 90 days. It is indicated that morphological alterations in the adrenal cortex produced by the administration of manganese chloride may have marked effect on the functioning of this gland.

There appears to be only one report devoted to morphological alterations produced by manganese chloride in the adrenal cortex of guinea pigs (1). It describes the changes occurring in the adrenal cortex at 20 days after the metal administration. The present report deals with detailed morphological alterations seen in the adrenal cortex of rabbits at various time intervals caused by daily administration of manganese chloride for 90 days.

MATERIALS AND METHODS

Adult male rabbits from the Industrial Toxicology Research Centre colony maintained on a standard pellet diet* were used in these studies. Body weight ranged from 1.5 to 2 kg. Animals were housed individually in an air conditioned animal house and were given tap water ad libitum. Twelve rabbits (group I) were administered intravenously manganese chloride ($\text{MnCl}_2 \cdot 4\text{H}_2\text{O}$, 2.5 mg/kg) dissolved in 0.5 ml of physiological saline daily for 90 days. Six animals (group II) were given by the

* (Hind Lever Laboratory Animal Feeds, India. Pellet composition confirming to the nutritional standards recommended by the U. S. National Research Council's Publication No. 990 »Nutritional Requirements of Laboratory Animals«)

same route 0.5 ml physiological saline daily for the same period and served as controls. Four rabbits from group I and two animals from group II were sacrificed at the intervals of 30, 60 and 90 days. Adrenals were taken out and divided into two halves. On half of the gland was immediately fixed in buffered formalin. The tissues were then dehydrated in graded alcohols and embedded in paraffin. Sections were cut at $5\ \mu$ and stained with haematoxylin and eosin. The other half of the adrenal gland was fixed in chilled Bakers Calcium Formol (2). The tissues were then placed at 4°C for seven days. Frozen sections were cut at $20\ \mu$ and were used for the demonstration of cholesterol by the *Schulz* method (3).

RESULTS

None of the animals died during the experiment. No gross abnormality was observed in the adrenals of animals from either group at different period of sacrifice.

Microscopic examination

The adrenal cortex of animals from group I (controls) and group II (manganese chloride 2.5 mg/kg/day for 30 days) presented normal histological appearance (Fig. 1). The adrenal cortex of rabbits treated with manganese chloride daily for 60 days showed marked alterations in the zona glomerulosa. Large vacuoles indicating the presence of lipid were apparent in the cytoplasm of many cells. The nuclei were pyknotic and markedly hyperchromatic (Fig. 2). No changes were seen in the zona fasciculata and zona reticularis. The cholesterol content, as demonstrated histochemically, was increased in the adrenal cortex of manganese treated rabbits (Fig. 3, 4).

After 90 days of daily administration of manganese chloride to rabbits the adrenal cortex was hyperaemic and revealed marked degenerative changes in the zona glomerulosa and zona fasciculata. Foci of cellular atrophy, pyknosis and nuclear fragmentation denoting degenerative changes were seen in these layers. The zona glomerulosa was markedly affected. The trabecular arrangement in the zona fasciculata was not as well defined as in the controls, leucocytic infiltration was seen in the septa. The capsule of the adrenal gland was thickened and haemorrhagic. Red blood cells were also seen lying in the septal spaces of the zona fasciculata (Fig. 5, 6). No changes were observed in the zona reticularis.

DISCUSSION

Adrenal glands are known to play a role in regulating the metabolism of manganese in the body (4). An excess of this metal in the system is likely to have a deleterious effect on the physiology and morphology of this endocrine gland. An increase in the weight of adrenal glands (5),

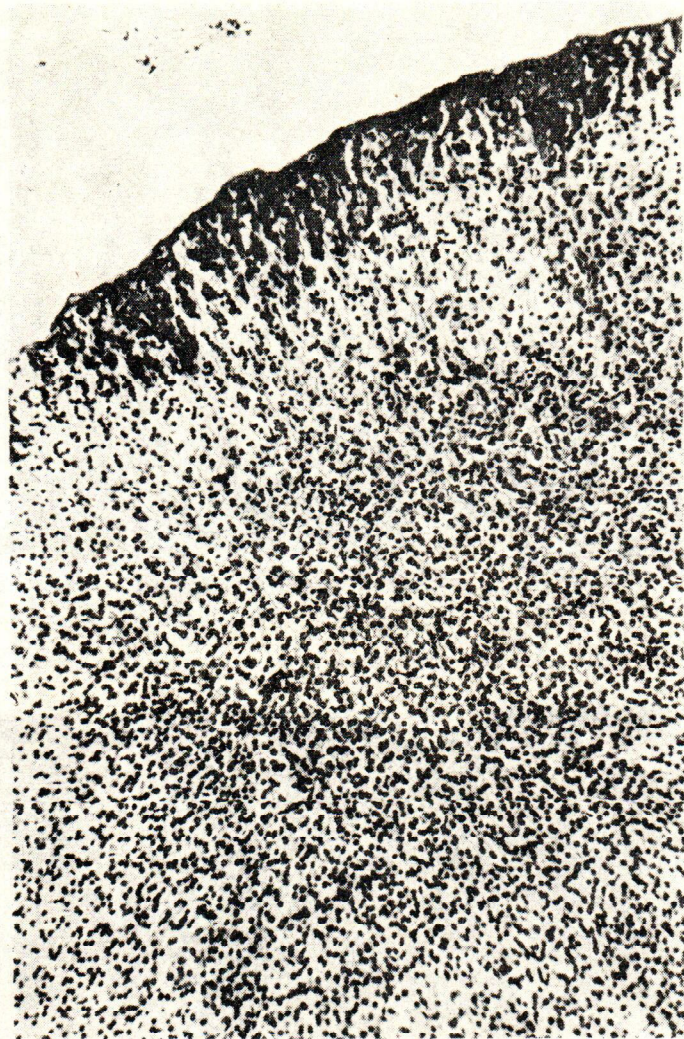

Fig. 1. Adrenal cortex of a normal rabbit. H & E X 160



Fig. 2. Adrenal cortex of a rabbit, administered intravenously manganese chloride (2.5 mg/kg/day) for 60 days, showing large vacuoles in the cells of the zona glomerulosa and pyknotic nuclei. H & X 640

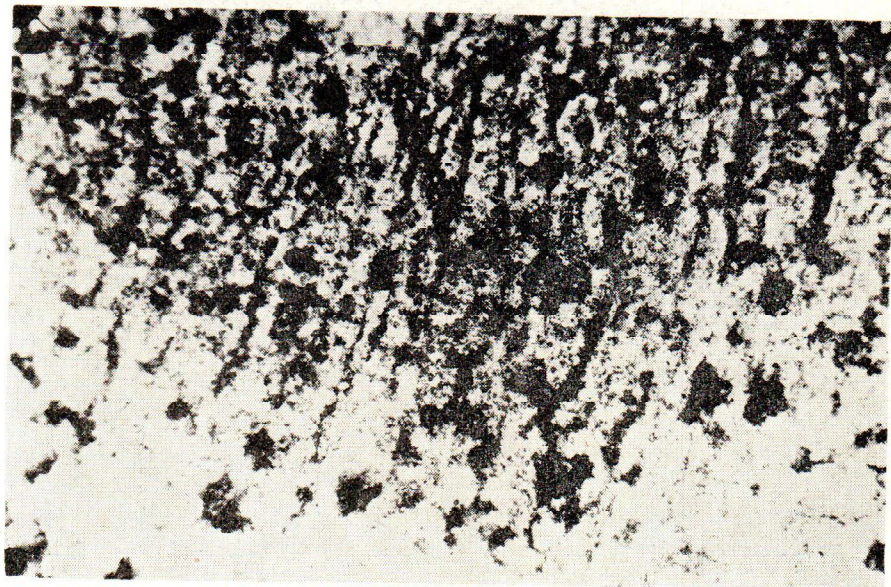

Fig. 3. Adrenal cortex of a normal rabbit showing cholesterol deposits. Frozen section, Schultz method X 160



Fig. 4. Adrenal cortex of a rabbit administered intravenously manganese chloride (2.5 mg/kg/day) for 60 days, showing increased cholesterol in the zona glomerulosa. Frozen section, Schultz method X 160

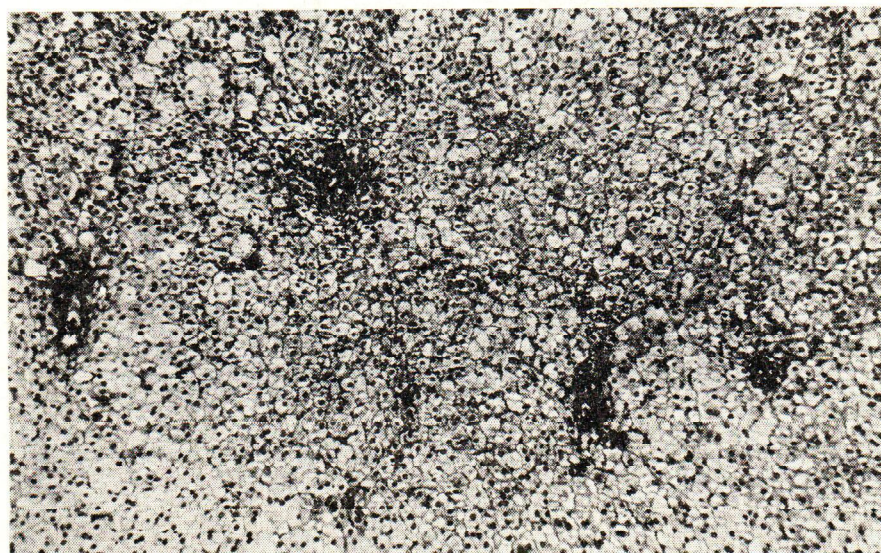

Fig. 5. Adrenal cortex of a rabbit, administered intravenously manganese chloride (2.5 mg/kg/day) for 90 days, showing degeneration and leukocytic infiltration in the zona glomerulosa and zona fasciculata. H & E X 160

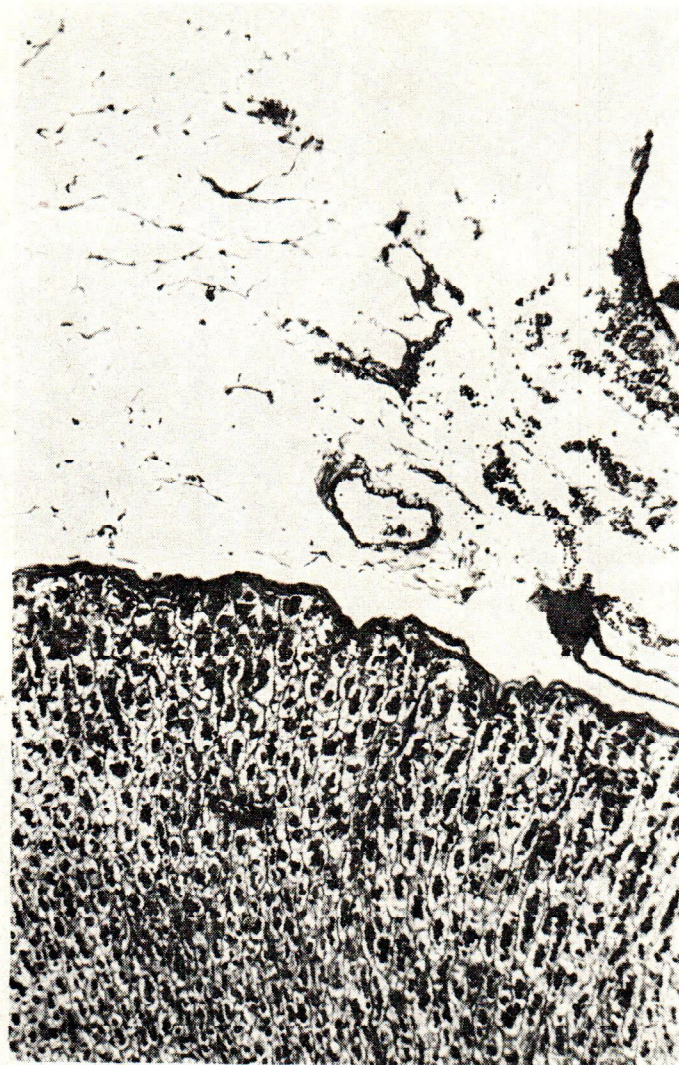


Fig. 6. Adrenal cortex of a rabbit, administered intravenously manganese chloride (2.5 mg/kg/day), showing thickened and haemorrhagic capsule. H & E X 160

alterations in the plasma 17-oxycorticosteroids and ascorbic acid content of adrenals (6) have been described in animals treated with manganese.

The present study demonstrated an increase in the cholesterol content and degenerative changes in the zona glomerulosa and zona fasciculata of the adrenal cortex. Marked hyperaemia and the thickening of the capsule were found. The zona reticularis did not reveal any morphological alterations. These findings are not entirely comparable with those of *Laskavaya* (Loc. cit.) who described a loss of lipids, hyperaemia and hypertrophy of the glomerular and reticular zones of the adrenal cortex. Elevated cholesterol in the adrenal cortex of manganese increased synthesis of this lipid component induced by manganese which is known to stimulate cholesterol synthesis in the body (7). However, further work is needed to correlate the concentration of manganese in the adrenals and its relation with increased cholesterol formation in this endocrine gland. Degenerative changes in the zona glomerulosa and zona fasciculata after prolonged administration of manganese chloride may also indicate a disturbance in the synthesis of some important hormones by the cells of these layers. Experiments are in progress to find out the functional derangement resulting from the necrotic changes in the adrenal cortex.

ACKNOWLEDGEMENT

Authors are grateful to Shri S. G. Husain and I. Ansari for their technical assistance and to Sri M. Ahmed for photomicrography.

References

1. *Laskavaya, A. I.*: Endokrinopatii Lech Gorm Resp. Mezhved SB., 5 (1970) 94.
2. *McManus, J. F. A., Mowry, W. R.*: Staining methods: Histological and histochemical, Div. Harper & Row Publisher, New York, Evanston and London, 1965.
3. *Weber, A. F., Phillips, M. G., Bell, J. T. Jr.*: Histochem. Cytochem., 4 (1956) 308.
4. *Mikhaitoo, V. G., Truda, F., Patol, P.*: Toksikol Sverdlovsk., 6 (1961) 284.
5. *Maksimov, S V., Laskavaya, A. L.*: Probl. Endokrinol., 14 (1968) 59.
6. *Hughes, E. R., Miller, S. T., Cotzias, G. C.*: Am. J. Physiol., 211 (1966) 207.
7. *Mena, I., Marin, O., Fuenzalida, S. Cotzias, G. C.*: Neurology, 17 (1967) 128.

Sažetak

UČINAK MANGANA NA MORFOLOGIJU NADBUBREŽNE ŽLIJEZDE

Manganov klorid, u dozi od 2,5 mg/kg je intravenski svakodnevno injiciran skupini od 12 kunića, dok je kontrolnoj skupini od 6 kunića injicirana jednaka količina fiziološke otopine. Po četiri životinje iz pokusne skupine i

po 2 iz kontrolne usmrćene su nakon 30, 60, odnosno 90 dana pokusa i nadbubrežne žlijezde su analizirane histološki i histokemijski.

U kontrolnih životinja i u onih trovanih manganom do 30 dana nije bilo uočljivih histoloških promjena nadbubrežnih žlijezda. Nakon 60-dnevnog tretiranja manganom utvrđene su značajne promjene u zoni glomerulozi u obliku pojave velikih vakuola i povećanog sadržaja kolesterola. Nakon 90-dnevnog tretiranja manganom u kori nadbubrežne žlijezde javile su se degenerativne promjene sa žarištima celularne atrofije i fragmentacije jezgara.

Rezultati upućuju na to da morfološke promjene mogu značajno utjecati na promjene funkcije ove žlijezde s unutrašnjim izlučivanjem.

*Istraživački centar
za industrijsku toksikologiju,
Lucknow, Indija*

Primljeno 24. VI 1974.