

## Synchronous caecal small-cell neuroendocrine carcinoma and adenocarcinoma of the rectum

*Sinkroni neuroendokrini karcinom malih stanica cekuma i adenokarcinom rektuma*

Goran Zukanović, Željko Glavić, Goran Šantak, Tomislav Crnković, Mirela Frančina, Mia Zukanović\*

---

### Summary

Small-cell neuroendocrine colon carcinoma is a rare entity with a usually poor prognosis. An 80-year-old female had colon cancer surgery due to synchronous tumour of the rectum and caecum. Pathohistological analysis of the caecal tumour showed trabecular and solid clusters, relatively uniformed small to middle sized epithelial cells, deficient cytoplasm and there were a great number of mitosis with larger areas of necrosis in the connective tissue. The immunohistochemistry was positive for chromogranin A. The caecal tumour was diagnosed as a small-cell neuroendocrine carcinoma. In addition, the rectal tumour showed microscopic findings consistent with stage IIA adenocarcinoma. The immunohistochemical panel showed that the tumour was negative for neuroendocrine markers. There were no clinical findings suggestive of hormone hypersecretion. Cancer metastases were not found. Postoperative chemotherapy was applied. The patient is still alive, in good general condition and with no signs of tumour progression.

**Key words:** neuroendocrine, small-cell carcinoma, caecum, immunohistochemistry

---

### Sažetak

Neuroendokrini karcinom malih stanica debeloga crijeva rijedak je entitet s najčešće lošom prognozom. Osamdesetogodišnja žena podvrgnuta je operaciji debeloga crijeva zbog sinkronog tumora rektuma i cekuma. Patohistološka analiza tumora cekuma pokazala je trabekularne i čvrste nakupine, relativno uniformne male do srednje velike epitelnice, oskudne citoplazme, a u vezivnom tkivu bilo je dosta mitozu s većim područjima nekroze. Imunohistokemija je bila pozitivna na kromogranin A. Tumor je dijagnosticiran kao neuroendokrini karcinom malih stanica cekuma. Osim toga, tumor rektuma pokazao je mikroskopske nalaze u skladu s IIA stadijem adenokarcinoma. Imunohistokemijski panel pokazao je da je tumor bio negativan na neuroendokrine markere. Nije bilo kliničkoga nalaza koji ukazuje na pojačanu sekreciju hormona. Metastaze karcinoma nisu nađene. Provedena je postoperativna kemoterapija. Pacijentica je i dalje živa, dobrog općega stanja, bez znakova progresije tumora.

Ključne riječi: neuroendokrini, karcinom malih stanica, cekum, imunohistokemija

*Med Jad 2016;46(3-4):109-114*

### Introduction

Neuroendocrine carcinomas are malignant tumours that show histopathological and immunohistochemical evidence of neuroendocrine differentiation. Neuroendocrine tumours can develop at many different sites

of the body, but colon is a very rare site.<sup>1</sup> Most neuroendocrine tumours are carcinoids and they have a better prognosis than conventional adenocarcinomas. The original term "carcinoid" equates to neuroendocrine tumours that are both grade 1 and 2 (well differentiated), whereas grade 3 neuroendocrine tumours are mostly small-cell neuroendocrine

---

\* **General County Hospital of Požega, Department of Abdominal Surgery** (Goran Zukanović, MD, Željko Glavić, MD PhD Professor, Goran Šantak, MD PhD); **Department of Orthopaedic Surgery** (Tomislav Crnković, MD PhD); **Department of Pathology** (Mirela Frančina, MD); **Department of Radiology** (Mia Zukanović, MD)

Correspondence address / *Adresa za dopisivanje*: Goran Zukanović, dr. med., General County Hospital of Požega, Department of Abdominal Surgery, Osječka 107, 34000 Požega, Croatia; e-mail address: zukinjo@hotmail.com

Received / *Primljeno* 2016-04-17; Revised / *Ispravljeno* 2016-06-22; Accepted / *Prihvaćeno* 2016-07-05.

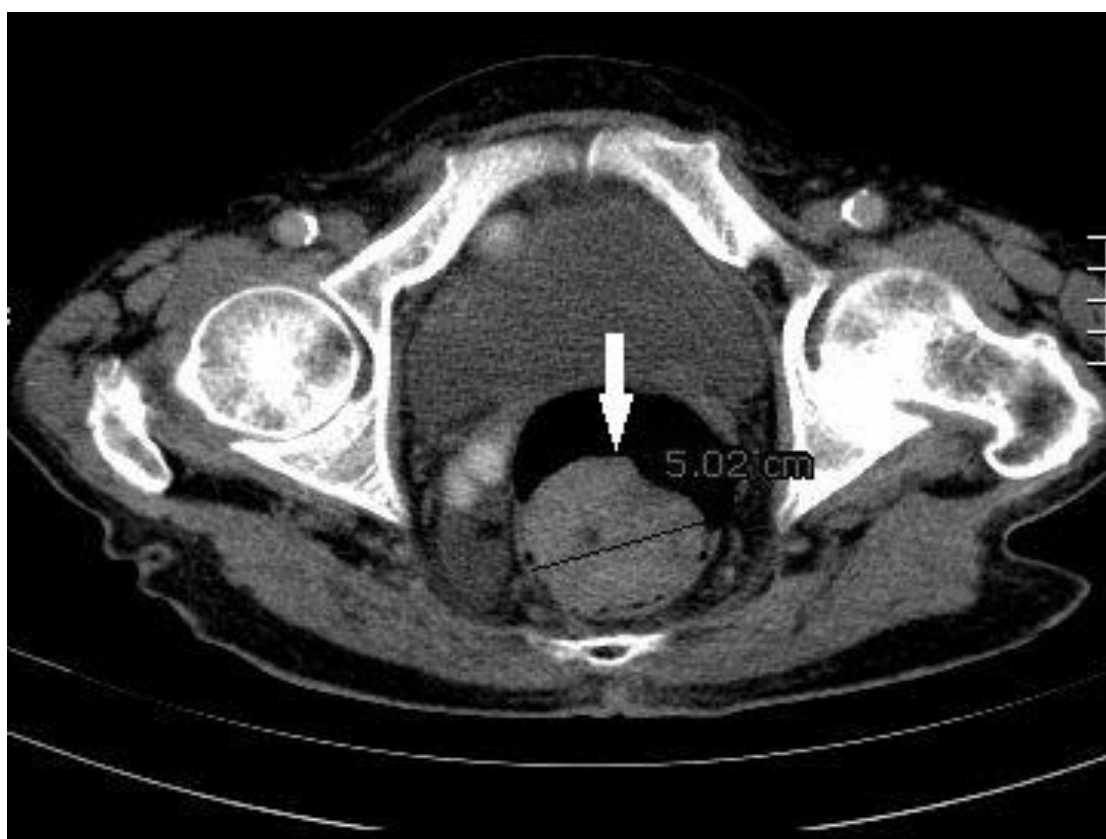carcinomas (SCNEC) with a minority component being large-cell type (poorly differentiated).<sup>2</sup> Small-cell neoplasia most commonly originates in the lung but also other sites such as skin, thymus, kidney, breast, ovary, uterus, urinary bladder, hepatobiliary tree, pancreas and salivary glands.<sup>3</sup> More specifically, the colorectal SCNEC accounts for 0.2%<sup>4</sup> to 1.5%<sup>5</sup> of all colonic cancers and is considered to be an aggressive neoplasm with rapid growth and early spread carrying poor prognosis.<sup>4</sup>

### Case report

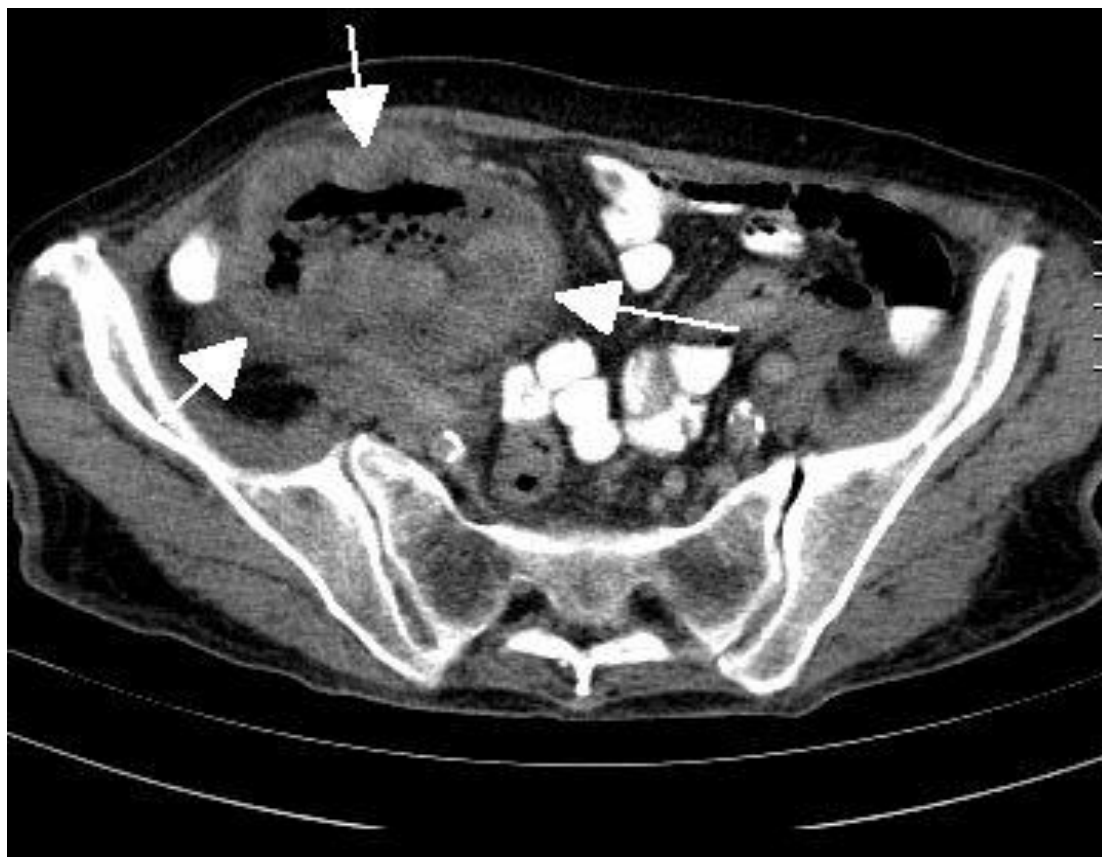An 80-year-old female was admitted with leading symptom of abdominal discomfort. Patient's past medical history was unremarkable. In the last four months the patient is periodically experiencing upper abdominal pain and loss of appetite, denying nausea and vomiting. In the same period of time she lost 20 kg of weight. In the last four months patient's stool is irregular (absent from time to time in periods of 8 days) with occasional diarrhea without tinge of blood or melena. The laboratory results verify microcytic anemia.

Colonoscopy has showed a tumorous mass in the mid third of rectum. Irigography has verified a lack in filling measured 40 mm in diameter, in the area of rectosigmoid crossing, which is considerably reducing the lumen of the bowel and where the barium enema isn't passing through. Computed tomography (CT) of the abdomen and pelvis has shown a thickening of the bowel wall which was highly suspect of an infiltration of the rectal ampulle on the left side just above the anocutaneous border, and just above the same rectosigmoid area near the back bowel wall has shown a round tumorous mass 5 cm in diameter (Picture 1). The wall of the caecum was slightly thicker (Picture 2). The pelvic CT showed no enlarged lymphatic nodes.

On the third day of patient's hospitalization, based upon diagnostic criteria, we decide to perform a medial laparotomy which has shown a smaller tumour measured 5 cm in diameter in the mid third of rectum. Right hemicolectomy with the resection of infiltrated ileum was performed and the Hartmann procedure in the rectosigmoidal area. The recovery was unremarkable. The patient was discharged 12 days after the surgical procedure.



Picture 1 CT finding of the abdomen and pelvis. Tumorous mass in the rectum (arrow)  
*Slika 1. CT nalaz abdomena i zdjelice. Tumorska masa u rektumu (strelica)*



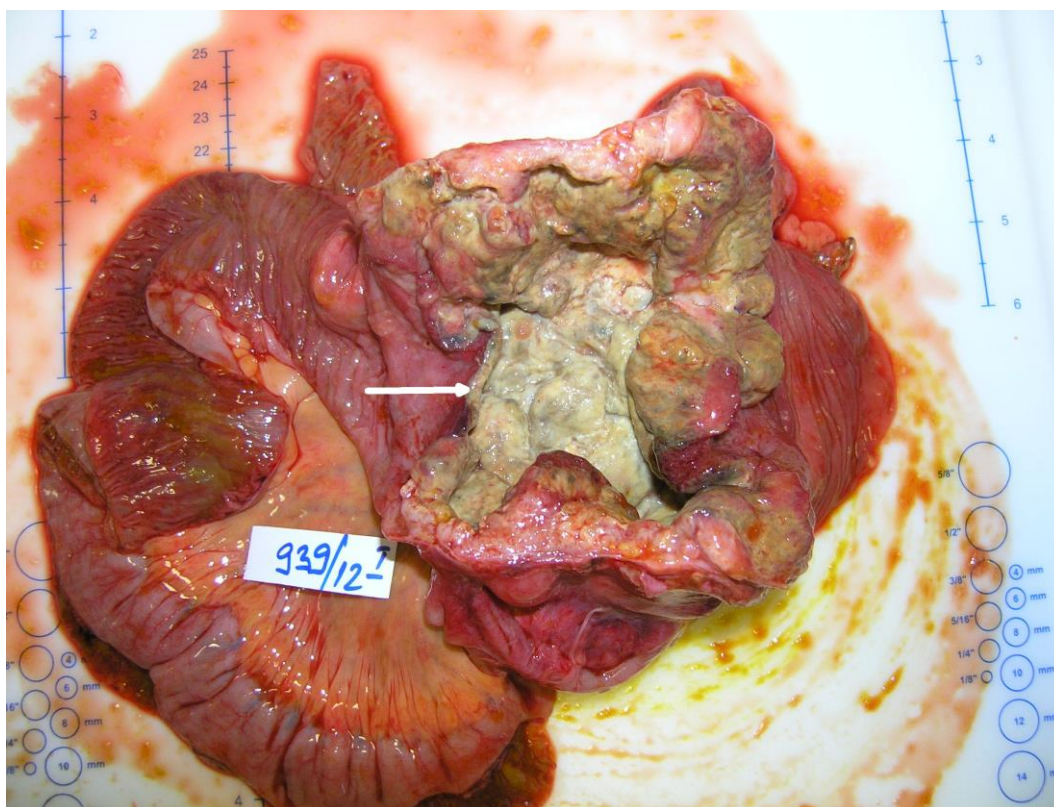
Picture 2 CT finding of the abdomen and pelvis. Thickened caecal wall caused by giant small cell neuroendocrine carcinoma (arrows)

*Slika 2. CT nalaz abdomena i zdjelice. Zadebljanje stijenke cekuma uzrokovano velikim neuroendokrinim karcinomom malih stanica (strelice)*

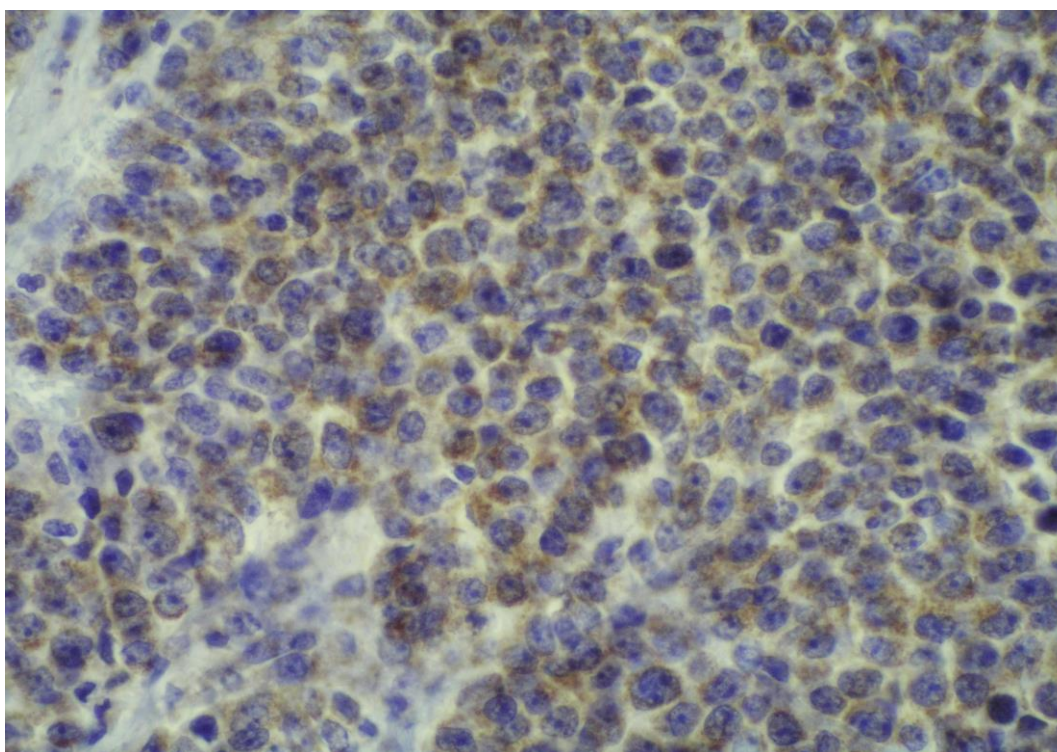
The macroscopic examination has shown, in the area of the Bauchin's valve, caecum and ascendant colon on a length of 8.5 cm, a yellowish white tumorous tissue that engages the whole circumference of the bowel (Picture 3). This tumour involved the pericolic adipose tissue. The rectum margin was free from tumour. Metastasis was found in neither of eleven dissected regional lymph nodes. The histological examination has shown that the tissue in question was a cluster of trabecular and solid, relatively uniformed small to middle sized epithelial cells with deficient cytoplasm and in the connective tissue were a lot of mitosis (up to 100 per 10 high power field) with larger areas of necrosis. An immunohistochemical panel was performed, and the tumour was found to be positive for chromogranin A. The synaptophysin and CD56 was negative. Therefore, our diagnosis of the tumour was a giant small-cell neuroendocrine carcinoma (Picture 4).

The macroscopic examination of the second sample, a part of rectosigmoid colon, has shown an exophytic tumour sized 4.5 x 2 cm, which engages

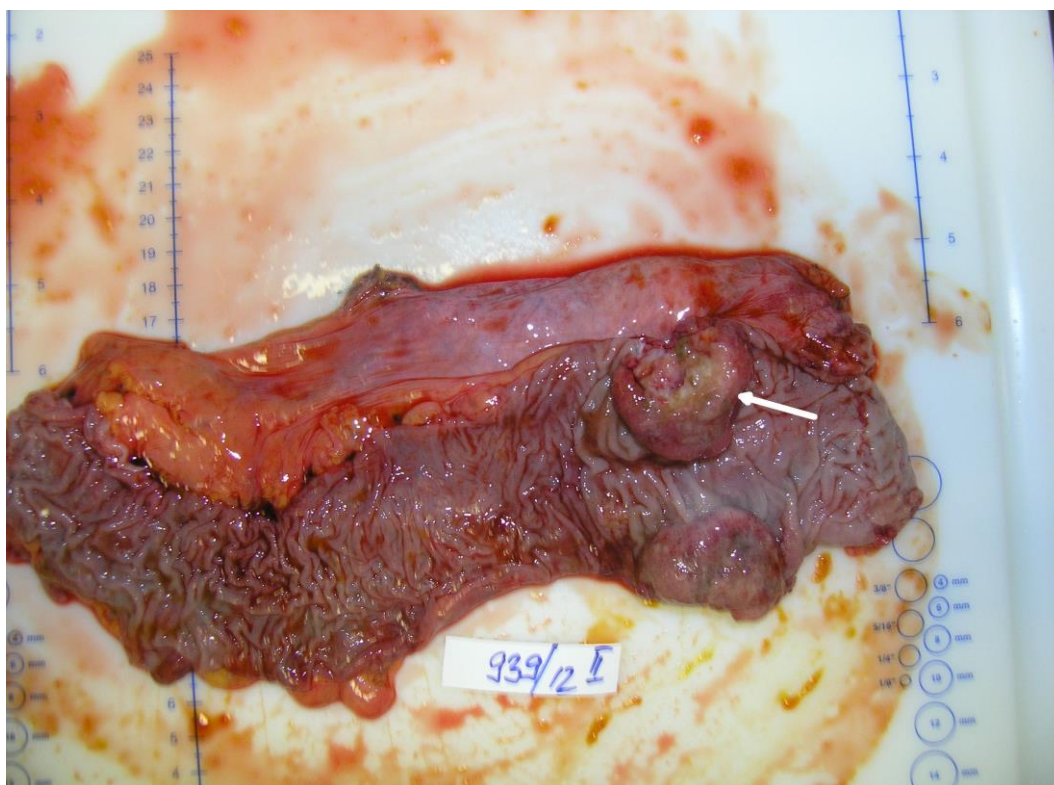
the whole circumference of bowel (Picture 5). All sampled lymph nodes and surgical ends were free of tumour involvement. The tumour is histologically made of atypical glandular formations coated with malignant epithelium partly making a cribriform form. The tumorous tissue infiltrates the whole thickness of the bowel wall and spreading to the under laying fat tissue. Diagnosis was stage IIA adenocarcinoma. On the immunohistochemical staining panel, the tumour was negative for neuroendocrine markers (chromogranin A, synaptophysin and CD56). Thus, we concluded that the patient had synchronous a primary adenocarcinoma of the rectum and a primary giant SCNEC in the caecum. The patient received postoperative chemotherapy with 5-fluorouracil. Five cycles of chemotherapy were performed. The patient is still alive and with no sign of tumour progression or distant metastasis 6 month after the treatment. In the follow up of patient we determined carcinoembryonic antigen (CEA), performed liver ultrasound and control thorax-abdomen-pelvis CT.



Picture 3 Giant yellowish white neuroendocrine carcinoma in the caecum (arrow)  
*Slika 3. Veliki žuto-bijeli neuroendokrini karcinom u cekumu (strelica)*



Picture 4 Microscopic finding. Immunohistochemical staining revealed positive findings for chromogranin A.  
*Slika 4. Mikroskopski nalaz. Imunohistokemijsko bojenje pokazalo je pozitivan nalaz na kromogranin A.*



Picture 5 Macroscopic appearance of the resected specimen. Exophytic adenocarcinoma in the rectum (arrow).  
*Slika 5. Makroskopski prikaz reseciranog uzorka. Egzofitični adenokarcinom u rektumu (strelica).*

### Discussion

This case has two aspects of clinical interest. First, synchronous adenocarcinoma and SCNEC is the rare appearance in clinical practice. Second, there are no clear guidelines for appropriate treatment and follow up of SCNEC with a synchronous secondary malignancy; therefore, our experience may help in the consideration of treatment for similar patients.

SCNEC are rare in the large bowel, but more common in this location than elsewhere in the intestines. Neuroendocrine carcinomas including SCNECs comprise approximately 0.6% of all carcinomas of the large bowel.<sup>6</sup> The average age of patients with neuroendocrine carcinomas of the large bowel is 61.5 years and the male-to-female ratio is essentially 1 : 1, similar to the values for large-bowel adenocarcinomas.<sup>6,7</sup> Neuroendocrine carcinomas of the colorectum are grossly similar to conventional adenocarcinomas. If an associated adenoma is present, they may be polypoid; if not, they are typically ulcerated neoplasms with a raised border, and on cut section they are infiltrative. SCNEC is a neuroendocrine tumour that has features in common with neuroendocrine-differentiated tumours as well as specific cytological features: small cells with minimal

cytoplasm and fusiform nuclei and have very high mitotic rate, averaging 65 per 10 high power field.<sup>8</sup> Small cell carcinomas typically express chromogranin A, synaptophysin and CD56.<sup>9</sup> In the report by Vilallonga et al.,<sup>10</sup> on neuroendocrine tumours, excluding carcinoid tumours, most patients presented with a paraneoplastic or carcinoid syndrome. However, our patient had no such symptoms. However, we cannot rule out the possibility of secreted hormones in the plasma at very low concentrations not associated with a clinical syndrome, or if there were secreted peptides they were not associated with clinical effects. The precise pathogenesis of secondary cancers with neuroendocrine carcinoma remains unclear. Some reports have suggested that neuroendocrine tumours occur as secondary primary carcinoma. According to one previous study, gastrin and cholecystokinin were associated with neuroendocrine carcinoma; this resulted in tissue growth in the gastrointestinal tract and carcinogenesis leading to colorectal and gastric cancer.<sup>11</sup> In addition, Prommeger et al.<sup>12</sup> reported that neuroendocrine tumours are associated with a high risk of secondary gastrointestinal malignancy. They studied 96 patients with neuroendocrine tumours and found that 14 patients had a neuroendocrine tumours

and a second primary malignancy. Five patients had a synchronous second primary malignancy. The locations were two colon cancers with one double colon cancer, one gastric cancer, one bladder cancer, and one ovarian cancer. In recent study Kato et al.<sup>13</sup> suggested a possible link between colorectal neuroendocrine carcinoma and adenocarcinoma. These reports are consistent with the findings in our case where the patient had an advanced stage of neuroendocrine carcinoma in the caecum and a synchronous adenocarcinoma in the rectum. It is possible that the neuroendocrine carcinoma was associated with the development of the adenocarcinoma of the rectum. However, further confirmation is needed to support this.

For colonic neuroendocrine tumours (excluding appendiceal tumours), 5-year survival rates are 76.0% for localized disease, 71.6% for regional disease, and 30.0% for tumours with distant metastases. Overall, the 5-year survival rate is 61.8%.<sup>14</sup> If the neuroendocrine carcinoma is completely resected, the 5-year survival rate has been reported to be 61%.<sup>15</sup> However, most patients are not candidates for curative resection.

After completely resection both of the tumours, our patient received systemic chemotherapy with 5-fluorouracil. 5-fluorouracil is the chemotherapeutic agent of first choice in the treatment of patients with colorectal cancer. Five cycles of systemic chemotherapy were provided. The patient is still alive with good performance status and no sign of tumour progression.

In conclusion, we report a SCNEC of the caecum that coexisted with an adenocarcinoma, suggesting possible association between colorectal neuroendocrine carcinoma and adenocarcinoma. Further investigations are required to determine the pathogenesis of these synchronous tumours.

### References

1. Kloppel G, Perren A, Heitz PU. The gastropancreatic neuroendocrine cell system and its tumors: the WHO classification. *Ann NY Acad Sci.* 2004;1014:13-27.
2. Eggenberger JC. Carcinoid and other neuroendocrine tumors of the colon and rectum. *Clin Colon Rectal Surg.* 2011;24:129-134.
3. Pearse AG. The diffuse neuroendocrine system and the apud concept: related 'endocrine' peptides in brain, intestine, pituitary, placenta and anuran cutaneous glands. *Med Biol.* 1977;55:115-125.
4. Clery AP, Dockerty MB, Waugh JM. Small cell carcinoma of the colon and rectum. A clinicopathological study. *Arch Surg.* 1961;83:164-171.
5. Saclarides TJ, Szeluga D, Staren ED. Neuroendocrine cancers of the colon and rectum. Results of a ten-year experience. *Dis Colon Rectum.* 1994;37:635-642.
6. Bernick PE, Klimstra DS, Shia J, et al. Neuroendocrine carcinomas of the colon and rectum. *Dis Colon Rectum.* 2004;47:163-169.
7. Stelow EB, Moskaluk CA, Mills SE. The mismatch repair protein status of colorectal small cell neuroendocrine carcinomas. *Am J Surg Pathol.* 2006;30:1401-1404.
8. Bosman FT, Carneiro F, Hruban RH, Theise ND, editors. WHO classification of tumours of the digestive system. Lyon: IARC Press; 2010, str. 165-168.
9. Grabowski P, Schonfelder J, Ahnert-Hilger G, et al. Expression of neuroendocrine markers: a signature of human undifferentiated carcinoma of the colon and rectum. *Virchows Arch.* 2002;441:256-263.
10. Vilallonga R, Espin EB, Lopez MC, Landolfi S, Armengal MC. Neuroendocrine carcinomas of the colon and rectum: a unit's experience over six years. *Rev Esp Enferm Dig.* 2008;100:11-16.
11. Reim D, Weirich G, Neu B, Bajbouj M, Brücher BL. Synchronous adenocarcinoma of the lung and neuroendocrine carcinoma of the ileum. *Int J Colorectal Dis.* 2008;23:325-327.
12. Prommegger R, Ensinger C, Steiner P, Sauper T, Profanter C, Margreiter R. Neuroendocrine tumors and second primary malignancy: a relationship with clinical impact? *Anticancer Res.* 2004;24:1049-1051.
13. Kato T, Terashima T, Tomida S, et al. Cytokeratin 20-positive large cell neuroendocrine carcinoma of the colon. *Pathol Int.* 2005;55:524-529.
14. Modlin IM, Lye KD, Kidd M. A 5-decade analysis of 13,715 carcinoid tumors. *Cancer.* 2003;97:934-959.
15. Park JS, Kim L, Kim CH, et al. Synchronous large-cell neuroendocrine carcinoma and adenocarcinoma of the colon. *Gut Liver.* 2010;4:122-125.