

Injuries in Water Polo

Water polo originated in mid-19th century England and Scotland as an aquatic form of rugby football (1). Players used “pulu,” an inflated, vulcanized rubber ball imported from India, pronounced “polo.” The game became known as water polo and that name has been used ever since. Water polo first appeared in modern Olympics in Paris in 1900, making it the earliest and longest-running olympic team competition. It has been traditionally dominated by Europeans – Hungary, Spain, Italy, Croatia, Russia, Greece, and Serbia, but in the last decades the popularity of water polo has been constantly growing in the USA, Australia, Canada, and Asia.

The modern game of water polo is a unique combination of swimming, throwing, and martial arts. Physiologically, it is extremely demanding, because it is comprised of intense burst activity of less than 15-second duration, followed by lower intensity intervals of less than 20 seconds. Water polo is becoming more physical than ever (2). This results in a number of typical acute traumatic events such as contusions, lacerations, sprains, dislocations, or fractures (3). On the other hand, vigorous training with numerous repetitions of ball throws, swims, or kicks may result in overuse injuries (4). This review covers, in systematic fashion, the most important acute and overuse injuries in water polo by analyzing four different regions of the body: head, spine, upper extremities, and lower extremities.

Head injuries

Facial injuries

Close contact among water polo players and high ball velocities of 60-70 km/h frequently cause

head and facial injuries (Figure 1). Sometimes, benign head injury can quickly deteriorate into a life-threatening condition and it is critical to ensure maintenance of a proper airway in short time. Water polo is unique because the physician or the coach must rely on other players to bring the injured athlete to the pool side for evaluation. The most common types of injuries are facial lacerations, especially of the supraorbital region, requiring immediate treatment. Direct contact with another player carries sufficient force to fracture the thinner bones of the face. Fractures of the facial bones represent severe head and face injuries, and immediate medical evaluation and x-ray assessment are necessary. In all facial or head injuries, players must be closely monitored for signs of disorientation, poor balance, and coordination. Also, the patient must be awakened at regular intervals during the night for the first 24 hours (5).

Swimmer's ear (*otitis externa*)

Otitis externa is an inflammatory process of the external auditory canal. It is so common among people who spend many hours in water that it has be-



Figure 1. Close contact between players may result in different injuries of the head, face, and hand.

come known as the swimmer's ear (6). The most common precipitant of the swimmer's ear is excessive moisture that removes cerumen and increases pH of the external auditory canal, which provides a good setting for bacterial growth (7). Thorough hygiene of the auditory canal is essential for diagnosis and treatment. In addition, acidification with a topical solution of 2% acetic or boric acid, combined with hydrocortisone for inflammation is an effective treatment in most cases and, when used after exposure to moisture, is an excellent prophylactic.

Trauma to the ear drum

Traumatic perforation of the ear drum is unfortunately a fairly common injury in water polo (8). The injury is the result of a slap on the side of the head with a cupped palm. This causes a dramatic rise in pressure in the canal. The increased pressure causes rupturing and development of a hole in the tympanic membrane. In most of the cases, this injury will heal without any significant impairment, but during the healing phase players should be kept out of water (9). If this is not acceptable due to necessity of training or competition, swimming may be allowed with molded ear plug and a bathing cap.

Eye injuries

The most frequent eye injuries in water polo can be roughly divided into three main categories (10,11).

Corneal abrasions. One of the most frequent injuries to the eye occurs as a result of a scratch from either a fingernail or foreign body. The treatment of corneal abrasions includes the instillation of antibiotic eye drops and padding of the eye.

Hyphema. Bleeding into the anterior chamber of the eye results from ruptured iris vessels and may be visible on slit lamp examination. The aim of the treatment is to prevent further bleeding, which may in turn result in uncontrollable glaucoma or blood staining of the cornea. The patient needs to rest in bed while the hemorrhage clears, usually 3 to 5 days.

Blow-out fracture of the orbita. Blow-out fracture of the orbita is the result from a direct trauma caused by a fist or a ball. Compression of the globe and orbital contents produces a fracture in the weakest part of the orbita, the orbital floor. Contents of the orbita may herniate through the defect. The patient typically presents with a periorbital hematoma, protruding or sunken eye, double vision on upward gaze, and numbness of the cheek. A detailed examination of the eye must be performed to exclude intraocular injuries. Surgery may be required to release the trapped muscle and repair the bony defect.

Spine injuries

Due to the fact that many anatomical structures in the spine region may be the source of pain, it is often very difficult for a clinician to determine the exact cause (5).

Repetitive cervical spine rotation required for breathing in freestyle swimming often produces neck pain in water polo players. A relatively common injury that can be extremely painful for the player is acute wry neck. It is characterized by a sudden onset of sharp neck pain with deformity and limitation of movement. It occurs either after a sudden, quick movement or on waking.

After a direct blow from an opponent player, acute acceleration/deceleration injury to the cervical spine can occur. Acute cervical nerve root is characterized by moderate to severe arm pain (12). Neck pain may or may not be a feature. The pain is aggravated by the movements of the cervical spine. There may be associated sensory symptoms. In older athletes or those who had previously suffered trauma to the neck, osteoarthritis may develop, particularly affecting the apophyseal joints. Headache, shoulder, and upper arm pain are often associated with neck pain, which is very important in differential diagnosis.

Low back pain is a common symptom in water polo players because the amount of rotational forces is significant during throwing and passing

the ball (13). Any of the pain-producing structures of the lumbar spine may cause low back pain, but the intervertebral discs and the apophyseal joints are the most common causes (14). With low back pain of lengthy duration, a number of factors will contribute to the overall clinical picture. These may include abnormalities of the ligaments of the intervertebral joints, muscles and fascia, as well as neural structures. Low back pain is usually associated with hypomobility of one or more intervertebral segments (15). The assessment of the segments mobility is a major component of the examination of the athlete with low back pain. Correction of segmental hypomobility forms an important part of the treatment program. Acute nerve root compression in the lumbar region is usually the result of an acute disk prolapse. In the acute phase, the most appropriate treatment is rest in a position of maximum comfort with administration of analgesics. Surgery may be required if neurological signs persist or worsen. If bowel or bladder symptoms are present, emergency surgery may be necessary.

There is a number of different techniques available for the correction of these spine abnormalities (16) – manual therapy to the joints (mobilization, manipulation, traction), muscles (massage therapy and dry needling), and neural structures (neural stretching).

When acute spinal injury is suspected, assessment begins on the field, with the ABC protocol (17). Airway maintenance is vital as circulation is usually not disturbed. Any unconscious athlete or any athlete who complains of numbness, weakness, paralysis, or neck pain should be assumed to have cervical spine injury until proven otherwise. Spinal immobilization is much more difficult when performed in the water and requires team work coordination. Taking the players with spinal injuries out of the water is a particularly important aspect of aquatic sports, especially water polo and diving. Aquatic spine boards and neck collars should always be available on the pool decks at competitions. The head

needs to be immobilized in a neutral position and flexion and extension movements should be particularly avoided.

Upper extremity injuries

Shoulder trauma

Water polo players are also at risk for traumatic dislocations and subluxations of the glenohumeral and the acromioclavicular joints from contact with opponent players or the ball. Both injuries usually occur to the throwing arm during the act of shooting or passing the ball, when the player has the arm in the cocked position, holding the ball. The force may be great enough to rupture the anterior capsule and glenohumeral ligament complex (Bankart lesion), resulting in antero-inferior subluxation or dislocation (Figure 2) (18). Posterior dislocation is less frequent. Closed reduction of acute shoulder dislocation is a treatment of choice. Although there are still some controversies regarding the necessity of operation, most authors nowadays recommend immediate arthroscopic stabilization in a subset of patients who are younger than 30 years and are top athletes (19-21). Arthroscopic Bankart repair of anterior capsulolabral lesions with use of suture anchors is a treatment of choice (22).

Swimmer's shoulder (shoulder pain)

Shoulder pain is the most common musculoskeletal complaint in water polo players. The incidence of shoulder pain is directly correlated with the level of competition and years spent competing in the sport. According to the data published in scientific literature it can reach up to 80% (23,24). It can be clearly demonstrated by magnetic resonance imaging (MRI) that various pathological changes are present even in those players that are completely asymptomatic (25). Swimmer's shoulder is a multifactorial clinical entity of a hypermobile glenohumeral joint, which allows increased translation of the humeral head in the glenoid. This multidirectional instability (MDI) leads to problems of

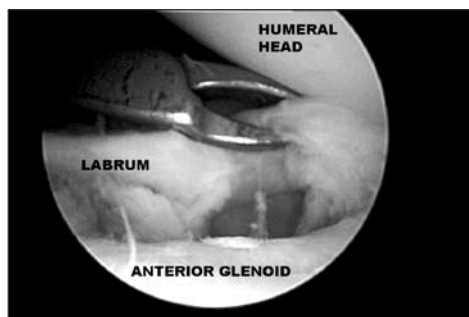


Figure 2. Arthroscopic image showing avulsion of the labrum from the anterior glenoid after traumatic shoulder dislocation in a water polo player.

impingement against the undersurface of the acromion, the coraco-acromial ligament, and occasionally, the coracoid process. Internal impingement is the unique condition in sports that require abduction and extremes of external rotation, such as those seen in late cocking stage of shot at goal or pitching (Figure 3) (26). This is a result from the contact between the posterior glenoid rim and the posterior aspect of the insertion of the supraspinatus and the superior aspect of the infraspinatus insertion into the posterior greater tuberosity (27). Most of the athletes with swimmer's shoulder can be successfully treated nonoperatively, with a specific exercise program. If a 6-month trial of non-operative management fails, the patient is a candidate for surgical reconstruction. The treatment of choice is arthroscopic capsular plication (28).

Rotator cuff injury

Injury to the rotator cuff among water polo players can include tendinopathies, partial thickness tears, and full thickness tears. In younger age groups, repetitive microtrauma and macrotrauma are the main causative factors, but with aging the etiology of the rotator cuff lesions shifts to degenerative. The diagnosis is based on detailed clinical examination, followed by ultrasonography and magnetic resonance imaging (MRI) (29,30). Although these imaging methods show similar accuracy in diagnosis of rotator cuff lesions, significant advantage of MRI is its ability to show the concomitant pathologic le-



Figure 3. During the late cocking stage of the shot at goal, the player's shoulder is in the position of abduction and maximal external rotation, which may result in the development of internal impingement.

sions. In general, the approach to the rotator cuff itself is similar to that in any sport. Athletes suffering from tendinopathies and partial thickness rotator cuff tears usually respond well to conservative treatment which consists of activity modification with avoidance of overhead activities, use of anti-inflammatory medications and stretching and strengthening of the shoulder and scapular muscles (31). Failure of conservative treatment during 3 to 6 months or presence of full-thickness rotator cuff tears indicates surgical treatment. The surgical management includes arthroscopic rotator cuff repair with or without acromioplasty (32).

Superior labrum from anterior to posterior lesions

Although the very first description dates in 1985 and was given by Andrews et al (33), superior labrum from anterior to posterior (SLAP) lesions were named and thoroughly described by Snyder et al (34). The lesion originates in the area behind the biceps muscle tendon insertion to the glenoid labrum and extends anteriorly to half of the glenoid (35). The most common etiology is a fall or direct blow to the shoulder, although repetitive biceps tension from overhead activity in water polo players is probably more common etiological factor. Athletes usually present with pain and various mechanical symptoms, but so far no reliable SLAP-lesion-specific physical examination tests have been developed to facilitate clinical diagnosis (36). The most accurate imaging method is MRI with gadolinium, but the most

reliable diagnostic tool still remains arthroscopy of the shoulder (37). The treatment depends on the stage of the lesion and involves fixation of the detached labrum to the glenoid or resection of the torn fragment (38).

Thrower's elbow (elbow pain)

Elbow pain is a common complaint of the water polo athletes and it poses a great diagnostic and therapeutic challenge because of a unique pathology that results from repetitive overhead throwing (39). Various different conditions have been attributed to the overhead throwing motion, but ulnar collateral ligament (UCL) injuries, valgus extension overload syndrome with olecranon osteophytes and posteromedial impingement, and osteochondritis dissecans of the capitellum are the most frequent in water polo (40). The valgus forces generated during the cocking and acceleration phases of throwing exceed the intrinsic tensile strength of the UCL and microtears occur (41). If not treated adequately, additional cumulative microtrauma will cause further damage and a complete rupture of the UCL will occur. Conservative treatment includes a brief period of rest, use of nonsteroidal anti-inflammatory medications (NSAIDs) and local physical therapy modalities (42). Operative treatment should be performed in competitive athletes with acute complete ruptures of the UCL or chronic symptoms due to instability that have not significantly improved after at least 3 to 6 months of conservative treatment (43). Posteromedial impingement is the result of the combination of tensile forces medially and shear forces posteriorly (44). In most of the cases the athlete can be treated conservatively, but if symptoms persist surgical intervention is indicated (45). Osteochondritis dissecans (OCD) of the elbow is a localized injury or condition affecting an articular surface that involves separation of a segment of cartilage and subchondral bone of the humeral capitellum (Figure 4) (46). OCD of the elbow is often observed in dominant extremity of young ath-

letes involved in throwing sports such as baseball, handball and water polo. Excessive cyclic loading of the radiocapitellar joint due to the repetitive valgus stress associated with throwing is thought to be the main cause. Symptoms include pain, swelling of the joint, and mechanical symptoms such as catching or blocking, and the diagnosis is confirmed with plain radiographs, computerized tomography, and/or MRI. The treatment is initially conservative with rest and physical therapy. Failure of such treatment during 3 to 6 months calls for open or arthroscopic surgery (47).

Hand and wrist injuries

Hand and wrist injuries are common in water polo players. The wrist functions to position the hand in space for gripping and grasping activities. This is accomplished by a unique and complex arrangement of bony and ligamentous structures.

Stenosing tenosynovitis (de Quervain's syndrome) of the first dorsal compartment is the most common tendinitis of the wrist in the athletes (48). It is the result of repetitive gliding of tendons (abductor pollicis longus and extensor pollicis brevis) beneath the sheath of the first compartment over the radial styloid. Treatment is dictated by stage of the disease. Rest and immobilization in early stages, after corticosteroid injection into first dorsal compartment results in reported cure rates of 62%, 80%, and 100% (49-51). If there is no progress, surgical release of the first dorsal compartment may be performed. Extensor carpi ulnaris tendinitis is second to de Quervain's in frequency in athletes, but it may affect tendons in all dorsal compartments. Treatment of tendinitis involves splinting, rest, nonsteroids, and occasional corticosteroid injection in the tendon sheath.

The commonly encountered acute injuries to the hand and fingers consist of lacerations, dislocations of the interphalangeal and metacarpophalangeal joints, and fractures of the phalanges and metacarpal bones (52,53). The web space tear associated with forcible abduction of two

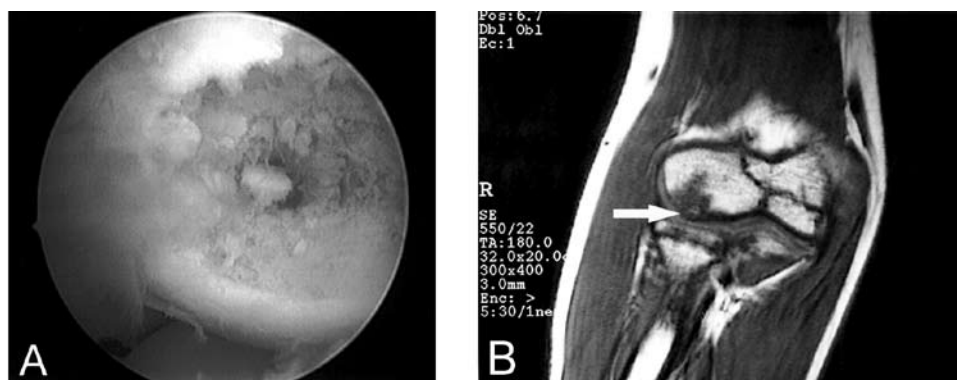


Figure 4. Osteochondritis dissecans of the humeral capitellum in a young water polo player. (A) Arthroscopic view of the lesion situated on the posterolateral aspect of the humeral capitellum; (B) magnetic resonance imaging of the same patient (white arrow indicates the lesion).

adjacent fingers is the most common laceration in water polo. Dislocation of the joints of the fingers and hand, usually a dorsal dislocation of the proximal interphalangeal joint with or without a fracture of the middle phalanx is common. The mechanism of injury is usually a hyperextension of the joint, which occurs when a player tries to catch a ball or block a shot (54).

Lower extremity injuries

Groin pain

Groin pain is defined as tendon enthesitis of adductor longus, iliopsoas, and/or abdominal muscles and can present a diagnostic and treatment challenge (55,56). The balance between the adductors and abdominal muscles is of great importance, as well as the elasticity of pubic symphysis. The weakness of the abdominal muscle wall is the most common cause of groin pain. This symptom seems to occur frequently in sports involving twisting and turning. History of chronic groin pain that is nonresponsive to treatment should raise suspicion of sportsman's hernia (57). Adductor muscle strains are common injury in sports that involve sudden changes of direction. The onset is acute and the area of pain and tenderness is usually well localized, either to the belly of the adductor longus, the proximal musculotendinous junction or the tendon near its origin on the inferior pubic ramus (58). Recurrent ad-

ductor muscle strains are common. This may be due to inadequate rehabilitation of the initial injury, resuming sport too quickly or not resolving associated problems such as lumbar spine stiffness or pelvic imbalance. Adductor tendinopathy causes proximal groin pain, which has a tendency to warm up with increasing activity. If the condition remains untreated, the pain tends to persist during activity and may migrate either to the contralateral groin or to the suprapubic region. Treatment of groin pain is complex and individual, including relative rest, anti-inflammatory medications if there is an acute exacerbation, physiotherapy modalities and massage therapy and eccentric strengthening. If conservative treatment is not successful, surgery is indicated.

Knee injuries

Swimmers, especially breast stroke, have long been complaining of medial knee pain. Kenal reports this percentage to be as high as 73% (59). It has been documented that leg work accounts for 40 to 55% of the game, depending on the position played and game tactics. Water polo players seldom perform the breaststroke "whip kick," but instead, the right leg rotates counterclockwise while the left rotates clockwise in the "eggbeater" kick unique to water polo. The rotation of the knee, with compression on the medial aspect of the joint, causes degenerative changes (60). Pain along or over the origin or insertion of the medi-

al collateral ligament is typically an overuse syndrome from the chronic stress and overuse of the eggbeater kick. The treatment should be directed to the correction of improper leg work technique along with proper warm-up exercises, local application of ice, and ultrasound (61).

Miljenko Franić

mfranic@kdb.hr

Alan Ivković

Ratko Rudić*

Acknowledgment

The authors thank Prof. Dr Nikola Čičak and Dr Ivan Bojanić from the Department of Orthopaedic Surgery Medical School, University of Zagreb for providing photographs of the shoulder and elbow, as well as Tonči Vlašić, journalist of Radio Dubrovnik, and Vladimir Dugačić, photographer of “Slobodna Dalmacija” for providing photographs from the World Swimming and Water Polo Championships in Melbourne 2007.

*EDITORIAL NOTE

Ratko Rudić is by far the most successful coach in the history of water polo, who, during his long and fruitful career, won 21 international trophies. He won three consecutive gold Olympic medals – Los Angeles 1984 and Seoul 1988 with the national team of Yugoslavia, and Barcelona 1992 with Italian national team. He also won three gold medals on World championships with three different national teams – Madrid 1986 with Yugoslavia, Rome 1994 with Italy, and Melbourne 2007 with Croatia. He earned his last gold medal in 2007 with Croatia in the dramatic final match against Hungary at the World Championship in Melbourne, Australia. In May 2007, Ratko Rudić was officially introduced to the International Swimming Hall of Fame in Fort Lauderdale, Florida, USA. Although he is the fifth Croatian awarded with this honor, this was the first time in the history of this institution that the Croatian flag was lifted.

References

- Eagan T. Water Polo: rules, tips, strategy, and safety. New York: Rosen Pub Group; 2005.
- Lozovina V, Pavicic L. Anthropometric changes in elite male water polo players: survey in 1980 and 1995. *Croat Med J.* 2004;45:202-5. [Medline:15103759](#)
- Junge A, Langevoort G, Pipe A, Peytavin A, Wong F, Mountjoy M, et al. Injuries in team sport tournaments during the 2004 Olympic Games. *Am J Sports Med.* 2006;34:565-76. [Medline:16303876](#)
- Pećina MM, Bojanić I. Overuse injuries of the musculoskeletal system. 2nd ed. Boca Raton: CRC Press; 2003.
- Brooks JM. Injuries in water polo. *Clin Sports Med.* 1999;18:313-9. [Medline:10230567](#)
- Wang MC, Liu CY, Shiao AS, Wang T. Ear problems in swimmers. *J Chin Med Assoc.* 2005;68:347-52. [Medline:16138712](#)
- Schelkun PH. Swimmer's ear: getting patients back in the water. *Phys Sportsmed.* 1991;19:85-8.
- Dominguez RH. Water polo injuries. *Clin Sports Med.* 1986;5:169-83. [Medline:3948253](#)
- Rybak LP, Johnson DW. Tympanic membrane perforations from water sports: treatment and outcome. *Otolaryngol Head Neck Surg.* 1983;91:659-62. [Medline:6420748](#)
- Barr A, Baines PS, Desai P, MacEwen CJ. Ocular sports injuries: the current picture. *Br J Sports Med.* 2000;34:456-8. [Medline:11131235](#)
- Rodriguez JO, Lavina AM, Agarwal A. Prevention and treatment of common eye injuries in sports. *Am Fam Physician.* 2003;67:1481-8. [Medline:12722848](#)
- Levitz CL, Reilly PJ, Torg JS. The pathomechanics of chronic, recurrent cervical nerve root neurapraxia. The chronic burner syndrome. *Am J Sports Med.* 1997;25:73-6. [Medline:9006696](#)
- Ong A, Anderson J, Roche J. A pilot study of the prevalence of lumbar disc degeneration in elite athletes with lower back pain at the Sydney 2000 Olympic Games. *Br J Sports Med.* 2003;37:263-6. [Medline:12782554](#)
- Lawrence JP, Greene HS, Grauer JN. Back pain in athletes. *J Am Acad Orthop Surg.* 2006;14:726-35. [Medline:17148620](#)
- Bono CM. Low-back pain in athletes. *J Bone Joint Surg Am.* 2004;86-A:382-96. [Medline:14960688](#)
- Richardson C, Jull G, Hodges P, Hides J. Therapeutic exercise for spinal segmental stabilization in low back pain. Edinburgh: Churchill Livingstone, 1999.
- Tintinalli JE, Kelen GD, Stapczynski JS, editors. Emergency medicine. A comprehensive study guide. 5th ed. New York: McGraw-Hill; 2000.
- Vlak T, Pivalica D. Handball: the beauty or the beast. *Croat Med J.* 2004;45:526-30. [Medline:15495273](#)
- Kuhn JE. Treating the initial anterior shoulder dislocation – an evidence-based medicine approach. *Sports Med Arthrosc.* 2006;14:192-8. [Medline:17135968](#)
- Kirkley A, Werstine R, Ratjek A, Griffin S. Prospective randomized clinical trial comparing the effectiveness of immediate arthroscopic stabilization versus immobilization and rehabilitation in first traumatic anterior dislocations of the shoulder: long-term evaluation. *Arthroscopy.* 2005;21:55-63. [Medline:15650667](#)
- Bottoni CR, Wilckens JH, DeBerardino TM, D'Alleyrand JC, Rooney RC, Harpstrite JK, et al. A prospective, randomized evaluation of arthroscopic stabilization versus nonoperative treatment in patients with acute, traumatic, first-time shoulder dislocations. *Am J Sports Med.* 2002;30:576-80. [Medline:12130413](#)
- Cicak N, Delimar D, Klobucar H, Korzinek K. Arthroscopic Bankart repair with extracapsular and extra-articular knot using the Mitek suture anchor. *Arthroscopy.* 1999;15:653-9. [Medline:10495186](#)
- Colville JM, Markman BS. Competitive water polo. Upper extremity injuries. *Clin Sports Med.* 1999;18:305-12. [Medline:10230566](#)
- Richardson AB, Jobe FW, Collins HR. The shoulder in competitive swimming. *Am J Sports Med.* 1980;8:159-63. [Medline:7377446](#)
- Jerosch J, Castro WH, Drescher H, Assheuer J. Magnetic resonance morphologic changes in shoulder joints of

- world class water polo players [in German]. *Sportverletz Sportschaden*. 1993;7:109-14. [Medline:8273011](#)
- 26 Jobe CM. Superior glenoid impingement. *Orthop Clin North Am*. 1997;28:137-43. [Medline:9113710](#)
- 27 Jobe CM, Coen MJ, Screnar P. Evaluation of Impingement Syndromes in the Overhead-Throwing Athlete. *J Athl Train*. 2000;35:293-9. [Medline:16558643](#)
- 28 Cicak N, Klobucar H, Bicanic G, Trsek D. Arthroscopic extracapsular plication to treat multidirectional instability of the shoulder. *Arthroscopy*. 2005;21:1278. [Medline:16226669](#)
- 29 Meister K, Thesing J, Montgomery WJ, Indelicato PA, Waleczak S, Fontenot W. MR arthrography of partial thickness tears of the undersurface of the rotator cuff: an arthroscopic correlation. *Skeletal Radiol*. 2004;33:136-41. [Medline:14513293](#)
- 30 van Holsbeeck MT, Kolowich PA, Eyerl WR, Craig JG, Shirazi KK, Habra GK, et al. US depiction of partial-thickness tear of the rotator cuff. *Radiology*. 1995;197:443-6. [Medline:7480690](#)
- 31 Fukuda H. The management of partial-thickness tears of the rotator cuff. *J Bone Joint Surg Br*. 2003;85:3-11. [Medline:12585570](#)
- 32 Matava MJ, Purcell DB, Rudzki JR. Partial-thickness rotator cuff tears. *Am J Sports Med*. 2005;33:1405-17. [Medline:16127127](#)
- 33 Andrews JR, Carson WG, McLeod WD. Glenoid labrum tears related to the long head of the biceps. *Am J Sports Med*. 1985;13:337-41. [Medline:4051091](#)
- 34 Snyder SJ, Karzel RP, Del Pizzo W, Ferkel RD, Friedman MJ. SLAP lesions of the shoulder. *Arthroscopy*. 1990;6:274-9. [Medline:2264894](#)
- 35 Funk L, Snow M. SLAP tears of the glenoid labrum in contact athletes. *Clin J Sport Med*. 2007;17:1-4. [Medline:17303998](#)
- 36 Jones GL, Galluch DB. Clinical assessment of superior glenoid labral lesions: a systematic review. *Clin Orthop Relat Res*. 2007;455:45-51. [Medline:17279037](#)
- 37 Chandnani VP, Yeager TD, DeBerardino T, Christensen K, Gagliardi JA, Heitz DR, et al. Glenoid labral tears: prospective evaluation with MRI imaging, MR arthrography, and CT arthrography. *AJR Am J Roentgenol*. 1993;161:1229-35. [Medline:8249731](#)
- 38 Imhoff AB, Agneskirchner JD, Konig U, Temme C, Ottl G, McFarland EG. Superior labrum pathology in the athlete [in German]. *Orthopade*. 2000;29:917-27. [Medline:11142911](#)
- 39 Badia A, Stennett C. Sports-related injuries of the elbow. *J Hand Ther*. 2006;19:206-26. [Medline:16713868](#)
- 40 Cain EL, Dugas JR, Wolf RS, Andrews JR. Elbow injuries in throwing athletes: a current concepts review. *Am J Sports Med*. 2003;31:621-35. [Medline:12860556](#)
- 41 Chen FS, Rokito AS, Jobe FW. Medial elbow problems in the overhead-throwing athlete. *J Am Acad Orthop Surg*. 2001;9:99-113. [Medline:11281634](#)
- 42 Safran MR. Ulnar collateral ligament injury in the overhead athlete: diagnosis and treatment. *Clin Sports Med*. 2004;23:643-63. [Medline:15474227](#)
- 43 Purcell DB, Matava MJ, Wright RW. Ulnar collateral ligament reconstruction: a systematic review. *Clin Orthop Relat Res*. 2007;455:72-7. [Medline:17279038](#)
- 44 Eygendaal D, Safran MR. Postero-medial elbow problems in the adult athlete. *Br J Sports Med*. 2006;40:430-4. [Medline:16632574](#)
- 45 Moskal MJ. Arthroscopic treatment of posterior impingement of the elbow in athletes. *Clin Sports Med*. 2001;20:11-24. [Medline:11227699](#)
- 46 Bojanić I, Ivković A, Borić I. Arthroscopy and microfracture technique in the treatment of osteochondritis dissecans of the humeral capitellum: report of three adolescent gymnasts. *Knee Surg Sports Traumatol Arthrosc*. 2006;14:491-6. [Medline:16217674](#)
- 47 O'Holleran JD, Altchek DW. Elbow arthroscopy: treatment of the thrower's elbow. *Instr Course Lect*. 2006;55:95-107. [Medline:16958443](#)
- 48 Bilić R, Kolundžić R, Jelić M. Overuse injury syndromes of the hand, forearm and elbow [Article in Croatian]. *Arh Hig Rada Toksikol*. 2001;52:403-14. [Medline:11831123](#)
- 49 Rettig AC. Athletic injuries of the wrist and hand: part II: overuse injuries of the wrist and traumatic injuries to the hand. *Am J Sports Med*. 2004;32:262-73. [Medline:14754754](#)
- 50 Lapidus PW, Guidotti FP. Stenosing tenovaginitis of the wrist and fingers. *Clin Orthop Relat Res*. 1972;83:87-90. [Medline:5014835](#)
- 51 Wood MB, Dobyns JH. Sports-related extraarticular wrist syndromes. *Clin Orthop Relat Res*. 1986;(202):93-102. [Medline:3006958](#)
- 52 Hutchinson M, Tansey J. Sideline management of fractures. *Curr Sports Med Rep*. 2003;2:125-35. [Medline:12831651](#)
- 53 Rettig AC. Athletic injuries of the wrist and hand. Part I: traumatic injuries of the wrist. *Am J Sports Med*. 2003;31:1038-48. [Medline:14623677](#)
- 54 Amadio PC. Epidemiology of hand and wrist injuries in sports. *Hand Clin*. 1990;6:379-81. [Medline:2211850](#)
- 55 Lovell G. The diagnosis of chronic groin pain in athletes: a review of 189 cases. *Aust J Sci Med Sport*. 1995;27:76-9. [Medline:8599748](#)
- 56 Holmich P. Long-standing groin pain in sportspeople falls into three primary patterns, a "clinical entity" approach: a prospective study of 207 patients. *Br J Sports Med*. 2007;41:247-52. [Medline:17261557](#)
- 57 Moeller JL. Sportsman's hernia. *Curr Sports Med Rep*. 2007;6:111-4. [Medline:17376339](#)
- 58 Macintyre J, Johnson C, Schroeder EL. Groin pain in athletes. *Curr Sports Med Rep*. 2006;5:293-9. [Medline:17067496](#)
- 59 Kenal KA, Knapp LD. Rehabilitation of injuries in competitive swimmers. *Sports Med*. 1996;22:337-47. [Medline:8923651](#)
- 60 Pecina M. Injuries in downhill (alpine) skiing. *Croat Med J*. 2002;43:257-60. [Medline:12035129](#)
- 61 Jones JH. Swimming overuse injuries. *Phys Med Rehabil Clin N Am*. 1999;10:77-94. [Medline:10081054](#)