

SUICIDE BY FENTANYL*

Davorka SUTLOVIĆ and Marija DEFINIS-GOJANOVIĆ

Department of Pathology and Forensic Medicine, Split University Hospital and School of Medicine, Split, Croatia

Received in September 2006

Accepted in April 2007

Fentanyl is a potent, short-acting narcotic analgesic widely used as surgical anaesthetic. This article presents a case in which fentanyl was self-injected by a 41-year old nurse, an employee at the hospital emergency department, who was found dead at home. She had no known history of drug and alcohol abuse. Two syringes, one empty and one filled with a clear liquid, were found near the body, while a needle was stuck into her hand.

Toxicological analysis showed fentanyl poisoning. Fentanyl overdose was declared the cause of death and the manner of death was classified as suicide.

To our knowledge, death due to the intravenous injection of fentanyl has not previously been reported in Croatia.

KEY WORDS: *death, intravenous injection, toxicology*

Fentanyl, *N*-[1-(2-phenylethyl)-4-piperidinyl]-*N*-phenyl-propanamide (Figure 1), is a narcotic analgesic, which primarily binds to opioid μ -receptors, producing not only the analgesia for which it is primarily used but also sedation, euphoria, and at high doses, respiratory depression and death (1). It was introduced into medical practice in the 1960s as an intravenous anaesthetic under the trade name of Sublimaze (2). Fentanyl has an LD_{50} of 3.1 mg kg^{-1} in rats, and 0.03 mg kg^{-1} in monkeys.

Fentanyl overdose is classically associated with intravenous use of α -methylfentanyl and 3-methylfentanyl, a powder form that is chemically different from therapeutic fentanyl (3). Occasionally these fentanyl derivatives are sold as heroin and at other times they go by street monikers such as *synthetic heroin* and *China white*, which is the same term used for high-quality south-east Asian heroin (4). However, fentanyl overdose has also been reported in cases of excessive transdermal application and ingestion or inhalation of transdermal patches (5-8).

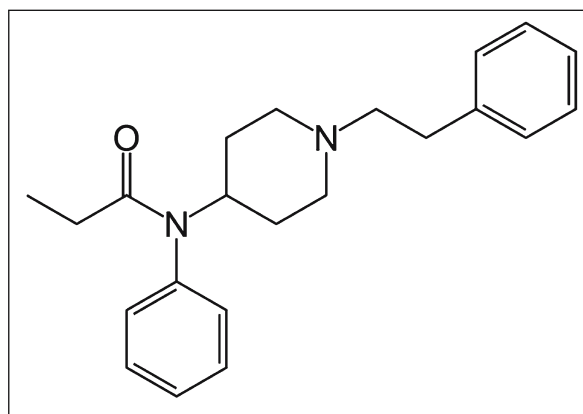


Figure 1 Fentanyl structural formula

The transdermal fentanyl system is designed to deliver a specific dose at a constant rate based on the initial concentration present in the patch. This delivery system effectively limits the peak versus trough concentration, which is a common problem associated with other routes of administration. We present a case in which a fatal dose of fentanyl was injected.

* Partly presented at the EUROTOX 2006/6 CTDC Congress, Cavtat, Croatia, 20-24 September 2006.

MATERIALS AND METHODS

Multiple samples were collected and stored at 4 °C until analysis in order to establish drug distribution. Samples were screened for ethanol, common drugs of abuse and other basic drugs. Quantification and confirmation analyses were performed by first isolating fentanyl by extraction of 1 mL g⁻¹ to 5 mL g⁻¹ specimen. Solid-phase extraction was performed using Amberlite XAD-2, polyaromatic adsorbent resin (Supelco; SIGMA ALDRICH, Taufkirchen, Germany) (9, 10).

Underivatized specimens were analysed using a Shimadzu GC-2010 mass spectrometer with ion trap (mass selective detector, MSD). The chromatographic column was RTX-5MS (5 % diphenyl - 95 % dimethyl polysiloxane, 30 m, and 0.25 mm i.d, with a film thick 0.25 μm). The initial column temperature of 90 °C was held for 3 min, then programmed to 270 °C at 20 °C min⁻¹, and held for 25 min. Ultra-pure grade helium was used as the carrier gas at a flow rate of about 1.5 mL min⁻¹. Quantification was performed using selective ion mode (SIM) with external standard curve prepared with fentanyl citrate 0.0785 mg mL⁻¹ (eq. to fentanyl 0.05 mg mL⁻¹). For fentanyl three ions were monitored m/z: 245, 146 and 189.

Blood-alcohol concentration (BAC) was measured using the Shimadzu GC-2010 with headspace and flame ionization detector (FID). Ter-Butanol was used as standard solution.

Case report

A 41-year old woman, employed as a nurse at the hospital emergency department, was found dead at home. She had a family, was well-situated, and had no psychological problems and previous suicidal attempts. She had no known history of drug and alcohol abuse. Two syringes, one empty and one filled with a clear liquid, were found near the body, while a needle was stuck into her hand.

Macroscopic and microscopic findings were unspecific and did not point to a certain precise cause of death.

Toxicological analysis showed fentanyl poisoning (Figure 2). Blood concentration of fentanyl was 540 μg L⁻¹; in stomach tissue mixed with blood it was 40 μg g⁻¹ and in urine 95 μg g⁻¹. Alcohol in blood and urine samples was not detected. The syringes and the needle found at the scene were positive for fentanyl. No other organic bases were detected, including other drugs of abuse such as opioids, cannabinoids, amphetamines, cocaine or hallucinogens.

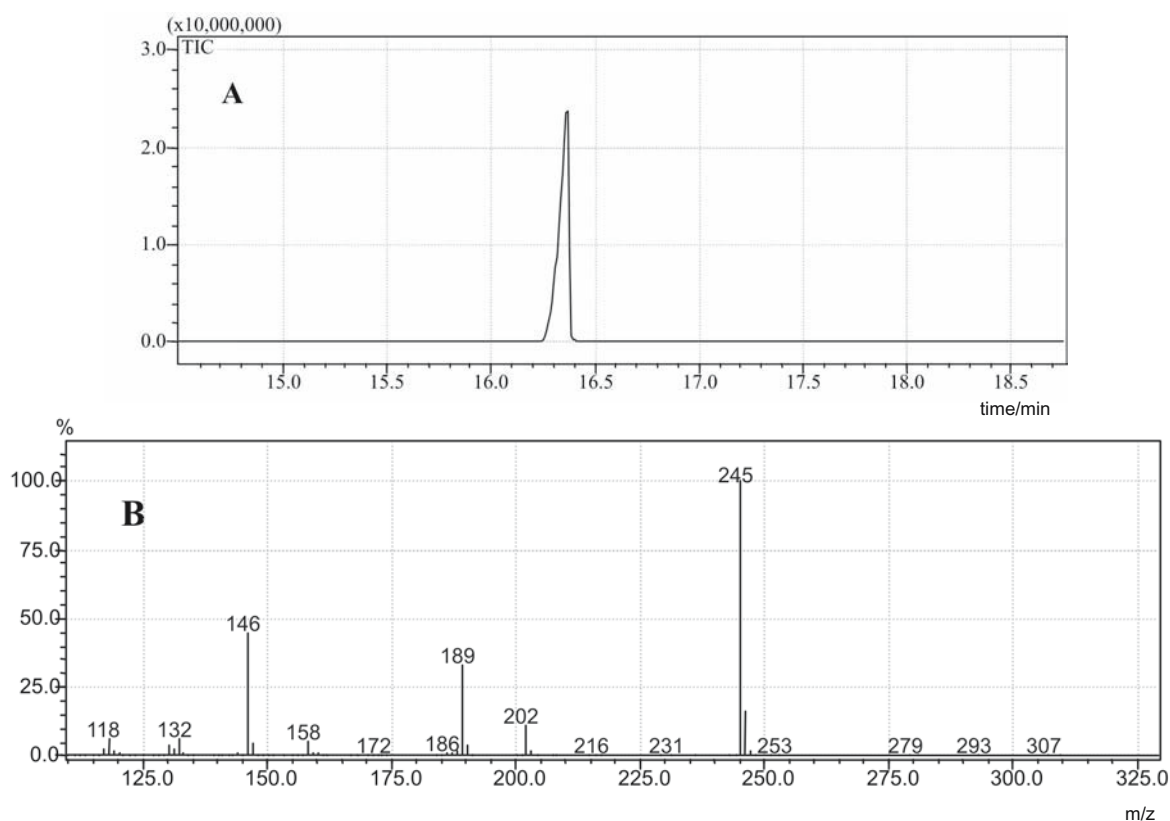


Figure 2 Selected ion chromatogram (A) and characteristic spectra of fentanyl (B)

The toxicological results and circumstantial evidences of the case indicate that the death resulted primarily from fentanyl overdose and the manner of death was classified as suicide.

DISCUSSION

To our knowledge, death due to intravenous injection of fentanyl has not yet been reported in Croatia. Developed by Janssen Pharmaceutica, fentanyl was originally introduced in the United States in 1968 for use as an intravenous analgesic-anaesthetic. Exposure may occur through the parenteral, oral, transmucosal, and dermal routes. Classical abuse of fentanyl has involved health care professionals who had access to the controlled drug. Since their introduction in 1990, transdermal fentanyl patches have been abused in a number of ways. Fentanyl is a potent analgesic. Intravenous or intramuscular fentanyl is used in the management of acute or post-surgical pain, as a component of balanced anaesthesia, or as preoperative analgesic in a hospital. As intravenous fentanyl is not readily available even in hospitals, it has lower poisoning incidence than transdermal fentanyl patches which are used for the treatment of chronic pain (4). Oral transmucosal fentanyl is used for acute pain in patients concurrently receiving transdermal therapy. Fentanyl and its derivatives have high dependence liability, and rapidly metabolise in the liver. About 70 % of a dose is excreted in the urine in 72 h, mostly as metabolites. The estimated minimum lethal dose is 2 mg (4).

Edinboro et al. reported a case of an 83-year-old female with terminal cancer who was found with a fatal level of fentanyl in her blood (25 g L^{-1}) after applying three patches to her chest (5). Arvanitis and Satonik described a case of a 38-year-old man who was found unresponsive on three separate occasions after chewing transdermal fentanyl patches (6). Tharp et al. presented four cases in which the source of fentanyl were transdermal patches, from which it

was extracted and then applied intravenously. In all these cases, the victims were white males who died at home (11). In all cases, fentanyl patches and needles with syringes were found at the scene, and there was physical evidence of intravenous injection on the body at the time of autopsy. It is very important to analyse all objects found at the crime scene. In our case, the results obtained from the syringes with needles instigated all other analyses.

Anderson and Muto analysed 25 deaths after transdermal fentanyl application (1). When fentanyl was not considered to be the cause of death, heart blood and liver tissue concentrations ranged from $<2.7 \text{ ng mL}^{-1}$ to 7 ng mL^{-1} (mean 3.6 ng mL^{-1}) and from 5.8 ng g^{-1} to 31 ng g^{-1} (mean 14.6 ng g^{-1}), respectively. When fentanyl was considered to be the cause of death, heart blood and liver tissue concentrations ranged from 16 ng mL^{-1} to 139 ng mL^{-1} (mean 50 ng mL^{-1}) and from 69 ng g^{-1} to 352 ng g^{-1} (mean 167 ng g^{-1}), respectively. The authors concluded that, in the case of transdermally delivered fentanyl, blood and liver tissue concentrations above 7 ng mL^{-1} and 69 ng g^{-1} , respectively, may indicate a fentanyl overdose. In our case, blood, stomach tissue mixed with blood and urine concentrations ranged from 40 ng mL^{-1} to 540 ng mL^{-1} (Table 1).

Although with pharmacological action similar to opiates, fentanyl has much different chemical structure and is not detected by standard narcotic screening tests. In the cases presented, it is highly improbable that intravenous abuse of fentanyl extracted from transdermal patches would have been considered or detected without thorough investigation of the scene and the decedent's history.

REFERENCES

1. Anderson DT, Muto JJ. Duragesic transdermal patch: postmortem tissue distribution of fentanyl in 25 cases. *J Anal Toxicol* 2000;24:627-34.
2. Answers.com [displayed 30 May 2007]. Available at <http://www.answers.com/topic/fentanyl>

Table 1 Fentanyl and its distribution in tissues

Sample	Fentanyl/ $\mu\text{g L}^{-1}$
Stomach tissue mixed with blood	40
Blood	540
Urine	95

3. Sternbach GL, Varon J. "Designer drugs": recognizing and managing their toxic effects. *Postgrad Med* 1992;91:169-76.
4. Smith FP. *Handbook of Forensic Drug Analysis*. Amsterdam: Elsevier Academic Press; 2005.
5. Edinboro LE, Poklis A, Trautman D, et al. Fatal fentanyl intoxication following excessive transdermal application. *J Forensic Sci* 1997;42:741-3.
6. Arvanitis ML, Satonik RC. Transdermal fentanyl abuse and misuse. *Am J Emerg Med* 2002;20:58-9.
7. Purucker M, Swann W. Potential for duragesic patch abuse. *Ann Emerg Med* 2000;35:314.
8. Marquardt KA, Tharratt RS. Inhalation abuse of fentanyl patch. *J Toxicol Clin Toxicol* 1994;32:75-8.
9. Gerhards P, Bons U, Sawazki J, Szigan J, Wertmann A. *GC/MS in Clinical Chemistry*. Weinheim: WILEY-VCH Verlag GmbH; 1999.
10. Moffa AC, Osselton MD, Widdop B. *Clarke's Analysis of Drugs and Poisons in Pharmaceuticals, Body Fluids and Postmortem Material*. 3rd ed. London: Pharmaceutical Press; 2004.
11. Tharp AM, Winecker RE and Winston DC. Fatal intravenous fentanyl abuse four cases involving extraction of fentanyl from transdermal patches. *Am J Forensic Med Pathol* 2004;25:178-81.

Sažetak

SAMOUBOJSTVO FENTANILOM

Fentanil je snažan narkotik u velikoj mjeri upotrebljavan kao anestetik pri kirurškim zahvatima. U ovom radu prikazan je slučaj samoubojstva upotrebom fentanila. 41-godišnja medicinska sestra, zaposlena u hitnoj službi pronađena je mrtva u svom stanu. Nije bilo podataka o njezinu zaživotnom uživanju alkohola niti drugih sredstava ovisnosti. Dvije šprice, jedna prazna i druga ispunjena prozirnom tekućinom, pronađene su kraj njezina tijela, dok je igla bila ubodena u njezinu ruku. Toksikološka analiza dala je pozitivan rezultat na fentanil. Uzrok smrti bio je predoziranje fentanilom u svrhu samoubojstva.

Prema našim saznanjima, ovo je prvi dokazani slučaj samoubojstva u Hrvatskoj koji je počinjen fentanilom.

KLJUČNE RIJEČI: *intravensko ubrizgavanje, smrt, toksikologija*

CORRESPONDING AUTHOR:

Davorka Sutlović
Department of Pathology and Forensic Medicine
Split University Hospital and School of Medicine
Spinčićeva 1, HR-21000 Split, Croatia
E-mail: dsutlou@kbsplit.hr