

Sandra Anić Milošević, Marina Lapter Varga, Mladen Šlaj

# Mogućnosti analize mekih tkiva u ortodontskoj dijagnostici

## *Possibilities of Soft Tissue Analysis in Orthodontics*

Sveučilište u Zagrebu Stomatološki fakultet, Zavod za ortodontciju  
*University of Zagreb, School of Dental Medicine, Department of Orthodontics*

### Sažetak

Nakon što je tridesetih godina prošlog stoljeća standardizirana rendgenkefalometrijska tehnika, važnost mekih tkiva došla je u drugi plan, a odlučujući čimbenik u analizi lica postali su dentoskeletni odnosi. Tek se početkom šezdesetih godina prošlog stoljeća počelo shvaćati da bi odnos između mekih tkiva i skeletalnih struktura mogao biti potpuno različit. Mnogobrojna istraživanja koja su se bavila psihološkim aspektom malokluzija pokazala su da se pacijenti ne bi trebali tretirati isključivo prema rigidnim dentoskeletalnim standardima. Ortodonti i maksilofacijalni kirurzi posljednjih godina tijekom planiranja terapije sve više promatraju meka tkiva te se oslanjaju više na kliničku sliku nego na kefalometrijsku analizu, s obzirom na to da isključivo oslanjanje na kefalometrijsku analizu ponekad može završiti neželjenim izgledom lica. U pregledu literature su radovi autora koji su se bavili proučavanjem i analizom mekih tkiva, utjecajem ortodontske terapije na meka tkiva te promjenama na mekim tkivima koje nastaju kao posljedica rasta i razvoja.

Zaprimljen: 8. svibnja 2006.  
Prihvaćen: 10. svibnja 2007.

### Adresa za dopisivanje

Dr. sc. Sandra Anić Milošević  
Sveučilište u Zagrebu  
Stomatološki fakultet  
Zavod za ortodontciju  
Gundulićeva 5, 10 000 Zagreb  
sanic@sfgz.hr

### Ključne riječi

ortodontcija; ortopantomogram

### Uvod

Skladan izgled lica, posebice donje trećine, te optimalna funkcionalna okluzija najvažnije su zadane uspješnoga ortodontskog tretmana. Sve nedavno korekcije su se temeljile na rendgenkefalometrijskoj analizi i uspostavljanju odgovarajuće okluzije između gornjih i donjih zubnih lukova. Standardne kefalometrijske vrijednosti i okluzijske norme pogrešno se prihvaćaju kao standard za prihvatljive proporcije lica (1), a sadašnji kriteriji za proporcije lica ne mogu se općenito primijeniti (2 - 5). Danas su dostupne mnogobrojne metode za procjenu facijalnih promjena i različitosti - antropometrija (6), fotogrametrija (7,8), kompjutorska simulacija (imaging) (9) i kefalometrija (10). Suвременa ortodontcija teži za što potpunijom dijagnostikom, u što je uključena i analiza mekih tkiva

### Introduction

A harmonious facial appearance, particularly of the lower third, and optimal functional occlusion represent the most important goals of successful orthodontic treatment. Until recently corrections were based on radiographic analysis and establishment of appropriate occlusion between the upper and lower dental arches. Standard cephalometric values and occlusive norms were mistakenly adopted as the standard for acceptable facial proportions (1), and the existing criteria for facial proportions are not generally applicable (2-5). Today many methods are available for evaluation of facial changes and diversity, including anthropometry (6), photogrammetry (7,8), computer imaging (9) and cephalometry (10). The goal of modern orthodontics is maximal comprehensive diagnosis, in which soft tissue analysis is

kojoj se posvećuje sve veća pozornost zbog znatnog utjecaja ortodontske terapije na profil mekih tkiva.

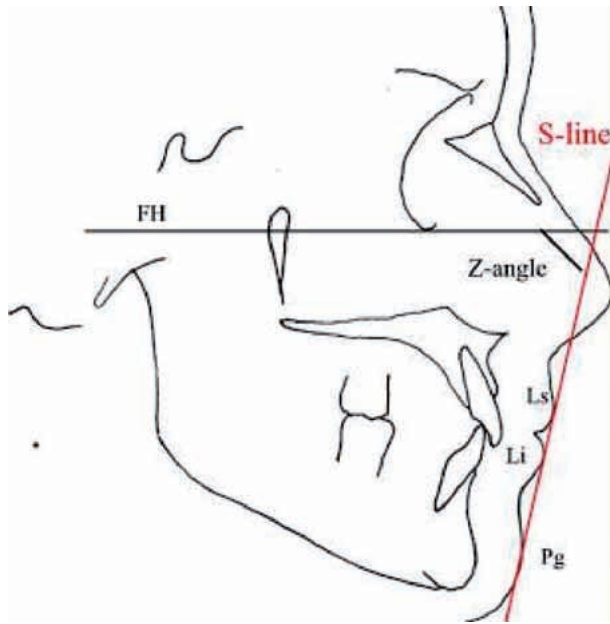
### Analize mekih tkiva - pregled literature

Camper je godine 1791. prvi znanstveno analizirao lice te predstavio "facijalni kut" koji je prema njemu i dobio ime (1). Nakon što su Broadbent i Hofrath godine 1931. standardizirali rendgenkefalometrijsku tehniku, važnost mekih tkiva našla se u drugom planu. Dentoskeletni odnosi postali su odlučujući čimbenik u analizi lica (11), jer se smatralo da su meka tkiva u vrlo uskoj vezi s konfiguracijom tvrdih tkiva. Osnovu za takvo razmišljanje postavio je Angle još davne godine 1907., prema kojoj sklad lica i oblik usana znatno ovise o okluziji, a gornja usna određuje zakrivljenost donje (12). Case (13), podupirući stajalište o povremenoj potrebi ekstrakcije zuba u ortodontskoj terapiji, pokušao je individualizirati terapiju te integrirati okluzalne i facijalne ciljeve. Downs (14) je počeo u kefalometrijska mjerenja uključivati i mjerenja na mekim tkivima, a koristio se filtrima u telerendgenografskoj tehnici, što je omogućilo vizualizaciju mekih tkiva. Svrha je bila dobiti informaciju o odnosu mekih i tvrdih tkiva, budući da neke anomalije tvrdih tkiva mogu biti prikrivene ili, pak, previše istaknute zbog različite debljine mekih tkiva. Downs je zaključio da meka tkiva ne prate uvijek dentoskeletni profil. Schwartz (15) je, pak, opisao kako bi trebao izgledati prosječan profil ("*Mittelwertprofil*"). Steiner (16) je povlačenjem linije od točke *pogonion* na mekom tkivu brade do točke "S" na polovici kolumele nosa, procjenjivao profil mekog tkiva (Slika 1.), ističući važnost analize jer uzima u obzir veličinu nosa i brade te ih usklađuje s usnama. Kod skladnog profila usne bi trebale dodirivati referentnu liniju. Burstone (17, 18) se bavio proučavanjem položaja usana u planiranju terapije. Njegova tzv. B-linija ide od točke *subnasale* do točke *pogonion* na mekom tkivu, te je zaključio da je gornja usna  $3,5 \pm 1,4$  mm, a donja usna  $2,2 \pm 1,6$  mm ispred Sn-Pg linije (Slika 2.). Položaj usana u odnosu prema Sn-Pg liniji vrlo je važan u analizi mekih tkiva. Pomaci zuba mijenjaju položaj usana u odnosu prema toj liniji te zbog toga i ukupan estetski dojam. Ekstrakcije bi se trebale izbjegavati u slučajevima ako bi se zbog retrakcije frontalnih zuba mogla dogoditi retrakcija usana, pa bi one bile smještene iza Sn-Pg linije. Legan i Burstone (10) ucrtavaju liniju kroz točku *subnasale* koja dodiruje točku *glabella* te liniju od *subnasale* do točke *pogonion*. Kut između tih dviju linija, ispod

included, which is given increasing importance because of the significant effect of orthodontic treatment on the soft tissue profile (2).

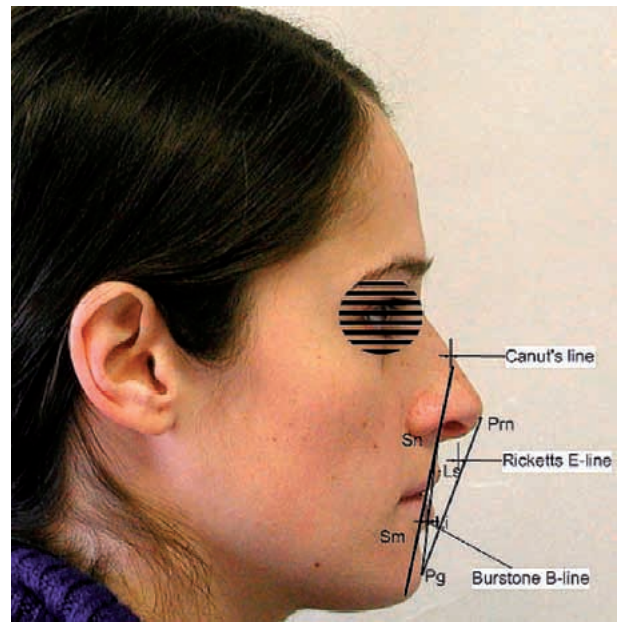
### Soft tissue analyses - a review of the literature

After Broadbent and Hofrath had standardised radiographic technique in 1931, the importance of soft tissues took second place in order of importance. Dentoskeletal relations became the decisive factor in facial analysis (11), as it was considered that soft tissues are very closely connected with the configuration of hard tissues. The basis of such an assumption was put forward by Angle many years ago in 1907, according to which facial harmony and the form of the lips depend to a large extent on occlusion, and the upper lip determines the distortion of the lower lip (12). Case (13), supporting the viewpoint of the occasional need for extraction of a tooth in orthodontic treatment, attempted to individualise the treatment plan and integrate occlusal and facial objectives. Downs (14) began to include measurement on soft tissues in cephalometric measurement, utilising filters in the teleroentgenographic technique, which enabled visualisation of the soft tissues. The purpose was to obtain the information on the relation of soft and hard tissues, since some anomalies of the hard tissues can be masked or even excessively emphasised because of the different thickness of soft tissues. Downs concluded that soft tissue does not always follow the dentoskeletal profile. Schwartz (15) described how the average profile should look ("*Mittelwertprofil*"). Steiner (16) evaluated soft tissue profile by drawing a line from the *pogonion* point on the soft tissue of the chin to the "S" point on half the column of the nose (Figure 1), stressing the importance of the analysis because it takes account of the size of the nose and chin and aligns them with the mouth. In a harmonious profile the lips should touch the reference line. Burstone (17,18) studied the position of the lips in treatment planning. His so-called B-line runs from the *subnasale* point to the *pogonion* point on the soft tissue and concludes that the upper lip is  $3.5 \pm 1.4$  mm and the lower lip  $2.2 \pm 1.6$  mm in front of the Sn-Pg line (Figure 2). The position of the lips in relation to the Sn-Pg line is of great importance in soft tissue analysis. Movements of the teeth change the position of the lips in relation to that line and consequently the total aesthetic impression as well. Extraction should be avoided in cases when retraction of the frontal teeth caused retraction of the lips, which would then be positioned behind the Sn-Pg line. Legan and Burstone (10) draw a line through the *sub-*



Slika 1. Merrifield Z-kut, Steiner S-pravac  
Figure 1 Merrifield's Z-angle; Steiner's S-line

točke *subnasale*, trebao bi iznositi  $11^\circ (\pm 4^\circ)$ . Ricketts (19, 20) je predložio potpuno nove načine analize mekih tkiva. Predstavio je estetsku, tzv. E-liniju koja dodiruje bradu i nos, a ide od vrha nosa do točke Pg (Slika 2.). Usne su ravnih obrisa, a kada su zatvorene ne bi trebale biti napete. U idealnom bi slučaju donja usna trebala biti dva milimetra iza E-linije, a gornja četiri milimetra iza nje kod ženskog spola, a kod muškoga te bi vrijednosti trebale biti malo veće zbog tanjih usana. Holdaway (21) opisuje analizu profila mekih tkiva uz pomoć H-linije (Ls-Pg) kojom određuje subnazalnu poziciju, poziciju gornjeg i donjeg labijalnog sulkusa te donje usne. Definirao je i prominenciju nosa i debljinu gornje usne u razini točke A i brade u visini točke *pogonion*. Holdaway dovodi u odnos kut koji čini H-linija i NB linija s ANB kutem. Ako je ANB kut od  $1$  do  $3^\circ$ , tada H-kut treba biti od  $7$  do  $8^\circ$ , donja usna dodiruje H-liniju, a vrh nosa je  $9$  mm ispred te referentne linije. Ako je ANB kut veći ili manji od  $1$  do  $3^\circ$ , za toliki broj stupnjeva povećava se ili smanjuje H-kut. Prema stajalištu Holdaway, u idealnom slučaju obje su usne smještene na H-liniji. Merrifield (22) je modificirao Holdawayevu H-liniju, koju je nazvao "profilna linija", povlačeći je od mekog tkiva *pogonion* do protrudiranije usne, češće gornje. Kut između "profilne linije" i Frankfurtske horizontale, tzv. Z-kut, kod odraslih iznosi  $90^\circ$  (Slika 1.). Mjerio je koštani dio brade smješten ispred NB-linije prema *pogonionu*, a na istom mjestu i po-



Slika 2. Najčešće spominjane linije na mekim tkivima  
Figure 2 The lines most frequently mentioned in the literature for linear measurement on soft tissues

*nasale* point which touches the *glabella* point and a line from the *subnasale* to the *pogonion* point. The angle between these two lines, under the *subnasale* point, should amount to  $11^\circ (\pm 4^\circ)$ . Ricketts (19,20) introduced a completely new method of soft tissue analysis. He introduced an aesthetic, so-called E-line, which touches the chin and nose, and goes from the tip of the nose to the Pg point (Figure 2). The lips are a straight contour, and when closed they should not be tense. Ideally the lower lip should be  $2$  mm and the upper  $4$  mm behind the E-line in women, and slightly higher in men because of thinner lips. Holdaway (21) described soft tissue profile analysis by means of the H-line (Ls-Pg), by which the subnasal position, position of the upper and lower labial sulcus and the lower lip can be determined. He also defined the prominence of the nose and thickness of the upper lip at the level of point A, and of the chin at the height of the *pogonion* point. Holdaway related the angle made by the H-line and the NB line with the ANB angle. If the ANB angle is  $1 - 3^\circ$ , then the H-angle should be  $7 - 8^\circ$ , the lower lip touches the H-line and the tip of the nose is  $9$  mm in front of the reference line. If the ANB angle is greater or smaller than  $1 - 3^\circ$ , the H-angle is increased or decreased by the same number of degrees. According to Holdaway, ideally both lips should be situated on the H-line. Merrifield (22) modified Holdaway's H-line, which he called the "profile line", drawing it from the soft tissue *pogonion* up to the protruding lip, most frequently the upper.

krovnna meka tkiva. Uočio je da koštani dio brade i njezin pokrov mekog tkiva individualno znatno variraju te zato ističe značenje sveukupne procjene područja brade, a ne samo koštanog dijela. Hambleton (23) je nakon mnogih istraživanja različitih metoda za analizu mekog tkiva istaknuo Holdawayev H-kut kao najkorisnije mjerenje, budući da se uzima u obzir i čvrsta podloga mekog tkiva u odnosu prema NB liniji i ANB kutu te zato što dodiruje gornju usnu, gdje ortodontska terapija ima najveći učinak. Muzj (24) se koristio analizom profila mekog tkiva koju je nazvao "Muzjev frontalni kut lica", a tvore ga dvije linije koje polaze od točke *subnasale* prema gore do *glabelle* i prema dolje do točke *gnathion*. Povukao je horizontalnu liniju koja povezuje točku *subnasale* i Boltonovu točku. Ona presijeca frontalni kut lica i određuje prednji ili stražnji položaj *gnathiona*. Canut (25) je predstavio analizu u kojoj se bavi međudnosima prominencije nosa, usana i brade glede Sn-Sm linije i dubinom nazolabijalnog sulka (Slika 2.). Naziva ju nazolabijalnom estetskom sigmom, a mjeri je između dviju okomitih linija na Frankfurtsku horizontalu, kroz Sn i Ls. U literaturi se još spominje i kao "Juanitova linija", prema Canutovu imenu Juan, a nalazi se i u nekim istraživanjima (25). Gonzales-Ulloa i Stevens (26) predstavili su tzv. liniju nultog meridijana - okomita je na Frankfurtsku horizontalu, a prolazi kroz točku *nasion* te mjeri poziciju brade. Prema njegovu mišljenju, kod profila koji se smatraju lijepima, brada bi trebala ležati na toj liniji.

Planiranje terapije isključivo na osnovi kefalometrijske dentoskeletne analize može završiti pogrešnom procjenom profila, posebice ako se pokušava predvidjeti izgled mekih tkiva isključivo na temelju normativnih vrijednosti tvrdih tkiva (21, 27, 28). Meka tkiva koja prekrivaju kosti mogu znatno varirati, pa kod procjene disharmonije lica dentoskeletni odnos nije adekvatan (10, 17, 18).

Neger (29) je spoznao da je dentoskeletna analiza nepotpuna. Istaknuo je kako meko tkivo ne prati uvijek promjene tvrdoga, i zato analizu mekog tkiva treba obavljati posebno, odvojeno od dentoskeletne analize.

Altemus (30, 31) vjeruje da su kraniofacijalni odnosi temelj prema kojem anatomi i antropolozi mogu klasificirati ljude u različite populacijske skupine. Uspoređivao je kefalometrijske odnose različitih populacijskih skupina te potvrdio kako profil mekog tkiva ne ovisi u cijelosti o tvrdim tkivima. Vig i Cohen (32) te Mamandras (33) ističu koliko je važna aktivnost mišića za područje donje treći-

The angle between the "profile line" and the Frankfurt horizontal, the so-called Z-angle, amounts to 90° in adults (Figure 1). He measured the bony part of the chin located in front of the NB-line towards the *pogonion*, and also the covering of soft tissue on the same site. He noticed that the bony part of the chin and its covering of soft tissue significantly individually differ and he therefore emphasised the importance of comprehensive evaluation of the area of the chin, and not only the bony part. After studying various methods of soft tissue analysis, Hambleton (23) concluded that Holdaway's H-angle was the most useful measurement, since it also takes into account the firm base of the soft tissue in relation to the NB line and ANB angle, and because it touches the upper lip, where orthodontic treatment has the greatest effect. Muzj (24) used soft tissue profile analysis which he called "Muzj's frontal facial angle", which consists of two lines which run from the *subnasale* point upwards to the *glabelle* and downwards to the *gnathion* point. He drew it in a horizontal line which connected the *subnasale* line and Bolton's point. It crosses the frontal facial angle and determines the anterior and posterior position of the *gnathion*. Canut (25) introduced an analysis which involves mutual relations of the prominence of the nose, lips and chin with regard to the Sn-Sm line and the depth of the nasolabial sulcus (Figure 2), which he called the nasolabial aesthetic sigma, and measured it between two vertical lines on the Frankfurt horizontal, through Sn and Ls. In the literature it is still referred to as the "Juanita line", after Canut's first name, Juan, and has been mentioned in some investigations (25). Gonzales-Ulloa and Stevens (26) showed the so-called line of zero meridian, which is vertical on the Frankfurt horizontal, crosses through the *nasion* point and measures the position of the chin. In their opinion, in a good-looking profile the chin should lie on that line.

The planning of treatment exclusively on the basis of cephalometric dentoskeletal analysis can lead to incorrect evaluation of the profile, particularly if an attempt is made to envisage the appearance of the soft tissues exclusively on the basis of normative values of the hard tissues (21,27,28). The soft tissues covering the bone can vary significantly and therefore the dentoskeletal relation is inadequate for evaluation of facial disharmony (10,17,18),

Neger (29) noticed the inadequacy of dentoskeletal analysis. He stressed that the soft tissue does not always follow the changes of the hard tissue and thus analysis of the soft tissue should be performed separately from dentoskeletal analysis.



ne lica kao bitan detalj u analizi mekih tkiva te kako treba obratiti pozornost na različite analize mekog tkiva zato što neke uključuju, a neke ne uključuju promjene u nazalnom području. Konveksitet profila u velikoj mjeri ovisi o promjenama mekog tkiva u području nosa. Naime, zapaženo je kako se u istraživanjima, u kojima neku varijablu čini točka *pronasale*, s rastom povećava i konveksitet lica, dok je u istraživanjima u kojima nije uključeno područje nosa, uočeno smanjenje konveksiteta.

### Analiza mekih tkiva na fotografijama

Usporedno s razvojem rentgenkefalometrije, razvija se i metoda linearne i angularne analize mekih tkiva profila na fotografijama.

Farkas (34) je standardizirao fotografsku tehniku i snimio ispitanike u dobi od 6 do 12 godina s glavom u prirodnom položaju. Zaključio je da su mjerenja na uzorku mladih Amerikanaca europskog podrijetla različita od neoklasičnih kanona koji su se dugo koristili kao norma za estetiku lica. Fernandez-Riveiro sa suradnicima (35, 36) proučavao je profile 50 ispitanika i 162 ispitanice metodom linearne i angularne fotogrametrijske analize. Svi su fotografirani s glavom u prirodnom položaju. Kod linearnih varijabli zaključili su kako u području usana, nosa i brade postoji spolni dimorfizam. Arnett i Bergman (37, 38) te Arnett i njegovi suradnici (39) opisuju analizu mekog tkiva profila na fotografijama snimljenima s glavom u prirodnoj poziciji. Vrlo je važna njihova horizontalna i vertikalna analiza simetrije, obris linije osmijeha, linije koje prolaze sredinom lica te obrisi lica. Kod linearnih mjerenja analizirali su položaj gornje i donje usne u odnosu prema Sn-Pg liniji (ranije spomenuta kod Burstonea), dužini gornje usne (Sn-Ls), dužini donje usne (Li-Me), vidljivosti gornjih inciziva u stanju mirovanja (1-5 mm) i interlabijalnom razmaku.

Altemus (30,31) believed that craniofacial relations are the basis by which anatomists and anthropologists can classify people into different population groups. He compared the cephalometric relations of different population groups and confirmed that the soft tissue profile does not depend entirely on the hard tissues. Vig and Cohen (32) and Mamandras (33) stress the importance of muscle activity in the area of the facial lower third as an important detail in soft tissue analysis and that attention should be paid to different analyses of soft tissue, because some include and others exclude changes in the nasal area. The convexity of the profile depends to a large extent on changes in the soft tissue in the area of the nose. Namely, in investigations where the *pronasale* point was a variable it was observed that with growth facial convexity increases, while in investigations where the area of the nose was not included, reduced convexity was observed.

### Soft tissue analysis on photographs

Parallel with the development of radiographic cephalometry a method was also developed of linear and angular soft tissue profile analysis on photographs.

Farkas (34) standardised photographic technique and photographed subjects aged from 6 to 12 years with the head in a natural position. He concluded that measurements on a sample of young Americans of European origin differed from neoclassical canons which were used for many years as the norms for facial aesthetics. Fernandez-Riveiro et al (35,36) studied the profiles of 50 male subjects and 162 female subjects by the method of linear and angular photogrammetric analysis. Subjects were photographed with the head in a natural position. For the linear variables they concluded that sexual dysmorphism existed in the area of the lips, nose and chin. Arnett and Bergman (37,38) and Arnett et al. (39) described soft tissue analysis of the facial profile on photographs taken with the head in a natural position. Their horizontal and vertical analysis of symmetry, smile line contour, the line which crosses through the midface and the facial contour are significant. For the linear measurements they analysed the position of the upper and lower lip in relation to the Sn-Pg line (previously known as Burstone), the length of the upper lip (Sn-Ls), length of the lower lip (Li-Me), visibility of the upper incisors while resting (1-5mm) and the interlabial gap.

## Promjene na mekim tkivima pod utjecajem rasta

Kako bi se predvidio odgovor mekog tkiva na promjene položaja tvrdog tkiva, nužno je razumjeti ponašanje mekog tkiva u odnosu prema ortodontskim i ortopedskim promjenama, te se mora uzeti u obzir i njihov rast i razvoj. Kod većine ortodontskih pacijenata terapija je gotova prije nego što je njihov rast završio (40 - 45), a dijagnoza se u većini slučajeva postavlja ne uzimajući u obzir i očekivani rast.

Prema istraživanjima Genecova i suradnika (40), kod obaju spolova u dobi od 7 do 13 godina, na mekim i tvrdim tkivima od točaka N-Sm, odnosno N-SNA, vidljiv je porast od 5 do 7 mm. Kod ispitanika od 11. godine do odrasle dobi uočen je rast mekih tkiva od 6 mm, dok kod ispitanica on iznosi 1 mm. Zato je, kod ispitanika u odrasloj dobi, profil u srednjoj trećini lica bio 3 do 4 mm duži nego kod ispitanica. Autori zaključuju da se većina promjena događa između 7. i 13. godine. Behrents (41) je istaknuo da se nakon 25. godine mijenja mali broj parametara te kako se nakon 20. godine povećava vertikalni smjer rasta, za razliku od horizontalnog smjera dominantnoga do te dobi. Također je uočio da se vrh nosa pomiče naprijed i dolje više nego *subnasale*, gornja usna ili točka A. Takav smjer rasta čini nos većim. Vrh nosa i *stomion* pomiču se vertikalno, a gornja se usna izdužuje pomičući se više prema dolje nego prema naprijed. Formby i suradnici (42) na ispitanicima odrasle dobi s dentalnom klasom I. primijetili da se kod obaju spolova povećava dimenzija nosa, a smanjuje debljina gornje usne, pa profil postaje ravniji, a obje usne retrudiranije. Debljina mekog tkiva brade kod muškaraca se povećava, a kod žena smanjuje, dok je s debljinom donje usne obrnuto. Kod muškaraca najveće promjene u mjerenju tvrdih tkiva zbivaju se do 25. godine, a promjene mekih tkiva nosa, usana i brade nastaju i nakon te dobi. Ferrario i suradnici (43) koristili su se metodom trodimenzionalne facijalne morfometrije. Zaključili su kako se s godinama kut konveksiteta lica ne mijenja, a totalni se facijalni konveksitet povećava zbog rasta nosa kod obaju spolova. Nazolabijalni kut smanjuje se kod obaju spolova, a mentolabijalni se povećava. Rast kod djevojčica gotovo je završen u dobi od 13 godina, dok kod dječaka u toj dobi počinje progresivniji rast, što je najuočljivije na srednjoj trećini lica (N-Sn) gdje je kod obaju spolova zapažen sličan iznos rasta sve do 13. godine, a nakon te dobi znatno je uočljiviji kod dječaka. Nanda i suradnici (44) zaključili su kako najveće promjene tijekom rasta nastaju u području nosa i usana. Tijekom rasta promjene mekog tkiva brade minimalne

## Soft tissue changes under the influence of growth

In order to envisage the response of the soft tissue to changes in the position of the hard tissue it is necessary to understand the behaviour of the soft tissue in relation to orthodontic and orthopaedic changes, and the growth and development of the same must be taken into account. In the majority of orthodontic patients treatment is finished before growth has been completed (40-45), and diagnosis in the majority of cases is made without taking into account the anticipated growth.

According to the investigations of Genecov et al. (40), in both sexes from the age of 7 to 13 years, growth of 5-7 mm is visible on both the soft and hard tissues from points N-Sm and N-SNA. In male subjects from the age of 11 years up to adulthood growth of the soft tissues of 6 mm is visible, while in female subjects it amounts to 1 mm. Thus, in the male subjects in adulthood the profile in the mid-facial third is 3-4 mm longer than in the female subjects. The authors conclude that the majority of changes occur between the 7th and 13th year of life. Behrents (41) concluded that after 25 years only a small number of parameters change and that after 20 years an increase in the vertical direction of growth occurs, in contrast to the horizontal direction, which is dominant up to the 20th year of life. He also observed that the tip of the nose moves towards the front and downwards more than *subnasale*, upper lip or A point. Such a direction of growth causes the nose to appear larger. The tip of the nose and *stomion* move vertically, while the upper lip elongates, moving more downwards than towards the front. In adult subjects with dental class I Formby et al. (42) observed that in both sexes the dimensions of the nose increased and the thickness of the upper lip decreased, causing the profile to appear flatter and both lips more retruded. The thickness of the soft tissue of the chin in men increased and in women decreased, while in the case of the thickness of the lower lip this was reversed. In men the greatest changes in measurement of hard tissues occurred up to the 25th year, and changes in the soft tissues of the nose, lips and chin occur after that age. Ferrario et al. (43) used a method of three-dimensional facial morphometry. He concluded that over the years the angle of facial convexity does not change, and that total facial convexity increases in both sexes because of growth of the nose. The nasolabial angle decreases in both sexes, while the mentolabial increases. Growth in girls is almost completed by the age of 13 years, while in boys at this age be-

su kod obaju spolova. No, skeletni rast mandibule na neki način kompenzira minimalne promjene debljine mekog tkiva brade. Rast dužine gornje usne gotovo je završen u dobi do 7 godina, što znači da se dijagnoza skraćene gornje usne može donijeti već u ranoj dobi. Naime, vertikalni rast gornje usne kod dječaka, ali i djevojčica, završava u dobi od 15 godina. Donja usna, pak, kontinuirano raste nakon 15. godine kod djevojčica te do 18. godine kod dječaka. Subtenly (45) je ustvrdio da profil mekih tkiva nije uvijek u pravilnom odnosu sa skeletnim profilom. Pokrovno tkivo brade i nosa može biti u dobrom odnosu, što ne mora vrijediti i za usne. Skeletni profil tijekom godina postaje manje konveksan, a povećava se konveksitet profila mekog tkiva. Zbog dužinskoga rasta, donja usna kod mlađih pacijenata jače je izražena u odnosu prema gornjoj. Povećanje konveksiteta profila mekog tkiva objašnjava se znatnijim povećanjem debljine mekog tkiva u području maksile nego što je to u području čela ili mandibule. Subtenly (46) smatra kako se, kao rezultat rasta, usne povećavaju u dužini i debljini sve do 15. godine, a vertikalni odnos do incizalnog brida konstantan je nakon kompletne erupcije gornjih i donjih centralnih inciziva. Hellman (47) je istaknuo da su promjene mekog tkiva lica tijekom rasta različite kod djevojčica i dječaka te najčešće nisu u sklopu standardnih vrijednosti. Kod djevojčica je meko tkivo stabilno ili se smanjuje, a kod dječaka se uglavnom smanjuje proporcionalno s rastom, odnosno povećanjem koštanih struktura. Blanchette i njegovi suradnici (29) prikazali su kako se debljina i dužina usana tijekom rasta razlikuje kod dolihokefala, odnosno brahikefala, te da i kod jednih i drugih postoji kompenzacija mekih tkiva.

## Zaključak

Dijagnoza, plan terapije i terapijski postupci, samo su sastavni dijelovi uspješne terapije malokluzije. Kako bi se odredila terapija, nužno je poznavati kraniofacijalni rast i utjecaj ortodontske terapije na meka tkiva. Istodobno s razvojem kefalometri-

gins more progressive growth, which is most noticeable in the mid-facial third (N-Sn) where in both sexes a similar amount of growth is visible up to 13 years, after which it is markedly more visible in boys. Nanda et al. (44) concluded that the greatest changes during growth take place in the area of the nose and mouth. In both sexes changes in the soft tissue of the chin during growth are minimal. However, skeletal growth of the mandible compensates to a certain extent the minimally changed thickness of the soft tissue of the chin. Growth of the length of the upper lip is almost completed by the age of 7 years, and consequently diagnosis of a shortened upper lip can be made at an early age. Namely, vertical growth of the upper lip in boys and in girls finishes at the age of 15 years. However, the lower lip shows continued growth after 15 years in girls and up to 18 years in boys. Subtenly (45) determined that the soft tissue profile is not always in symmetric relation with the skeletal profile. The covering tissue of the chin and nose can be in a symmetric relation, which is not necessarily the case for the lips. The skeletal profile becomes less convex over the years and the convexity of the soft tissue profile increases. As a result of the growth in length in younger patients the lower lip is more expressed in relation to the upper. Increase in convexity of the soft tissue profile is explained by the greater increase in thickness of the soft tissue in the area of the maxilla than in the area of the forehead or mandible. Subtenly (46) considered that as a result of growth the lips enlarge in length and thickness up to the age of 15 years, and the vertical relation up to the incisal ridge is constant after complete eruption of the upper and lower central incisors. Hellman (47) considers that changes in the soft tissue of the face during growth differ in girls and boys and are most frequently not within standard values. In girls the soft tissue is stable or decreases, while in boys it usually decreases proportionally with growth, i.e. with increase in bone structures. Blanchette et al. (29) showed that the thickness and length of the lips during growth differ in dolichocephaly, and brachycephaly, and that in both cases occurs compensation of the soft tissues.

## Conclusion

Diagnosis, treatment plan and treatment procedures are merely steps in the direction of successful treatment of malocclusion. In order to determine the treatment plan it is necessary to have knowledge of craniofacial growth and the effect of orthodontic

treatment on soft tissues. Parallel with the development of cephalometry, various analyses were also developed with the aim of qualitative and quantitative evaluation of profile aesthetics. Facial structures can be studied from the profile or frontally. Today, numerous methods are available for evaluation of facial changes and variations, including anthropometry, photogrammetry, computer imaging and cephalometry. The planning of treatment exclusively on the basis of cephalometric dentoskeletal analyses can lead to incorrect evaluation of the profile, particularly if an attempt is made to envisage the appearance of the soft tissues exclusively on the basis of normative values of hard tissues. The soft tissue covering the bones can vary significantly and thus the dentoskeletal relation is inadequate for evaluation of facial disharmony. Profiles differ with regard to skeletal convexity, protrusion of the lips and position of the lower incisors. Application of the standards for adult patients is inadequate for children and it is therefore necessary to examine the changes in soft tissues which occur during growth, with emphasis on the lower facial third. With knowledge of the normal values for soft tissues, the treatment plan can be directed so that analysis of the soft tissue is individualised, taking into account family and ethnic characteristics.

je, razvijene su i različite analize kako bi se s kvalitativno i kvantitativno procijenila estetika profila. Facijalne strukture moguće je proučavati iz profila ili frontalno. Danas su dostupne mnogobrojne metode za procjenu facijalnih promjena i različitosti - antropometrija, fotogrametrija, kompjutorska simulacija (imaging) i kefalometrija. Planiranje terapije isključivo na osnovi kefalometrijske dentoskeletne analize može završiti pogrešnom procjenom profila, posebice ako se pokušava predvidjeti izgled mekih tkiva isključivo na temelju normativnih vrijednosti tvrdih tkiva. Meka tkiva koja prekrivaju kosti mogu znatno varirati, pa dentoskeletni odnos nije adekvatan kod procjene disharmonije lica. Profili se razlikuju u skeletnom konveksitetu, protruziji usana i poziciji donjih inciziva. Primjena standarda odraslih pacijenata ne odgovara djeci te je zbog toga nužno istražiti promjene na mekim tkivima koje se događaju tijekom rasta, osobito na donjoj trećini lica. Ako znamo normalne vrijednosti za meka tkiva, plan terapije može biti usmjeren tako da individualizira analizu mekog tkiva, uzimajući u obzir obiteljske i etničke značajke.

#### Abstract

After standardisation of radiographic technique during the 1930s the importance of soft tissues were of secondary importance and dentoskeletal relations became the decisive factor in facial analysis. However, at the beginning the 1960s it was observed that the relation between soft tissues and skeletal structures could differ considerably. The many investigations engaged in the psychological aspect of malocclusion indicated that the patient should not be treated exclusively in accordance with rigid dentoskeletal standards. More recently, when planning therapy, orthodontists and maxillofacial surgeons increasingly consider the soft tissues and rely more on the clinical condition than on cephalometric analysis, in view of the fact that exclusive reliance on cephalometric analysis can occasionally lead to an undesired facial appearance. Through a review of the literature the investigations of authors has been presented who have been engaged in the study and analysis of soft tissues, influence of orthodontic treatment on soft tissues and changes in soft tissues which occur as a result of growth and development.

Received: May 8, 2006

Accepted: May 10, 2007

#### Address for correspondence

Sandra Anić Milošević  
University of Zagreb  
School of Dental Medicine  
Department of Orthodontics  
Gundulićeva 5  
HR-10000 Zagreb, Croatia  
sanic@sfzg.hr

#### Key words

Orthodontics, Corrective; Radiography, Dental

#### References

1. Brons R. Facial harmony. Standards for orthognatic surgery and orthodontics. London: Quintessence Publishing Co. Ltd; 1998.
2. McNamara JA, Brust EW, Riolo ML. Soft tissue evaluation of individuals with an ideal occlusion and well-balanced face. In: McNamara JA, editor. Esthetics and the treatment of facial form. Ann Arbor: Center for Human Growth and Development, University of Michigan; Craniofacial Growth Series. 1993;28:115-46.
3. McNamara JA Jr, Ellis E. Cephalometric analysis of untreated adults with ideal facial and occlusal relationships. Int J Adult Orthodon Orthognath Surg. 1988;3(4):221-31.
4. Casco JS, Shepherd WB. Dental and skeletal variation within the range normal. Angle Orthod. 1984;54(1):5-17.
5. Pogrel MA. What are normal esthetic values? J Oral Maxillofac Surg. 1991;49(9):963-9.
6. Farkas LG. Anthropometry of the head and face in medicine. New York: Elsevier North Holland Inc; 1981.
7. Gavan JA, Washburn SL, Lewis PH. Photography: an anthropometric tool. Am J Phys Anthropol. 1952;10(3):331-53.
8. Neger M. A quantitative method for the evaluation of the soft tissue facial profile. Am J Orthod Dentofacial Orthop. 1959;45(10):738-51.



9. Guess MB, Solzer WV. Computer treatment estimates in orthodontics and orthognathic surgery. *J Clin Orthod.* 1989;23(4):262-8.
10. Legan HL, Burstone CJ. Soft tissue cephalometric analysis for orthognathic surgery. *J Oral Surg.* 1980;38(10):744-51.
11. Steiner CC. Cephalometrics in clinical practice. *Angle Orthod.* 1959;29(1):8-29.
12. Angle EH. Treatment of malocclusion of the teeth. Philadelphia: S.S. White Dental Manufacturing Company; 1907.
13. Case CS. A question of extraction in orthodontia. *Am J Orthod.* 1964;50(1): 658-91.
14. Downs WB. Analysis of the dentofacial profile. *Angle Orthod.* 1956;26(1):191-212.
15. Schwartz AM. Die roentgenostatik. Innsbruck: Wien; 1958.
16. Steiner CC. The use of cephalometrics as an aid to planning and assessing orthodontic treatment. *Am J Orthod.* 1960;46(10):721-35.
17. Burstone CJ. The integumental contour and extension patterns. *Angle Orthod.* 1959(2);29:93-104.
18. Burstone CJ. Lip posture and its significance in treatment planning. *Am J Orthod.* 1967;53(4):262-84.
19. Ricketts RM. Esthetic, environment and the law of lip relation. *Am J Orthod.* 1968;54(4):272-89.
20. Ricketts RM. Perspectives in the clinical application of cephalometrics. *Angle Orthod.* 1981;51(2):115-50.
21. Holdaway RA. A soft-tissue cephalometric analysis and its use in orthodontic treatment planning. Part I. *Am J Orthod.* 1983;84(1):1-28.
22. Merrifield LL. The profile line as an aid in critically evaluating facial esthetics. *Am J Orthod.* 1966;52(11):804-22.
23. Hambleton RS. The soft tissue covering of the skeletal face as related to orthodontic problems. *Am J Orthod.* 1964;50(6):405-20.
24. Muzj E. Biometric correlations among organs of the facial profile. *Am J Orthod.* 1956;42:827-57.
25. Canut J. Un analisis estetico dentofacial. *Rev Esp Orthod.* 1996;26:13-30.
26. Gonzales-Ulloa M, Stevens E. The role of chin correction in profile plasty. *Plast Reconstr Surg.* 1961;36:364-73.
27. Wylie GA, Fish LC, Epker BN. Cephalometrics: a comparison of five analyses currently used in the diagnosis of dentofacial deformities. *Int J Adult Orthodon Orthognath Surg.* 1987;2(1):15-36.
28. Park YC, Burstone CJ. Soft-tissue profile--fallacies of hard-tissue standards in treatment planning. *Am J Orthod Dentofacial Orthop.* 1986;90(1):52-62.
29. Blanchette M, Nanda RS, Currier GF, Ghosh J, Nanda SK. A longitudinal cephalometric study of the soft tissue profile of short-and long-face syndromes from 7 to 17 years. *Am J Orthod Dentofacial Orthop.* 1996;109(2):116-31.
30. Altemus LA. Comparative integumental relationships. *Angle Orthod.* 1963;33:217-21.
31. Altemus LA. Cephalofacial relationships. *Angle Orthod.* 1968;38(3):175-84.
32. Vig PS, Cohen AM. Vertical growth of the lips: a serial cephalometric study. *Am J Orthod.* 1979;75(4):405-15.
33. Mamandras AH. Vertical growth of the lips in two dimensions: a serial cephalometric study. *Am J Orthod.* 1984;86:61-6.
34. Farkas LG, Hreczko TA, Kolar JC, Munro IR. Vertical and horizontal proportions of the face in young adult North American Caucasians: revision of neoclassical canons. *Plast Reconstr Surg.* 1985;75(3):328-38.
35. Fernández-Riveiro P, Suárez-Quintanilla D, Smyth-Chamosa E, Suárez-Cunqueiro M. Linear photogrammetric analysis of the soft tissue facial profile. *Am J Orthod Dentofacial Orthop.* 2002;122(1):59-66.
36. Fernández-Riveiro P, Smyth-Chamosa E, Suárez-Quintanilla D, Suárez-Cunqueiro M. Angular photogrammetric analysis of the soft tissue facial profile. *Eur J Orthod.* 2003;25(4):393-9.
37. Arnett GW, Bergman RT. Facial keys to orthodontic diagnosis and treatment planning-Part I. *Am J Orthod Dentofacial Orthop.* 1993;103(4):299-312.
38. Arnett GW, Bergman RT. Facial keys to orthodontic diagnosis and treatment planning-Part II. *Am J Orthod Dentofacial Orthop.* 1993;103(5):395-411.
39. Arnett GW, Jelic JS, Kim J, Cummings DR, Beress A, Worley CM et al. Soft tissue cephalometric analysis: diagnosis and treatment planning of dentofacial deformity. *Am J Orthod Dentofacial Orthop.* 1999;116(3):239-53.
40. Genecov JS, Sinclair PM, Dechow PC. Development of the nose and soft tissue profile. *Angle Orthod.* 1990;60(3):191-8.
41. Behrents RG. An atlas of growth in the aging craniofacial skeleton. Ann Arbor: Center for Human Growth and Development. University of Michigan; Craniofacial Growth Series Monograph 18:1985.
42. Formby WA, Nanda RS, Currier GF. Longitudinal changes in the adult facial profile. *Am J Orthod Dentofacial Orthop.* 1994;105(5):464-76.
43. Ferrario VF, Sforza C, Poggio CE, Schmitz JH. Soft-tissue facial morphometry from 6 years to adulthood: A three-dimensional growth study using a new modeling. *Plast Reconstr Surg.* 1999;103(3):768-78.
44. Nanda RS, Meng H, Kapila S, Goorhuis J. Growth changes in the soft tissue facial profile. *Angle Orthod.* 1990;60(3):177-90.
45. Subtenly JD. A longitudinal study of soft tissue facial structures and their profile characteristics, defined in relation to underlying skeletal structures. *Am J Orthod.* 1959;45:481-507.
46. Subtenly JD. The soft tissue profile, growth and treatment changes. *Angle Orthod.* 1961;31:105-22.
47. Hellman M. Some facial features and their orthodontic implications. *Am J Orthod Oral Surg.* 1939;25:927-51.