

Željko Verzak¹, Silvija Čuković-Čavka², Ivana Čuković-Bagić¹

Prikaz slučaja bulimijom inducirane dentalne erozije kod adolescentice

A Case Report of Bulimia Induced Dental Erosion in a Female Adolescent

¹ Zavod za pedodonciju Stomatološkog fakulteta Sveučilišta u Zagrebu
Department of Pedodontics School of Dental Medicine University of Zagreb

² Zavod za gastroenterologiju Klinike za unutarnje bolesti KBC-a Zagreb
Division of Gastroenterology Department of Internal Medicine University Hospital Rebro

Sažetak

Vrlo teški oblici dentalne erozije rijetki su u adolescentskoj populaciji. Ovaj rad opisuje 17-godišnju pacijenticu koja se žalila na pojačanu osjetljivost zuba na hladan podražaj i dodir. Stomatološkim kliničkim pregledom ustanovljene su teške promjene - dentalna erozija svih zuba, što je tipično za intrinzične čimbenike dentalne erozije. Pacijentica je također ispunila upitnik kako bi se povezali erozija i mogući etiološki čimbenici. Odgovori iz upitnika, heteroanamnestički podaci i dentalni status, potvrdili su preliminarnu dijagnozu bulimije nervoze koja je rezultirala, za tu dob, rijetkom dentalnom destrukcijom i to u razdoblju od samo tri godine.

Zaprimljen: 29. rujna 2006.
Prihvaćen: 12. veljače 2007.

Adresa za dopisivanje

Dr. sc. Željko Verzak
Sveučilište u Zagrebu
Stomatološki fakultet
Zavod za pedodonciju
Gundulićeva 5, 10 000 Zagreb
verzak@sfzg.hr

Ključne riječi

bulimia nervosa; dentalna erozija;
adolescent; žensko

Uvod

Bilo koji čimbenik s pH vrijednošću manjom od kritičnih pH 5,5, u dodiru s površinom zuba može ih erodirati. Smatra se da oko 40 posto erozija mogu biti posljedica intrinzičnih čimbenika, kao što su gastroezofagealni refluks, anoreksija, bulimija te povraćanje uzrokovano lijekovima ili neutvrđenim sistemskim bolestima. Među ekstrinzične čimbenike ubrajaju se zakiseljeni napitci i hrana te okolišni faktori, poput industrijskih onečišćenja. U velikom broju slučajeva i eksterni i interni čimbenici djeluju istodobno (1-5). Prevalencija bulimije nervoze je u porastu i u suvremenom je društvu među najčešćim javnozdravstvenim problemima. To je poremećaj prehrane, a obilježava ga prežderavanje i povraćanje,

Introduction

Any agent with a pH value less than 5.5 may cause erosion of tooth surface. About 40% of erosions may be due to intrinsic reasons, such as gastroesophageal reflux disease, anorexia, bulimia, vomiting due to medication or underlying systemic disease. Extrinsic reasons are acidic drinks and foodstuffs, and environmental factors, such as industrial fumes. In many cases both external and internal causes act concomitantly (1-5). The prevalence of bulimia nervosa has been increasing and is among the most common health problems in the contemporary society. Bulimia nervosa is an eating disorder characterized by bingeing and purging behaviour that affects a significant number of ado-

a javlja se kod znatnog broja adolescenata i mlađe odrasle populacije, ponajprije ženske (6,7). Bulimija je sindrom samoinduciranog gubitka tjelesne težine, a povezan je, osim uz fizičke i psihičke simptome, i s određenim dentalnim obilježjima. Točna etiologija toga poremećaja nije poznata, no čini se da genetski, kulturni i psihički čimbenici imaju posebnu ulogu (8,9). Medicinski tretman uključuje hospitalizaciju kako bi se pacijent stabilizirao, zatim promjenu navika te lijekove i psihoterapiju. Osobe s bulimijom u kratkom vremenskom razdoblju pojedu velike količine hrane s tisućama kalorija. Neposredno nakon toga oslobađaju se pojedenoga kako bi spriječile debljanje, dakle, prazne probavni trakt najmanje jedanput na dan. To se može učiniti tako da se poduzmu mjere koje reduciraju broj kalorija apsorbiranih tijekom prežderavanja (povraćanje neposredno nakon jela), ili one koje smanjuju napuhnutost (zlouporaba laksativa i diuretika). Prema dijagnostičkim i statističkim kriterijima, svako prežderavanje nužno prati osjećaj grizodušja i srama (10).

Takve nenormalne prehranbene navike, prouzročene čišćenjem organizma, mogu potaknuti medicinske komplikacije, kao što su disbalans tekućina i elektrolita te menstrualni poremećaji. Takvo često povraćanje može oštetiti sluznicu donjeg dijela jednjaka (11) te uzrokovati jake bolove i velika krvarenja. Unatoč tome što su te komplikacije teške pa ponekad zahtijevaju endoskopski zahvat zaustavljanja krvarenja, oštećenja jednjaka obično zacijele. Vrlo rijetko, moguće su teške komplikacije, kao što su perforacija jednjaka ili želuca (12). Osim toga, kod bulimije još su: povećani гастриčki kapacitet, smanjena гастриčna relaksacija, odgođeno gastrično pražnjenje, smanjeno otpuštanje kolecistokinina te poremećaji unutarnjih autonomnih funkcija. Medicinske komplikacije zbog restrikcije kalorija jesu kardiovaskularni, gastrointestinalni, bubrežni, hematološki, endokrini i neurološki poremećaji (6,8).

Bulimija može uzrokovati i ozbiljne dentalne komplikacije (14,15). Rana pojava teških oblika dentalne erozije potaknute bulimijom, vrlo je rijetka. Stomatolog praktičar ima važnu zadaću u identificiranju tog poremećaja, budući da je trošenje zuba česta klinička manifestacija zbog kiselog oralnog okruženja prouzročenog povraćanjem (14,16-18). Rano prepoznavanje tog entiteta i dobra prevencija, mogu smanjiti učinke bulimije na denticiju (19,20).

Svrha ovog prikaza slučaja jest opisati sedamnaestogodišnju adolescenticu s bulimijom, kod koje je bulimija u tri godine uzrokovala neobično teške destrukcije zuba.

lescents and young adults, primarily women (6,7). Bulimia is a self-induced weight loss syndrome associated with distinct dental manifestations involving physical and psychologic symptoms. The exact etiology of this eating disorder is unknown, but genetic, cultural, and psychiatric factors appear to play a specific role (8,9). Medical management may involve hospitalization to stabilize the patient, behavior modification, drugs, and psychotherapy. Bulimic individuals will consume large quantities of food and thousands of calories in short periods of time. Then, to rid themselves of the food and to prevent weight gain, they purge at least once a day. Purging can include measures that reduce the number of calories absorbed during a binge meal (vomiting after the binge) or measures that reduce bloating (laxative or diuretic abuse). To meet the Diagnostic and Statistical Manual IV criteria, every binge-eating episode must be followed by feelings of remorse and shame (10).

This abnormal eating pattern may cause many medical complications. Medical complications resulting from purging are: fluid and electrolyte imbalance and menstrual irregularities. Such recurrent vomiting also can lead to tears in the lining of the lower esophagus (11). These tears can cause severe pain and significant bleeding. Although this complication is severe, sometimes requiring endoscopy to stop the bleeding, the tears will usually heal. Sometimes, but rarely, serious complication is esophageal or gastric perforation (12). Reported gastrointestinal disturbances in bulimia include increased gastric capacity, diminished gastric relaxation, delayed gastric emptying, diminished release of cholecystokinin and abnormalities of enteric autonomic function (13). Medical complications from caloric restriction are cardiovascular, gastrointestinal, renal, hematologic, endocrine and neurologic disturbances (6,8).

Bulimia may cause serious dental complications (14,15). Early appearance of severe forms of dental erosion caused by bulimia nervosa is very rare. The dental practitioner has an important role in identifying this disorder since toothwear is very frequent clinical manifestation related to the acidic oral environment caused by vomiting (14,16-18). Early recognition of this manifestation and its good prevention can minimize the effects of bulimia on the dentition (19,20).

The purpose of this case report is to describe a 17 year old female adolescent with bulimia nervosa that resulted in unusually severe dental destruction over a 3-year period.

Prikaz slučaja

Sedamnaestogodišnja pacijentica javila se u Zavod tri godine nakon posljednjeg pregleda, žaleći se na osjetljive zube. Nakon analize dentalnih i medicinskih anamnestičkih podataka, nije pronađena nikakva bilješka ili zapis o bilo kakvim simptomima dentalne erozije, a ni o poremećajima prehrane. Kliničkim pregledom utvrđene su opsežne dentalne erozije površina svih zuba, te je pacijentica zamoljena da ispuni upitnik posebno oblikovan za pacijente s dentalnom erozijom. Prema odgovorima posumnjali smo da je u pitanju poremećaj praćen čestim povraćanjem. Gastroenterolog je ezofagogastroduodenoskopijom isključio patološki nalaz sluznice jednjaka, želuca i dvanaesnika (tumori ili gastroezofagealni refluks). S obzirom na rezultate analize ispunjenog upitnika o dentalnoj eroziji i negativan nalaz endoskopije gornjeg dijela probavnog trakta, posumnjali smo na bulimiju te smo dodatno, osim stomatološkog kliničkog pregleda, tražili i ortopantomogramsku snimku zuba.

Oralni nalaz i preporučena terapija

Pacijentica ima sve trajne zube (Slika 1.). Kliničkim pregledom ustanovljen je težak oblik dentalne erozije i to IV. stupnja prema Smith i Knight's Tooth Wear Indexu (TWI) na svim površinama - kako maksilarnih tako i mandibularnih zuba, osim na drugom gornjem desnom premolaru koji je opskrbljen keramičkom krunicom (Slika 2., Slika 3.). Svi ispuni, kompozitni i amalgamski, "izdignuti" su iznad strukture zuba, što je tipičan nalaz za erodirane zube (Slika 4., Slika 5.). Znatno su smanjene vertikalne dimenzije svih zuba, posebice u frontalnom segmentu, gdje je pronađen prednji otvoreni zagriz (Slika 6.). Neki maksilarni i mandibularni zubi imaju nove kariozne lezije. Kserostomije nema.

Nakon medicinske opservacije (specijalist internist-subspecijalist gastroenterolog) potvrđena je dijagnoza bulimije nervoze. Nalazi su potvrdili našu sumnju da je riječ o etiologiji poremećaja prehrane.

Navike vezane za oralnu higijenu i prehranu bile su tipične za pacijenta oboljeloga od bulimije. Inicijalno, stomatološki bi tretman trebao biti palijativan. Kiseli sadržaj tijekom povraćanja dodatno erodira caklinu i pojačava abraziju, osobito ako četkanje zuba slijedi odmah nakon povraćanja. Preporučuje se ispirati usta otopinom natrijeva bikarbonata ili magnezijevim hidroksidom, kako bi se neutralizirala kiselina. Uz to će caklinu remineralizirati otopina natrijeva fluorida neutralnog pH, te gelovi kositrenog fluorida. Rekonstrukcija kompozitnim

Case Report

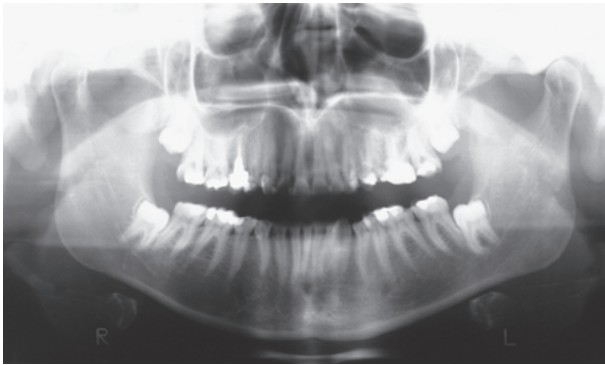
A 17-year old female patient came to our Department three years after last visit complaining of sensitive teeth. Analysing patient's former dental and medical history, we haven't found any records about any kind of eating disorders, as well as any records about any kind of dental erosion symptoms. Present oral examination revealed extensive dental erosion of all teeth surfaces, so the patient was asked to fill a questionnaire specially designed for patients with dental erosion. According to the patient's answers we suspected that the patient was suffering from vomiting. An upper endoscopy was performed by gastroenterologist to exclude some pathologic findings of the esophagus and stomach (tumors, gastroesophageal reflux disease). Regarding a dental erosion questionnaire evaluation and after negative upper endoscopy we suspected the problem was bulimia and made a clinical and radiological analysis.

Oral findings and proposed treatment

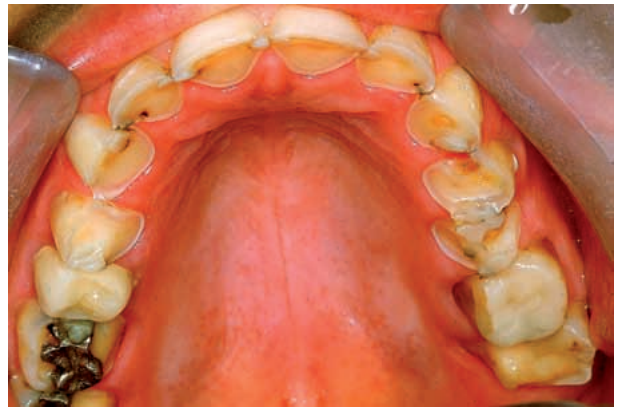The patient has all permanent teeth (Fig. 1). The clinical findings included severe form of dental erosion according to Smith and Knight's Tooth wear index (TWI) (4th degree) on all surfaces of both maxillary and mandibular teeth except the second upper right premolar which has ceramic crown (Fig. 2, Fig. 3). Both the composite and amalgam restorations are «raised» which is a typical finding for eroded teeth (Fig. 4, Fig. 5). Decreased vertical dimensions are visible, especially in frontal segment where there is an anterior open bite present (Fig. 6). Some of the maxillary and mandibular teeth have new carious lesions. Xerostomia is not present.

After medical observation (by an internal medicine specialist-gastroenterologist) a diagnosis of bulimia nervosa has been confirmed. The data confirmed our suspicion about eating disorder etiology of the clinical manifestation.

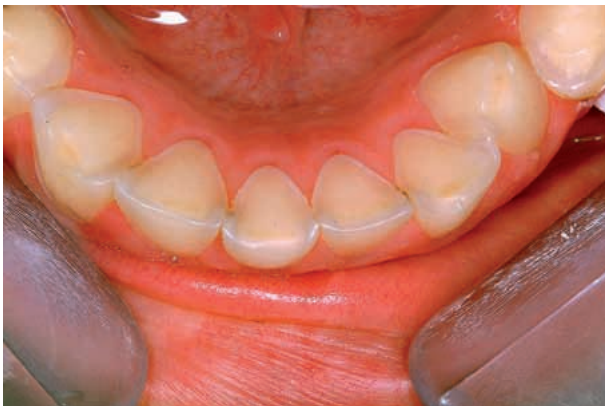Oral hygiene and dietary habits were typical for bulimic patient. Initially, dental treatment should be palliative. The acidic contents of the vomitus will further erode enamel and increased abrasion because of the weakness, especially if the action of toothbrushing succeeds immediately after such a vomiting episode. It has been recommended to rinse with sodium bicarbonate or magnesium hydroxide solution to neutralize the gastric acid. Additionally, use of neutral pH sodium fluoride rinses and stannous fluoride gels will promote remineraliza-



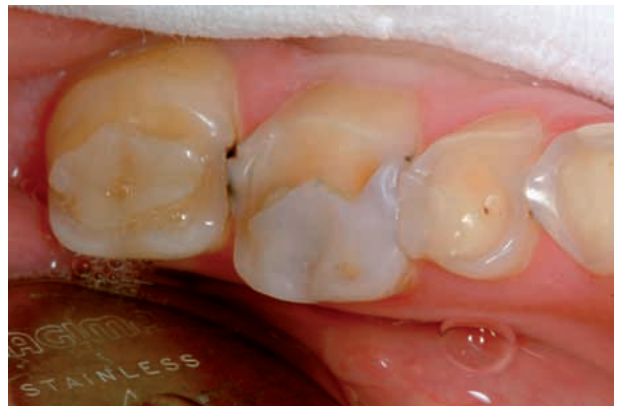Slika 1. Ortopantomogram pacijentice s bulimijom
Figure 1 Orthopantomogram of female bulimic patient



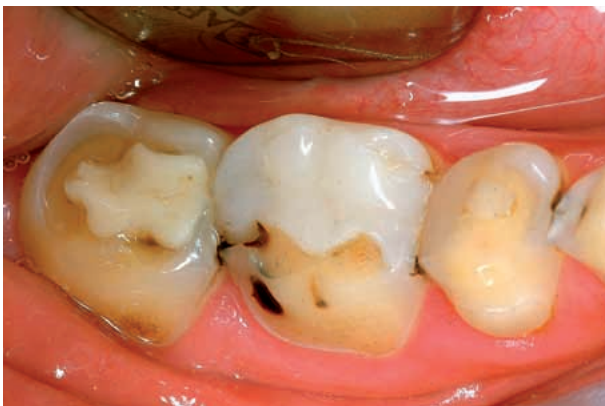Slika 2. Opsežna dentalna erozija gornjih zuba
Figure 2 Extensive dental erosion of maxillary teeth



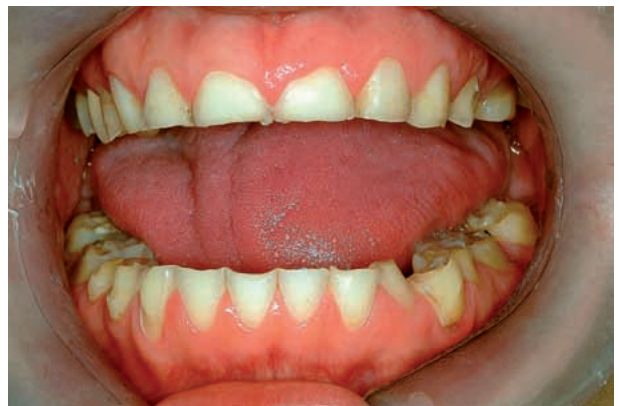Slika 3. Opsežna dentalna erozija donjih zuba
Figure 3 Extensive dental erosion of mandibular teeth



Slika 4. Izdignuti kompozitni ispuni gornjih zuba
Figure 4 Raised composite restorations of maxillary teeth



Slika 5. Izdignuti kompozitni ispuni donjih zuba
Figure 5 Raised composite restorations of mandibular teeth



Slika 6. Znatno smanjena vertikalna dimenzija zuba
Figure 6 Significantly decreased vertical dimension

materijalima može se primijeniti na zube s minimalnom erozijom ili one s dentinskom preosjetljivošću, a zubi s opsežnim erozijama cakline koje rezultiraju smanjenom vertikalnom dimenzijom okluzije te prednjim otvorenim zagrizom, zahtijevaju kompletno rekonstruiranje protetskim nadomjescima. Naža-

tion of the enamel. The resin composite restorations could be used to restore teeth with minimal erosion or dentin hypersensitivity as well as teeth with severe enamel erosion, resulting in a decreased vertical dimension of occlusion and an anterior open bite, may require complete-coverage crowns to re-

lost, naša pacijentica odbila je takvu terapiju te prihvatila samo desenzibilizaciju i uporabu tekućina za ispiranje usta. Očito će tek tada, kada bolest bude pod nadzorom, doći u obzir i definitivan stomatološki tretman koji će trebati prilagoditi potrebama mlade pacijentice.

Rasprava i zaključak

Više čimbenika, poput emocionalnog, obiteljskog i sociokulturalnog, pridonosi nastanku bulimije. Kako društvo ističe potrebu specifičnih navika prehrane i praćenja mode, mlade su osobe jako opterećene vitkošću te su sklone poremećajima prehrane (21). Dakle, psihološka komponenta poremećaja prehrane predstavlja kompleks različitih čimbenika. Kako poremećaj prehrane napreduje, tako i zdravstveno stanje pacijenta postaje ozbiljno, a čak mu može biti ugrožen i život.

Tijekom kliničkog pregleda pacijenta s bulimijom stomatolog može uočiti eroziju, "izdignute ispune", karijes, otečenu parotidnu žlijezdu, kserostomiju te lezije mekih tkiva (22,23). Kiseli sadržaj tijekom povraćanja erodira caklinu. Ta erozija glatkih površina najčešća je na nepčanim površinama maksilarnih zuba, pa se taj fenomen naziva perimoliza. Kako se struktura zuba gubi, amalgamski i kompozitni ispuni djeluju izdignuto, što se vidi i u našem prikazu slučaja. Čini se da razina karijesa, bilo da je u prihvatljivoj ili povećanoj mjeri, ovisi o prehrani, kvaliteti sline i njezinoj količini te kiselosti, oralnohigijenskim navikama i trajanju bulimičarskih navika dotičnog pacijenta (24-26).

Tretaman pacijenta s poremećajem prehrane počinje dijagnosticiranjem problema (27,28). Među djecom i adolescentima pedodont ima ulogu jednog od prvih promicatelja oralnog zdravlja koji može identificirati bulimiju. Kad se pacijent identificira, treba se uputiti na medicinsku i psihološku evaluaciju, a multidisciplinarni pristup tretmanu prijeko je potreban kako bi se uspješno zadovoljile mnoge potrebe pacijenta oboljelog od bulimije (29). Zapravo, treba ustrajati na prevenciji poremećaja prehrane koja bi se mogla obavljati kako u dječjim ordinacijama tako i na široj razini, u želji da se preveniraju ili postponiraju takve teške dentalne erozije kod mladeži, poput opisanog slučaja. Pedijatri edukacijom mogu pomoći obiteljima i djeci kako bi primijenili načela pravilne prehrane i fizičke aktivnosti te spriječili nezdrav utjecaj na tjelesnu težinu. Osim toga pedijatri i pedodonti mogu zajedno provoditi

store the dentition, or resin-bonded ceramic crowns, veneers, and etched metal onlays. Unfortunately, our patient refused such a therapy and accepted only desenzibilization of the teeth and mouth rinsing. Obviously, when the patient's eating disorder will be under control, definitive dental treatment could be provided and should be tailored to the needs of the young patient.

Discussion and Conclusion

Multiple factors, such as emotional, family and sociocultural, are believed to contribute to the development of bulimia. As society places increased emphasis on diet and fashion, young individuals obsessed with becoming thin are especially prone to develop eating disorders (21). So, the psychologic component of eating disorders is a complex of numerous factors. As the eating disorder progresses in duration and intensity, medical conditions are more likely to become serious or even life threatening.

During dental examination of a bulimic patient, a practitioner may find enamel erosion, „raised restorations“, caries, parotid gland swelling, xerostomia, and soft tissue lesions (22, 23). The acidic contents of the vomitus erode the enamel. This smooth-surface erosion is most commonly found on the palatal surfaces of maxillary anterior teeth and this phenomenon is well known as perimolysis. As surrounding tooth structure is lost, dental amalgam and composite restorations appear raised which is visible also in our case. It seems that the caries rate, is dependent on the diet, the salivary quality, quantity and pH, the oral hygiene habits and the binge-purging history of the bulimic patient (24-26).

Treatment of a patient with an eating disorder begins with the diagnosis of the problem (27, 28). Among the children and adolescents, a pedodontist is in the position to be one of the first health-care providers to identify a young bulimic patient. Once the patient is identified, he/she should be referred for medical and psychologic evaluation and a multidisciplinary approach to treatment is required (29). In fact, we should insist on the prevention of eating disorders which could take place in the pediatric practice as well as in the community setting, in order to prevent or postpone such severe dental erosion in young adolescents. Pediatricians can help families and children learn to apply the principles of proper nutrition and physical activity and to avoid unhealthy emphasis on weight and dieting. In addition, pediatricians and pedodontists together can implement screening strategies to detect the early

Ime i prezime • Name and surname: _____

Dob • Age: _____

Spol • Gender: Ž • F 1
 M • M 2

Status: učenik • pupil 1
 student 2
 zaposlen • employed 3
 nezaposlen • unemployed 4

I. dio • Part I:

- Znate li što je dentalna erozija (erozija zuba)? •
Do you know what dental erosion (tooth erosion) is? ne • no 1 da • yes 2
- Znate li koji su joj uzroci i kako nastaje? •
Do you know what are the causes of it and how it develops? ne • no 1 da • yes 2
- Primjećujete li na vašim zubima neke promjene?
(brzo trošenje zuba -“kraći” zubi, neravni i tanki grizni brid kod gornjih prednjih zuba)
Have you noticed any changes on your teeth
(rapid tooth wear – “shorter” teeth, uneven or thin biting surface of the upper front teeth)? ne • no 1 da • yes 2

II. dio • Part II:

- Pijete li svaki dan gazirana pića? •
Do you take carbonated drinks on a daily basis? ne • no 1 da • yes 2
- Pijete li svaki dan negazirane voćne napitke? •
Do you take non-carbonated fruit drinks on a daily basis? ne • no 1 da • yes 2
- Pijete li često športska energetska pića? •
Do you often take energy drinks? ne • no 1 da • yes 2
- Jedete li svaki dan svježe voće? •
Do you eat fresh fruit every day? ne • no 1 da • yes 2
- Sišete li agrume? •
Do you suck citrus fruits? ne • no 1 da • yes 2
- Jedete li jače zakiseljenu hranu? •
Do you eat more sour food? ne • no 1 da • yes 2
- Uzimate li redovito preparate C vitamina? •
Do you take vitamin C supplements on a regular basis? ne • no 1 da • yes 2
- Uzimate li tablete željeza? •
Do you take any iron supplement? ne • no 1 da • yes 2
- Stišćete li ili škrgućete zubima? •
Do you grind your teeth? ne • no 1 da • yes 2
- Bavite li se bazenskim športovima (plivanje, vaterpolo)? •
Are you active in a water pool sport (swimming, water-polo)? ne • no 1 da • yes 2

III. dio • Part III:

- Boli li vas često želudac? •
Do you often have stomachache? ne • no 1 da • yes 2
- Budite li se s kiselim okusom u ustima? •
Do you wake up with a sour taste in your mouth? ne • no 1 da • yes 2
- Imate li refluks (vraćanje hrane iz želuca u usta)? •
Do you have reflux (i.e. the liquid content of the stomach regurgitates
or backs up into the oesophagus)? ne • no 1 da • yes 2
- Imate li žgaravicu? •
Do you have heartburn (acid indigestion)? ne • no 1 da • yes 2
- Povraćate li često? •
Do you throw up often? ne • no 1 da • yes 2
- Ruminirate li (vraćanje hrane iz želuca u usta, ponovno žvakanje i gutanje istog zalogaja)? •
Do you ruminate (i.e. the contents of the stomach are drawn back up into the mouth,
chewed for a second time and swallowed again)? ne • no 1 da • yes 2

Slika 7. Upitnik za dentalnu eroziju
Figure 7 Questionnaire for dental erosion

«screening strategije» kako bi rano prepoznali poremećaj prehrane i kako ne bi previdjeli prve znakove koji služe kao precipitanti za nastanak poremećaja prehrane. Između različitih «screening strategija» vrlo koristan može biti upitnik, kao što je to bio slučaj kod naše pacijentice (Slika 7) ili nekoga sličnog. Šira se zajednica slaže da će biti nužne promjene u kulturalnim pristupima težini i prehrani, kako bi se smanjio sve veći broj djece i adolescenata s poremećajima prehrane.

I na kraju, ovaj prikaz slučaja adolescentice s bulimijom pokazuje da kronična regurgitacija, kao posljedica ponašanja tipičnog za bulimiju, uzrokuje u određenom vremenskom razdoblju znatnu eroziju cakline. Ako ne prepoznamo i ne liječimo psihološki problem koji je u podlozi te bolesti, pacijentovo opće i oralno zdravlje pogoršavat će se proporcionalno napredovanju poremećaja prehrane. Izgled zuba pacijenta s bulimijom mora potaknuti stomatologa da provjeri njegove prehrambene navike, te utvrdi je li mu potreban multidisciplinarni pristup (14,16,30,31). Oblici skrbi obuhvaćaju medicinski i nutricionistički aspekt te suradnju sa stručnjacima – psihijatrima, kako bi se postigli psihosocijalni i psihijatrijski učinci liječenja. Većinu djece i adolescenata s poremećajima prehrane ambulantno treba pratiti multidisciplinarni tim koji koordinira pedijatar ili subspecialist odgovarajuće specijalnosti za skrb djece i adolescenata s poremećajima prehrane (6,28).

onset of an eating disorder and be careful to avoid seemingly innocuous statements that can sometimes serve as the precipitant for the onset of an eating disorder. Implementation of a questionnaire as used in this case (Fig. 7) could be very useful among various screening strategies. At the community level, there is a general agreement that changes in the cultural approaches to weight and dieting issues will be required to decrease the growing numbers of children and adolescents with eating disorders.

In conclusion, this case report of a bulimic adolescent shows that the chronic regurgitation resulting from bingeing-purging behaviour (typical for bulimics) causes significant enamel erosion over time. Without identification and treatment of the underlying psychologic problem, a patient's medical and dental health will deteriorate as the eating disorder progresses. The dentition of a bulimic patient provides several clues to alert an observant practitioner to the patient's habit and the need to refer the patient for proper treatment by a multidisciplinary team (14, 16, 30, 31). The aspects of care include medical and nutritional management and coordination with mental health personnel in provision of the psychosocial and psychiatric aspects of care. Most children and adolescents with eating disorders will be managed in an outpatient setting by a multidisciplinary team coordinated by a pediatrician or subspecialist with appropriate expertise in the care of children and adolescents with eating disorders (6, 28).

Abstract

Very severe forms of dental erosion are uncommon finding in adolescent population. This paper describes a 17-year old female who complained of increased teeth sensitivity to cold temperature and to touch. Dental examination revealed extensive and severe pattern of dental erosion of all teeth typical for intrinsic causes of dental erosion. She also completed a questionnaire investigating any association between the presence of erosion and possible etiological factors. Questionnaire responses, heteroanamnestic data and dental status confirmed our preliminary diagnosis of bulimia nervosa that resulted in a rarely significant dental destruction for that age in only three years period.

Received: September 29, 2006

Accepted: February 12, 2007

Address for correspondence

Željko Verzak, DDS, PhD
University of Zagreb
School of Dental Medicine
Department of Pedodontics
Gundulićeva 5
10 000 Zagreb, Croatia
verzak@sfzg.hr

Key words

Bulimia Nervosa; Tooth Erosion;
Adolescent; Female

References

1. Ali DA, Brown RS, Rodriguez LO, Moody EL, Nasr MF. Dental erosion caused by silent gastroesophageal reflux disease. *J Am Dent Assoc.* 2002;133(6):734-7.
2. Munoz JV, Herreros B, Sanchiz V. Dental and periodontal lesions in patients with gastro-esophageal reflux disease. *Dig Liver Dis.* 2003;35(7):461-7.
3. Dahshan A, Patel H, Delaney J, Wuerth A, Thomas R, Tolia V. Gastroesophageal reflux disease and dental erosion in children. *J Pediatr.* 2002;140(4):474-8.
4. Schroeder PL, Filler SJ, Ramirez B. Dental erosion and acid reflux disease. *Ann Intern Med.* 1995;122(11):809-15.
5. Meurman JH. Pathology and etiology of dental erosions.

- EJPD. 2000;1(3):110-1.
6. McGilley BM, Pryor TL. Assessment and treatment of bulimia nervosa. *Am Fam Physician*. 1998;57(11):2743-50.
 7. Studen-Pavlovich D, Elliott MA. Eating disorders in women's oral health. *Dent Clin North Am*. 2001;45(3):491-511.
 8. Comerici GD. Medical complications of anorexia nervosa and bulimia nervosa. *Med Clin North Am*. 1990;74(5):1293-310.
 9. Gurenlian JR. Eating disorders. *J Dent Hyg*. 2002;76(3):219-34.
 10. American Psychiatric Association. Practice Guideline for the treatment of patients with eating disorders. 2nd edn. Washington DC: American Psychiatric Association; 2000.
 11. Mendell DA, Logemann JA. Bulimia and swallowing: cause for concern. *Int J Eat Disord*. 2001;30(3):252-8.
 12. Abdu RA, Garritano D, Culver O. Acute gastric necrosis in anorexia nervosa and bulimia. Two case reports. *Arch Surg*. 1987;122(7):830-2.
 13. Hadley SJ, Walsh BT. Gastrointestinal disturbances in anorexia nervosa and bulimia nervosa. *Curr Drug Targets CNS Neurol Disord*. 2003;2(1):1-9.
 14. Woodmansey KF. Recognition of bulimia nervosa in dental patients: implications for dental care providers. *Gen Dent*. 2000;48(1):48-52.
 15. Little JW. Eating disorders: dental implications. *Oral Surg Oral Med Oral Pathol Oral Radiol Endod*. 2002;93(2):138-43.
 16. Mueller JA. Eating disorders: identification and intervention. *J Contemp Dent Pract*. 2001;2(2):98.
 17. Young WG. The oral medicine of tooth wear. *Aust Dent J*. 2001;46(4):236-50.
 18. Hetherington MM. Eating disorders: diagnosis, etiology, and prevention. *Nutrition*. 2000;16(7-8):547-51.
 19. Sundaram G, Bartlett D. Preventative measures for bulimic patients with dental erosion. *Eur J Prosthodont Restor Dent*. 2001;9(1):25-9.
 20. Valena V, Young WG. Dental erosion patterns from intrinsic acid regurgitation and vomiting. *Aust Dent J*. 2002;47(2):106-15.
 21. Burns JJ, Stanton B, Perkins K, Pack R, Hobby-Burns L. Eating disorders in adolescents. *W V Med J*. 2003;99(2):60-6.
 22. Jahn M. Dental wear as a stomatologic manifestation of bulimia nervosa - a clinical case. *Fogorv Sz*. 2003;96(2):71-3.
 23. de Moor RJ. Eating disorder-induced dental complications: a case report. *J Oral Rehabil*. 2004;31(7):725-32.
 24. Abrahamsen TC. The worn dentition--pathognomonic patterns of abrasion and erosion. *Int Dent J*. 2005;55(4 Suppl 1):268-76.
 25. Stich H. Erosion. Clinical aspects – diagnosis – risk factors – prevention – therapy. *Schweiz Monatsschr Zahnmed*. 2005;115(10):917-46.
 26. Touger-Decker R. Eating disorders: detection and referral – the role of the dental professional. *Quintessence Int*. 2006;37(3):199-201.
 27. Paszynska E, Limanowska-Shaw H, Slopian A, Rajewski A. Evaluation of oral health in bulimia nervosa. *Psychiatr Pol*. 2006;40(1):109-18.
 28. Ebeling H, Tapanainen P, Joutsenoja A, Koskinen M, Morin-Papunen L, Jarvi L et al. A practice guideline for treatment of eating disorders in children and adolescents. *Ann Med*. 2003;35(7):488-501.
 29. Christensen GJ. Oral care for patients with bulimia. *J Am Dent Assoc*. 2002;133(12):1689-91.
 30. Kavoura V, Kourtis SG, Zoidis P, Andritsakis DP, Doukoudakis A. Full-mouth rehabilitation of a patient with bulimia nervosa. A case report. *Quintessence Int*. 2005;36(7-8):501-10.
 31. Bonilla ED, Luna O. Oral rehabilitation of a bulimic patient: a case report. *Quintessence Int*. 2001;32(6):469-75.