

## SENTIMAG SENTINEL LYMPH NODE BIOPSY IN BREAST CONSERVATIVE SURGERY – PRELIMINARY RESULTS

ILIJA GUTEŠA, IVANA POTESAK, IVANA PAVIČIĆ, GORDAN TOMETIĆ, IVA KIRAC,  
IVAN PENAVIĆ, IVAN MILAS and MLADEN STANEC

Department of Surgical Oncology, University Hospital for Tumors,  
University Hospital Center Sestre milosrdnice, Zagreb

---

### Summary

Segmentectomy and sentinel lymph node biopsy is a golden standard for early breast cancer (clinical and radiological cT1-2, c N0). Recently, superparamagnetic iron oxide (SPIO) nanoparticle tracer has been introduced enabling intraoperative tracer injection. We prospectively recorded data on tumor histology, marked lymph nodes and their final histology and patient characteristics for early breast cancer patients who underwent breast conservative surgery. At 128 female breast cancer patients underwent sentinel lymph node biopsy by SentiMag. Three patients were excluded from further analysis because the postoperative pathology report was ductal carcinoma in situ (DCIS). The identification rate was 95.2 % (119 of 125). Of the 19.2 % (24 of 125) patients with lymph node involvement, 1.6% (2 of 125) had micrometastasis, and 1 % (1 of 125) had single tumor cells within the sentinel, 1 at least a micrometastasis. Of 30 positive lymph nodes removed, 24 (80 %) were true sentinel nodes. The average lymph node retrieval rate was 2.3 nodes per patient. SentiMag's performance was comparable to published data and to standard sentinel with blue patent dye and/or technetium. The benefit of easier application and logistics is a great advantage.

KEY WORDS: *SentiMag*, *Sienna*+®, *superparamagnetic iron oxide*, *early breast cancer*

### SENTIMAG BIOPSIJA LIMFNOG ČVORA STRAŽARA U KONZERVATIVNOJ KIRURGIJI DOJKE – PRELIMINARNI REZULTATI

#### Sažetak

Segmentektomija i biopsija limfnog čvora stražara zlatni su standard za kirurško liječenje ranog raka dojke (klinički i radiološki cT1-2,c N0). Čestice superparamagnetskog željeznog oksida (*superparamagnetic iron oxide*, SPIO) od nedavno se koriste kao unutaroperacijski nanočestični obilježivač. Prospektivno smo bilježili demografske podatke o bolesnicama, histologiju tumora te označenih i neoznačenih limfnih čvorova. U 128 bolesnica učinjena je biopsija limfnog čvora stražara u aksili detektorom SentiMag. Tri bolesnice su isključene, jer je konačan patohistoloski nalaz bio *carcinoma ductale in situ* (DCIS). Limfni čvor je pronađen u 119 od 125 bolesnica (95.2%), pozitivne limfne čvorove su imale 24 (19.2%), makrometastaze 2 (1.6%) i mikrometastaze 1 bolesnica (0.08%). Od 30 pozitivnih odstranjenih limfnih čvorova, obilježenih je bilo 24 (80 %). Prosječno su po bolesnici izvađena 2.3 limfna čvora. Mogućnost otkrivanja limfnog čvora stražara SentiMagom usporediva je s dosad objavljenim podacima i zlatnim standardom. Prednosti metode su lakše rukovanje i minimalna logistika.

KLJUČNE RIJEČI: *SentiMag*, *Sienna*+®, *superparamagnetski željezni oksid*, *rani rak dojke*

---

### INTRODUCTION

Sentinel node biopsy is the standard of care for staging of early breast cancer (1). Sentinel lymph

node biopsy is accepted as the final surgical procedure in the axilla when the sentinel node (SN) is proven negative and sometime even in the presence of metastases (2). Moreover, neoadjuvant

breast cancer treatment indications require more sentinel lymph node biopsies (3). At our Institution we surgically treat over 800 newly diagnosed breast cancer patients annually. Due to well organized One Day clinic a significant number of patients is diagnosed with early breast cancer (4). Nuclear medicine division is dislocated and this proved to complicate the standard isotope based sentinel lymph node biopsy procedure. Therefore, we welcomed the emergence of superparamagnetic iron oxyde (SPIO) nanoparticle tracer in clinical use backed with The SentiMag Multicentre Trial (5), The Nordic SentiMag Trial (6) and The Central European SentiMag study (7). In this paper, we analyzed our initial experience with the method.

## METHODS

Early breast cancer patients are defined as T1-2 axillary lymph node negative tumors on imaging (either ultrasound or magnetic resonance imaging), with primary tumor confirmed by cytology or core biopsy. Exclusion criteria were prior breast surgery or irradiation of breast and/or axillary region. Patients hypersensitive to iron products or dextrate were excluded as well as patients suffering of diseases with iron overload. Sienna+® suspension (2 ml) is applied subcutaneously under nipple areola complex followed by 5 minutes of massage to the injection area. We performed the entire sequence when patient is already under anesthesia due to potential discomfort. There is a 20 minutes

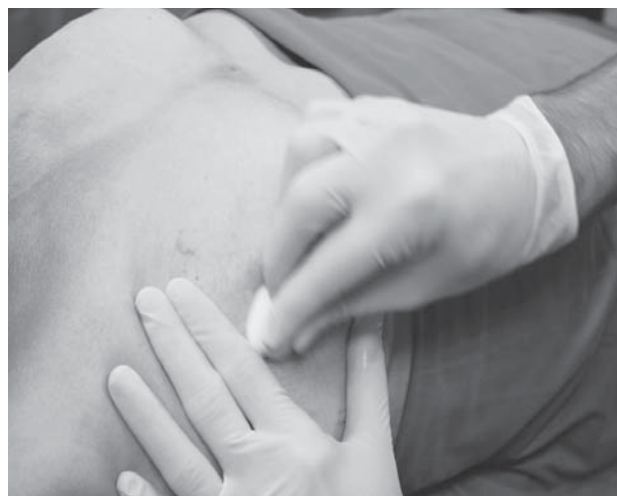
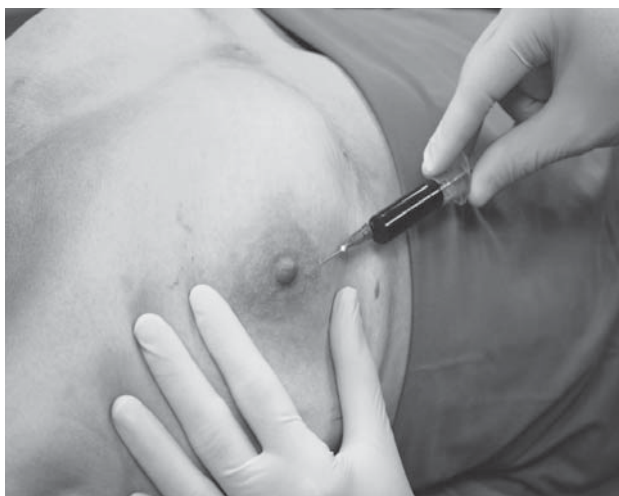
Figure 1. Application of Sienna+® suspension (a) and 5 minutes massage of the area (b).

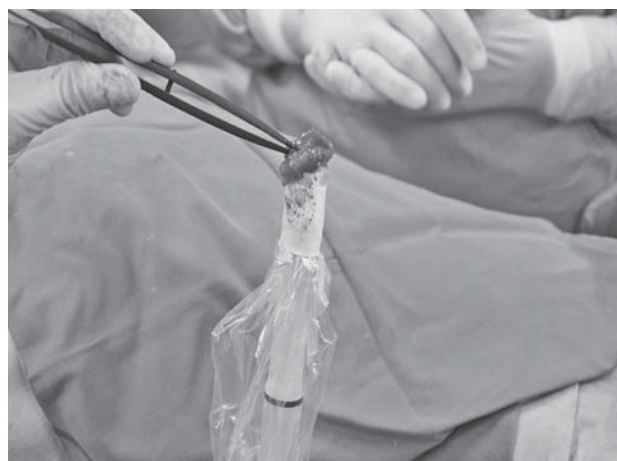
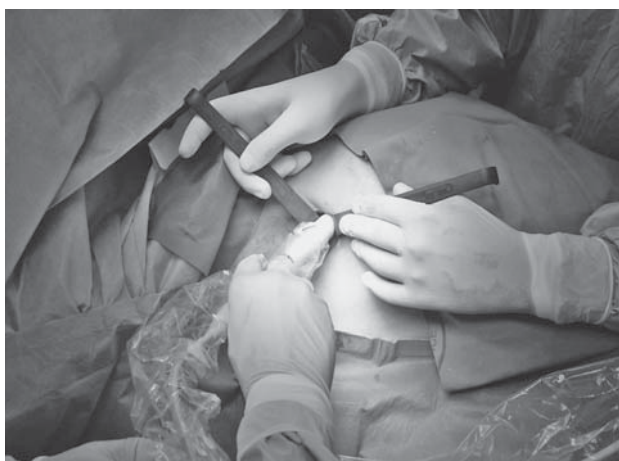
Figure 2. Detection of SIOS positive node with the probe (a) and verification of the extracted node (b)

waiting time prior to breast lesion excision. SentiMag device is then applied transcutaneous to hint the sentinel node location. Axillary skin incision is then made and the lymph node is tracked by the probe signals. When the sentinel node is excised and confirmed with the probe signal, the axilla is also checked for additional lymph nodes. The highest displayed signal was recorded for each extracted and confirmed sentinel node. The breast tumor tissue and the sentinel nodes were then analyzed on Pathology in standard fashion.

## RESULTS

Hundred and twenty eight female patients were treated with breast conservative treatment consisting of segmentectomy and SPIO tracer axillary sentinel lymph node biopsy. Three patients were excluded from the analysis as the final pathology confirmed ductal carcinoma in situ (DCIS)

Table 1.  
SENTINEL LYMPH NODE POSITIVITY IN CORRELATION WITH TUMOR SIZE

	N(%)	Sentinel positiveN (%)	Lymph nodes harvested N (%)
pT1a	4 (3,2)	0	9 (3.08)
pT1b	27 (21,6)	1 (3,7)	75 (25.68)
pT1c	65 (52,0)	16 (24,6)	153 (52.4)
pT2	29 (23,2)	7 (24,1)	55 (18.84)
All stages	125 (100)	24 (19,2)	292 (100)

■ Central ■ Upper medial quadrant ■ Lower medial quadrant

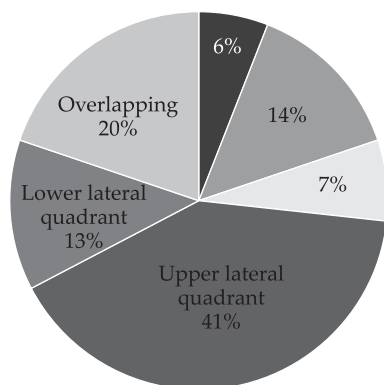


Figure 3. Localization of primary breast lesion. Overlapping lesions denote either tumors between quadrants or multiple tumors.

without invasive components. Total of 294 lymph nodes were harvested, out of which 30 were positive and 24 were detected by SPIO tracer (19%). On average, 2.336 nodes were extirpated. The SentiMag count was 2664 on average, ranging from 140-10000.

Preoperative diagnosis was made by cytology in 68.0% (87 of 128), in 11.7% (15 out of 128) by core biopsy.

We compared the lymph node positivity according to localization, but the number of tumors at each localization was not sufficient for the analysis. Finally, 24 out of 24 identified lymph nodes were positive, to 24 SentiMag detected additional 6 patients positive on pathology).

## DISCUSSION

Current standard for sentinel lymph node biopsy remains technetium 99m radioisotope and patent blue die tracers. Their application requires nuclear medicine department which makes this method unavailable to great number of surgical departments dealing with early breast cancer. The logistical simplification with SPIO tracer and SentiMag probe was the most important reason for adopting the technique at our institution. The SentiMag Multicentre Trial (5), The Nordic SentiMag Trial (6) and The Central European SentiMag (7) study designed as non-inferiority study on 150 patients showed a detection rate of 97,3% (146/150) for (99m)Tc and 98% (147/150) for Sienna+® (8). The French SentiMag feasibility trial confirmed the non-inferiority on 108 patients. Sentinel lymph node (SLN) identification rate was 98.1% (93.5-99.8) for both methods, 97.2% for Sienna+® and 95.4% for (99m) Tc and blue die. A mean of 2.1 sentinel lymph nodes per patient was removed (9). Italian trial confirmed these findings with detection rates per patient for (99m)Tc was 99% and 97,9% for SentiMag based on 193 women analyzed in the study (10). Similar study was performed in Spain on 181 patients. Detection rates were 97.8% for SentiMag and 98.3% for (99m) Tc (concordance rate 99.4%). The study also compared ex-vivo detection rates (97.8%, SentiMag and 98.3% (99m)Tc); concordance rate 99.4%), transcutaneous and intraoperative detection rates (95.5% vs 97.2%, and 97.2% vs 97.8% for SentiMag and (99m)Tc; concordance rates > 97%) and node level detection rates

intraoperatively and ex-vivo (92.5% vs 89.3% and 91.0% vs 86.3% for SentiMag and (99m)Tc) (11).

In our preliminary findings, the sensitivity was comparable to published data. Due to at least one additional lymph node harvested during the procedure we were able to detect additional 6 positive lymph nodes. Nevertheless, during the introduction of the method we observed inconsistent probe signals in elderly (patient born in 1929 had the minimal signal for a positive node 140), we had inconsistent data for patients with high BMI, diabetes, vascular diseases or smokers, therefore we could not reach a valid conclusion on these biases. The BMI issue was more carefully studied than the others, since the depth sensitivity of the probe is currently inferior to radioisotope based system (12). Experimental porcine model suggested 59 nm superparamagnetic iron oxide tracer as optimal due to speed and selectivity of node uptake (13). To further increase the sensitivity the same group achieved larger number of nodes tracked with increased volumes of tracers and longer waiting time to incision, up to 60 minutes (14).

As for the cost effectiveness, the standard method and SentiMag are comparable, but partial axillary lymph node dissection, spares the nerves and has the same rate of lymphedema as SLNB, harvests false negative SLNBs and is less time consuming.

Despite above mentioned shortcomings of the superparamagnetic tracer detection method, a meta-analysis by MD Anderson group showed once again a no inferiority of Sienna+® mapping agent to current standard on 1683 lymph nodes from 804 patients who participated in five trials. Their conclusion will bring this method closer to becoming the standard (15).

## CONCLUSION

Based on these data we adopted the technique and have reached similar conclusions to those already published. These are our preliminary experiences and the more in depth analysis of BMI, age, localization and pathology findings will be conducted in near future.

## REFERENCES

1. Mansel RE, Fallowfield L, Kissin M, Goyal A, Newcombe RG, Dixon JM, et al. Randomized multicenter trial of sentinel node biopsy versus standard axillary treatment in operable breast cancer: the ALMANAC trial. *J Natl Cancer Inst.* 2006;98(9):599-609.
2. Lyman GH, Temin S, Edge SB, Newman LA, Turner RR, Weaver DL, et al. Sentinel lymph node biopsy for patients with early-stage breast cancer: American Society of Clinical Oncology clinical practice guideline update. *American Society of Clinical Oncology Clinical Practice.* *J Clin Oncol.* 2014;32(13):1365-83.
3. Kaufmann M, von Minckwitz G, Mamounas EP, Cameron D, Carey LA, Cristofanilli M, et al. Recommendations from an international consensus conference on the current status and future of neoadjuvant systemic therapy in primary breast cancer. *Ann Surg Oncol.* 2012 May;19(5):1508-16.
4. Ramljak V, Vielh P. One day diagnosis. *Libri Oncol.* 2014;42(1-3):83-5.
5. Douek M, Klaase J, Monypenny I, Kothari A, Zeichmeister K, Brown D, et al. Sentinel node biopsy using a magnetic tracer versus standard technique: the SentiMAG multicentre trial. *Ann Surg Oncol.* 2014;21(4):1237-45.
6. Karakatsanis A, Christiansen PM, Fischer L, Hedin C, Pistoli L, Sund M, et al. The Nordic SentiMag trial: a comparison of super paramagnetic iron oxide (SPIO) nanoparticles versus Tc(99) and patent blue in the detection of sentinel node (SN) in patients with breast cancer and a meta-analysis of earlier studies. *Breast Cancer Res Treat.* 2016;157(2):281-94.
7. Thill M, Kurylcio A, Welter R, van Haasteren V, Grosse B, Berclaz G, et al. The Central-European SentiMag study: sentinel lymph node biopsy with superparamagnetic iron oxide (SPIO) vs. radioisotope. *Breast.* 2014;23(2):175-9.
8. Houpeau JL, Chauvet MP, Guillemin F, Bendavid-Athias C, Charitansky H, Kramar A, et al. Sentinel lymph node identification using superparamagnetic iron oxide particles versus radioisotope: The french SentiMag feasibility trial. *J. Surg. Oncology.* 2016;113(5):501-7.
9. Ghilli M, Carretta E, Di Filippo F, Battaglia C, Fustaino L, Galanou I, et al. The superparamagnetic iron oxide tracer: a valid alternative in sentinel node biopsy for breast cancer treatment. *Eur J Cancer Care (Engl).* 2015 Sep 14. doi: 10.1111/ecc.12385.
10. Pinero-Madrona A, Torro-Richart JA, de Leon-Carillo JM, de Castro-Parga G, Navarro-Cecilia J, Dominguez-Cunchillos F, et al. Superparamagnetic iron oxide as a tracer for sentinel node biopsy in breast cancer: A comparative non-inferiority study. *Eur J Surg Oncol.* 2015;41(8):991-7.
11. PouW JJ, Bastiaan DM, Klaase JM, Ten Haken B. Phantom study quantifying the depth performance of a handheld magnetometer for sentinel lymph node biopsy. *Phys Med.* 2016;32(7):926-31.
12. PouW JJ, Ahmed M, Anninga B, Schuurman K, Pinder SE, Van Hemerlrijck M, et al. Comparison of three

magnetic nanoparticle tracers for sentinel lymph node biopsy in an in vivo porcine model. *Int J Nanomedicine*. 2015;10:1235-43.

13. Ahmed M, Anninga B, Pouw JJ, Vreemann S, Peek M, Van Hemerlijck M, et al. Optimising magnetic sentinel lymph node biopsy in an in vivo porcine model. *Nanomedicine*. 2015;11(4):993-1002.
14. Teshome M, Wei C, Hunt KK, Thompson A, Rodriguez K, Mittendorf EA. Use of a magnetic tracer for

sentinel lymph node selection in early-stage breast cancer Patients: A meta-analysis. *Ann Surg Oncol*. 2016 May;23(5):1508-14.

*Corresponding author: Ilija Guteša, Department of Surgical Oncology, University Hospital for Tumors, University Hospital Center Sestre milosrdnice, Illica 197, 10000 Zagreb, Croatia. e-mail: ilija.gutesa@gmail.com*