

## **The influence of different age, breed, use and gender on the palmar ligament width in non-lame horses**

**Nika Brkljača Bottegaro<sup>1\*</sup>, Berislav Radišić<sup>1</sup>, Ivan Šandrić<sup>2</sup>, Jelena Gotić<sup>3</sup>, Darko Capak<sup>1</sup>, Ozren Smolec<sup>1</sup>, Zoran Vrbanac<sup>4</sup>, Bojan Toholj<sup>5</sup>, Krunoslav Bojanić<sup>6</sup>, and Josip Kos<sup>1</sup>**

<sup>1</sup>*Clinic of Surgery, Orthopaedics and Ophthalmology, Faculty of Veterinary Medicine, University of Zagreb, Zagreb, Croatia*

<sup>2</sup>*Private practice, Sinj, Croatia*

<sup>3</sup>*Clinic for Internal Diseases, Faculty of Veterinary Medicine, University of Zagreb, Zagreb, Croatia*

<sup>4</sup>*Department of Radiology, Ultrasound Diagnostic and Physical Therapy, Faculty of Veterinary Medicine, University of Zagreb, Zagreb, Croatia*

<sup>5</sup>*Department of Veterinary Medicine, Agricultural Faculty, University of Novi Sad, Novi Sad, Serbia*

<sup>6</sup>*EpiLab, Institute of Veterinary, Animal and Biomedical Sciences, Massey University, Palmerston North, New Zealand*

---

**BRKLJAČA BOTTEGARO, N., B. RADIŠIĆ, I. ŠANDRIĆ, J. GOTIĆ, D. CAPAK, O. SMOLEC, Z. VRBANAC, B. TOHOLJ, K. BOJANIĆ, J. KOS: The influence of different age, breed, use and gender on the palmar ligament width in non-lame horses. Vet. arhiv 87, 1-11, 2017.**

### **ABSTRACT**

The present study was carried out to investigate whether age, breed, use and gender have any influence on palmar ligament width in non-lame horses. Pathology of the metacarpophalangeal joint are frequently associated with lameness in horses. Although osteoarticular lesions are the most common, soft tissue lesions of the proximal scutum, are not rare. Diagnosis of injuries to the palmar ligament and its associated structures is mainly based on abnormal imaging features, such as increased width of the ligament above 0.6 cm. The palmar ligament width was measured in 58 non-lame horses. The horses were divided into groups according to age, breed, use and gender. None of the examined horses had disruption of the palmar ligament from the proximal sesamoid bones, or alterations of echogenicity within the ligament. Fourteen horses (24%) had at least one palmar ligament wider than 0.6 cm. The statistically significant influence of age, breed, use and gender on the mean palmar ligament width was recorded. These findings suggest that a palmar ligament width above 0.6 cm is not always a certain sign of proximal scutum pathology, but could also be influenced by the age, breed, use and gender of horses.

**Key words:** equine, intersesamoidean ligament, proximal scutum, ultrasonography

---

\*Corresponding author:

Assist. Prof. Nika Brkljača Bottegaro, PhD, Clinic of Surgery, Orthopaedics and Ophthalmology, Faculty of Veterinary Medicine, University of Zagreb, Heinzelova 55, 10000 Zagreb, Croatia, Phone: +385 91 2390 165; Fax: +385 1 2390 390; E-mail: nikabb@vef.hr

## **Introduction**

Lameness originating from the metacarpophalangeal (fetlock) joint has a significant effect on the use and athletic competitiveness of horses (GONZALEZ et al., 2010). Lesions occur more frequently in the fetlock joint in the horse than in any other joint, deriving from both traumatic and degenerative lesions (POOL and MEAGHER, 1990; BROOMER et al., 2003). Although it is regarded as a simple joint, diagnosis of a fetlock disorder can be challenging, and various imaging modalities are routinely used for an accurate diagnosis (DENOIX, 1996; VANDERPERREN and SAUNDERS, 2009). Osteoarticular lesions are common features of fetlock pathology and are most widely discussed in the literature. However, soft tissue lesions of the palmar/plantar aspect of the fetlock are not rare and must be taken into account when investigating distal limb lameness (SEIGNOUR et al., 2012).

The palmar ligament (PL) of the fetlock, also referred to as the intersesamoidean ligament, is a thick collagen structure that completely covers the palmar and axial structures of the proximal sesamoid bones, and is strongly attached to them. Together with the proximal sesamoid bones, PL forms the proximal scutum (DYSON and GENOVESE, 2011). When the fetlock overextends, the proximal scutum slides distally to the metacarpal condyle and its palmar surface undergoes pressure from the flexor tendons. In this position the distal branches of the third interosseous muscle induce high tension on the abaxial surface of the proximal sesamoid bones (DENOIX et al., 1997). Such high tension on the PL could explain the biomechanical cause of proximal scutum injuries (DENOIX et al., 1997).

The anatomical location and the architecture of the proximal scutum make injuries of this structure difficult to identify by physical examination, and radiographic findings are only based on visualization of osseous lesions (BARCLAY et al., 1985), therefore ultrasonographic examination provides essential information for an accurate diagnosis of proximal scutum soft tissue damage (DENOIX et al., 1997). Ultrasonographic abnormalities of the PL desmitis described by SCHRAMME and SMITH (2011) are enlargement of the distance between both the proximal sesamoid bones of more than 0.6 cm, alteration of the echogenicity within the PL, asymmetrical reduction in the thickness of the PL and irregular bony outline to the palmar surface of proximal sesamoid bones.

To our knowledge, the literature on PL in horses is sparse and consists mostly of clinical observations and case reports rather than controlled population studies.

The purpose of the present study was to evaluate the influence of age, breed, use and gender and on the PL width in non-lame horses.

## Materials and methods

*Animals.* The study consisted of 58 horses admitted to the University Clinic, due to causes unrelated to lameness. Other inclusion criteria were: no history of lameness, no palpable abnormality on either fetlock, and no lameness detection on the lameness exam, which consisted of a walk and trot evaluation on hard and soft surfaces, both in a line and in a circle, and lower flexion tests of both front legs.

*Technical elements.* Both forelimbs were prepared for ultrasonographic examination of the zone 3C (palmar aspect of the metacarpophalangeal joint). The area was clipped, followed by a 2 stage cleaning process using a surgical chlorhexidine gluconate scrub and ethanol solution to prepare the skin. A very high viscosity contact gel was massaged into the skin. Ultrasonography was performed with the limb bearing full weight. The measurements were done using a portable ultrasound Terason t-300 (Terason, 77 Terrace Hall Avenue, Burlington, MA 01803, United States) with a veterinary linear array transducer 5-12 MHz. Transducer penetration depth was set at 3 cm. The PL width was measured by tracing the ligament borders of the transverse image that corresponded to the distance of the proximal sesamoid bones at their narrowest position on the image. Three measurements, done by three different clinicians, were recorded for each ligament and the arithmetic mean of the readings was used for calculations.

*Statistical analysis.* The horses were divided into groups according to age (from 1 to 5 years of age, from 6 to 10 years of age, from 11 to 16 years of age and from 17 to 25 years of age), breed (Thoroughbreds, Warmbloods and draft horses), use (sport and pleasure horses) and gender (mares, stallions and geldings).

The agreement between different observers was assessed by the intraclass correlation coefficient (ICC). Means and standard deviations were used to describe the PL values. The paired Student *t*-tests and Pearson correlation coefficient were used to assess the difference in mean PL width and correlation of PL width, respectively, between left and right legs. The data were checked for normality using the Shapiro-Wilk test. One-way analysis of variance (ANOVA) was used for univariate analysis of the influence of age, gender, use and breed on mean PL width. Two-way ANOVA was used for comparison of multiple groups and evaluation of interaction. Variables with  $P < 0.3$  from univariate analysis were used for bivariate and multivariate models. Model building was based on the backward step procedure from the saturated model and model selection, based on ANOVA tests. Model diagnostics included evaluation of linearity, homoscedasticity, independence of errors and multicollinearity. The Tukey's honest significant difference method was used in univariate and multivariate analysis, as a *post hoc* test for differences between groups. A *P* value less than 0.05 was considered significant. Statistical and exploratory data analyses were performed using R v3.2.2 (R: A language and environment for statistical computing. R Core Team, 2013) (©The R Foundation. The R Foundation for

Statistical Computing, c/o Institute for Statistics and Mathematics, Wirtschaftsuniversität Wien, Welthandelsplatz 1, 1020 Vienna, Austria. URL <http://www.R-project.org/>).

*Ethics.* The study was approved by the institutional animal care and use committees of the Faculty of Veterinary Medicine, University of Zagreb, and the Croatian Ministry of Science, Education and Sport.

## Results

The study sample consisted of 19 Thoroughbreds, 15 Croatian Warmbloods, 11 draft horses, six Holsteiner horses, two Lipizzaner horses, two Hungarian Warmblood horses, one Nonius horse, one Russian Warmblood and one French saddle horse. The number of horses per group within the variables of interest (age, breed, use and gender) are presented in Table 1.

Table 1. The distribution of horses and the mean palmar ligament width according to groups

|                     | n horses | Mean PL width |
|---------------------|----------|---------------|
| <b>Age</b>          |          |               |
| 1 to 5 years        | 13       | 0.49 ± 0.07   |
| 6 to 10 years       | 23       | 0.52 ± 0.07   |
| 11 to 16 years      | 11       | 0.55 ± 0.06   |
| 17 to 25 years      | 11       | 0.58 ± 0.06   |
| <b>Breed</b>        |          |               |
| Thoroughbred horses | 19       | 0.49 ± 0.08   |
| Warmblood horses    | 28       | 0.53 ± 0.05   |
| Draft horses        | 11       | 0.60 ± 0.04   |
| <b>Use</b>          |          |               |
| Sport horses        | 23       | 0.48 ± 0.07   |
| Pleasure horses     | 35       | 0.56 ± 0.06   |
| <b>Gender</b>       |          |               |
| Mares               | 27       | 0.54 ± 0.06   |
| Stallions           | 13       | 0.49 ± 0.09   |
| Geldings            | 18       | 0.55 ± 0.06   |

Data are shown as the mean ± 1 standard deviation in cm

None of the examined horses had disruption of the PL from the proximal sesamoid bones or alterations of echogenicity within the PL (Fig. 1). Fourteen horses (24%) had at least one PL wider than 0.6 cm. Regarding age, PL width above 0.6 cm was determined in one horse in the 1 to 5 years age group, three horses in the 6 to 10 years and five horses in both the 11 to 16, and the 17 to 25 years age groups. Among them, six horses (43%) were draft horses, and four horses were Thoroughbred horses (28.5%) and Warmblood horses

(28.5%) respectively. PL width above 0.6 cm was noticed in three horses from the group of sport horses and 11 horses from the group of pleasure horses. The PL width above 0.6 cm was observed in six mares, five geldings and three stallions. High agreement of PL width measurements was observed between the different observers, with ICC of 0.642 ( $P < 0.001$ ). The Shapiro-Wilk test revealed normally distributed data on both left and right PL widths ( $P = 0.4$  and  $P = 0.3$  respectively). A high correlation (Pearson's  $r = 0.95$ ) between width values of the left and right PL was estimated and there was no significant difference between the left and right mean PL widths in the same horses ( $P > 0.6$ ). Therefore, for univariate and multivariate analyses, a mean value of left and right PL was used, and the mean PL width based on raw data is presented in Table 1.

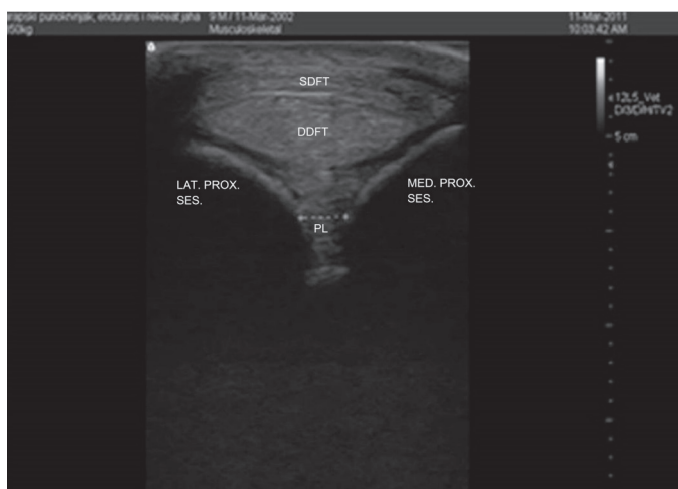


Fig. 1. Transverse image of zone 3C. SDFT, superficial digital flexor tendon; DDFT, deep digital flexor tendon; PL, palmar ligament; LAT. PROX. SES., lateral proximal sesamoid bone osseous shadow; MED. PROX. SES., medial proximal sesamoid bone shadow

Boxplots of PL width according to groups within the variables (age, breed, use and gender) are presented in the Fig. 2, with the results of one-way ANOVA for each variable separately using a letter sharing code above the boxes. The final multivariate model retained all the univariate variables except gender. It is notable that several two-way interaction terms approached significance (use and gender, age and gender, and use and age) during the model evaluation, but were not retained in the final model. Using the adjusted  $P$  values of Tukey's honest significant difference method, the following groups had a statistically significant difference between mean PL width: sport v. pleasure ( $P < 0.001$ ), Thoroughbreds v. draft horses ( $P = 0.01$ ) and the 1 to 5 years old v. 17-25 years old age groups ( $P = 0.01$ ).

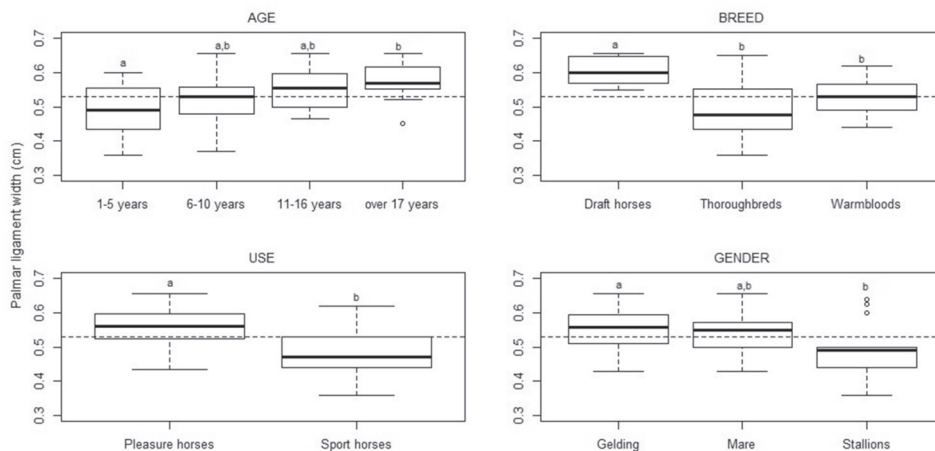


Fig. 2. Boxplot of mean palmar ligament width between horse groups (sharing of at least one letter between the boxes denotes no significant difference using one-way ANOVA; a dashed line represents overall mean palmar ligament width)

## Discussion

Injuries of the PL usually cause acute onset, moderate to severe lameness, and the diagnosis is based on abnormal imaging features (SCHRAMME and SMITH, 2011). Ultrasound enables evaluation of the PL with detectable abnormalities, including: disruption of the PL from the proximal sesamoid bones, enlargements of the distance between the two proximal sesamoid bones, alteration of echogenicity within the PL, thinning or degeneration of the PL (usually asymmetrical), thickening of the PL, and an irregular margin or osteolysis of the proximal sesamoid bones (DENOIX et al., 1997; DABAREINER et al., 2001). SCHRAMME and SMITH (2011) describe PL rupture as an ultrasonically detectable enlargement of the distance between both proximal sesamoid bones of more than 0.6 cm. In our study, 24% of horses had at least one PL wider than 0.6 cm without showing any clinical signs of PL rupture or desmitis. DENOIX et al. (1997) performed ultrasonography examinations of the proximal scutum on 10 sound horses, and found that the smallest distance between the 2 proximal sesamoid bones varied from 0.3 to 0.6 cm. Post mortem examination of 305 pairs of proximal sesamoid bones revealed radiological changes in 25.8% and gross abnormalities of the PL in 25.9% (HERTSCH and BECKER, 1986), but there was no information regarding the clinical effects of these pathologies.

The results of this study showed the value of mean PL width rising with age, which might be a sequel of cumulative subclinical ligament degeneration due to high

biomechanical stress during locomotion. Those defects heal with increased synthesis of collagen type III (WILLIAMS et al., 1984; DAHLGREN et al. 2005; SÖDERSTEN et al., 2012). Furthermore, collagen type III prevails as the horse ages (SMITH and WRIGHT, 2006). Age is frequently associated with increased prevalence of tendinosis and injury in humans (DRESSLER et al., 2002), and degenerative changes are commonly found in the tendons of people over 35 years of age (KANNUS and JOZSA, 1991). YU et al. (2013) imply that aging might exert a negative effect on tendon structure or its healing process by a mechanism that involves increased matrix metalloproteinase-2 and -9 activities, and decreased proliferation of tenocytes. Thickening and hypoechogenicity of tendons and ligaments have been described in recent, old or chronic injuries (DENOIX et al., 1997). Taking into account that PL injuries habitually cause lameness, and none of the horses in our study had clinical signs of fetlock pathology, we may conclude that the increasing value of PL width could be a sequel of some old desmopathy.

With regard to breed, the widest, and a statistically significantly wider ligament value than in either of the other breed groups, was observed in draft horses, which in our opinion was a consequence of their strong constitution, in contrast to Thoroughbred horses which have a significantly lighter constitution and consequently narrower PL width. Thoroughbred horses also had lower values of PL width compared to Warmblood horses, although this was not statistically significant. The mean PL width of Thoroughbred horses was expected to be wider than that of Warmblood horses due to the high biomechanical stress they undergo during locomotion, especially during the intermediate part of the stance phase, which causes tremendous force on the bones and soft tissue, in particular during rapid hyperextension of the fetlock in racehorses. This stress is responsible for lesions involving the different structures of the fetlock joint (DENOIX, 1996; BRAMLAGE, 2009a; BRAMLAGE, 2009b; RICHARDSON and DYSON, 2011; SEIGNOUR et al., 2012). Contrary to our prediction, the reason for this unexpected finding could be the small number of races taking place in Croatia in recent years and therefore the low training load of those horses, as well as the already mentioned influence of their lighter constitution.

We recorded the statistically significant influence of the use of horses on the mean PL width, with sport horses having significantly lower values of PL width. This finding could be accounted for by the age differences between sport and pleasure horses, having mostly younger horses performing sport. This finding could also be explained by the percentage of Thoroughbred influence in sport horses, since many Warmblood breeding societies favour adding Thoroughbred bloodlines to their studbooks.

With regard to gender, a significant difference in PL width was recorded between stallions and geldings, with stallions having smaller values. This finding could be attributed to the use of stallions since they are often not used for work and, apart from

their breeding activities, are often just kept on pasture, unlike geldings that are typically used for work, often regardless of their age.

Comparison between symmetrical structures and contralateral limbs increases the diagnostic sensitivity and specificity (DENOIX, 1996), but we observed no statistically significant differences when comparing the measurements of the left and right legs, which was expected due to the lack of obvious clinical pathology of the fetlock.

Although radiography has historically been the only imaging modality used on horses presenting with clinical signs of fetlock pathology, this technique has major limitations in the diagnosis of soft tissue lesions (DENOIX, 1996; DENOIX et al., 1997). Ultrasonography is the technique of choice for examination of the palmar/plantar aspect of the fetlock joint, which is mainly composed of tendons and ligaments. Furthermore, ultrasonography is a non-invasive technique that can be easily performed in the field with portable machines, and used not just as diagnostic, but also a prognostic tool (SEIGNOUR et al., 2012). Still, accurate diagnostic ultrasonography requires a skilled and experienced operator, with an in-depth knowledge of the anatomy and normal images. Correct positioning and angulation of the probe are critical to obtain images of diagnostic value and limit artefacts or misinterpretation (DENOIX et al., 1997).

Palmar ligaments may be further assessed by tenoscopy, indicated as a diagnostic procedure complementary to ultrasonography in cases presenting with tenosynovitis of the digital sheath. Although this is an invasive modality, requiring general anaesthesia, it has the advantage of performing treatment (WILDERJANS et al., 2003). Contrary to ultrasonography, the inner architecture of tendons and ligaments cannot be assessed with tenoscopy, but this technique is more sensitive for differentiating adhesions, longitudinal tears and superficial fibrillations (EDINGER et al., 2005; SMITH and WRIGHT, 2006; CAUVIN, 2011). High MRI field scanners require general anaesthesia of the patient, but provide images of better accuracy. They are particularly indicated when a lesion of the PL is suspected (SEIGNOUR et al., 2012), especially taking into account that some lesions identified by MRI do not show visible modifications on ultrasound examination (GONZALEZ et al., 2010; KING et al., 2013). A good alternative could be the use of standing MRI scanners, although they are still expensive and seldom available in daily practice.

A factor that could potentially interfere with the PL measurements performed in this study is that there was no well-defined position of measurement on the ligament itself. We attempted to reduce this negative effect by taking the mean value of three separate measurements of the PL width, as well as having three clinicians perform all the examinations. Furthermore, no histopathological study was performed on PLs in this study, thereby the significance of our findings can only be established by comparison with previous studies involving findings of the PL (HERTSCH and BECKER, 1986; DENOIX et al., 1997).



In conclusion, PL width above 0.6 cm is not always a reliable sign of proximal scutum pathology. The present results showed that the age, use and breed of horses influence the PL width, which should be taken into account when investigating proximal scutum pathologies. Moreover, considering the results of univariate analysis, horse gender could have an important association with mean PL width, as well as several two-way interaction terms from the multivariate model evaluations. However, a larger study is needed to evaluate these associations. One clinical implication of the results of this study is that cut-off values of normal PL width could be adjusted according to the above variables, but a limitation of this study is the lack of clinical cases for the respective comparisons.

## References

- BARCLAY, W. P., J. J. FOERNER, T. N. PHILLIPS (1985): Axial sesamoid injuries associated with lateral condylar fractures in horses. *J. Am. Vet. Med. Assoc.* 186, 278-279.
- BRAMLAGE, L. R. (2009a): Operative orthopedics of the fetlock joint of the horse: traumatic and developmental diseases of the equine fetlock joint. Proceedings of the 55<sup>th</sup> American Association Equine Practitioners Annual Convention, 5-9 December, Las Vegas, USA, pp. 96-143.
- BRAMLAGE, L. R. (2009b): Arthrodesis if the metacarpal/metatarsal phalangeal joint in the horse Proceedings of the 55<sup>th</sup> American Association Equine Practitioners Annual Convention, 5-9 December, Las Vegas, USA, pp. 144-49.
- BROOMER, H., R. R. VAN WEEEREN, P. A. J. BRAMA, A. BARNEVELD (2003): Quantification and age-related distribution of articular cartilage degeneration in the equine fetlock joint. *Equine Vet. J.* 35, 697-701.
- CAUVIN, E. (2011): Tenoscopy and bursoscopy, In: *Diagnosis and management of lameness in the horse*, Second edition. (Ross M. W., S. J. Dyson, Eds.), Saunders Elsevier, St. Louis, pp.260-266.
- DABAREINER, R. M., J. P. WATKINS, G. K. CARTER, C. M. HONNAS, T. EASTMAN (2001): Osteitis of the axial border of the proximal sesamid bones in horses: eight cases (1993-1999). *J. Am. Vet. Med. Ass.* 219, 82-86.
- DAHLGREN, L. A., B. D. BROWER-TOLAND, A. J. NIXON (2005): Cloning and expression of type III collagen in normal and injured tendons of horses. *Am. J. Vet. Res.* 66, 266-270.
- DENOIX, J. M. (1996): Ultrasound examination in the diagnosis of joint disease. In: *Joint disease in the horse*. (Mellwraith, C. W., G. W. Trotter, Eds.) W. B. Saunders Co., Philadelphia, pp. 165-202.
- DENOIX, J. M., V. BUSONI, M. OLALLA (1997): Ultrasonographic examination of the proximal scutum in the horse. *Equine Vet. J.* 29, 136-141.
- DRESSLER, M. R., D. L. BUTLER, R. WENSTRUP, H. A. AWAD, F. SMITH, G. P. BOIVIN (2002): A potential mechanism for age-related declines in patellar tendon biomechanics. *J. Orthop. Res.* 20, 1315-1322.

- DYSON, S. J., R. L. GENOVESE (2011): The suspensory apparatus. In: *Diagnosis and management of lameness in the horse* Second edition. (Ross M. W., S. J. Dyson, Eds.), Saunders Elsevier, St. Louis, pp. 654-672.
- EDINGER, J., G. MÖBIUS, J. FERGUSON (2005): Comparison of tenoscopic and ultrasonographic methods of examination of the digital flexor tendon sheath in horses. *Vet. Comp. Orthop. Traumatol.* 18, 209-214.
- GONZALEZ, L. M., M. C. SCHRAMME, I. D. ROBERTSON, D. E. THRALL, R. W. REDDING (2010): MRI features of metacarpo(tarso)phalangeal region lameness in 40 horses. *Vet. Radiol. Ultrasound* 51, 404-414.
- HERTSCH, B., C. BECKER (1986): Zum Vorkommen der aseptischen Nekrose im Ligamentum palmare bzw plantare beim Pferd: ein Betrag zur Differenzierung der Gleichbeinerkrankungen. *Dtsch. Tierärztl. Wochenschr.* 93, 263-266.
- KANNUS, P., L. JOZSA (1991): Histopathological changes preceding spontaneous rupture of a tendon. A controlled study of 891 patients. *J. Bone Joint Surg. Am.* 73, 1507-1525.
- KING, J. N., C. J. ZUBROD, R. K. SCHNEIDER, S. N. SAMPSON, G. ROBERTS (2013): MRI findings in 232 horses with lameness localized to the metacarpo(tarso)phalangeal region and without a radiographic diagnosis. *Vet. Radiol. Ultrasound* 54, 36-47.
- POOL, R. R., D. M. MEAGHER (1990): Pathological findings and pathogenesis of racetrack injuries. *Vet. Clin. North. Am-Equine Practice* 6, 1-30.
- RICHARDSON, D. W., S. J. DYSON (2011): The metacarpophalangeal joint. In: *Diagnosis and management of lameness in the horse*. Second edition. (Ross M. W., S. J. Dyson, Eds.), Saunders Elsevier, St. Louis, pp. 394-410.
- SCHRAMME, C. M., R. K. W. SMITH (2011): Diseases of the digital flexor tendon sheath, palmar annular ligament and digital annular ligaments. In: *Diagnosis and management of lameness in the horse*, Second Edition. (Ross M. W., S. J. Dyson, Eds.), Saunders Elsevier, St. Louis, pp. 764-776.
- SEIGNOUR, M., V. COUDRY, R. NORRIS, J. M. DENOIX (2012): Ultrasonographic examination of the palmar/plantar aspect of the fetlock in the horse: Technique and normal images. *Equine Vet. Educ.* 24, 19-29.
- SMITH, M. R., I. M. WRIGHT (2006): Noninfective tenosynovitis of the digital flexor tendon sheath: a retrospective analysis of 76 cases. *Equine Vet. J.* 38, 134-141.
- SÖDERSTEN, F., K. HULTENBY, D. HEINEGÅRD, C. JOHNSTON, S. EKMAN (2012): Immunolocalization of collagens (I and III) and cartilage oligomeric matrix protein in the normal and injured equine superficial digital flexor tendon. *Connect. Tissue Res.* 54, 62-69.
- VANDERPERREN, K., J. H. SAUNDERS (2009): Diagnostic imaging of the equine fetlock region using radiography and ultrasonography. Part 1: Soft tissue. *Vet. J.* 181, 111-122.
- WILDERJANS, H., B. BOUSSAUW, K. MADDER, O. SIMON (2003): Tenosynovitis of the digital flexor tendon sheath and annular ligament constriction syndrome caused by longitudinal tears in the deep digital flexor tendon: a clinical and surgical report of 17 cases in warmblood horses. *Equine Vet. J.* 35, 270-275.

- WILLIAMS, I. F., K. G. McCULLAGH, I. A. SILVER (1984): The distribution of types I and III collagen and fibronectin in the healing equine tendon. *Connect. Tissue Res.* 12, 211-227.
- YU, T. Y., J. H. S. PANG, K. P. H. WU, M. J. L. CHEN, C. H. CHEN, W. C. TSAI (2013): Aging is associated with increased activities of matrix metalloproteinase-2 and -9 in tenocytes. *BMC Musculoskelet. Disord.* 14, 2-9.

Received: 19 October 2015

Accepted: 4 June 2016

---

**BRKLJAČA BOTTEGARO, N., B. RADIŠIĆ, I. ŠANDRIĆ, J. GOTIĆ, D. CAPAK, O. SMOLEC, Z. VRBANAC, B. TOHOLJ, K. BOJANIĆ, J. KOS: Utjecaj dobi, pasmine, korištenja i spola na širinu palmarnog ligamenta u konja bez znakova hromosti. *Vet. arhiv* 87, 1-11, 2017.**

**SAŽETAK**

Cilj ovog rada bio je istražiti učinak dobi, pasmine, korištenja i spola na širinu palmarnog ligamenta u konja bez znakova hromosti. Patološka stanja putičnog zgloba vrlo su često povezana s pojavom hromosti u konja. Iako su oštećenja zglobova i kosti najčešća, oštećenja mekih tkiva proksimalnog štita nisu rijetka. Dijagnostika ozljeda palmarnog ligamenta i okolnih struktura prvenstveno se osniva na rezultatima ultrazvučne pretrage, poput povećanja širine ligamenta iznad 0,6 cm. U ovome je radu mjerena širina palmarnog ligamenta u 58 konja koji nisu pokazivali znakove hromosti. Konji su bili podijeljeni u skupine prema dobi, pasmini, korištenju i spolu. U nijednog konja nije pronađena ruptura palmarnog ligamenta, kao ni promjene u ehogenosti ligamenta. Četrnaest konja (24 %) imalo je barem jedan palmarni ligament širi od 0,6 cm. Statistički značajan utjecaj na širinu palmarnog ligamenta zabilježen je za dob, pasminu te korištenje konja. Ovi podatci ukazuju da širina palmarnog ligamenta iznad 0,6 cm ne mora nužno označavati nedvojbenu patologiju proksimalnog štita, već može biti uvjetovana dobi, pasminom i korištenjem konja.

**Ključne riječi:** konj, palmarni ligament, proksimalni štit, ultrazvuk

---

