

# Femoral Neck Anteversion: Values, Development, Measurement, Common Problems

G. Gulan<sup>1</sup>, D. Matovinović<sup>1</sup>, B. Nemeč<sup>1</sup>, D. Rubinić<sup>1</sup> and J. Ravlić-Gulan<sup>2</sup>

<sup>1</sup> Clinic for Orthopaedic Surgery Lovran, Lovran, Croatia

<sup>2</sup> Department of Physiology, Medical Faculty University of Rijeka, Rijeka, Croatia

## ABSTRACT

*The femoral neck anteversion angle is an important factor for hip stability and normal walking. It is multifactorial result of evolution, heredity, fetal development, intrauterine position, and mechanical forces. Abnormal FNA sometimes can be associated with many clinical problems ranging from harmless intoeing gait in the early childhood, to disabling osteoarthritis of the hip and the knee in the adults.*

*In most cases is associated with minor functional problems in children during growth, but cause a concern in parents for children future. The child must be examined carefully and an accurate diagnosis must be established. The most important part of care is observation of the children. If abnormal femoral neck anteversion produces severe functional disability, derotational osteotomy should be done, but delayed until late childhood.*

---

## General consideration

Anatomists and orthopaedics have long been interested in the femoral neck anteversion angle (FNA)<sup>1–44</sup> since it is widely recognised as an important factor for hip stability<sup>1–3</sup>. It is multifactorial result of evolution, heredity, fetal development, intrauterine position, and mechanical forces. Abnormal FNA sometimes can be associated with many clinical problems ranging from harmless intoeing gait in

the early childhood, which could be a reason for parents concern for children future, to disabling osteoarthritis of the hip and the knee in the adults.

## Definition and normal values

The femoral neck anteversion is the inclination of the axis of the femoral neck with reference to the knee axis projected on a plane perpendicular to the shaft axis (Fig. 1). Femoral anteversion is a physio-

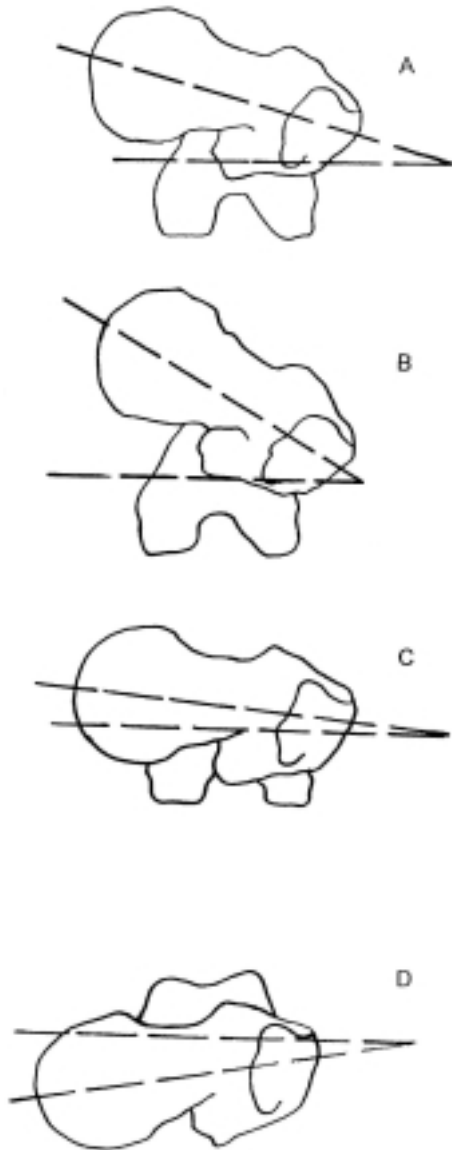


Fig. 1. Angle of femoral neck anteversion or torsion in the transverse plane: (A) normal angle of anteversion; (B) increased angle of anteversion; (C) decreased angle of anteversion; (D) retroversion

logical condition, within certain variations in degrees and differences depending on age<sup>4-7</sup>.

If the axis of the neck inclines forward (anterior to the transcondylar plane), the angle of torsion is called anteversion, antetorsion or anterotation. Similarly, if it points backward (posterior to the transcondylar plane), it is called retroversion, retrotorsion or retrorotation. Concerning retroversion the things can be sometimes confused, because this term is sometimes used to describe anteversion which is below the normal range.

The terminology describing inclination of the femoral neck vary in different study. In German studies the term antetorsion is mostly used<sup>8-9</sup>. In Anglo-Saxon studies, the most widely used terms are torsion of the femur, and femoral anteversion angle<sup>10</sup>. Pediatric Orthopaedic Society of North America called an FNA angle above 2 SD of mean for age, medial torsion of the femur<sup>11</sup>.

The normal values given for the FNA for children and adults differ considerably in the available literature. Different techniques of examination, as well as different population, may explain the different results.

On the average, femoral anteversion ranges from 30–40 degrees at birth and decreases progressively throughout growth due to hereditary factors and local muscle forces<sup>12</sup> and has a great importance in normal walk development<sup>7</sup>.

In adults, anteversion averages between 8 and 14 degrees<sup>10</sup> with an average of 8 degrees in men and 14 degrees in women<sup>13</sup>. The range of normal is broad, with specimens having shown as much as 36 degrees of anteversion.

Based on previous studies by several authors, Svenningsen (1991) reported that the normal values of femoral neck anteversion angle from birth until adult age are the following: median FNA value

ranging from 36° at birth to 33°, 28°, 26°, 25°, 22°, 21°, 16°, 15° in group of age 2–4, 4–6, 6–8, 8–10, 10–12, 12–14, 14–16 and adults, respectively. According to him, value of FNA regression is about 1.5 (0.2–3.1) degrees per year<sup>14</sup>.

Cyvin demonstrated a correlation between the FNA and the build of the child<sup>15</sup>. Slender children on average have higher values of the FNA compared with those of the more »athletic« type. On the other hand, decreased femoral anteversion is commonly seen in the obese children and in association with slipped capital femoral epiphysis. When is unilateral, it is more common on the right side. Cyvin was not able to find any correlation between the age of walking start and the values of the FNA, concluding that well balanced muscle tone did not influence on the FNA<sup>15</sup>.

### **Prenatal development**

Torsion is extension of a normal developmental process of lower limb. Negative torsion in human embryonic femurs has much variations. There is an initial negative torsion of up to 26 degrees, followed by the development of positive femoral anteversion averaging 25–31 degrees, at birth. No histological changes have accounted for the torsion<sup>4,16</sup>, but there may be a tendency for sidedness, especially in females<sup>16</sup>.

Most torsional abnormalities are the result of intrauterine moulding, and are extreme manifestations of normal development. Staheli felt that intrauterine flexion, lateral rotation of the hips, and medial rotation of the feet and tibia are further exacerbated by compressive forces, but that these moulding forces decreased after birth, resulting in gradual improvement of the deformities<sup>16</sup>. According to Le Damany<sup>17</sup> muscle tensions and local forces gave a rotary stress to the epiphysis that resulted in the deve-

lopment of femoral neck anteversion. Browne<sup>18</sup> discussed the relationship of intrauterine compressive forces and congenital deformities. He observed that mechanical moulding of the uterus on the limbs resulted in rotational deformities.

However, the development of femoral anteversion is a multifactorial result of fetal development, evolution, heredity, mechanical forces, and intrauterine position<sup>19</sup>.

### **FNA and hip rotational movement**

Hip rotational movement is highly dependable of the femoral neck anteversion, and some methods for clinical measuring FNA are based on the value of hip rotation. While femoral anteversion is greatest in children younger than two years of age, external hip rotation exceeds internal rotation at three years of age<sup>11</sup>.

In children older than three years, there is a positive correlation between internal rotation of the hip and femoral anteversion<sup>7,20,21</sup>.

Gelberman et al. (1989) suggested that greater lateral rotation indicates normal anteversion<sup>22</sup>, while in our investigations (in press) we found negative correlation between lateral rotation and femoral anteversion. We also found a correlation between differences in passive medial/lateral rotation and femoral anteversion which was the most evident.

### **Measurement**

Precise measurement of femoral anteversion is important in the selection of patients and the preoperative planning for derotational osteotomy of the femur. There are several methods for the measurement of femoral anteversion. Rentgenographic techniques include fluoroscopy<sup>23</sup>, biplane imaging<sup>24–27</sup>, axial roentgenography<sup>28</sup>, axial tomography<sup>29</sup>, ultrasound<sup>30</sup>, and computerised tomographic scann-

ing<sup>31</sup>. In spite of many modern methods, they are not much more accurate than clinical methods<sup>32</sup>. Furthermore, modern techniques are expensive and involve radiation exposure. According to our experience, clinical examination is sufficient and appropriate, and imaging is indicated only if operative correction is planned.

The clinical test most widely used to assess femoral neck anteversion is comparison of internal and external hip rotation, because many studies have confirmed the existence of correlation between hip rotational movement and femoral neck anteversion<sup>16,20,21</sup>. This test is inaccurate in a children below 3 years of age, because the internal rotation is limited by factors extrinsic to the hip joint. Ruwe et al.<sup>32</sup> described clinical technique for assessing femoral neck anteversion with mean errors 3.5 and 4.0 degrees. A child is lying prone. The examiner stands on the contralateral side: the left hand is used to palpate the great trochanter while the right hand internally rotates the hip, with the patient's knee flexed to 90 degrees. At the point of maximum trochanteris prominence, the femoral neck is horizontal. The angle subtended between the tibia and the true vertical, represents the femoral neck anteversion. The angle is measured with a goniometer.

Another techniques for assessing femoral angle anteversion was described by our group<sup>33</sup>. The method is based on differences between medial and lateral rotation on the extended hip (Fig 2). To predict an abnormally high anteversion angle (above +2SD) the differences between medial and lateral rotation must be 45° or more, whereas an abnormal low anteversion angle (lower than mean -2SD) could be predicted when the lateral rotation was at least 50° higher than the medial rotation.

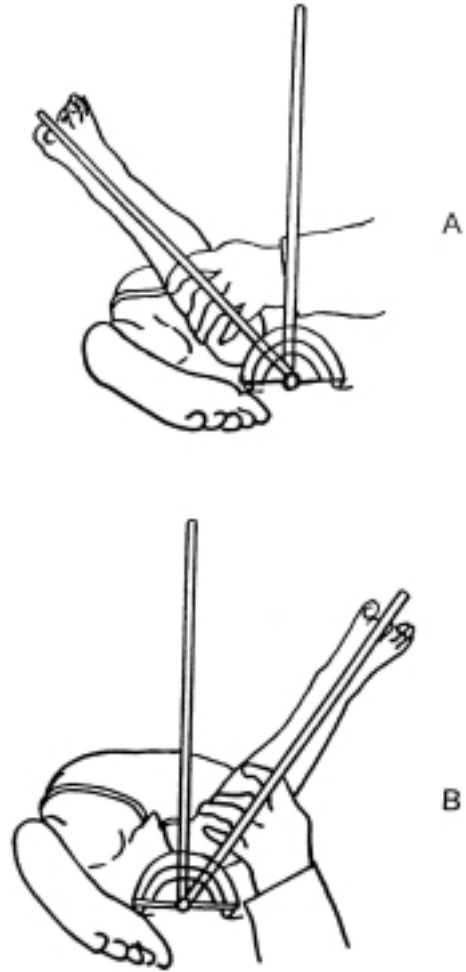


Fig. 2-A and 2-B. Technique for the clinical assessment of femoral anteversion. The child lay prone with hips extended and knees flexed to right angle. The pelvis is stabilized by the examiner's hand to prevent rotation of the pelvis. The examiner measured the passive motion with no power to increase the range of motion. The rotation was measured with a goniometer having long arms. Angles are measured to the nearest 5°.

### **Common clinical problems associated abnormal FNA**

Abnormal femoral anteversion can sometimes be associated with many clinical problems ranging from harmless intoeing gait to disabling osteoarthritis of the hip and knee<sup>34–37</sup>. Excessive anteversion is thought to be particularly important in congenital dislocation of the hip and Legg-Calve-Perthes disease<sup>38</sup>. In case of Legg-Calve-Perthes disease some authors stated the increased FNA as etiologic factor, while McEwen studied 160 patients with Legg-Calve-Perthes disease and revealed anteversion which is about normal for the age group. His study revealed values above normal only for patients over 12 years of age when the femoral head had usually been reconstituted, suggesting that increased anteversion is secondary to the coxa plana and not an etiologic factor<sup>38</sup>.

Increased femoral anteversion is frequently found in congenital dislocation of the hip<sup>3,6,16</sup> and may, however, also be found in otherwise normal hips, and is then commonly called idiopathic increased femoral anteversion<sup>14</sup>.

#### *Intoeing gait*

Increased femoral anteversion is the most common cause of intoeing gait (walking with inward rotation of the foot) that first presents in early childhood. It is twice as common in girls as in boys. It is nearly always symmetrical, and it is often familial. The child walks with an intoeing gait with the patella medially rotated. The appearance while running is characterised by medial rotation of the thighs during swing phase, producing an outward rotation of the legs and feet. The gait appears clumsy and inefficient, and the intoeing becomes more pronounced when the child is tired. Tripping as a result of crossing the feet may occur. Intoeing occurred in 30% of four-years old

group as opposed to 4% in adults<sup>15</sup>. Children with intoeing gait at age seven showed on average anteversion 42 degrees in comparison with an average 24 degrees in the normal group. After this age Fabry did not show significant decrease in anteversion which averaged 39.48<sup>6</sup>. They concluded that after the age of eight no significant change in anteversion occurred. More than 50% of children with increased FNA and intoeing gait had a normal gait at maturity. They postulated that compensatory external rotation of the tibia was responsible for the observed improvement of gait. Svenningsen et al. observed the same angle of femoral anteversion in group of children with intoeing gait, but analysing the regression of femoral anteversion they could not confirm the findings of Fabry et al. In group of 30 children they observed a decrease of anteversion to average 28 degrees at age 16 and concluded that significant regression of the anteversion can occur after eight years of age<sup>15</sup>. The same findings were observed by Schwarzenbach<sup>13</sup> and Jani<sup>14</sup>. All investigators agree that in some cases intoeing gait causes compensatory external rotation of the tibia, that created a malalignment of the patella, causing anterior knee pain in adolescents<sup>34,39,40</sup> and osteoarthritis of the knee in adult life<sup>36</sup>.

#### *Osteoarthritis*

Yet there are not consensus in etiology or pathogenesis of so-called idiopathic osteoarthritis of the hip. Many studies were performed analysing the increased femoral neck anteversion as predisposing factor for coxarthrosis. In all of them, statistically significant higher FNA values in group with coxarthrosis in comparison with normal individuals were found. They highlighted that most severe coxarthrosis had the highest femoral neck angles and recommended prophylactic osteotomy of the femur for children who

have intoeing gait and radiographic evidence of increased femoral anteversion<sup>6,35,37,41,42</sup>. However, others suggested that the relationship between increased FNA and idiopathic osteoarthritis has not been established sufficiently.

In study of cadavers during eleven-year period, Wedge et al. could not confirm that increased femoral anteversion alter the risk for development of osteoarthritis of the hip<sup>43</sup>.

### Treatment

Many nonoperative methods have been proposed (shoe wedges, twister cables, night splints)<sup>6</sup>. According to Staheli<sup>44</sup> nonoperative treatment of abnormal femoral angle anteversion is ineffective. On the basis of medial hip rotation for more than 70 degrees he suggested that appearance of increased femoral anteversion under 8 years of age has to be observed and in 99% has spontaneous regression. This is confirmed by findings of Sveningsen who found that frequency of intoeing gait decreased from 30% in 4 years old children to 4% in adults. If it is mild to moderate increased femoral anteversion which appear after 8 age the treatment is the same. The operative procedure should be performed only in children after the age of 8 (Staheli) or 12 (Sveningsen) if they still have considerable problems connected with walking. The angle of anteversion should be more than 50 degrees and medial rotation of

the hip more than 80 degrees<sup>44</sup>. Considerable care should be taken with the technique. We prefer straight lateral longitudinal incision extending distally from the great trochanter with intertrochanteric level of osteotomy, because the available bone will ensure good contact between fragment with good stability and rapid healing. The rotation should be determined preoperatively as well as angle of the blade plate, entrance point and the level of osteotomy. Intraoperatively rotation is monitored by guide K-wires placed along the anterior femoral neck and in distal femoral metaphysis perpendicular to the long axis of the femur to ensure accuracy. Postoperatively the child may begin weight bearing with crutches within several days of surgery. Full weight bearing usually is allowed 8 weeks after surgery.

### Conclusion

Increased femoral neck anteversion is common problem in childhood. In most cases is associated with minor functional problems in children during growth, but cause a concern in parents for children future. The child must be examined carefully and an accurate diagnosis must be established. The most important part of care is observation of the children. If abnormal femoral neck anteversion produces severe functional disability, derotational osteotomy should be done, but delayed until late childhood.

### REFERENCES

1. LE DAMANY, P. Z., *Ortop.*, 21 (1908) 129. — 2. MCKIBBIN, B. J., *Bone Joint Surg.*, 48 (1970) 148. — 3. GETZ, B., *Acta Orthop. Scand. Suppl.*, 18 (1955) — 4. REIKARS, O., I. BJERKREIM, A. KOLBENSTVEDT, *Acta. Orthop Scand.*, 53 (1982) 781. — 5. SCHWARZENBACH, U., *Arch. Orthop. Unfall-Chir.*, 70 (1971) 230. — 6. JANI, L., U. SCHWARZENBACH, K. AFIFI, P. SCHOLDER, P. GISLER, *Orthopade*, 8 (1979) 5. — 7. SVENNINGSEN, S., T. TERJESEN, M. AUFLEM, V. BERG, *Clin. Ortop. Rel. Res.*, 60 (1989) 177. — 8. MITTELEMIER, H., M. JAGER, *Arch. Orthop. Unfall-Chir.*, 65 (1969) 1. — 9. SCHOLDER, P., *Orthopade*, 8 (1979) 12. — 10. FABRY, G., D. MACEWEN, A. R. SHANDS, J. *Bone Joint Surg.*, 55 (1973) 1726. — 11. STAHELI, L. T., *Orthop. Ttransl.*, 4 (1980) 64. — 12. EVANS, F. G., V. E. KRAHL, *Am. J. Anat.*, 76 (1945) 76. — 13. KATE, B. R., *Acta Anat.*, 94 (1976) 457. — 14. SVENNINGSEN,

- S., University of Trondheim, Faculty of Medicine, Trondheim, Norway 1991. — 15. CYVIN, K. B., Acta Orthop. Scand. Suppl., 166 (1971) 1. — 16. STAHELI, L. T., M. CORBETT, C. WYSS, J. Bone Joint Surg., 39 (1985) 39. — 17. LE DAMANY, P., J., Anat et Physiol., 45 (1909) 589 — 18. BROWNE, D., Arch. Dis. Child., 30 (1955) 37. — 19. GUIDERA K. J., T. M. GANEY, C. R. KENEALLY, J. OGDEN, Clin. Orthop. Rel. Res., 302 (1994) 17. — 20. CRANE, L., J., Bone Joint Surg., 41A (1959) 421. — 21. STAHELI, L. T., W. R. DUNCAN, E. SCHAEFER, Clin. Orthop., 60 (1968) 205. — 22. GELBERMAN, R. H., M. S. COHEN, S. S. DESAI, P. P. GRIFFIN, P. B. SALAMON, T. M. O'BRIEN, J. Bone Joint Surg., 69B (1994) 75. — 23. ROGERS, S. P., J. Bone Joint Surg., 60B (1978) 530. — 24. DUNLAP, K., A. R. Jr. SHANDS, J., Bone Joint Surg., 35A (1953) 289. — 25. LEE, D. Y., C. K. LEE, T. J. CHO, Internat. Orthop., 16 (1992) 277. — 26. MAGILLIGAN, D. J., J., Bone Joint Surg., 38A (1956) 846. — 27. OGATA, K., E. M. GOLDSAND, J. Bone joint Surg., 61A (1978) 846. — 28. DUNN, D. M., J., Bone joint Surg., 34B (1952) 181. — 29. HUBBARD, D. D., L. T. STAHELI, Clin. Orthop., 86 (1972) 16. — 30. TERJESEN, T., S. ANDA, H. RONNINGEN, Skel. Radiol., 22 (1993) 33. — 31. WEINER, D. S., A. J. COOK, W. A. HOYT, C. E. ORFNAEC, Orthopaedics, 1 (1989) 299. — 32. RUWE, P. A., J. R. AGAE, M. B. OZHONOFF, P. A. DELUCA, J. Bone Joint Surg., 74A (1992) 820. — 33. KOŽIĆ, S., G. GULAN, D. MATOVINOVIĆ, B. NEMEC, B. ŠESTAN, J. RAVLIĆ-GULAN, Acta Orthop. Scand., 66 (1997) 533. — 34. INSALL, J., K. A. FALVO, D. W. WISE, J. Bone Joint Surg., 58A (1976) 1 — 35. HALPERN, A. A., J. TANER, L. RINSKY, Clin. Orthop., 145 (1979) 213. — 36. TURNER, M. S., I. S. SMILIE, J. Bone Joint Surg., 63B (1981) 396. — 37. TERJESEN, T., P. BENUM, S. ANDA, S. SVENNINGSSEN, Acta Orthop. Scand., 53 (1982) 571. — 38. McEWEN, M. D., Postgrad. Med. 60 (1976) 154. — 39. FAIRBANK, J. C., P. B. PYNSENT, J. A. VAN POORTVLIET, H. PHILIPS, J. Bone Joint Surg., 66B (1984) 685. — 40. LEFORT, G., J. COTTALARD, F. LEFEVRE, M. A. BUCH-PILLON, S. DAOUD, Rev. Chir. Orthop., 77 (1991) 491. — 41. ALVIK, I., Clin. Orthop., 22 (1962) 16. — 42. REIKARS, O., A. HOISETH, Acta Orthop. Scand., 53 (1982) 781. — 43. WEDGE, J. H., I. MUNKACSI, D. LOBACK, J. Bone Joint Surg., 71A (1989) 1040. — 44. STAHELI, L. T., J. Bone Joint Surg., 75A (1993) 939.

*D. Matovinović*

*Clinic for Orthopaedic Surgery, M. Tita 1, 51415 Lovran, Croatia*

## **ANTEVERZIJA VRATA FEMURA: VRIJEDNOST, RAZVOJ, MJERENJE, NAJČEŠĆE KOMPLIKACIJE**

### **S A Ž E T A K**

Anteverzija vrata femura predstavlja važan čimbenik stabilnosti kuka pri stajanju i hodu. Brojni etiološki čimbenici utječu na njen razvoj kao što su evolucija, nasljeđe, fetalni razvoj, intrauterini položaj i djelovanje mehaničkih sila. Povećan kut anteverzije vrata femura može biti uzrokom mnogih kliničkih problema, od bezazlenog hoda s uvrnutim prstima, pa do teških osteoartrotskih promjena zgloba kuka i koljena. U većini slučajeva povezan je s prolaznim problemima tijekom razvoja djeteta, ali često uzrokuje zabrinutost roditelja. Djeca moraju pažljivo biti pregledana uz postavljanje odgovarajuće dijagnoze, pri čemu promatranje djeteta mora biti jedan od najvažnijih dijelova liječenja. Ako povećan kut anteverzije vrata femura uzrokuje značajne funkcionalne smetnje preporuča se učiniti derotacijsku osteotomiju u predpubertetskom razdoblju.