

## Aging – What Do We Know?

**Beata Bergler-Czop, Bartosz Miziołek**

Department of Dermatology, Medical University of Silesia School of Medicine, Katowice, Poland; Department of Dermatology, Andrzej Mielęcki Silesian Independent Public Clinical Hospital in Katowice, Katowice, Poland

### Corresponding author:

Beata Bergler-Czop, MD  
Department of Dermatology  
Silesian Medical University  
ul. Francuska 20-24  
40-027 Katowice  
Poland  
[bettina2@tlen.pl](mailto:bettina2@tlen.pl)

**ABSTRACT** Skin aging is a combination of reduction in the biological activity of cells, a slowing down of regenerative processes, and a loss of resistance to environmental factors. Genetics, lifestyle, and hormones significantly affect proper functioning of the skin. The aim of this article was to present the current knowledge about aging processes and concurrent therapies which can influence skin aging.

**KEY WORDS:** aging, skin, treatment

Received: April 18, 2016

Accepted: January 10, 2017

### INTRODUCTION

Skin aging is a combination of reduction in the biological activity of cells, a slowing down of regenerative processes, and a loss of resistance to environmental factors. Genetics, lifestyle, and hormones significantly affect proper functioning of the skin. For example, ultraviolet (UV) radiation, environmental pollution, smoking, and improper care can significantly affect skin condition. Simultaneously, hormonal dysregulations, poor nutrition, or vitamin deficiencies can also alter proper functioning of the skin. We can distinguish endogenous and exogenous skin aging (1-3).

#### Aging within the epidermis

Atrophy is a condition which affects all layers of the epidermis except the stratum corneum, which has a tendency to increase its thickness. Keratinocytes manifest reduced proliferative activity and therefore their turnover within the epidermis can be prolonged, even doubled. Simultaneously, synthesis of vitamin D3 is diminished, which severely impairs cornification in the epidermis. Skin aging also affects

melanocytes because their number decreases over the lifespan, and these cells can form lentiginos or disappear from other sites, causing cutaneous discoloration. Additionally, the dermal-epidermal junction gains a tendency to be flattened, and adhesion of the epidermis to the dermis is reduced.

#### Aging within the dermis

There is a progressive reduction in the number and size of fibroblasts due to aging. The cells lower oxygen metabolism, therefore leading to decrease in synthesis of intracellular adenosine triphosphate (ATP) and extracellular proteins. A loss of extracellular components such as hyaluronic acid, dermatan sulfate, or proteoglycan gel diminishes the water-binding capacity of the dermis. A synthesis of collagen bundles decreases over the lifespan. Elastin fibers, another component of the dermis, disappear mainly in the papillary layer; however some of them become hypertrophied in a reticular layer, which leads to a condition called senile elastosis. All these abnormalities are responsible for a formation of wrinkles and

furrows as well as decreased flexibility or increased sensitivity of the skin. Another cutaneous process which is significantly impaired over the lifespan is angiogenesis. A temporary reduced blood supply to the skin leads to abnormal vascular growth, causing visible cutaneous telangiectasia (Figure 1) (1,6).

### Aging of the skin appendages

Aging skin becomes dry due to decreased activity of sebaceous and sweat glands. Exogenous substances such as soaps, detergents, and UV radiation additionally affect skin pH and hydro-lipid balance, impairing resistance of the epidermis to the environment and microorganisms and increasing transepidermal water loss. This increases the irritability and fragility of the skin and predisposes it to itch and eczema (1,4,5).

Another part of the body affected by aging are the nails. Their recovery process slows down, plates become thickened and gain longitudinal furrows. Nails become more brittle with age, and different external factors (drying, chemical agents, cosmetics) can easily destroy the nail bed. Finally, skin aging has a significant effect on hair growth; this influence is discussed in more detail in a later chapter (see Menopause and skin aging) (1,7).

### Theories of endogenous skin aging

Several theories try to explain the mechanisms which alter functioning of body cells, tissues, and organs with age.

#### a) Genetic theory

The first theory is the so-called programming theory; it highlights a group of gerontogenes which could be responsible for aging. It assumes that the duration of life is a genetically determined characteristic. According to this theory, the influence of external factors is less significant. Nuclear DNA includes

genes which drive the speed of aging, the so-called gerontogenes. Additionally, it has been proven that in coexistence of both senescent and young cells, the former can evoke degenerative changes in the young cells. This observation demonstrates that gerontogenes are dominant (1,7).

#### b) Theory of a limited number of cell divisions (Hayflick theory)

The division potency of each cell is limited and it decreases with age. If cells outlive the number of divisions they are capable of, they enter into apoptosis. This limited potency for cell divisions is also called the Hayflick phenomenon or cellular aging. It is a consequence of progressive decrease in activity of nuclear telomerase, an enzyme which is responsible for replication of telomeres (the acral parts of chromosomes). Each cellular division shortens the telomeres, inevitably leading to cellular death (7,8).

#### c) Stochastic theory of skin aging

This theory assumes that aging of cells results from dysfunction secondary to different biochemical abnormalities in the human body (1,7). The most meaningful biochemical abnormalities include excessive formation of reactive oxygen radicals which damage proteins and DNA, causing a loss of the ability of cellular self-repair and tissue regeneration. Another biochemical disturbance is amino acid racemization which generates improper D-isomers from natural L-amino acids. The next abnormal process is non-enzymatic glycosylation of proteins which generates incorrect cross-linking of different proteins, including collagen fibers. All of these abnormalities impair proper functioning of tissues and organs, including the skin. This leads to an abnormal response to external stimuli, epidermal barrier dysfunction, or pathological immune reactions. Hormones are another endogenous factor responsible for skin aging (7-10,12).

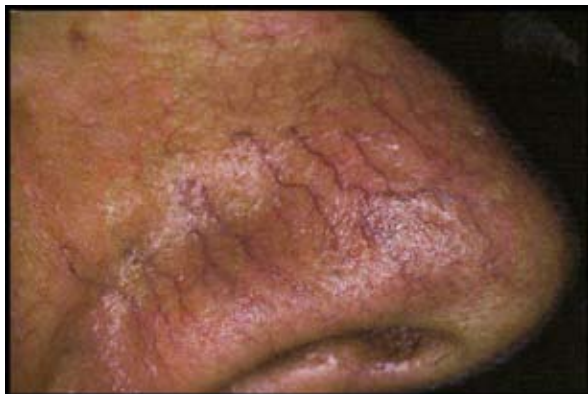

Figure 1. Telangiectasia on the nose.

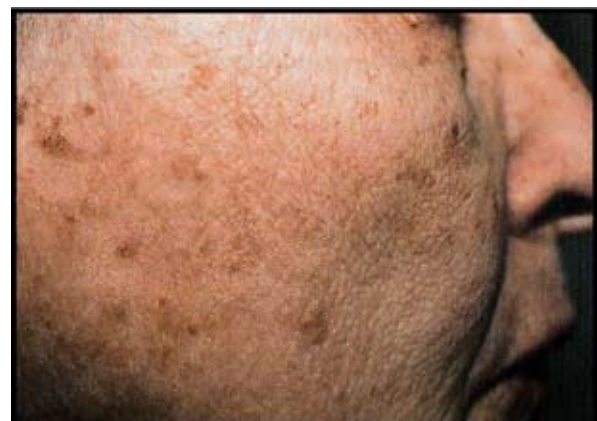
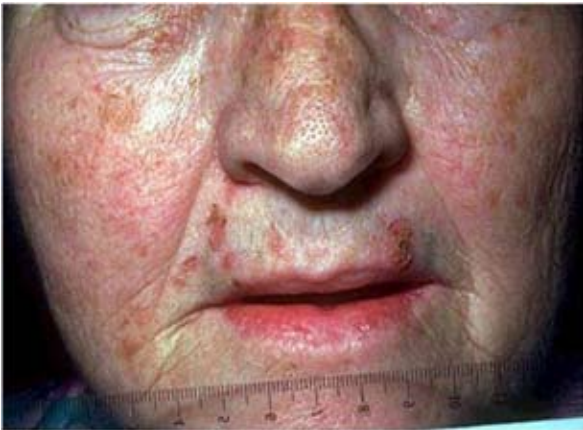
Figure 2. Photoaging.



**Figure 3.** Keratosis senilis of the upper lip.

### Menopause and skin aging

Menopause is defined as the last menses recognized after 12 months of amenorrhea that is not secondary to pathologic conditions. It is a transition from full ovarian functioning to a complete lack of ovarian estrogen biosynthesis. Estrogens are known to exert a protective influence on the functioning of the skin; therefore, many women report a sudden onset of cutaneous symptoms of aging within the first months of menopause. A decline in estrogen synthesis reduces mitotic activity of the basal layer in the epidermis as well as impairing epidermal lipid synthesis, causing severe xerosis. This loss of ovarian functions affects hair bulbs, leading to rarefaction of hair distribution. With menopause, the hair distribution of the female body starts to change, affecting both the distribution and structure of hair. Hair diameters in the both frontal and parietal scalp are lower in postmenopausal women, whereas those in the occipital area stay intact. Hormonal changes in menopause include a drop in estrogens: those previously produced in the ovaries; however, there is still synthesis of androgens in the adrenal glands. This significantly increases the ratio of androgens to estrogens, which predisposes women to such conditions as female pattern hair loss or frontal fibrosing alopecia. Additionally, the level of sex-hormone-binding globulins is decreased due to the lack of estrogens, which usually stimulates a synthesis of this protein. As a consequence, there is higher bioavailability of free testosterone which affects functioning hair bulbs, leading to their miniaturization (11,20).

### Somatopause and skin aging

After adolescence, pituitary growth hormone secretion progressively decreases, which affects the functioning of the skin. The effects of this hormone in the skin can be easily observed in patients with

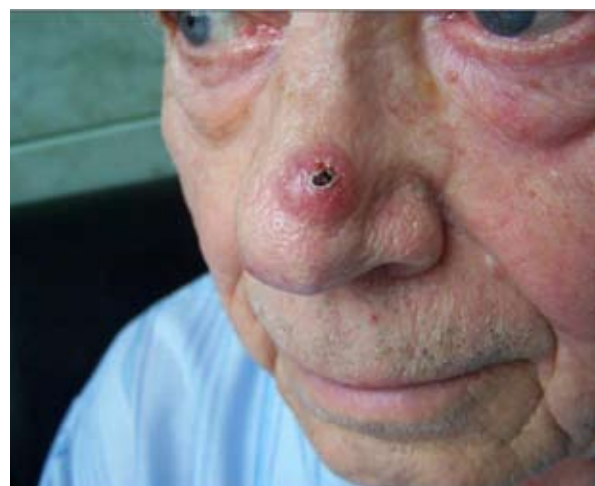
deficiency of its pituitary synthesis: content of collagen bundles is significantly reduced in skin deprived of the influence of growth hormone. Simultaneously, the activity of the sweat glands is also decreased since the functioning of these structures is also regulated by the growth hormone. Both conditions make the skin dry, flaccid, and thin, and body thermoregulation becomes impaired as well. Effort tolerance is decreased due to decreased sweating, while acral areas become significantly colder due to impaired blood supply (11).

### Exogenous factors affecting the skin aging process

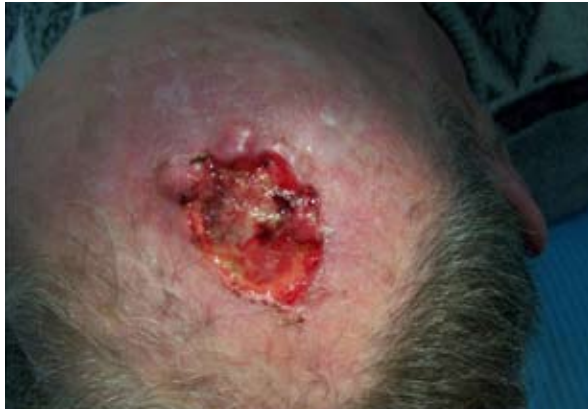There are three exogenous factors which are considered to be the main accelerators of skin aging: UV radiation, cigarette smoking, and environmental pollution.

Ultraviolet radiation is the primary factor responsible for the formation of uneven cutaneous lesions on sun-exposed areas. Biological effects triggered in the skin depend on the wavelength of UV radiation. Initially, UVB radiation was believed to play a crucial role in photo-aging. Nowadays it is obvious that both UVA and UVB radiation can induce the development of degenerative cutaneous changes (Figure 2) and what is more, these wavelengths also exert immunosuppressive and carcinogenic effects on the skin (13).

A shorter UVB wavelength (280-315 nm) is mainly absorbed in the epidermis and acts on the contained therein keratinocytes and Langerhans cells. Longer UVA wavelength (315-40 cm) penetrates deeper than UVB and affect the functioning of cells in the dermis (fibroblasts, dendritic cells, and endothelial cells of vessels). This can modulate infiltration of inflamma-



**Figure 4.** Keratoacanthoma on the nose.



**Figure 5.** Squamous cell carcinoma on the skin of the head.

tory cells (lymphocytes, monocytes, granulocytes) or induce a synthesis of free oxygen radicals. Subsequently, those oxygen derivatives cause lipid peroxidation, activate transcription factors, or upregulation of the expression of metalloproteinases, destroying the extracellular matrix. Additionally, UVA indirectly damages both nuclear and mitochondrial DNA through the induction of the release of free oxygen radicals. Shorter UVB wavelengths are also capable of generating free oxygen radicals and can also directly affect cellular DNA. UVB is responsible for generating characteristic mutations in DNA through induction of the transition of cytosine bases into thymine ones (C→T). In summary, increased exposure to both natural sources of UV (sunlight) and artificial ones (suntan beds) induces photo-aging and a development of precancerous (Figure 3 and Figure 4) or cancerous (Figure 5) conditions of the skin.

Even small daily doses of UVA can cause the thickening of both the stratum corneum and the whole epidermis. Such skin that has been over-exposed to ultraviolet radiation has a dry, earthen appearance with small wrinkles and numerous thick furrows on its surface. Facial skin damaged by sunlight can be covered with multiple horny cysts and open blackheads, which is a condition called Favre-Rachouhot disease. Other possible abnormalities of the facial skin are numerous telangiectasias or uneven pigmentations that resemble freckles and lentigines. Those cutaneous discolorations on the trunk and limbs manifest a spotty pattern called hypomelanosis guttata.

Histopathology of sun-damaged skin can reveal an increase of atypical keratinocytes in the epidermis, abnormal distribution of melanocytes along the epidermal basal layer, or a decrease in a number of Langerhans cells. Simultaneously, some infiltrations composed of lymphocytes can appear beneath the basal membrane. The epidermis can be simultane-

ously atrophic or thickened in other sites since keratinocytes often start to mature asynchronously. Long-term sun exposure affects the functioning of the dermis through UVA radiation which penetrates much deeper than UVB. It can damage stromal connective tissue through the induction of metalloproteinases, causing matrix proteolysis and therefore a degradation of collagen bundles. Simultaneously, some elastin fibers become hypertrophied in the reticular layer of the dermis, which leads to formation of a condition called senile elastosis. Blood vessels in the dermis become dilated and/or sinuous with a significant thickening of the innermost epithelial layer (13,14).

Long-term exposure to sunlight weakens the immunological and regenerative abilities of the skin. Chronic influence of UV radiation can lead to the development of numerous benign findings on the skin, such as seborrheic keratosis or a precancerous condition called as actinic keratosis (15,16).

Clinical cutaneous abnormalities in solar aging include:

- Telangiectasias, petechiae
- Whiteheads, solar blackheads
- Overgrowth of sebaceous glands (sebaceous hyperplasia)
- Small wrinkles, deep furrows
- Irregularity and roughness of the skin surface
- Skin spongiosis
- Freckles resembling cutaneous pigmentations, lentigines
- Skin discolorations (mottle depigmentation)
- Seborrheic keratosis, actinic keratosis
- Skin cancers: basal cell carcinoma and squamous-cell carcinoma (Figure 4).

#### **Histological changes in photo-aging of the skin include (16):**

- Thickening of the stratum corneum
- Atrophy of the epidermis
- Asynchronous mature of keratinocytes
- Atypia of keratinocytes
- Sunburn cells
- Thickening of the basal membrane
- Accumulation of melanocytes
- Abnormal distribution of melanocytes along the basal membrane
- Decrease of Langerhans cells
- Lymphocytic infiltrations beneath the epidermis

- Degeneration of the elastin net or collagen bundles
- Thickening of vessel walls.

### Changes observed on facial skin depend on age:

1.) Around the age of 30 years and onwards, excess skin on the upper eyelids is noticeable, leading to an appearance of ptosis in the upper eyelids. In addition, the skin is also lax around the corners of the eyes, commonly referred to as "crow's feet".

2.) Around the age of 40, nasolabial folds (furrows from nose wing to the corner of the mouth) become clearly marked, just as transverse forehead creases or frown lines (vertical lines between the eyebrows).

3.) Around the age of 50, horizontal bands of platysma become more visible, the lateral sides of the cheeks as well as the tip of nose start to prolapse.

4.) At the age of between 60-80 years there is a progressive thinning of the skin and subcutaneous tissue due to atrophy, wrinkles are more pronounced, and the skin becomes saggy (1,3).

### TREATMENT AND PREVENTION

Factors which could slowdown skin aging are still being investigated by the medical sciences. Lifestyle seems to have the main modulatory influence on skin aging. Proper diet, physical exercises, reduction of stress, and appropriate skin care are helpful, however they cannot stop the progression of skin aging. All products with biologically active substances (cosmeceuticals – combinations of cosmetics and pharmaceuticals) can inhibit skin aging, but their efficacy is also limited.

Recently widely advertised cosmeceuticals try to counteract skin aging by protecting from the deleterious influence of UV radiation or environmental pollution. It is however essential to apply cosmeceuticals systematically, which allows for better penetration into the deeper parts of the epidermis. All these products can facilitate epidermal regeneration and improve skin nourishing and hydration. Appropriate use of cosmeceuticals requires understanding of the mechanisms of their functioning in the skin. For example, light and air can decay the activity of retinol which is a component of different cosmeceuticals, therefore avoiding these factors is mandatory.

Substances which effectively prevent skin aging include:

Vitamin A and its derivatives, UVA and UVB protective filters, hydroxyl acids (especially smaller molecules as glycolic acid), or antioxidants. All of them

enhance the protective and regenerative mechanisms in the skin. Among antioxidants, the most effective are vitamin C (concentration at least 10%), krill oil, zinc, vitamin D, sea buckthorn berry oil, cocoa, red isoflavones, or hormone-substances (e.g. the soybean known as phytoestrogen).

Substances which can significantly prevent skin aging are components of the extracellular matrix in the dermis. Hyaluronic acid is a polymer of disaccharides which is responsible for the water-binding capacity of the dermis. It is distributed in spaces between collagen bundles and allows for the maintenance of skin elasticity. Another component of the extracellular matrix which regulates the moisture of the skin are mucopolysaccharidies and chondroitin sulphate (4,8,17).

### Non-invasive (non-surgical) management decreasing the effects of skin aging

Non-invasive (non-surgical) management is based mainly on superficial chemical peelings:

- Alpha-hydroxy acids and/or hydroquinones,
- Beta-hydroxy acids,
- Topical retinoids applied as peelings or for long-term use (tazarotene, adapalene).

Topical retinoids can influence the functioning and morphology of the skin through regulation of the turnover of keratinocytes. They stimulate proliferation, mainly of those cells in the lower parts of the epidermis (basal and spinous layers). Additionally, they enhance the maturation of keratinocytes, decreasing their size and adhesion and therefore preventing abnormal cornification of the epidermis. In follicular units, retinoids accelerate growth and differentiation of follicular orifices, preventing their occlusion (17,18).

Invasive management decreasing the effects of skin aging:

- Botulinum toxin,
- Face volumetry with fillers and threads lifting,
- Mesotherapy and Roll-Cit,
- Micro-dermabrasion,
- CuBr laser (578 nm),
- Pulsatile dye laser (585-600 nm),
- N-lite laser (585 nm),
- IPL (500-1100 nm),
- Nd: YAG (1064 nm),
- CoolTouch (1320 nm)
- CO2 laser.

## Fillers

Fillers are biological or artificial components which are administered as subcutaneous or intradermal injections in order to shape the outlines of the face, to fill out wrinkles, or to enlarge the lips. Biological ones include hyaluronic acid, collagen, or the patient's own adipose tissue.

Dermal collagen fillers have been used for the smoothing of wrinkles since the 1980s. Initially, they were obtained from animals and therefore their administration was complicated by allergic events in nearly 10% of patients. Currently, the use of synthetic collagen compounds with a much lower potency for hypersensitivity is preferred.

Hyaluronic acid is a polysaccharide with an identical structure in all living organisms and thus does not require skin tests to exclude allergies. The one most commonly used in aesthetic medicine is non-animal hyaluronic acid. This component is injected subcutaneously or intracutaneously with the use of a thin needle to fill superficial or deep wrinkles in the skin. Subsequently, the injected gel undergoes a natural biodegradation within 6 to 12 months.

Autogenic fat grafts are obtained under local anesthesia from the patient's subcutaneous tissue of the abdomen, hips, or buttocks with the use of a special probe. Sampled fatty tissue is separated to obtain a clear mass of adipocytes, which is next injected into the target site on the skin (nasolabial folds, lips, frown lines, etc.). The treatment must be repeated every 4 weeks to 3 months since adipocytes are quickly removed from injected sites.

Artificial dermal fillers are based mainly on Gore-Tex and polyacrylamide (aquamid from the Contura Company). Aquamid is a gel composed of water (97.5%) and polyacrylamide (2.5%). It is a biocomponent, so allergic reactions are infrequent. The effect after the administration of this filler is durable because this component is not absorbed at the site of its application. It is usually administered subcutaneously with a thin needle, but sometimes local anesthesia is necessary. This management is not recommended for correction of fine wrinkles since its administration can easily impair the surface of the skin.

Administration of all the above fillers can cause temporary swelling, redness, and ache at the site of injection (4,9).

## Botulinum toxin

Botulinum toxin is known to be the strongest biological active toxin and it is produced by gram-positive, rod-shaped, anaerobic *Clostridium botulinum*

bacteria. There are seven types of toxin (named from A to G), however only the type A neurotoxin is used in medicine.

The toxin blocks conduction of nerve impulses to muscles. It causes a paralysis of mimic muscles, with the secondary effect of loosening the skin located above it and smoothing wrinkles. Indications for its use are: wrinkles between eyebrows (frown lines), horizontal forehead creases, "crow's feet", and neck wrinkles. The treatment can be carried out without anesthesia in outpatient settings. Insulin syringes 1 ml or 2.5 ml with a 30 G needle are used for such subcutaneous or intramuscular injections. The response to the application is observed after two-three days, and the final effect is obtained after 10-14 days and lasts for 4-8 months (4,7).

## Systemic retinoids

Retinoids are derivatives of vitamin A which can modify nuclear transcription in different types of tissues, acting via their own RAR and RXR receptors. They are capable of modifying the growth and differentiation of cells. The most common indications for the use of retinoids are psoriasis and conditions with sebaceous gland hyperactivity. They exert inhibitory effects on sebaceous glands, directly decreasing lipid synthesis and causing the apoptosis of sebocytes. They also act indirectly via blockage of 3-alpha-hydroxysteroid activity of retinol dehydrogenase, therefore leading to a reduction in tissue production of androgens. Retinoids improve terminal differentiation of keratinocytes, counteracting the pathological occlusion of orifices in the pilosebaceous unit. Their anti-inflammatory properties result from an inhibitory influence on the migration of neutrophils. Additionally, a downregulation of matrix metalloproteinases (collagenase, gelatinase, stromelysin, matrilysin) in connective tissue prevents the destruction of collagen bundles. Finally, retinoids are widely considered to exert antitumor activity; they can therefore prevent development of skin cancers. Daily doses of isotretinoin can counteract skin aging at 20 mg/day for 2-3 months twice a year or at 5 mg daily indefinitely (6,19).

## References:

1. Wysong A, Kim D, Joseph T, MacFarlane DF, Tang JY, Gladstone HB. Quantifying soft tissue loss in the aging male face using magnetic resonance imaging. *Dermatol Surg* 2014;40(7):786-93.
2. Ichibori R, Fujiwara T, Tanigawa T, Kanazawa S, Shingaki K, Torii K, *et al*; Objective assessment of facial skin aging and the associated environ-

- mental factors in Japanese monozygotic twins. *J Cosmet Dermatol* 2014;13:158-63.
3. Simić-Krstić JB, Kalauzi AJ, Ribar SN, Matija LR, Misevic GN. Electrical properties of human skin as aging biomarkers. *Exp Gerontol* 2014;3:163-7.
  4. Han A, Chien AL, Kang S. Photoaging. *Dermatol Clin* 2014;32:291-9.
  5. Trojahn C, Dobos G, Schario M, Ludriksone L, Blume-Peytavi U, Kottner J. Relation between skin micro-topography, roughness, and skin age. *Skin Res Technol* 2014;3:124-9.
  6. Choi YH, Kim D, Hwang E, Kim BJ. Skin texture aging trend analysis using dermoscopy images. *Skin Res Technol*. 2014;2:139-43.
  7. Chen Y, Lyga J. Brain-skin connection: stress, inflammation and skin aging. *Inflamm Allergy Drug Targets* 2014;13:177-90.
  8. Babizhayev MA, Vishnyakova KS, Yegorov YE. Oxidative Damage Impact on Aging and Age-Related Diseases: Drug Targeting of Telomere Attrition and Dynamic Telomerase Activity Flirting with Imidazole-Containing Dipeptides. *Recent Pat Drug Deliv Formul* 2014;2:198-207.
  9. Suggs A, Oyetakin-White P, Baron ED. Effect of botanicals on inflammation and skin aging: analyzing the evidence. *Inflamm Allergy Drug Targets* 2014;13:168-76.
  10. Godic A, Poljšak B, Adamic M, Dahmane R. The role of antioxidants in skin cancer prevention and treatment. *Oxid Med Cell Longev* 2014;7:860479.
  11. Werner S. Prurigo in the elderly. When the skin itches and burns. *Pflege Z* 2014;67:184-185.
  12. Goldberg LD, Crysler C. A single center, pilot, double-blinded, randomized, comparative, prospective clinical study to evaluate improvements in the structure and function of facial skin with tazarotene 0.1% cream alone and in combination with GliSODin (®) Skin Nutrients Advanced Anti-Aging Formula. *Clin Cosmet Investig Dermatol* 2014;7:139-44.
  13. Puglia C, Offerta A, Saija A, Trombetta D, Venera C. Protective effect of red orange extract supplementation against UV-induced skin damages: photoaging and solar lentigines. *J Cosmet Dermatol* 2014;13:151-7.
  14. Nishigori C. Solar ultraviolet light and pathogenesis of skin cancer – diagnosis, treatment, prevention update. *Gan To Kagaku Ryoho* 2014;41:441-4.
  15. Bhattacharyya TK, Pathria M, Mathison C, Vargas M, Thomas JR. Cosmeceutical effect on skin surface profiles and epidermis in UV-B-irradiated mice. *JAMA Facial Plast Surg* 2014;7:96-102.
  16. Min W, Liu X, Qian Q, Lin B, Wu D, Wang M, *et al*. The effects of baicalin against UVA-Induced photoaging in skin fibroblasts. *Am J Chin Med* 2014;42:709-27.
  17. Amaro-Ortiz A, Yan B, D' Orazio JA. Ultraviolet radiation, aging and the skin: prevention of damage by topic alcAMP manipulation. *Molecules* 2014;19:6202-19.
  18. Werner S. Expert tells what is involved in nursing care of the aging skin. Not too dry, not too grease. *Pflege Z* 2014;67:152-5.
  19. Oliveira MB, do Prado AH, Bernegossi J, Sato CS, Lourenço Brunetti I, Scarpa MV, *et al*. Topical application of retinylpalmitate-loaded nanotechnology-based drug delivery systems for the treatment of skin aging. *Biomed Res Int* 2014;2014:632570.
  20. Miziołek B, Brzezińska-Wcisło L, Wcisło-Dziadecka D, Zbiciak-Nylec M. Trichological problems related to menopause. *Post N Med* 2015;28:211-6.