



UDK 616.28-008.5-07
Review
Received: 17 January 2007
Accepted: 25 April 2007

ELECTROPHYSIOLOGICAL METHODS IN THE DIAGNOSTICS OF VERTIGO

Ivan Mikula

University Department of Neurology, Sestre Milosrdnice University Hospital, Reference Center for Neurovascular Disorders of the Ministry of Health and Social Welfare of the Republic of Croatia, Zagreb, Croatia

Summary

The role of neurophysiologic tests in the diagnostics of vertigo primarily consists of assessing the functional status of the sensory systems responsible for the concept of space. They also have a limited application in assessing the functional status of structures responsible for the integration of this information. The data obtained by neurophysiological testing are purely functional giving no information considering the etiology of the disturbance, and only point to the localization and type of the disturbance that lead to vertigo. That is why they always need to be combined with neuroradiologic, neurosonologic and laboratory tests. The brain relies on three sensory systems to maintain spatial orientation: the vestibular system (the inner ear), the visual system (the eyes), and the somatosensory system (which conveys information from the skin, joint, and muscle receptors). These three systems overlap, allowing the brain to assemble an accurate sense of spatial orientation. Information from these systems is integrated in the cerebrum and cerebellum. However, a compromised system or conflicting signals can cause vertigo

Key words: Neurophysiological diagnostic tests, vertigo, electromyography, evoked potentials

Considering the manner in which the concept of space is formed in the human brain, we might say that, under normal circumstances, the brain relies on three sensory systems to maintain spatial orientation: the vestibular system (the inner ear), the visual

Correspondence to: Ivan Mikula, University Department of Neurology, Sestre milosrdnice University Hospital, Reference Center for Neurovascular Disorders of the Ministry of Health and Social Welfare of the Republic of Croatia
Vinogradska 29, Zagreb, Croatia
E-mail: ivan.mikula@zg.t-com.hr

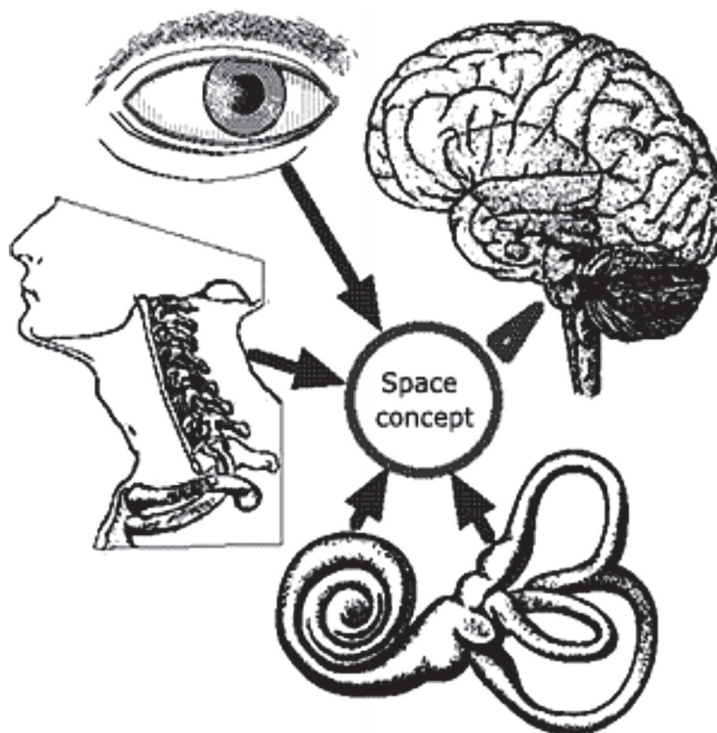


Figure 1. Space concept

system (the eyes), and the somatosensory system (which conveys information from the skin, joint, and muscle receptors). These three systems overlap, allowing the brain to assemble an accurate sense of spatial orientation [1]. Information from these systems is integrated in the cerebrum and cerebellum. However, a compromised system or conflicting signals can cause vertigo.

Among the proven causes of cervical vertigo, we count the vascular compression and the abnormal sensory input from the proprioceptive receptors. Vertebral arteries can be pressed by the nearby vertebrae or by local connective tissue structures. Other possible reasons include surgical procedures in the region and the chiropractic manipulation. The sensory information originating from cervical receptors can be absent or unreliable. Some individuals are more prone to this kind of damage, especially if there is any disturbance of function of other generators of information concerning the body position in space.

Electromyography (EMG) records the electric potential generated by muscle fibers in contraction or resting. It gives us indirect information about the state of cervical



receptors, by means of assessing the state of cervical nerve roots and the peripheral nerves originating from them. Combining EMG with measurement of the motor and sensory nerve conduction velocities, we also assess the function of the peripheral nerves [2].

For the orientation testing, we test the muscle activity at rest, during the maximum voluntary contraction and during moderate activity, from 10 needle positions in one muscle (2-3 needle placements, with rectangular needle movement). In special indications the exact analysis of motor unit action potentials is required (at least 20 potentials/muscle). We examine the number of phases and the duration of potentials.

Some significant pathologic changes that can be observed in a muscle at rest include: prolonged insertion activity, fasciculations, fibrillations, pseudo-myotonic discharges and positive sharp waves.

Insertion activity is the response of muscle fibers to a needle prick. It normally consists of short spike-shaped muscle potentials, which last a few seconds and promptly disappear after the needle is removed. It is shortened in fibrosis and fat degeneration, and prolonged in early denervation and myotonic disturbances.

Fibrillations are the earliest signs of neurogenic lesions. They appear 3-4 weeks after the neural damage, and disappear with the occurrence of re-innervation. They are short-lasting (<3 ms), of low amplitude (<300 μ v), and appear in partly rhythmic intervals (<30/s), although sometimes it seems that the frequency of discharge is purely accidental. They may reappear with each new movement of the needle.

Positive sharp waves represent the most certain sign of neurogenic lesions. They look like very sharp positive deflections from the baseline, followed by a slower return to the baseline, often with a short negative phase before the return to the baseline. The amplitude of these waves may reach up to 1 mv, and their duration is about 50 ms. They appear in very regular intervals. They usually occur and disappear abruptly and the rhythm of their occurrence seldom varies.

Fasciculations are spontaneous discharges of entire motor units in irregular intervals and they appear as normal motor unit action potentials (MUP). We tell them apart from the normal MUP by their occurrence at rest and their irregular rhythm of firing. Many so called fasciculations are in fact a result of an inadequate relaxation of the muscle. The true fasciculation will always cause a visible movement of the needle, while that does not happen in a badly relaxed muscle.

Normal EMG pattern has the following features: no spontaneous activities, thick interference pattern during the maximum contraction, 2-3-phasic motor unit potentials, and medium duration of a single potential [3].



Myopathic EMG pattern has the following features: no spontaneous activities, early interference pattern development, inadequate development of strength due to the phenomenon of early recruitment of motor units, interference pattern of low-amplitude, motor-unit potentials are low, short and polyphasic. There is a characteristic de-synchronization of the muscle activity, resulting in the typical sound, which is often described as a "metal scratching" [4,5].

Neuropathic EMG pattern is characterized by positive sharp waves and biphasic fibrillations at rest and a reduced interference pattern with individual high-amplitude potentials, while motor unit potentials are prolonged and polyphasic. Prominent features are a temporal compensation ("central driving"), when the remaining PMU fire in higher frequency (25-40 Hz), and a spatial compensation, where the remaining potentials are high and wide (over 12 ms, over 15 mV). The sound of these gigantic potentials is often described as "banging, drumming, thunder".

Complex repetitive discharges, known also as the high-frequency or bizarre repetitive potentials, consist of long series of fast firing potentials, characterized by an abrupt beginning and ending. These potentials are of low-voltage and short duration, with a tendency of grouping, and they fire with frequency of 20-40 Hz. They are mostly of a constant amplitude and frequency. They can be seen in various myopathic and neuropathic diseases.

In diseases where the transmission at neuromuscular junction is so impaired that it results with errors in transmission or completely fails, some fibers get excluded from the motor unit that reacts to the stimulus. If the number of excluded fibers is big enough, this can be observed as a change of the potential morphology during the repetitive stimulation. The presence of such disturbances can be manifested as flickering (jitter) of the potential, or in more severely affected muscles, as a decrease of amplitude after the repetitive stimulation.

Myography is regularly combined with measurements of maximal sensory and motor nerve conduction velocities, which help determine the level of the neurogenic lesion. Normal values of nerve conduction velocities are different for different nerves, even for different segments of the same nerves. They also depend on the skin temperature - 1-2 m/s°C. Using a stimulus that exceeds the threshold, we trigger an action potential in the nerve, and it spreads antidromically and orthodromically. In axonal lesions, we find a slight reduction of conduction velocities, but a significant reduction of amplitudes. In demyelinating lesions, there is a significant reduction of nerve conduction velocities.

Apart from measuring nerve conduction velocities, we also make reflexologic tests. Their primary applications are in testing the proximal, inaccessible part of the nerve and in a better assessment of the function of the afferent segment of the reflex arc. These tests



are F-wave latencies and H-reflex on the extremities and blink reflex on the face. The blink reflex is obtained by means of stimulating the skin above the eye, where the afferents of the trigeminal nerve are located (ophthalmic branch, supraorbital nerve), and registering the electrical activity on both mm. orbiculares oculi (n. facialis).

In neurophysiology an *evoked potential* (or “evoked response”) is an electric potential that is registered from a human or animal scalp after presentation of a certain kind of stimulus (as opposed to spontaneous electrical activities such as electromyography and electroencephalography) [6]. The amplitudes of evoked potentials are low, under few microvolts. To extract this low-amplitude signal from the surrounding noise and analyze it, it is necessary to average and amplify the signal. Early sensory evoked potentials were widely used in clinical medicine from 1970, namely SSEP (somatosensory), VEP (visual) and BAER (brainstem auditory evoked response), particularly in the diagnostics of demyelinating diseases. Nowadays, the late evoked potentials have also found their clinical application, particularly ERP (event-related, cognitive potentials), primarily in the diagnostics of dementias.

SSEP are elicited by applying a mild electrical shock to the peripheral nerve, **VEP** by watching the lighted checkerboard pattern (PSVEP, pattern shift visual evoked potential) or flash stimulation (LED or flashing lamp) and **BAER** by presenting the stimulus over light headphones.

Gustatory and olfactory evoked potentials are also used, although their clinical application is rather limited.

The importance of the clinical application of **cognitive and transcranial motor** potentials is increasing.

Indications for BAER testing are: suspected neurinomas of statoacoustic nerve which could not with certainty be diagnosed using other diagnostic methods, follow-up of the recovery of brainstem functions after the compression or during some surgical procedures, localization of central nervous system lesions which are detectable by means of neurological examination, but not by neuroradiologic testing (CT or MRI scan), diagnosis of the demyelinating diseases which affect the brainstem, evaluation or screening for hearing impairment in newborns and infants. They are also used as an accessory diagnostic method for the verification of brain death [7,8].

Indications for SSEP testing are myelopathies of unknown etiology, spinocerebellar and olivocerebellar degenerations, localization of central nervous system lesions which are detectable by means of neurological examination, but not by neuroradiologic testing (CT or MRI scan), identification of clinically silent lesions in persons with suspected multiple sclerosis or Pelizaeus-Merzbacher’s disease, for preoperative or intraoperative testing in persons due for surgical procedures on the spinal medulla. They are also used as an accessory diagnostic method for the verification of brain death.



The most common disturbances of vision that cause vertigo are abnormal movements of eyeballs, loss of vision acuity, differences of picture size, binocular conflicts and a reduction of visual field [9]. *Indications for VEP* are diagnostics of optical neuritis and multiple sclerosis, localization of visual system lesions which are detectable by means of neurological examination, but not by means of neuroradiologic testing (CT or MRI scan), and testing of vision in infants and newborns or persons unable to achieve verbal contact.

In the frame of diagnostics of cerebral functions, we can also test the *cognitive evoked potentials*. This test is mostly recommended for dementias and other disturbances of the higher brain functions. The most frequently tested component is P300 wave, which is registered above the frontal and parietal cortex as a response to target stimulus [10].

The *role of neurophysiologic tests in the diagnostics of vertigo* primarily consists of assessing the functional status of the sensory systems responsible for the concept of space, described earlier in the text. They also have a limited application for assessing the functional status of structures responsible for the integration of this information [11]. The data obtained by neurophysiological testing are purely functional and give no information considering the etiology of the disturbance, but only point to the localization and type of the disturbance that lead to vertigo. That is why they always need to be combined with neuroradiologic, neurosonologic and laboratory tests.

References

- [1] Loughran S, Tennant N, Kishore A and Swan IRC. Interobserver reliability in evaluating postural stability between clinicians and posturography. *Clinical Otolaryngology* 2005;30:3,255-257
- [2] Binnie C, Cooper R, Mauguiere F, Osselton J, Prior P and Tedman B. *Clinical Neurophysiology, Volume 1:EMG, Nerve Conduction and Evoked Potentials*. London: Elsevier; 2004, str. 100-453.
- [3] Chen CH, Young YH. Vestibular evoked myogenic potentials in brainstem stroke. *Laryngoscope* 2003;113(6):990-3.
- [4] Cruccu G, Iannetti GD, Marx JJ, Thoenke F, Truini A, Fitzek S, et al. Brainstem reflex circuits revisited. *Brain* 2005;128:386-394.
- [5] Ferber-Viart C, Dubreuil C., Duclaux R. Vestibular Evoked Myogenic Potentials in Humans: a Review. *Acta Otolaryngol* 1999;119:6-15.
- [6] Itoh A, Kim YS, Yoshioka K, Kanaya M, Enomoto H, Hiraiwa F, et al. Clinical Study of Vestibular-evoked Myogenic Potentials and Auditory Brainstem Responses in Patients with Brainstem Lesions. *Acta Otolaryngol* 2001;Suppl 545:116-119.
- [7] Sartucci F, Logi F. Vestibular-evoked myogenic potentials: A method to assess vestibulo-spinal conduction in multiple sclerosis patients. *Brain Res Bul* 2002;59:59-63.



- [8] *Versino M, Colnaghi S, Callieco R, Bergamaschi R, Romani A, Cosi V.* Vestibular evoked myogenic potentials in multiple sclerosis patients. *Clin Neurophysiol* 2002;113:1464-1469.
- [9] *Victor M, Ropper A.* Cerebrovascular diseases. In: *Wonsiewicz M, Medina M, Navrozov M, editors. Principles of Neurology. 7th ed. International Edition. New York: McGraw-Hill; 2001,220-223.*
- [10] *Vila N, Valls-Sole J, Obach V, Saiz A, Alday M, Chamorro A.* Blink reflex in patients with Wallenberg's syndrome. *J Neurol* 1997;244:30-34.
- [11] *Welgampola MS, Colebatch JG.* Vestibulocollic reflexes: normal values and the effect of age. *Clin Neurophysiol.* 2001;112(11):1971-9.

Sažetak

Elektrofiziološke metode u dijagnostici vrtoglavica

Uloga neurofizioloških pretraga u dijagnostici vrtoglavica primarno se sastoji u utvrđivanju funkcionalnog statusa senzornih sustava odgovornih za stvaranje koncepta prostora. Primjenjive su donekle i u određivanju stanja integrativnih neuralnih struktura, koji objedinjuju informacije dobivene iz istih senzornih sustava. Podaci dobiveni neurofiziološkim pretragama isključivo su funkcijskog karaktera i ne daju nikakvu informaciju o etiologiji poremećaja, već upućuju samo na lokalizaciju i vrstu poremećaja koji je doveo do vrtoglavice, te se uvijek moraju kombinirati s neuroradiološkim, neurosonološkim i laboratorijskim ispitivanjima. Obzirom na način stvaranja koncepta prostora u ljudskom mozgu, potencijalni generatori vrtoglavice su oči (koje prenose vidnu informaciju), unutarnje uho (koje prenosi slušnu i vestibularnu informaciju), cervikalni receptori (koji prenose proprioceptivnu informaciju), te mali i veliki mozak (čija je uloga u integraciji ovih informacija). Ovi sustavi se nadopunjavaju, omogućavajući mozgu da stvori točnu informaciju o položaju u prostoru. Neurofiziološka ispitivanja ovih struktura predstavljaju temelj neurofiziološke dijagnostike vertiginoznih smetnji.

Ključne riječi: Neurofiziološki dijagnostički testovi, vertigo, elektromiografija, evocirani potencijali

