



UDK 616.831-005.1:616.3
Original scientific paper
Received: 17 January 2007
Accepted: 25 April 2007

THE INFLUENCE OF VERTEBRAL ARTERY OCCLUSION ON VISUAL EVOKED RESPONSES IN POSTERIOR CEREBRAL ARTERY

Marijana Bosnar Puretić, Arijana Lovrenčić Huzjan,
Marina Roje Bedeković, Vida Demarin

University Neurology Department, Sestre Milosrdnice University Hospital, Zagreb
Reference Center for Neurovascular Disorders of the Croatian Ministry of Health

Summary

Stroke is the second leading cause of death and the leading cause of disability in Croatia. One-quarter of all ischemic strokes occur in the posterior circulation. One third of ischemic strokes are caused by large artery diseases. Transcranial Doppler sonography (TCD) is a non-invasive method with an excellent temporal resolution for real time investigations of cerebral hemodynamics and, among other methods, functional TCD tests are very useful tools for establishing the cerebral vasomotor capacity. TCD studies revealed that a proximal stenosis in the carotid circulation severely influences distal cerebral hemodynamics and autoregulative mechanisms.

The aim of this study was to establish the influence of a vertebral artery (VA) occlusion on visual evoked responses in the posterior cerebral artery (PCA) measured by means of TCD.

We measured mean blood flow velocities (MBFVs) in the PCA before and during a visual stimulation in patients with a VA occlusion by means of TCD.

Without visual stimuli there was no significant difference between the control group and the patients with a VA occlusion. During white light stimulation a statistically significant increase of MBFVs in the PCA in both groups occurred. In the control group the increase was $22.85 \pm 20.9\%$ for the right PCA and $20.67 \pm 15.31\%$ for the left PCA. In the group of patients with a VA occlusion the increase in the right PCA was $12.3 \pm 16.46\%$ and in the left PCA $11.89 \pm 13.08\%$. In the patients with a VA occlusion repeated testing led

Correspondence to: Marijana Bosnar Puretić, University Department of Neurology, Sestre milosrdnice University Hospital, Reference Center for Neurovascular Disorders of the Ministry of Health and Social Welfare of the Republic of Croatia
Vinogradska 29, Zagreb, Croatia
E-mail: mbos-puretic@inet.hr



to diminished responses, which could be an indicator of the exhaustion of the cerebrovascular vasomotor reserve.

Based on the results of our study we can conclude that there is a negative effect on the functioning of the distal small vessels in the case of a VA occlusion. Visually evoked functional TCD testing is a non-invasive and precise method for the estimation of vasoreactivity in the posterior circulation.

INTRODUCTION

Stroke is the second leading cause of death and the leading cause of disability in Croatia. One-quarter of all ischemic strokes occur in the posterior circulation [1]. One third of ischemic strokes are caused by large artery diseases; in the posterior circulation a vertebral artery (VA) occlusion has a significant role. Vertebral artery stenoses and occlusions account for approximately 20% of the posterior circulation strokes [2]. The most common cause of a VA occlusion is the development of an atherosclerotic plaque, but in a significant number of cases a distal embolism is present. In the extracranial part, a VA could be occluded due to the dissection of the artery, mostly after a traumatic event [3,4].

When an occlusion of the proximal VA occurs, ischemic events develop only in 9% of cases [5], the reason lies in good compensatory pathways. The most important one is an intact contralateral vertebral artery. In the case of a hypoplastic VA or additional vascular pathology the risk of an ischemic event in the vertebrobasilar territory and the development of posterior syndromes is higher [6,7].

Cerebral perfusion is maintained constant in different conditions due to protective mechanisms, cerebral autoregulation and cerebral vasoreactivity. Also, the cerebral circulation responds promptly to increased metabolic demands due to neuronal activity, known as neurovascular coupling. These three mechanisms are functioning on the level of small cerebral vessels, arterioles and capillaries. It is possible to make conclusions about the functioning of one mechanism based on the test results of one of the others because all three are representing the capability of cerebral vessels to constrict or dilate after some stimuli [8-11].

The introduction of the transcranial Doppler (TCD) in neurological diagnostic procedures and scientific studies enabled the estimation of the cerebral circulation in real time. Mean blood flow velocities (MBFVs) measured by TCD represent the size of the cerebral blood flow. Due to the very high temporal resolution of this method it is possible to watch and quantify the changes of the cerebral blood flow after different stimuli [12,13].

In the case a significant stenosis or occlusion of the cerebral artery, the distal blood flow remains normal if the collateral pathways and cerebral autoregulation function



properly. Some acute cerebral diseases, as well as chronic diseases like arterial hypertension, diabetes mellitus, atherosclerosis and others, impair the capacity of small cerebral vessels to constrict and dilate, with an inadequate compensation of the blood flow distal to the stenosis as a consequence. Previous studies investigated in detail the influence of a proximal internal carotid artery stenosis on the cerebral autoregulation in the area of the middle cerebral artery (MCA) [14]. They also revealed an association between the internal carotid artery stenosis, impaired autoregulation in the MCA and increased risk of an ipsilateral stroke. When the same tests were repeated after the carotid endarterectomy, the results showed a significant improvement [15,16]. Investigations of cerebral vasoreactivity, autoregulation and neurovascular coupling in the area of the posterior circulation are not as numerous as in the area of the MCA. In the posterior circulation a very reliable way of testing the neurovascular coupling is measuring the responses in the posterior cerebral artery (PCA) to light stimulation, as it is known that the light is the most powerful stimulus of metabolism in the visual cortex. This kind of testing was performed for the first time by R. Aaslid who found that MBFVs in the PCA significantly rose during watching at the white light [17].

The aim of this study was to investigate the velocity changes in the PCA during visual stimulation in patients with a VA occlusion by means of TCD. The main hypothesis in our study was that visually evoked flow responses in the PCA were reduced in patients with a VA occlusion.

Patients and methods

This study was performed in the Cerebrovascular Laboratory of the University Neurology Department, Sestre Milosrdnice University Hospital in Zagreb. It was a prospective study which included in- and outpatients with a VA occlusion. The same diagnostic tests were performed in the age and sex matched control group. Excluded from the study were patients with an intracranial stenosis of cerebral vessels, unconscious and demented patients and patients with hypertension and diabetes mellitus.

The VA occlusion in all patients was diagnosed by means of Color Doppler Flow Imaging using the Acuson 128 XP/10 device, Mountain View, California. For morphologic investigation a 7.5MHz linear probe, and for hemodynamic investigation a 5MHz probe were used. The VA occlusion was diagnosed according to the previously published criteria [18].

Transcranial Doppler sonography of the Willis circle and the vertebrobasilar region was performed using the MultiDop X4 DWL device, Electronische Systeme GmbH, Sipplingen, with a 2MHz probe. During the testing of the visual evoked flow responses in the PCA, a simultaneous recording of both PCAs by two Doppler channels was performed, using the software application for the evoked flow.

During the testing the patients were placed in a supine position in a quiet, dark room. The testing started after a 10 minute accommodation period with the patient's eyes closed. Both PCAs were insonated simultaneously through the temporal window in the P1 segment [13]. For light stimulation we used a light bulb of 100W placed 50cm far from the patient's eyes. First we measured MBFVs with the patient's eyes open, but without the light stimulation; thus obtained velocities were considered as MBFVs in basic, neutral conditions. Then the patient rested with the eyes closed for two minutes. After this period, MBFVs in both PCAs were measured for one minute with the patient's eyes closed. Then the patient was asked to open the eyes and to look at the light for one minute during which MBFVs in both PCAs were measured. These recordings were repeated three times in each patient, in the control group as well. For the visual evoked response calculation we took the mean value of MBFVs recorded during the one minute testing period. The size of the response was defined as the percentage of the PCA MBFVs change after light stimulation, as compared with the PCA MBFVs with subjects' eyes closed.

Statistical analysis was performed using standard statistical software. All results were presented as mean values with standard deviations. The differences between measurements were established using the T test and Kolmogor-Smirn test. For statistical significance the p value <0.05 was used.

Results

We investigated 30 patients with a VA occlusion, 24 males and 6 females. The mean age of the patients was 60.73 ± 11.63 years. The control group was age and sex matched and consisted of 26 subjects examined in our Cerebrovascular Laboratory on the basis of

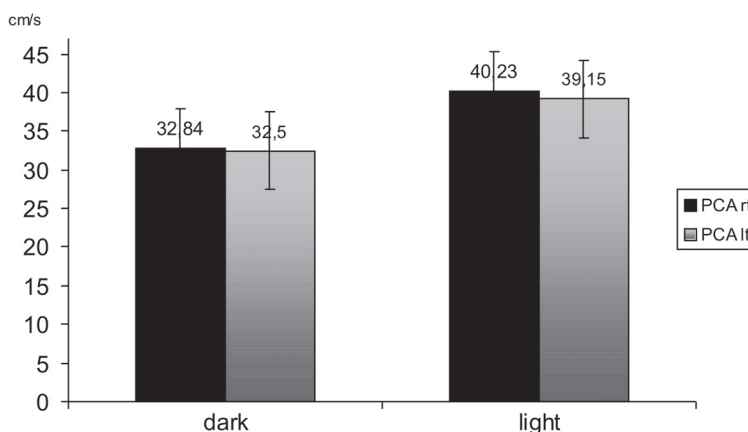


Figure 1. Visually evoked flow responses in the PCA in the control group.

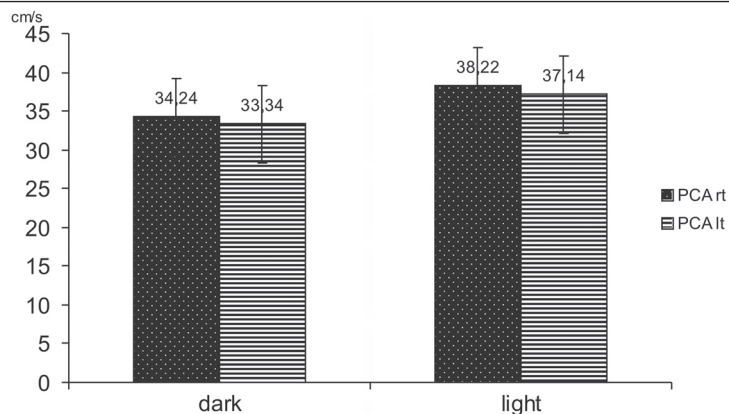


Figure 2. Visually evoked flow responses in the PCA in the patients with a vertebral artery occlusion.

cerebrovascular risk factors, but without any evidence of cerebrovascular diseases. In the male group most of the patients with a VA occlusion were in the age group between 55 and 74 years. In 57% of the patients the right VA was occluded, in 23% the left VA and in 20% both VAs were occluded. Majority of VA occlusions (58%) occurred in the extracranial part of the VA.

During recording of MBFVs in basic conditions, MBFV in the PCA did not differ significantly between patients and controls. In the control group MBFVs in the right VA were 36.3 ± 12.4 cm/s and in the left VA 35.61 ± 13.3 cm/s. In the patient group MBFVs in the right VA were 37.03 ± 12.9 cm/s and in the left VA 35.60 ± 11.52 cm/s. In the control group MBFVs in the PCA rose from 32.84cm/s in the right VA and 32.5cm/s in the left VA during the one minute recording in darkness to 40.23 cm/s in the right VA and 39.15cm/s in the left VA during the one minute recording with the light stimulus on. In the

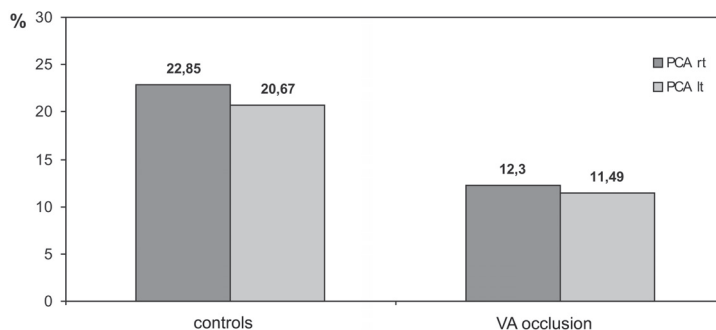


Figure 3. Percentage of visually evoked responses in both groups

patient group MBFVs in the PCA rose from 34.24cm/s in the right VA and 33.34cm/s in the left VA during the one minute recording in darkness to 38.22 cm/s in the right VA and 37.14 cm/s in the left VA during the one minute recording with the light stimulus on. In the control group the increase of MBFVs in the PCA during light stimulation was $22.85 \pm 20.9\%$ for the right and $20.67 \pm 15.31\%$ for the left PCA. In patients with a VA occlusion the right PCA showed increase of MBFVs by $12.3 \pm 16.46\%$ and the left PCA showed increase by $11.89 \pm 13.08\%$ (Figure 3). The visual evoked responses for the both groups and the comparison of responses in the form of percentages are shown in Figure 1 and 2. During the three consecutive testing periods, the values of MBFVs in the PCA in the patient group decreased for both types of conditions (darkness or white light) (Figure 4).

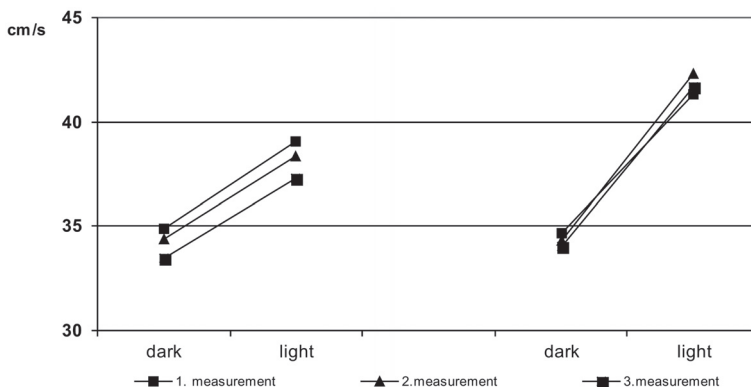


Figure 4. Reduction of evoked flow responses during repeated testing in patients with a VA occlusion in contrast with constant responses in the control group.

Discussion

Cerebrovascular ischemic incidents are in 30% of cases caused by large artery diseases. They are more frequent in the male population in the age group between 55-75 years. Our results showed a distribution of patients according to age and gender similar to the results of previous studies [19,20].

According to previous studies, 20% of ischemic events in the vertebrobasilar territory are caused by heart embolism and 20% by intraarterial embolism, usually from the VA [21]. The atherothrombotic process has a major role in vertebrobasilar ischemia. Usually it is located in the proximal, V1 part of the VA which is concordant with our results; 58% of VAs were occluded in the extracranial part. Similar to previous studies, our results showed that more often the right VA occlusion occurs [18]. Possible explanation is a vertebral artery hypoplasia that affects more often the right VA. This is a frequent inborn



condition, with a narrow lumen of the VA, 2mm in diameter or less. In a hypoplastic VA the hemodynamics is changed and the VA is more prone to an atherothrombotic process and occlusion [22-24].

MBFVs in the PCA with eyes open, without additional light stimuli, did not differ significantly between the control group and the patients with a VA occlusion. This is probably the result of a good compensatory mechanism of pathological changes in basic, physiological conditions.

During looking at a white light, in all investigated subjects occurred the increase of MBFVs in the PCA. This kind of study was for the first time performed in healthy volunteers by R. Aaslid in 1987. During watching at a white light MBFVs in the PCA rose for 16.4% and the regional blood flow volume rose for 20.2%. These changes developed in a very short time; 50% of the increase occurred in only 2.3 seconds [17]. Trkanjec and Demarin performed a similar study, but using different modes of light stimulation. Results showed that a flash light induced a greater response than continuous white light stimuli. Also, the responses depended of the wave-length of the light stimuli [23].

In our study results showed significantly lower responses in the PCA to light stimuli in the patients with a VA occlusion. Similar results were presented in the study of Urban, who performed similar testing in patients with an occipital infarction [26]. Before the light stimulation, MBFVs in the PCA in 13 patients and in the control group did not differ significantly. But, during the light stimulation in the control subjects MBFVs in the PCA rose for $30.6 \pm 9.7\%$ and in the patient group this response was significantly lower, $3.4 \pm 4.1\%$. The magnitude of the response in patients depended on the size of the occipital lobe infarction. Haubrich et al. performed a dynamic cerebral autoregulation testing distally to the severe bilateral vertebral artery disease where they detected autoregulatory deficits of different degrees [27].

This kind of functional testing of the cerebral vasculature by means of TCD is more often involving the carotid circulation pathology. Responses to functional stimuli in patients with a carotid disease are good indicators of the autoregulative, vasoreactive capacity of small cerebral vessels distal to the stenosis or occlusion. Silvestrini et al. showed in their study the change of MBFVs in the middle cerebral artery (MCA) during a two-minute task of moving the fingers in patients with a significant carotid artery stenosis. In the control group MBFVs in the MCA rose for $5.52 \pm 2.4\text{cm/s}$. In the patient group on the side of the carotid stenosis MBFVs increased by $1.76 \pm 1.6\text{cm/s}$ and on the contralateral, healthy side the increase was $3.82 \pm 2.1\text{cm/s}$. After carotid endarterectomy (CEA), the response to motoric stimuli improved and differences between sides became insignificant [16]. In similar groups of patients with a carotid disease before and after CEA Demarin et al. performed vasoreactivity testing using acetazolamide (Diamox, 1000mg), one of the currently used tests for cerebrovascular reactivity assessment. This



carboanhydrase inhibitor increases the CO_2 level in blood and the hypercapnia is used as the most potent vasodilatory stimulus for testing the cerebrovascular reactivity [28]. Patients with a carotid stenosis showed weaker responses after acetazolamide administration. On the side of the stenosis, the impairment of vasoreactivity correlated with the degree of stenosis. After the surgery, a significant recovery of vasoreactivity occurred¹⁵. Testing of the vasomotor reserve in patients with a carotid disease was also used as a possible predictor of ischemic events in the distal area [29,30].

In investigated subjects the measurement of MBFVs in the PCA was performed in three consecutive sequences. In the group of patients with a VA occlusion in every subsequent measurement, during resting as well as during the watching at the white light, MBFVs in the PCA became lower. The differences between the first and the third measurement were statistically significant. The possible explanation is the habituation during the repeated stimulation, but the possible cause lies in the exhaustion of the vasomotor reserve distal to the vertebral artery occlusion. In the control group we did not find any significant decrease of MBFVs in the PCA in the second and third sequence of testing.

Due to the anatomical position of VAs and the limited diagnostic and therapeutic possibilities, very few studies have dealt with vertebral artery pathology. Also, very few studies have dealt with the impaired autoregulation, vasoreactivity and neurovascular coupling in the posterior circulation up to now.

The advantages of functional testing by means of transcranial Doppler are non-invasiveness and regional selectivity. This is especially valid for the PCA and visual cortex, due to the exclusive irrigation of the visual cortex by PCAs, and very precise relations between the light stimulation, increase of neural metabolism and blood flow volume in the visual cortical area. Neurovascular coupling is functioning on the level of small cerebral vessels, which means that conditions that impair the cerebral autoregulation and cerebral vasoreactivity also affect the neuronal coupling. The diminished response after functional stimulation can be addressed to the functional or structural impairment of the neuronal area, impaired neurovascular coupling or compromised hemodynamics due to a proximal stenosis or occlusion [11].

The diminished answer in the PCA during light stimulation in the patients with a VA occlusion in our study probably reflects the hemodynamic impairment of the posterior circulation, which is not able to react properly to increased metabolic demands of the visual cortex. Also, it is possible that such results are also the consequence of a structural injury of the visual cortex, since in some patients a brain CT scan revealed ischemic changes in the PCA area.

Functional testing of the visual cortex by means of TCD is a non-invasive and reliable method for estimating the vasomotor reserve. In this study it revealed the impairment of the vasomotor reserve distal to the VA occlusion. The results of this study could



help in further investigations aimed at establishing the risks of ischemic events in the posterior circulation.

References

- [1] *Bernasconi A, Bogusslavsky J, Bassetti C, Regli F.* Multiple acute infarcts in the posterior circulation. *J Neurol Neurosurg Psychiatry* 1996;60:289-296.
- [2] *Khan S, Cloud G, Kerry S, Markus HS.* Imaging of vertebral artery stenosis: A systematic review. *J Neurol Neurosurg Psychiatry* 2007 Feb 7; [Epub ahead of print]
- [3] *Caplan LR, Amarenco P, Rosengart A, Lafranchise EF, Teal PA, Belkin M, DeWitt LD, Pessin MS.* Embolism from vertebral artery origin occlusive disease. *Neurology* 1992;42:1505-12.
- [4] *Iwase H, Kobayashi M, Kurata A, Inoue S.* Clinically unidentified dissection of vertebral artery as a cause of cerebellar infarction. *Stroke* 2001;32:1422-4.
- [5] *Wityk RJ, Chang HM, Rosengart A, Han WC, DeWitt LD, Pessin MS, Caplan LR.* Proximal extracranial vertebral artery disease in New England medical center posterior circulation registry. *Arch Neurol* 1998; 55:470-8.
- [6] *Chaturvedi S, Lukovits TG, Chen W, Gorelick PB.* Ischemia in the territory of a hypoplastic vertebralbasilar system. *Neurology* 1999; 52:980-3.
- [7] *Perren F, Poggia D, Landis T, Sztajzel R.* Vertebral artery hypoplasia: a predisposing factor for posterior circulation stroke? *Neurology* 2007 Jan 2;68(1):65-7.
- [8] *Thaller N.* Fiziologija i patofiziologija moždanog krvotoka. In: Demarin V, Štikovac M, Thaller N. *Doppler sonografija krvnih žila.* Zagreb: Školska knjiga; 1990. p. 24-36.
- [9] *Aaslid R.* Cerebral Hemodynamics. In: Newell DW, Aaslid R. *Transcranial Doppler.* New York: Raven Press Ltd; 1992. p.49-57.
- [10] *Rundek T.* Moždana autoregulacija. In: Demarin i sur. *Moždani krvotok-klinički pristup.* Zagreb: Naprijed; 1994. p.15-25.
- [11] *Daffertshoffer M.* Functional Doppler testing. In: Hennerici MG, Meairs S. *Cerebrovascular ultrasound: theory, practice and future developments.* Cambridge: University Press; 2001. p.341-360.
- [12] *Demarin V.* Transkranijski dopler. In: Demarin V, Štikovac M, Thaller N. *Doppler sonografija krvnih žila.* Zagreb: Školska knjiga; 1990. p.87-130.
- [13] *Alexandrov AV, Demarin V.* Insonation techniques and diagnostic criteria for transcranial Doppler sonography. *Acta clin Croat*1999;38:97-108.
- [14] *Bornstein NM, Gur AY.* Cerebralvasomotor reactivity and carotid occlusive disease. *Acta Clin Croat* 2006;45:357-364.
- [15] *Rundek T, Demarin V, Despot I, DeSyo D, Podobnik-Šarkanji S.* Value of cerebral vasoreactivity testing in patients with carotid artery disease before and after carotid endarterectomy. *Acta clin Croat* 1993; 32:141-150.



- [16] *Silvestrini M, Troisi E, Cupini LM, Matteis M, Pistolesse GR, Bernardi G.* Transcranial Doppler assessment of the functional effects of symptomatic carotid artery stenosis. *Neurology* 1994;44:1910-4.
- [17] *Aaslid R.* Visually evoked dynamic blood flow response of human cerebral cortex. *Stroke* 1987;18:771-5.
- [18] *Lovrenčić-Huzjan A, Vuković V, Bosnar Puretić M, Demarin V.* Sonographic features of vertebral artery occlusion (the role of color and power Doppler flow imaging). *Acta clin Croat* 1999;38:279-285.
- [19] *Lovrenčić-Huzjan A, Bosnar M, Huzjan R, Demarin V.* Frequency of different risk factors for ischemic stroke. *Acta clin Croat* 1999;38:159-163.
- [20] *Warlow CP.* Epidemiology of stroke. *Lancet* 1997; 352:1-4.
- [21] *Crawley F, Clifton A, Brown MM.* Treatable lesions demonstrated on vertebral angiography for posterior circulation ischemic events. *The British Journal of Radiology* 1998;71:1266-70.
- [22] *Lovrenčić-Huzjan A, Demarin V, Bosnar M, Vuković V.* Color Doppler Flow Imaging (CDFI) of the vertebral arteries-the normal appearance, normal values and the proposal for the standards. *Coll. Antropol* 1999; 231:175-181.
- [23] *Demarin V, Škarić Jurić T, Lovrenčić Huzjan A, Bosnar Puretić M, Vuković V.* Vertebral artery hypoplasia, sex-specific frequencies in 36 parent-offspring pairs. *Coll Antropol* 2001;25:501-509.
- [24] *Morović S, Škarić-Jurić T, Demarin V.* Vertebral artery hypoplasia: characteristics in a Croatia population sample. *Acta Clin Croat* 2006;45:325-329.
- [25] *Trkanjec Z, Demarin V.* Transcranial Doppler sonography during visual stimulation. *Acta clin Croat* 1999;38:285-9.
- [26] *Urban PP, Allardt A, Tettenborn B, Hopf H, Pfenningsdorf S, Lieb W.* Photoreactive flow changes in the posterior cerebral artery in control subjects and patients with occipital lobe infarctions. *Stroke* 1995;26:1817-9.
- [27] *Haubrich C, Kohnke A, Diehl RR, Möller-Hartmann W, Klötzsch C.* Impact of vertebral artery disease on dynamic cerebral autoregulation. *Acta Neurologica Scandinavica* 2005;112 (5):309-316.
- [28] *Bornstein NM, Gur AY.* Cerebral vasomotor reactivity and carotid occlusive disease. *Acta Clin Croat* 2006;45:357-364.
- [29] *Markus H, Cullinane M.* Severely impaired cerebrovascular reactivity predicts stroke and TIA risk in patients with carotid artery stenosis and occlusion. *Brain* 2001; 124:457-467.
- [30] *Silvestrini M, Vernieri F, Pasqualetti P, Matteis M, Passarelli F, Troisi I, Caltagirone C.* Impaired cerebral vasoreactivity and risk of stroke in patients with asymptomatic carotid artery stenosis. *JAMA* 2000;26:2122-7.



Utjecaj okluzije vertebralne arterije na odgovore u stražnjoj moždanoj arteriji tijekom vidnih podražaja

Moždani udar je po učestalosti drugi uzrok smrti i vodeći uzrok onesposobljenosti u Hrvatskoj. Četvrtina svih ishemijskih moždanih udara nastaje u području stražnje cirkulacije. Trećina svih ishemijskih moždanih udara uzrokovana je bolešću velikih krvnih žila. Transkranijaska dopler sonografija (TCD) je neinvazivna dijagnostička metoda s izvrsnom vremenskom rezolucijom koja omogućava ispitivanje moždanog krvotoka u živom vremenu. Funkcionalni TCD testovi, između ostalih metoda, imaju značajnu ulogu u procjeni moždanog vazomotornog kapaciteta. Rezultati prethodnih TCD istraživanja ukazali su da proksimalna stenozna u karotidnoj cirkulaciji izrazito utječe na distalnu hemodinamiku i mehanizme autoregulacije.

Cilj ovog istraživanja bio je pomoću TCD-a utvrditi utjecaj okluzije vertebralne arterije na odgovore u stražnjoj moždanoj arteriji tijekom vidnih podražaja.

Odgovore tijekom vidnih podražaja u stražnjoj moždanoj arteriji u bolesnika s okluzijom vertebralne arterije bilježili smo TCD-om mjereći srednje brzine strujanja krvi (SBSK) u stražnjoj moždanoj arteriji prije i tijekom vidnih podražaja.

Mjereći SBSK u stražnjoj moždanoj arteriji bez vidnih podražaja, vrijednosti u kontrolnoj skupini nisu se značajno razlikovale od vrijednosti SBSK u skupini bolesnika s okluzijom vertebralne arterije. Tijekom vidnih podražaja bijelim svjetlom u obje skupine ispitanika zabilježeno je statistički značajno povećanje SBSK u stražnjoj moždanoj arteriji. U kontrolnoj skupini to povećanje SBSK iznosilo je $22,85 \pm 20,9\%$ u desnoj, a $20,67 \pm 15,31\%$ u lijevoj stražnjoj moždanoj arteriji. U skupini bolesnika s okluzijom vertebralne arterije povećanje u desnoj stražnjoj moždanoj arteriji iznosilo je $12,3 \pm 16,46\%$, a u lijevoj $11,89 \pm 13,08\%$. U bolesnika s okluzijom vertebralne arterije opetovani vidni podražaji doveli su do smanjenja odgovora u stražnjoj moždanoj arteriji što je mogući pokazatelj iscrpljivanja moždane vazomotorne rezerve.

Na temelju našeg istraživanja možemo zaključiti da postoji negativni utjecaj okluzije vertebralne arterije na distalnu hemodinamiku. Funkcionalni TCD testovi vidnim podražajima predstavljaju neinvazivnu i preciznu metodu za procjenu vazoreaktivnosti u stražnjoj moždanoj cirkulaciji.

Ključne riječi: vertebralne arterije, vidni evocirani odgovori, ultrazvuk, stražnja moždana arterija

