



UDK 616.13  
Original scientific paper  
Received: 17 January 2007  
Accepted: 25 April 2007

# MORPHOLOGIC AND HEMODYNAMIC CHARACTERISTICS OF VERTEBRAL ARTERIES IN MEN AND WOMEN

Sandra Morović, Tatjana Škarić-Jurić<sup>1</sup>, Vida Demarin

University Department of Neurology, Sestre Milosrdnice University Hospital,  
Zagreb, Croatia

<sup>1</sup>Institute of Anthropology, Zagreb, Croatia

## Summary

*Introduction:* Men and women differ in diameters and MBFVs in VAs.

*Aim:* to compare morphology and hemodynamics of VAs between sexes.

*Patients and methods:* We examined 155 subjects using a linear 7.5 MHz probe (Aloka Prosound SSD-5500). Measurements were obtained at the V2 segment of VAs. Criteria: VA diameter of 2-4mm, systolic MBFVs of 0.35-0.70m/s, normal resistance pattern. Investigated parameters: diameters of VAs, MBFVs in VAs, sum of VA diameters, sum of MBFVs in VAs, diameter of the narrower and wider VA, and age.

*Results:* 68 men and 87 women; 88 with a dominant left VA (56% of men and 58% of woman), 11 (7%) showed no dominance. Group differences: men had both VAs wider, and a larger diameter of the "wider" VA. There were no differences in MBFVs between men and women.

*Conclusion:* Left VA is dominant in both sexes. There was no difference in MBFVs among sexes. Men have a wider VA than women.

**Key words:** Vertebral artery, Croatian population

## INTRODUCTION

The anatomical position of vertebral arteries caused them to be neglected in research until ultrasound methods became widely available [1,2]. The ultrasound allows a non-

---

Correspondence to: Sandra Morović, University Department of Neurology, Sestre milosrdnice University Hospital, Reference Center for Neurovascular Disorders of the Ministry of Health and Social Welfare of the Republic of Croatia  
Vinogradska 29, Zagreb, Croatia  
E-mail: sandra.morovic@hotmail.com

invasive view into the human body, and by performing color Doppler flow imaging (CDFI) of the blood vessels of the head and neck<sup>3</sup> we can painlessly, at bedside, assess cerebral circulation [4,5].

Vertebral arteries are responsible for one third of the brain's blood supply. They form the rear part of the Willis' circle and are responsible for the blood supply of the cerebellum, pons, middle ear, as well as the upper parts of the spinal cord and its meninges.

Changes in the morphology and hemodynamics of vertebral arteries can be the cause of many disorders. For example, 15% of all strokes occur in the irrigational territory of vertebral arteries, and stroke is still the leading cause of death and disability in Croatia. Vertigo, on the other hand, is not always a sign of a serious illness, but is a symptom which has a great effect on the quality of patients' lives. Changes on vertebral arteries, both atherosclerotic and congenital, can also serve as unfavorable prognostic factors in chronic degenerative changes on the cervical spine and trauma [9], or atherosclerotic [10] changes on other vessels.

All this makes the investigation of vertebral arteries worthwhile.

Studies have shown that men and women differ in the diameters and mean blood flow velocities (MBFVs) in vertebral arteries (VAs) [6-8].

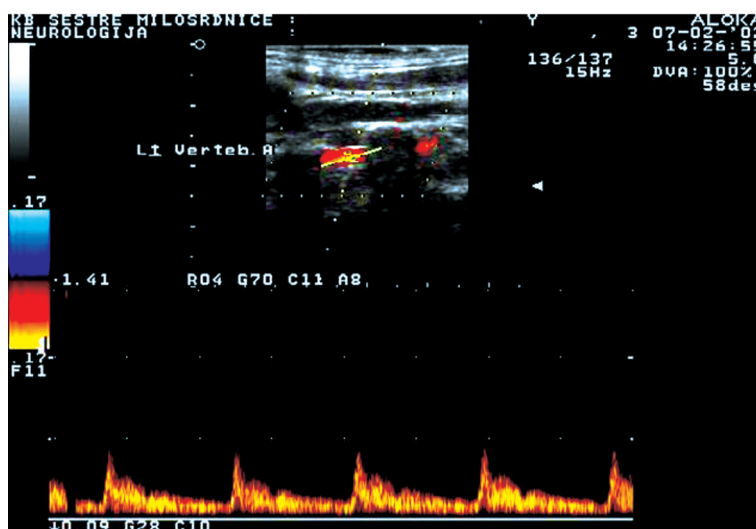
The aim of this study is to compare the morphology and hemodynamics of VAs between men and women in the Croatian population.

### Patients and methods

We examined 155 subjects at The University Department of Neurology, University Hospital Sestre Milosrdnice, Zagreb, Croatia. There were 68 men and 87 women. The subjects participating in the study were chosen among the hospitalized and out-patient subjects on whom CDFI of vertebral arteries was performed during the investigation of vertebral arteries as a part of the screening method for possible cerebrovascular disorders. All examined subjects had no apparent pathology of vertebral arteries such as an occlusion, hypoplasia, and aplasia of vertebral arteries or severe hemodynamic changes. The subjects with abnormalities of vertebral arteries were excluded from the study (abnormalities such as a vertebral artery stenosis, occlusion of vertebral artery, extracranial flow, etc.). All the subjects in the study had normal vertebral arteries.

All measurements were done using the extracranial color Doppler technique, with a 7,5 MHz probe, on an Aloka Prosound 5500. Vertebral arteries were measured at the V2 segment, between the vertebrae C6 and C5. The criteria used for normal vertebral arteries were: lumen diameter of 2,5-4,5 mm, mean blood flow velocities of 0,35-0,70 m/s, and absence of increased resistance pattern (diastolic velocities above 0,05 m/s). All measurements were done with the patient lying on his/her back, head in mid-position, lifted to 45 degrees, chin facing upwards. By moving the probe horizontally, keeping in contact with the skin, a vertebral artery appears [8,13,14]. (Figure)

The two groups were compared in several categories: sex, age, diameter of the right, left, and both vertebral arteries, narrower vertebral artery (being the one with a smaller



Normal vertebral artery as seen by CDFI.

diameter in both groups), hemodynamics in the right and left vertebral artery, and resistance patterns.

Data were analyzed descriptively, and the differences among groups were analyzed using the student t-test and  $\chi$ -square.

## Results

Color Doppler flow imaging reports of vertebral arteries performed on 155 healthy subjects were analyzed. There were 68 men (44%) and 87 (56%) women. Among men and women the right vertebral artery was noticed to be narrower than the left vertebral artery in most cases (Table 1). The term "narrower" relates to a smaller vertebral artery lumen when both sides are compared. Fifty-seven percent of subjects had a narrower right vertebral artery as opposed to 36% of subjects with a narrower left vertebral artery. Vertebral arteries of equal width were found in 10% of subjects. A similar percentage of men and women were found to have narrower right vertebral arteries - 56% of men and 58% of women. Results were similar for the other side also, 36% of men and 37% of women had a narrower left vertebral artery. Eight percent of men and 5% of women had an equal width of vertebral arteries. (Table 1)

**Table 1.** Side of the “narrower” vertebral artery

	Right	Left	Right = left	Total
Men	37 (56%)	24 (36%)	7 (8%)	68
Women	51 (58%)	32 (37%)	4 (5%)	87
Men and women	88 (57%)	56 (36%)	11 (6%)	155

**Table 2.** Comparison of mean values of tested parameters among examined subjects.

Tested parameter	Men	Women
Age	36,19	47,35***
AV-R	3,26	3,11
AV-L	3,43	3,26
AV-R hemo	0,46	0,46
AV-L hemo	0,47	0,48
AV-R+AV-L	6,69	6,37**
AV-R+L hemo	0,93	0,94
Narrower	3,02	2,88
Wider VA	3,67	3,49**

\*p=0.005

\*\* p=0.01

\*\*\* p=0.001

Age = mean age of patients

AV-R = diameter of the right vertebral artery

AV-L = diameter of the left vertebral artery

AV-R hemo = hemodynamics of the right vertebral artery

AV-L hemo = hemodynamics of the left vertebral artery

AV-R+AV-L = diameter of both vertebral arteries

AV-R+L hemo = hemodynamics of both vertebral arteries

Narrower = diameter of the narrower vertebral artery

Wider VA = diameter of the “wider” vertebral artery

Men and women differed greatly in some examined parameters. Women were in average eleven years older than men. Men had the right and left vertebral artery wider than women even though the differences were not statistically significant. But, when we compared both diameters together, the difference between men and women was statistically significant. Men had both vertebral arteries wider than women. There were no great differences in mean blood flow velocities in the left and right vertebral artery between men and women. Also, when compared, the sum of mean blood flow velocities in both vertebral arteries showed no difference between men and women. The difference in the diameters of the “narrower” vertebral artery was not significant between



these two groups. But, men showed a statistically significant wider diameter of the “wider” vertebral artery. (Table 2)

## Discussion

Because of their anatomic location and inconvenient access for surgical procedures vertebral arteries stayed neglected in research for a long time<sup>16-19</sup>, even though they are the second largest blood supplier of the brain. They are responsible for 30% of the brain’s blood supply and form the rear part of the Willis’ circle. Circulatory changes in vertebral arteries can cause serious conditions such as stroke, or uncomfortable symptoms such as vertigo. A greater interest in vertebral arteries followed the introduction of noninvasive ultrasound methods to the study of blood vessels [20,21].

The results obtained by this investigation confirmed some earlier findings on this subject. Back in 1999 Seidel [22] showed that mean blood flow velocities are lower in right vertebral arteries and that lumen diameters of right vertebral arteries are smaller than those of the left side. Our results showed different findings in regard to mean blood flow velocities which didn’t differ greatly between the right and left vertebral artery, but confirmed dominance of the left vertebral artery. Our investigation confirmed some results of earlier studies done by Karayenbuehel and Yasargila in 1957. They found that vertebral arteries had different diameters in 74% of the population, and 42% of the population had a dominant left vertebral artery. Our study showed different diameters of the right and left vertebral artery in 92% of men and 95% of women. Touboul et al. [14] found a dominant left vertebral artery in 48% of subjects, with 14% having a dominant right vertebral artery. In 1999 Lovrenčić-Huzjan et al. [8] found 64% of dominant left vertebral arteries in the Croatian population. This investigation on a larger number of subjects showed 57% of dominant left vertebral arteries. Also, women were in average eleven years older than men, which was found to be statistically significant. We have found no apparent reason for this difference until now. Possibly, this could partly be explained by a longer life expectancy of women in our population. Or there could be another undetermined reason since this study compared groups only by the characteristics of vertebral arteries. Other risk factors were not investigated or compared in this study.

## Conclusion

This investigation showed dominance of the left VA in diameter (57%) in both men and women, as was presented by some authors in earlier investigations. But, as opposed to earlier findings, this investigation showed no difference in MBFVs of both men and women. This investigation also showed that men have a larger sum of both VA diameters

and a larger diameter of the wider VA which leads to a conclusion that men have wider VA than women.

## References

- [1] *Bartels E.* Duplex ultrasound of the vertebral arteries. 1. Practical implementation, possibilities and limitations of the method. *Ultraschall Med* 1991;12(2):54-62.
- [2] *Bartels E.* Duplex ultrasonography of the vertebral arteries. 2. Clinical applications. *Ultraschall Med* 1991;12(2):63-69.
- [3] *De Bray JM, Dauzat M, Teisseire-Girod F, Davinroy M, Emile J.* The Doppler effect applied to the study of vertebral arteries. *Nouv Presse Med* 1978;7(1):39-42.
- [4] *Bluth EI, Merritt CR.* Doppler color imaging. Carotid and vertebral arteries. *Clin Diagn Ultrasound* 1992;27:61-96.
- [5] *Landwehr P, Schulte O, Voshage G.* Ultrasound examination of carotid and vertebral arteries. *Eur Radiol* 2001;11(9):1521-34.
- [6] *Bartels E, Fluegel KA.* Advantages of color Doppler imaging for the evaluation of vertebral arteries. *J. Neuroimaging* 1993; 3(4):229-33.
- [7] *Bartels E, Fuchs HH, Flugel KA.* Duplex sonography of vertebral arteries: examination, the normal values, and clinical applications. *Angiology* 1992;43(3):169-80.
- [8] *Lovrenčić-Huzjan A, Demarin V, Bosnar M, Vuković V, Podobnik-Šarkanji S.* Color Doppler Flow Imaging (CDFI) of the Vertebral Arteries - The Normal Appearance, Normal Values and the Proposal for the Standards. *Coll Antropol* 1999;23:175-81.
- [9] *Mann T, Refsauge KM.* Causes of complications from cervical spine manipulation. *Aust J Pjysiother* 2001;47(4): 255-66.
- [10] *Ackerstaff RG, Grosveld WJ, Eikelboom BC, Ludwig JW.* Ultrasonic duplex sonography of the prevertebral segment of the artery in patients with cerebral atherosclerosis. *Eur J Vasc Surg* 1988;2(6):387-93.
- [11] *Lovrenčić-Huzjan A, Demarin V, Rundek T, Vuković V.* Role of vertebral artery hypoplasia in migraine. *Cephalalgia* 1998;18:684-6.
- [12] *Oder B, Oder W, Lang W, Marschnigg E, Deecke L.* Hypoplasia, stenosis and other alterations of the vertebral artery impaired blood rheology manifest a hidden disease? *Acta Neurol Scand* 1998;97(6):398-403.
- [13] *Kremkau FW.* Diagnostic Ultrasound: Principles and Instruments. 6<sup>th</sup> edn. W. B. Saunders Company, New York 2002.
- [14] *Touboul PJ, Bousser MG, LaPlane D, Castaigne P.* Duplex scanning of normal vertebral arteries. *Stroke* 1986;17:921-3.
- [15] *Demarin V, Škarić-Jurić T, Lovrenčić-Huzjan A, Bosnar-Puretić M, Vuković V.* Vertebral Artery Hypoplasia – Sex-Specific Frequencies in 36 Parent-Offspring Pairs. *Coll Antropol* 2001;25:501-9.

- [16] *Bluth EI, Merritt CR, Sullivan MA, Bernhardt S, Darnell B.* Usefulness of duplex ultrasound in evaluating vertebral arteries. *J Ultrasound Med* 1089;8(5):229-35.
- [17] *Delcker A, Diener HC.* The value of color duplex for sonography of the vertebral artery. *Vasa Suppl* 1991;33:204-5.
- [18] *Delcker A, Diener HC.* Color-coded duplex sonography in evaluation of vertebral arteries *Bildgebun* 1992;59(1):16-21.
- [19] *Delcker A, Diener HC.* Various ultrasound methods for studying the vertebral arteries- a comparative evaluation. *Ultraschall Med* 1992;13(5):213-20.
- [20] *Bendick PJ, Glover JL.* Hemodynamic evaluation of vertebral arteries by duplex ultrasound. *Surg Clin North Am* 1990;70(1):235-44.
- [21] *Bendick PJ, Jackson VP.* Evaluation of the vertebral arteries with duplex sonography. *J Vasc Surg* 1986;3(3):523-30.
- [22] *Seidel E, Eicke BM, Tettenborn B, Krummenauer F.* Reference Values for Vertebral Artery Flow Volume by Duplex Sonography in Young and Elderly Adults. *Stroke* 1999;30:2692-6.

#### Sažetak

### Morfološke i hemodinamske karakteristike vertebralnih arterija kod muškaraca i žena

*Uvod:* Muškarci i žene se razlikuju u promjerima i srednjim brzinama strujanja krvi (SBSK) u vertebralnim arterijama (VA).

*Cilj:* usporediti morfologiju i hemodinamiku VA među spolovima.

*Ispitanici i metode:* Pregledali smo 155 osoba upotrebom linearne sonde 7,5 mHz (Aloka Prosound SSD-5500). Mjerenja su vršena u V2 segmentu VA. Kriteriji: VA dijametar 2-4mm, sistoličke SBSK 0,35-0,70m/s, normalan otpor. Mjereni parametri: promjeri VA, SBSK u VA, ukupni promjeri VA, ukupne SBSK u VAs, promjeri "uže" i šire VA, i dob.

*Rezultati:* 68 muškaraca i 87 žena; 88 dominantnih lijevih VA (56% muškaraca i 58% žena), 11 (7%) bez dominacije. Razlike među grupama: muškarci imaju šire obje VA i promjer "šire" VA. Nije bilo razlika u sbsk među spolovima.

*Zaključak:* Lijeva VA je dominantna u oba spola, nema razlika u SBSK među spolovima. Muškarci imaju šire VA od žena.

**Ključne riječi:** Vertebralna arterija, Hrvatska populacija