

Subcircular perforations of the hard palate of the individual from Lchashen site (Armenia)

• Anahit Yu. Khudaverdyan and Levon Petrosyan •

Institute of Archaeology and Ethnography, National Academy of Science, Republic of Armenia
Yerevan, 0025, Charents st.15, Armenia

Address for correspondence:

Anahit Yu. Khudaverdyan
Institute of Archaeology and Ethnography
National Academy of Science, Republic of Armenia
Yerevan, 0025, Charents st.15, Armenia
E- mail: ankhudaverdyan@gmail.com

Bull Int Assoc Paleodont. 2017;11(1):23-31.

Abstract

This paper identifies the presence of palate cleft in the individual from Middle Bronze Age and Late Bronze Age in the Armenia. The remains of skeleton from Lchashen site (burial 221/2), comprise the skull and post-cranial skeleton of a female 30-39 years. Macroscopic physical examination revealed that individual suffered from inflammation. The study reveals that inflammation possibly caused by because of sinusitis or inhaling polluted air for a long duration. In addition, we have seen skeletal evidence for pulmonary disease: tuberculosis. The female from Lchashen led a physically strenuous lifestyle.

Keywords: Armenia; palate cleft; sinusitis; paleopathology

Introduction

Cleft defects of the primary and secondary palate are the most frequent birth malformation of the head and neck (1). There are two forms of cleft palate. The commonest, known as midline cleft palate, affects the back of the mouth, either unilaterally or bilaterally. Modern incidence of cleft palate is 1:400 (a world average, with variations between countries), with males affected twice as often as females (2). Barnes (3), however, states that females are affected more commonly than males. The second form may occur in association with cleft lip, in which case only the front of the mouth (the pre-maxilla) is affected.

A developmental delay in the formation of the roof of the mouth leads to the non-union of the palate. This type of defect is a "dorsal notch", affecting the posterior margin of the palate (3). Dorsal notches are the result of short delays in development, and clinically are often only discovered when individuals suffer from recurring middle ear infections, chest infections and hearing loss (3, 4, 5). Severe defects like this can also extend back along the maxilla into the mouth, leaving the mouth and the nose as one cavity instead of two. This can be surgically corrected today, but in the past it may have been incompatible with survival in some babies, as eating, drinking and breathing would be difficult for the infant (2, 4, 5, 6).

Acquired palatal perforations are produced and by other conditions. The unusual causes are exemplified by the gumma of tertiary syphilis. Tertiary syphilis is a non-infective multi-organ stage characterised by a painless localised granuloma (gumma) (7) which classically presents on the midline of the palate (8). Chronic necrosis destroys the palatal bone to leave a clean perforation (9). Oral tuberculosis is rare and accounts for less than 1% of all cases of tuberculosis (10). Oral tuberculosis may either be primary, or more often, secondary to pulmonary tuberculosis. In secondary oral tuberculosis, the bacilli reach the oral mucosa by hematogenous or lymphatic spread. In primary oral tuberculosis there is direct inoculation of the mycobacterium due to break or loss of the natural barrier resulting from trauma, inflammatory conditions, leukoplakia, tooth extraction, or poor oral hygiene (10). The palatal lesion of tuberculosis may be seen as granulomas, ulceration, or perforation and are usually more common in the hard palate than in the soft palate (11). The incidence of defects caused by cocaine abuse

is dependent upon its route of administration. Snorting most commonly results in an isolated septal perforation (12, 13) but can also lead to perforation of the hard palate (14). Maxillary sinusitis is an infection of the sinus areas in the maxillae. Sinusitis is often associated with, or caused by, upper respiratory infections, allergic rhinitis, asthma, immunodeficiency disorders, and/or cystic fibrosis (15). Cleft lip and palate perturbs osseous and soft-tissue development of the nasolabial regions, often resulting in chronic maxillary sinusitis and mucosal thickening of the maxillary sinus (16).

Very few articles concerning defective plate crania are in the literature of paleopathology and mostly dated to later than the middle of the first millennium AD (17, 18, 19, 20, 21, 22, 23, 24, 25, 26, 27). Very few cleft skulls have been found in earlier archaeological specimens (28, 29, 30, 31, 32). Anderson (21) described the surgical repair of a cleft palate (although this must surely have been a cleft lip) during the English Anglo-Saxon period and a repair carried out in China c.390 BC has also been described (21, 29). Palate clefts were not seen in ancient skeletons from Armenia. Although it might be hypothesized that palate defects did not exist in the Armenia during earlier eras, from a biological standpoint, this supposition is unrealistic. The only instance of a palatal defect which was found is seen in Figure 1.

Materials and methods

Lake Sevan is the only large expanse of water in landlocked Armenia. When the level was reduced, a very extensive barrow cemetery was revealed at Lchashen. Mnacakanyan was excavated from 1957-1967, but the excavations continued on archaeologist Petrosyan. The Lchashen site is a mass (500) burial site, which includes at least 300 adult individuals of both sexes and all ages, accompanied with many stone and bone tools, as well as ornamental objects. The burials were made in burial chambers, the walls of which were made of slabs weighing 2 to 5 tons. The ceilings were covered by logs supported by solid wooden columns, and the vaulted roof of huge slabs was placed thereon. One of the burials 221 (excavated in 2004, Figure 2) of the Middle Bronze Age and Late Bronze Age (17th to 16th centuries BC), was over 11.10 m in diameter and 1.20 metres high, and proved to cover a very rich chariot burial. There were in fact two burial chambers,

one at the centre, and a second added on at the side like a sort of pimple. At the centre was the burial chamber with a two individuals, a 30-to-39-year-old female and a one-to-four-year-old child, presumably mother and child (the skull was absent).

The age-at-death and sex of individual were assessed through the use of multiple indicators: morphological features of the pelvis and cranium were used for the determination of sex (33, 34); a combination of pubic symphysis (35, 36, 37), auricular surface changes (38), degree of epiphyseal union (38), and cranial suture closure (37) were used for adult age estimation. For subadult, long bone length, and the appearance of ossification centres and epiphyseal fusion were used (34, 39). Measurements were taken as outlined in Alexseev (40, 41). The bone is measured on an osteometric board, and stature is then calculated using a regression formula developed upon individuals of known stature (42). Non-metric traits have been recorded for these skulls (43) and dentition (44) in order to allow future comparisons with findings from other sites of Armenia.

Gross observations of abnormal changes appearing in ancient skeletons principally provide the basic information for paleopathological diagnosis. In the present study, bearing in mind the various diseases, pathological changes were completely described and given tentative diagnosis.

Results

The remains of a Middle Bronze Age and Late Bronze Age skeleton, burial 221/2, from Lchashen site, comprise the skull and post-cranial skeleton of a female 30-39 years. At 1.655m she was average height for an Lchashen female of the time. The following measurements (mm) were recorded from the skull: cranial breadth, 137.5; occipital breadth, 102; parietal chord, 98; occipital chord, 95; alveolar arch length, 59; alveolar arch breadth, 65; palatal length, 52; palatal breadth, 32; nasal breadth, 25. The following traits were presence: foramina infraorbitalia, os wormii suturae squamosum, os parietale bipartitum (incomplete) (Figure 3), os wormii suturae coronalis, foramina parietalia, os apicis lambda (Figure 3), os asterion, foramina mentalia, sulcus mylohyoideus (Figure 4), sutura mendoza. Teeth of the individual of the Lchashen are characterised by hypocone UM2

(Figure 1), four-cusped LM2. Two measurements, faciolingual (maxilla: M2 10mm, M3 10.5mm; mandible: M1 10.2 mm, M2 10mm, M3 9.5mm) diameter and mesiodistal (maxilla: M1 9mm, M2 9mm, M3 8.5mm; mandible: M1 9mm, M2 10mm, M3 10mm) diameter were taken for each M as described by Zubov (44).

A severe case of chronic sinusitis was noted in the female. Maxillary sinusitis is an infection of the sinus areas in the maxillae. Bacteria, viruses, and fungi have all been noted as causing sinusitis, with bacteria the leading cause. In the clinical literature, sinusitis is often associated with, or caused by, upper respiratory infections, allergic rhinitis, asthma, immunodeficiency disorders, and/or cystic fibrosis (15), with upper respiratory infection being the most frequent cause. The inferior wall of the left maxillary sinus is completely resorbed. The root apices of RM1 are completely exposed by the eroded bone (Figure 1), the alveolus has been completely eroded by a massive lytic lesion. The remaining of the molars from the maxillary left and right side were recovered; their presence indicates that the teeth and gums were still in place at the time of death. The internal sinus walls exhibit prominent reactive bone. Two holes (10×7.8 mm /left/ and 5×4 mm /right/) is present on the medial wall of the maxillary sinus, communicating through the inferior meatus into the nasal aperture. The anterior surface of the right maxilla displays reactive periosteal bone, indicating that the exterior portion of the bone was affected by periostitis, most likely a result of the sinusitis. The infection of the maxilla was so extreme that hematogenous dissemination of the infectious agents could have occurred, possibly leading to the death of the individual (45). In addition to a chronic sinusitis, had also possibly tuberculosis. It was on the internal (posterior) surface of the manubrium, which had a latticework appearance (Figure 6). Given that tuberculosis is characterized by lytic lesions and is known to affect the sternum to some degree, the presence of pronounced lattice-like porosity on the posterior surface of the manubrium could have potential associations with tuberculosis.

We found a correlation between the maxillary sinusitis with periodontal disease and tooth lost antemortem. Tooth wear may have resulted from a variety of processes, including attrition, abrasion, and erosion. Calculus is fixed in a female.

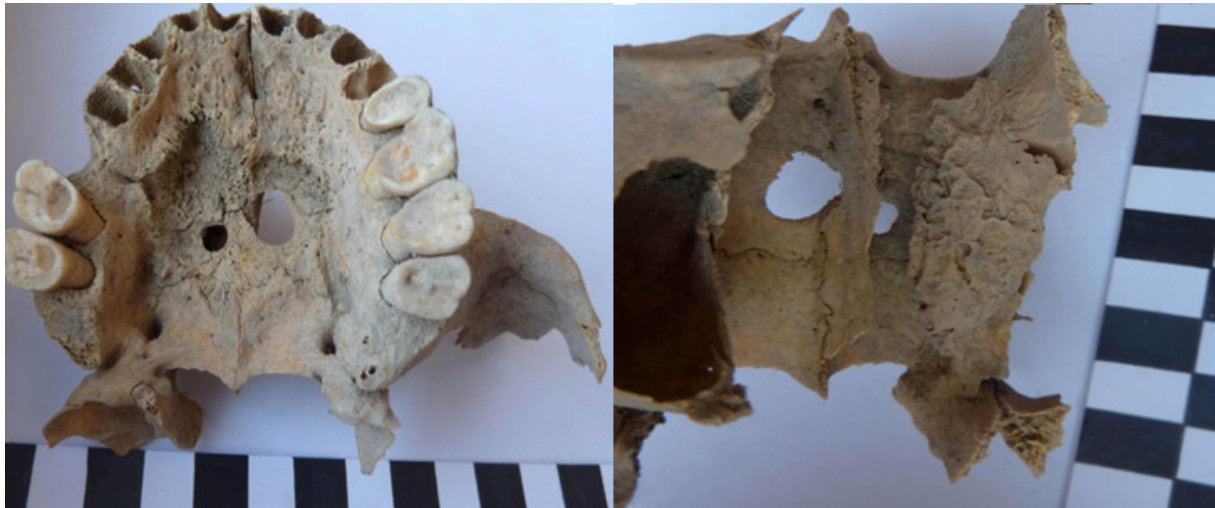

Figure 1. Perforation of the hard palate, with two small defects in the hard palate.



Figure 2. Burial 221 from Lchashen.

Calculus may harbour pathogenic bacteria which may lead to periodontal disease. Some authors defend that calculus deposition may be mainly related to consumption of protein-rich food, as fish or meat (46), whereas others have found that diets rich in carbohydrates may promote calculus deposition (47). It can be explained more logically by a specific occupational activity of the Sevan Basin inhabitants, which in turn points towards fishing activity.

The left parietal exhibits two separate depression fractures, on the right - one fracture. These injuries were most likely caused by multiple blows with a blunt instrument. These lesions is roughly circular

and semi-circular in shape. Periostitis was located on the humerus, radius and tibia of female 221/2 and child 221/1 skeletons. A non-specific bacterial infection such as periostitis is probably caused by injury.

A deep radial fossa on the distal end of the humerus (Figure 7) could result from the habit of carrying loads in a bag slung over the shoulder and held in place with the hand. The arm is tightly flexed at the elbow so that the head of the radius impacts above the distal epiphysis of the humerus (48). The deltoid muscle (Figure 8) was used in flexing and adducting the arm (at the shoulder) and pulling it across the chest (medial rotation) (49). Both arms are affected. The constant pressure of

the edge of the glenoid of the scapula on the humerus shaft has led to a depression and loss of bone in the area below the humeral neck of both arms. The traits that characterize habitual horse-riders were observed in femora (Figure 9). These include hypertrophied ligament attachment areas around the fovea of the femur, as well as a pronounced linear aspera which supports attachment of the muscles that a rider uses to grip the back of the horse (50).

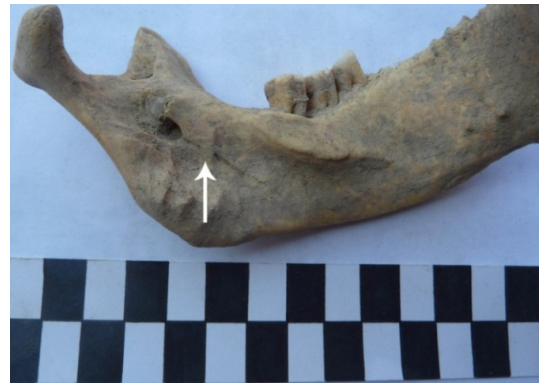

Figure 4. Non-metric trait/normal variation in the skeleton (sulcus mylohyoideus)




Figure 3. Non-metric trait/normal variation in the skeleton (os apicis lambda, os parietale bipartitum /incomplete/)

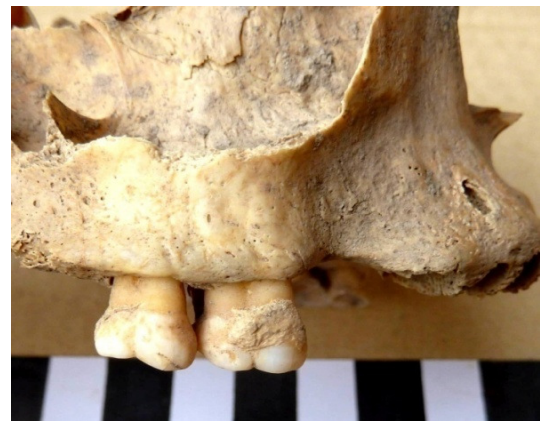

Figure 5. Periodontal disease, tooth lost antemortem and dental calculus

Discussion

We have looked at a number of pathological conditions in a skeleton 221/2 from Lchashen site. Our study of the paleopathology in this individual has shed some light on not only the health and disease aspects of this female. The transition from a hunting-gathering way of life to agriculture caused permanent settlements to arise, decreasing population mobility and increasing population density. This change resulted in exposure to many infections and diseases (51). Increased intake of carbohydrates in the diet has an adverse impact on overall health and in particular, dental health. Merrett and Pfeiffer (52) found a relationship between dental pathology and sinusitis in 28% of their cases. There is a strong possibility for oral bacteria to be transmitted from the mouth through the middle

meatus to the maxillary sinus (53) suggesting a closer association between dental pathology and sinusitis than is directly observable. This is only one of the probable reasons. Further, the presence of chronic infections in combination with a compromised immune system leads to poor resistance and a disease-related stress may lead to overall poor health to individual. In combination with the health hazards mentioned, repetitive pregnancies further stressed both maternal and child health. Infections like maxillary sinusitis can be viewed as major indicators of the adverse effect of cultural practices on health of the individual.



Figure 6. Tuberculosis of sternum.

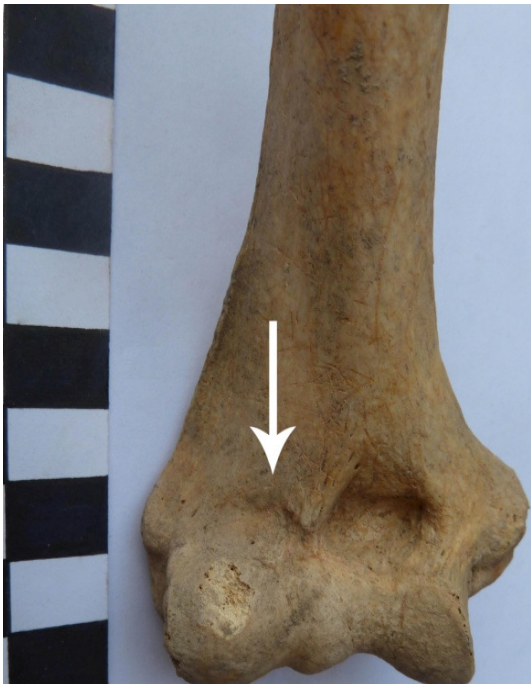

Figure 7. Radial fossa on the distal end of the humerus.

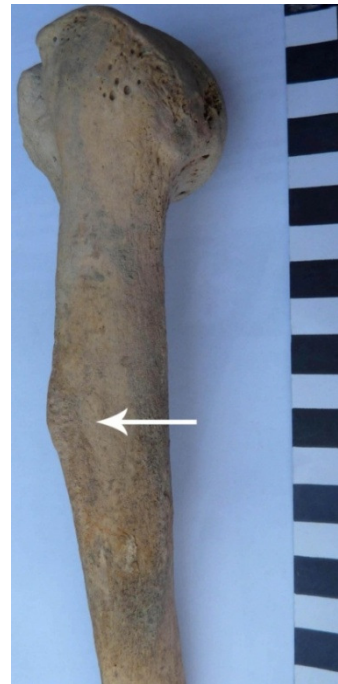

Figure 8. Deltoid muscle attachments on a humerus; robusticity score 3.



Figure 9. Left femur of skeleton, enthesopathies for gluteus maximus.

Reddy (54) discusses etiologies for the occurrence of maxillary sinusitis in archaeological populations such as air pollution from different fuels, the aridity or humidity within environment, the diet of the people and dental pathology. Cooking and heating with solid fuels both lead to high levels of indoor air pollution, mainly a complex mix of health-damaging pollutants (e.g. particulate matter and carbon monoxide) (55). Many studies examine the effect of exposure to smoke by humans, with a particular focus on mothers and children. At the same time infants are exposed to pollutants as they are close to their mothers when they are engaged in domestic chores. Even after the cooking is finished, smoke lingers in the house for a long time as there are no windows. Not only is the environment inside the house polluted but also, the outside environment is contaminated with dust and other particles which create irritation in the upper respiratory tract. In the ancient societies, with the advancement in technology and agricultural production, many different occupational activities developed. It is evident

that people were engaged in metal smelting, pottery making, brick making, leather making, quarrying etc. where there was a constant exposure to the polluted air and unwanted particles (56). Even different agricultural activities such as burning of weeds for preparing land for agriculture, cutting the dry crops and removing the husks from the grains creates a high potential for sinusitis. In addition, we have seen skeletal evidence for pulmonary disease: tuberculosis.

The female from Lchashen led a physically strenuous lifestyle. Before us is the individual with signs of intensive exercise stresses. The signs of development of a relief is possible bound to regular riding are expressed. The potential information which can be obtained from this research is enormous, adding to our knowledge and understanding of past life ways and Armenia's rich and diverse prehistory.

References

1. Hagberg C, Larson O, Milerad J. Incidence of cleft lip and palate and risks of additional malformations. *The Cleft Palate-Craniofacial Journal* 1998; 35(1): 40-45.
2. Levene MI, Tudehope D. *Essentials of Neonatal Medicine*. Oxford: Blackwell Scientific Publications, 1993.
3. Barnes E. *Developmental defects of the axial skeleton in palaeopathology*. Colorado, 1994.

4. Avery ME, Tausch JIW. Schaffer's Diseases of the Newborn. WB Saunders: Philadelphia, 1984.
5. Levene MI. Jolly's Diseases of Children. Blackwell Scientific Publications: Oxford, 1991.
6. Romero M, Saez JM. Scope of western surgical techniques to correct cleft lip and palate prior to the 18th century. *Cleft Palate Craniofacial Journal* 2014; 51: 497–500.
7. Alam F, Argiriadou A, Hodgson TA, Kumar N, Porter SR. Primary syphilis remains a cause of oral ulceration. *Br Dent J.* 2000; 189:352–354.
8. Kearns G, Pogrel MA, Honda G. Intraoral tertiary syphilis (gumma) in a human immunodeficiency virus- positive man: a case report. *J Oral Maxillofac Surg.* 1993; 51: 85–88.
9. Scully C, Cawson RA. Medical problems in dentistry. 4th ed. Oxford: Wigh, 1998.
10. Dixit R, Sharma S, Nuwal P. Tuberculosis of oral cavity. *Indian J Tuberc.* 2008; 55: 51–53.
11. Suhail Z, Khambaty Y, Ashrafi SK, Musani A. An unusual site of presentation of tuberculosis: Tuberculosis hard palate. *Pak J Surg.* 2010; 26:180–181.
12. Lancaster J, Belloso A, Wilson CA, McCormick M. Rare case of naso-oral fistula with extensive osteochondrogenous necrosis secondary to cocaine abuse: Review of otorhinolaryngological presentations in cocaine addicts. *J Laryngol Otol.* 2000; 114: 630–633.
13. Trimarchi M, Nicolai P, Lombardi D, Facchetti F, Morassi ML, Maroldi R, Gregorini G, Specks U. Sinonasal osteochondrogenous necrosis in cocaine abusers: experience in 25 patients. *Am J Rhinol.* 2003; 17: 33–43.
14. Smith JC, Kacker A, Anand VK. Midline nasal and hard palate destruction in cocaine abusers and cocaine's role in rhinologic practice. *Ear Nose Throat J.* 2002; 81: 172–177.
15. Friday GA, Fireman P, Sukanich A, Steinberg ML. Sinusitis. In: *Childhood Rhinitis and Sinusitis: Pathophysiology and Treatment*: CK. Naspitz, DG. Tinkel-Man (Eds). New York: Marcel Dekker, p. 193-215, 1990.
16. Erdur O, Ucar FI, Sekerci AE, Celikoglu M, Buyuk SK. Maxillary sinus volumes of patients with unilateral cleft lip and palate. *Int J Pediatr Otorhi.* 2015; 79 (10): 1741-1744.
17. Munizaga JR. Labio leporino en una población precolombina de Chile. *Antropología Física Chilena* 1961; 2: 49–51.
18. Berndorfer A. A 500-year-old skull with cleft lip. *British Journal of Plastic Surgery* 1962; 15: 123–128.
19. Gilkey F. Cleft lip and palate in paleopathological material. *Paleopathology Newsletter* 1978; 24: 8–11.
20. Brothwell DR. Digging up bones. New York: Cornell University Press, 1981.
21. Anderson T. Medieval example of cleft lip and palate from St. Gregory's Priory, Canterbury. *Cleft Palate-Craniofacial Journal* 1994; 31:466–472.
22. Hegyi A, Marcsik A, Kocsis GS. Developmental disorders of nasal bones in human osteoarcheological samples. *Journal of Paleopathology.* 2002; 14: 113–119.
23. Hegyi A, Marcsik A, Kocsis SG. Frequency of developmental defects on the skull and the axial skeleton on skeletal collections (Hungary). *Journal of Paleopathology.* 2004; 16: 15–25.
24. Phillips SM, Sivilich M. Cleft palate: a case study of disability and survival in prehistoric North America. *Int J Osteoarchaeol.* 2006; 16: 528–535.
25. Weiss E. When it rains it pours: multiple congenital pathologies in single individuals. In: *Archaeology research trends: AR. Suárez, MN. Vázquez (Eds). New York: Nova Science Publishers, p. 65–77, 2008.*
26. Altamirano Enciso AJ, García-Zapata MTA. Un caso de fisura labiopalatina o "boca-de-lobo" en Makatampu, valle del Rimac, Perú, siglos XV-XVI. *Revista do Museu de Arqueologia e Etnologia, São Paulo* 2010; 20: 361–380.
27. Lewis ME. Children of the Golden Minster: St. Oswald's priory and the impact of industrialisation on child health. Hindawi Publishing Corporation *J Anthropol.* 2013. <http://dx.doi.org/10.1155/2013/959472>
28. Brooks ST, Hohenthal WD. Archaeological defective palate crania from California. *Am J Phys Anthropol.* 1963; 21: 25–32.
29. Fiori MG. Facial clefting in antiquity. *Paleopathology Newsletter* 1983; 44: 5.
30. Gladkowska-Rzeczycka J. Congenital anomalies of early Polish man. In: *Advances in paleopathology: L. Capasso (Ed). Marino Solfanelli: Chieti, p. 111-116, 1989.*
31. Hawass Z, Gad YZ, Ismail S, Khairat R, Fathalla D, Hasan N, Ahmed A, Elleithy H, Ball M, Gaballah F, Wasef S, Fateen M, Amer H, Gostner P, Selim A, Zink A, Pusch CM. Ancestry and pathology in king Tutankhamun's family. *Journal of the*

- American Medical Association 2010; 303: 638–647.
32. Pachajoa H, Rodriguez CA. Holoprosencephaly with premaxillary agenesis in a prehistoric skull. *Archives of Disease in Childhood. Fetal and Neonatal Edition* 2013; 98: 264.
 33. Phenice TW. A newly developed visual method of sexing the os pubis. *Am J Phys Anthropol.* 1969; 30: 297-302.
 34. Buikstra JE, Ubelaker DH. Standards for data collection from human skeletal remains. Fayetteville, AR: Archaeological Survey Research (Series 44), 1994.
 35. Gilbert BM, McKern TW. A method for aging the female os pubis. *Am J Phys Anthropol.* 1973; 38:31-38.
 36. Katz D, Suchey JM. Age determination of the male os pubis. *Am J Phys Anthropol.* 1986; 69: 427-435.
 37. Meindl RS, Lovejoy CO, Mensforth RP, Carlos LD. Accuracy and direction of error in the sexing of the skeleton: Implications for paleodemography. *Am J Phys Anthropol.* 1985; 68: 79-85.
 38. Lovejoy CO, Meindl RS, Pryzbeck TR, Mensforth RP. Chronological metamorphosis of the auricular surface of the ilium: A new method for the determination of adult skeletal age at death. *Am J Phys Anthropol.* 1985; 68: 15-28
 39. Ubelaker D. Human skeletal remains. Excavation, analysis, interpretation. Washington: Taraxacum, 1989.
 40. Alekseev VP. Osteometry (methods of anthropological research). Moscow: Science, 1966.
 41. Alekseev VP, Debets GF. Craniometry (method of anthropological research). Moscow, 1964.
 42. Trotter M, Gleser G. A Re-evaluation of Estimation of Stature Based on Measurements of Stature Taken During Life and of Long Bones after Death. *Am J Phys Anthropol.* 1958; 16: 79-123.
 43. Movsesyan AA, Mamonova NN, Richkov YG. The program and method of research of anomalies of a skull. *Anthropology questions* 1975; 51: 127-150.
 44. Zubov AA. Methodical manual for the anthropological analysis odontological materials. Moscow, 2006.
 45. Ortner DJ, Putschar WGJ. Identification of Pathological Conditions in Human Skeletal Remains. Washington. 1985.
 46. Lieveise AR. Diet and the aetiology of dental calculus. *Int J Osteoarchaeol.* 1999; 9: 219-232.
 47. Littleton J, Frohlich B. An analysis of dental pathology and diet on historic Bahrein. *Paléorient* 1989; 15: 59-84.
 48. Molleson T. A method for the study of activity related skeletal morphologies. *Bioarchaeology of the Near East* 2007; 1:5-33.
 49. Lieveise AR, Bazaliiskii VI, Goriunova OI, Weber AW. Upper Limb Musculoskeletal Stress Markers Among Middle Holocene Foragers of Siberia's Cis-Baikal Region. *Am J Phys Anthropol.* 2009; 138: 458–472
 50. Blondiaux J. À propos de la dame d'Hochfelden et de la pratique cavalière: discussion autour des sites fonctionnels fémoraux. In: *La femme pendant le Moyen Âge et l'Époque Moderne*: Buchet L. (Ed.). Paris: CNRS, p. 97-109, 1994.
 51. Khudaverdyan A.Yu. The anthropology of infectious diseases of Bronze Age and Early Iron Age from Armenia. *International Journal of Dental Anthropology* 2012; 20: 9–37.
 52. Merrett DC, Pfeiffer S. Maxillary sinusitis as in an indicator of respiratory health in past populations. *Am J Phys Anthropol.* 2000; 111: 301-318.
 53. Paju S, Bernstein JM, Haase EM, Scannapieco AF. Molecular analysis of bacterial flora associated with chronically inflamed maxillary sinuses. *J Med Micro.* 2003; 52: 591-597.
 54. Reddy NK. An ethnoarchaeological investigation into the maxillary sinusitis: Pathology of the Chalcolithic record. Unpublished M.A. Dissertation submitted to Deccan College Post Graduate and Research Institute. Pune, 2002.
 55. Naeher LP, Smith KR, Leaderer BP, Mage D, Grajeda R. Indoor and Outdoor PM_{2.5} and CO in high and low density Guatemalan villages. *J Exp Analy and Environmental Epidemiology.* 2000; 10:544-551.
 56. Mushrif-Tripathy V. Maxillary Sinusitis from India: A Bio-cultural Approach. *Korean J Phys Anthropol.* 2014; 27 (1):11-28.