

## TUMORAL CALCINOSIS PRESENTING AS A SOFT TISSUE MASS IN A 16 YEAR OLD PATIENT

MARIJA MILKOVIĆ PERIŠA<sup>1,4</sup>, SANDA ŠITIĆ<sup>1</sup>, IRENA VELIKI DALIĆ<sup>1</sup>,  
LJUBICA LUETIĆ CAVOR<sup>2</sup>, ILIJA GUTEŠA<sup>3</sup> and SVEN SEIWERTH<sup>4</sup>

<sup>1</sup> Department of Pathology, University Hospital for Tumors,  
Sestre milosrdnice University Hospital Center, Zagreb, Croatia;

<sup>2</sup> Department of Radiology, University Hospital for Tumors,  
Sestre milosrdnice University Hospital Center, Zagreb, Croatia;

<sup>3</sup> Department of Surgery, University Hospital for Tumors,  
Sestre milosrdnice University Hospital Center, Zagreb, Croatia;

<sup>4</sup> Department of Pathology, School of Medicine, University of Zagreb, Zagreb, Croatia

---

### Summary

Background: Tumoral calcinosis is a rare clinicopathological condition characterized by periarticular tumor-like calcium deposits most commonly found around major joints, especially the hips, shoulders and elbows. Tumoral calcinosis is not primarily a bone- or cartilage- forming lesion, but it can closely simulate osteochondromatous tumors. These lesions are predominantly seen during the first two decades of life and may be multicentric or bilateral. Laboratory analysis frequently shows high serum phosphate but normal serum calcium levels.

A 16 year old male presented with a huge mass in the left hip which had been growing for a month. MR detected large tumor mass in the left gluteal region with possible infiltration of m.gluteus maximus. Soft tissue mass was surgically resected, measuring 24 cm in diameter. Histologically, it was composed of multiple large cystic spaces with nodules of amorphous calcified deposits surrounded by multinucleated giant cells and mononuclear infiltrates. The lesion was poorly circumscribed with infiltration into surrounding striated muscle.

Tumoral calcinosis is an uncommon and benign condition that generally occurs as a complication of trauma or renal dialysis, and is rarely seen in familial and sporadic cases. It can occur in a variety of clinical settings: primary normophosphatemic, primary hyperphosphatemic and secondary tumoral calcinosis occurring along with disorders that are capable of producing soft tissue calcification. Histologically, tumoral calcinosis is characterized by amorphous calcified deposits in the background of granulomatous appearance with multinucleated giant cells and other inflammatory cells. The differential diagnosis is broad and includes all tumoral calcinosis-like lesions that lead to abnormal dystrophic or metastatic calcium deposition in soft tissues. Surgical excision is the primary treatment.

KEY WORDS: *tumoral calcinosis, radiology, histopathology*

### TUMORSKA KALCINOZA PRIKAZANA KAO MEKOTKIVNA TVORBA U 16-GODIŠNJEG BOLESNIKA – PRIKAZ SLUČAJA

#### Sažetak

Tumorska kalcinoza je rijetko kliničko-patološko stanje obilježeno periartikularnim kalcificiranim deponitima nalik tumorima najčešće smještenim u području kuka, ramena i lakta. Tumorska kalcinoza nije primarna bolest koštano-hrskavičnog sustava, iako svojim obilježjima nalikuje i upućuje na tumor koštano-hrskavičnog sustava. Izraslina se obično pojavljuje multicentrično i bilateralno u prva dva desetljeća života. Laboratorijska analiza učestalo pokazuje povećanu razinu fosfata i normalnu razinu kalcija u serumu.

Lječeni dječak (16 god) imao je veliku tvorbu u području lijevog kuka koja je rasla mjesecima. MR je prikazala izraslinu s mogućom infiltracijom velikog glutealnog mišića. Kirurški je odstranjena neoštro ograničena tvorba najvećeg promjera 24 cm koja je infiltrirala strijajni mišić. Histološki je bila građena od brojnih velikih cističnih prostora s okruglastim kalcificiranim nakupinama okruženim multinuklearnim orijaškim stanicama i mononuklearnim upalnim infiltratom. Tumorska kalcinoza je rijetko, benigno stanje koje se uglavnom očituje kao komplikacija traume ili bubrežne dijalize, a rijetko se viđa i u obiteljskom i u sporadičnom obliku. Može se očitovati u nekoliko kliničkih oblika: primarna normofosfatemična, primarna hiperfosfatemična i sekundarna tumorska kalcinoza. Neovisno o obliku uvijek je prisutan poremećaj s nakupljanjem kalcifikata u mekom tkivu. Histološki se vide amorfnj kalcificirani depoziti okruženi granulomatoznom upalom s multinuklearnim orijaškim i mononuklearnim upalnim stanicama. Diferencijalna dijagnoza obuhvaća široki spektar promjena koje uključuju pretjerano distrofično i metastatsko nakupljanje kalcija u mekom tkivu. Kirurška ekscizija je izbor liječenja.

**KLJUČNE RIJEČI:** tumorska kalcinoza, radiologija, histopatološki nalaz

## INTRODUCTION

Tumoral calcinosis (TC) is a rare clinicopathological condition characterized by calcium salt deposition in periarticular soft tissue. Despite this entity was described by Giard in 1898, Duret in 1899 and Teutschlander in 1935, the term tumoral calcinosis was coined by Inclan et al in 1943 (1-4). The latest group of authors described essential pathologic features of this entity, multiple cysts filled with calcified deposits lined by histiocytes, giant cells and xanthomatous histiocytes. This condition mainly manifests in childhood or adolescence as tumor-like masses around the joints, usually in hip, shoulder and elbow region. The main symptoms are swelling and joint function limitation (4-6). On the basis of 122 reviewing cases and their clinical and pathologic findings, Smack et al divided all TCs in three groups (7). One group are primary normo-phosphatemic TCs usually presenting in first two decades of life as solitary lesions. According to this group of authors these patients are without evident familial connection, although recent literature detected familial connection involving mutations in the gene encoding SAMD9 protein (8). The second group are primary hyperphosphatemic TCs usually presenting during the first and second decades of life (9). This group of patients have genetic predisposition with reduced urinary phosphate excretion caused by recessive mutations in *GALNT3* and *KLOTHO*, that causes the inactivation of FGF23, a phosphaturic hormone (10-13). The third group encompasses secondary TCs connected with chronic renal failure (7). Despite their different etiology and pathogenesis, histopathology is identical in all types suggesting possible common pathway which eventually results in the formation of

the characteristic TC lesions and originates from minimal repetitive trauma and reparative inflammatory process (14). Treatment for the both, first and second group, is early surgical excision, and medical for third group (15,16).

## CASE REPORT

A 16 year old male presented with a huge mass in the left hip which had been growing for a month. MR detected large tumor mass measuring 18.5:13.5 cm in the left gluteal region with possible infiltration of m.gluteus maximus. In dorsomedial part tumor extends to femoral diaphysis (Figure 1.). On gross examination the soft tissue mass was solid and cystic indicating malignant soft tissue tumors. It was surgically resected, measuring 24 cm in the largest diameter. Histologically, it was composed of multiple large cystic spaces with nodules of amorphous calcified deposits surrounded by multinucleated giant cells and mononuclear infiltrates (Figure 2. and 3.). The lesion was poorly circumscribed with infiltration into

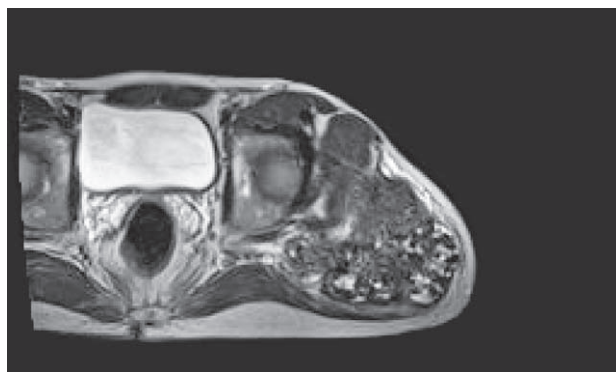


Figure 1. Tumor mass in the left gluteal region (MR)

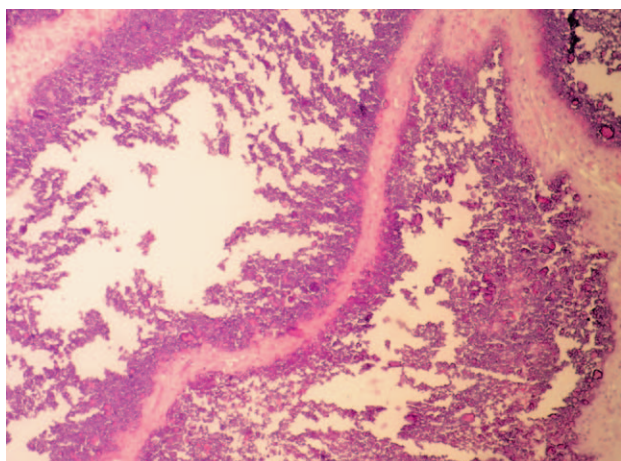


Figure 2. Histology of tumoral calcinosis, H&E stains, 100x

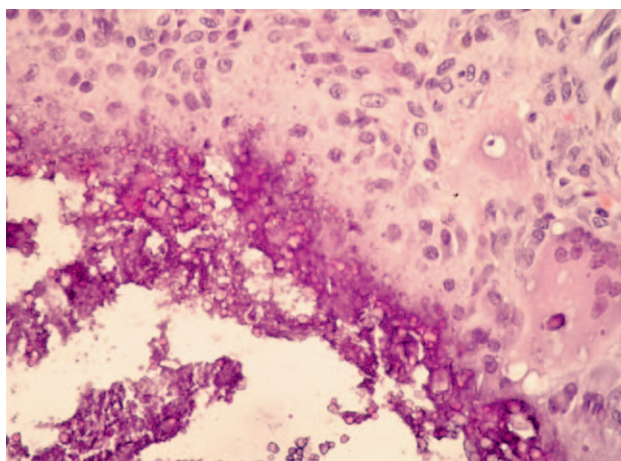


Figure 3. Histology of tumoral calcinosis, H&E stains, 400x

surrounding striated muscle. No signs of malignancy were found.

## DISCUSSION

Tumoral calcinosis is a rare benign condition. Fathi et Sakr reviewed the literature on tumoral calcinosis emphasising the importance of propagating this entity to radiologists, clinicians and pathologists in order to avoid a misleading imprecise diagnosis (17).

This entity was first described in the end of 19<sup>th</sup> century but the term was first stated by Inclin et al in 1943. who described histopathology with inflammation and dystrophic calcificated deposits implicating inflammatory pathogenesis.(1-4). It is well-known that TCs can have different etiology,

but interestingly histopathology of all the lesions is identical. According to clinical manifestation, TCs are divided in three groups, first two groups comprise primary and the third one secondary TCs. Primary TCs either have normal or elevated serum phosphates but both express genetic changes. The third group encompasses patients with renal failure. Diagnostic problem occurs in the group of patients without serum or renal abnormalities, only presenting with periarticular tumor. Petscavage and Richardson presented a case of a young women with tumoral calcinosis mimicking recurrent osteosarcoma (18). The patient was initially diagnosed with osteosarcoma of the left femur and tibia at the age of 12, and after surgery treated with chemotherapy. At the age of 29 a new lesion occurred in the proximal thigh which clinically and radiologically implied the recurrent tumor. It is interesting that the patient had also undergone dialysis due to renal failure in the end stage of renal disease secondary to type 1 diabetes. After surgical excision and re-evaluation of the initial pathology report the diagnosis of tumoral calcinosis was established in both of the tumors. According to information that osteosarcoma is the most common primary bone malignant tumor in the adolescent group it is clearly that the periarticular tumor mass in childhood and adolescents implies to malignant tumor (19). But nevertheless, tumoral calcinosis can appear radiographically similar to malignant tumors and therefore should be considered in differential diagnosis.

## CONCLUSION

Although tumoral calcinosis is a benign condition, it represents serious clinical and radiological problem in differentiation from malignant bone tumors. These patients are usually young without evident or underlying clinical conditions. It is usually associated with familial predisposition, although usually other family members do not present any manifestation of the disease. Hereby we present a case of tumoral calcinosis in a young male with large tumor mass which clinically and radiologically resembled malignant osteocartilaginous tumor.

## REFERENCES

1. Giard A. Sur la calcification hibernale. C R Soc Biol. 1898;10:1013-15.

2. Duret MH. Tumors multiples et singulieres des bourses sereuses. Bull Mem Soc Anat Paris. 1899;74:725-33.
3. Teutschlander O. Über progressive Lipogranulomatose der Muskulatur. Klin Wochenschr. 1935;14:451-3.
4. Inclan A, Leon P, Camejo MG. Tumoral calcinosis. J Am Med Ass.1943;121:490-5.
5. McClatchie S, Bremner AD. Tumoral calcinosis – an unrecognized disease. Br Med J. 1969;1:153-5.
6. Slavin G, Klenerman L, Darby A, Bansal S. Tumoral calcinosis in England. Br Med J. 1973;1:147-9.
7. Smack D, Norton SA, Fitzpatrick JE. Proposal for pathogenesis-based classification of tumoral calcinosis. Int J Dermatol. 1996;35:265-71.
8. Hershkovitz D, Gross Y, Nahum S, Yehezkel S, Sarig O, Uitto J, et al. Functional characterization of SAMD9, a protein deficient in normophosphatemic familial tumoral calcinosis. J Invest Dermatol. 2011;131:662-9.
9. Olsen KM, Chew FS. Tumoral calcinosis: pearls, polemics, and alternative possibilities. Radiographics. 2006;26:871-85.
10. Topaz O, Shurman DL, Bergman R, Indelman M, Ratajczak P, Mizrachi M, et al. Mutations in GALNT3, encoding a protein involved in O-linked glycosylation, cause familial tumoral calcinosis. Nat Genet. 2004;36:579-81.
11. Benet-Pages A, Orlik P, Strom TM, Lorenz-Depiereux B. An FGF23 missense mutation causes familial tumoral calcinosis with hyperphosphatemia. Hum Mol Genet. 2005;14:385-90.
12. Larsson T, Yu X, Davis SI, Draman MS, Mooney SD, Cullen MJ, et al. A novel recessive mutation in fibroblast growth factor-23 causes familial tumoral calcinosis. J Clin Endocrinol Metab. 2005;90:2424-7.
13. Ichikawa S, Imel EA, Kreiter ML, Yu X, Mackenzie DS, Sorenson AH, et al. A homozygous missense mutation in human KLOTHO causes severe tumoral calcinosis. J Musculoskelet Neuronal Interact. 2007;7:318-9.
14. Slavin RE, Wen J, Barmada A. Tumoral calcinosis – a pathogenetic overview: a histological and ultrastructural study with a report of two new cases, one in infancy. Int J Surg Pathol. 2012;20:462-73.
15. Steinbach LS, Johnston JO, Tepper EF, Honda GD, Martel W. Tumoral calcinosis: radiologic-pathologic correlation. Skeletal Radiol. 1995;24:573-8.
16. Seyahi A, Atalar AC, Ergin HK. Tumoral calcinosis: Clinical and biochemical aspects of a patient treated with vinpocetine. Eur J Intern Med. 2006;17:436-8.
17. Fathi I, Sakr M. Review of tumoral calcinosis: A rare clinic-pathological entity. World J Clin Cases. 2014;2:409-14.
18. Pestcavage JM, Richardson ML. Tumoral calcinosis mimicking recurrent osteosarcoma. Radiol Case Rep. 2009;4:336-9.
19. Manaster BJ, May DA, Disler DG. Musculoskeletal imaging: The requisites. 3<sup>rd</sup> ed. Philadelphia PA: Mosby;2007.

*Corresponding author: Marija Milković Periša, Department of Pathology, University Hospital for Tumors, Sestre milosrdnice University Hospital Center, Ilica 197, 10000 Zagreb, Croatia. e-mail: mmperisa@gmail.com*