

## Kerion Celsi due to *Microsporum canis* with a Dermatophytid Reaction

**Biljana Gorgievska-Sukarovska<sup>1</sup>, Mihael Skerlev<sup>2,3</sup>, Lidija Žele-Starčević<sup>4</sup>, Karmela Husar<sup>2</sup>, Mirna Halasz<sup>5</sup>**

<sup>1</sup>Dermatology and Venereology Unit, Zabok General Hospital, Zabok, Croatia; <sup>2</sup>Zagreb University School of Medicine, University Department of Dermatology and Venereology, Zagreb University Hospital, Zagreb, Croatia; <sup>3</sup>Reference Laboratory for Dermatological Mycology and Parasitology of the Ministry of Health and Social Welfare of Republic of Croatia, Zagreb, Croatia; <sup>4</sup>Department of Clinical and Molecular Microbiology, Zagreb University Hospital, Zagreb, Croatia; <sup>5</sup>Ruđer Bošković Institute, Division of Molecular Biology, Laboratory for Molecular genetics, Zagreb, Croatia

### Corresponding author:

Biljana Gorgievska-Sukarovska, MD  
Dermatology and Venereology Unit  
Zabok General Hospital  
Bračak 8  
49210 Zabok  
Croatia  
[Biljana.gs@gmail.com](mailto:Biljana.gs@gmail.com)

Received: February 25, 2016  
Accepted: May 25, 2017

**ABSTRACT** *Microsporum (M.) canis* is the most common fungus to cause tinea capitis in Europe, especially in the Mediterranean region and South and Central Europe. Fungal scalp infections caused by *M. canis* tend to be non-inflammatory. Recently, a growing number of cases of tinea capitis characterized by inflammatory infection caused by *M. canis* and *M. gypseum* have been registered. We present a case of highly inflammatory tinea capitis, also known as kerion celsi, caused by *M. canis* in a 6-year-old-patient. Scalp infections due to *M. canis* are a growing problem in dermatological practice. Changes in epidemiology, etiology, and clinical patterns of fungal infections due to *M. canis* are significant. Greater awareness of this problem is needed in order to establish proper diagnosis and successful treatment strategy for these patients.

**KEY WORDS:** kerion celsi, tinea capitis profunda, dermatophyte, *Microsporum canis*

### INTRODUCTION

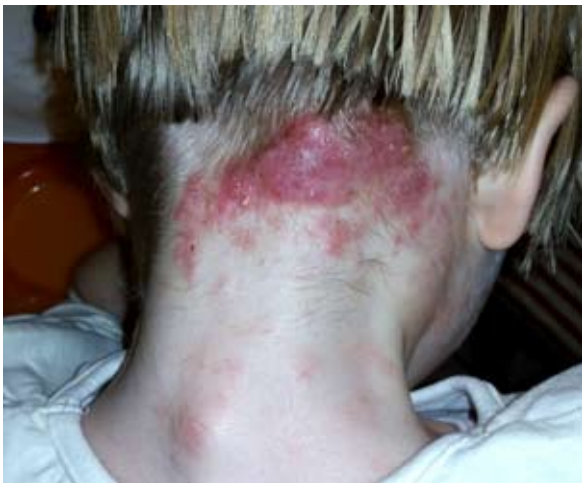Tinea capitis is an infection of the scalp with a dermatophyte fungus from the *Microsporum (M.)* and *Trichophyton (T.)* genera. Although common in children, it can occur in adults as well, though less frequently (1). In Europe, especially in the Mediterranean region and South and Central Europe, *M. canis* is the most common dermatophyte fungus to cause tinea capitis (2). Fungal scalp infections caused by *M. canis* tend to be non-inflammatory, presenting as single or multiple patches with broken-off hairs, discrete erythema, and scaling (3). Recently, significant changes in epidemiology, etiology, and clinical patterns of fungal infections caused by the *Microsporum* species have

been observed (4-6). A growing number of cases of tinea capitis characterized by inflammatory infection caused by *M. canis* and *M. gypseum* have been registered. Previously, *Trichophyton* spp. used to be a typical and almost the only pathogen in such cases (5,6).

We present a case of highly inflammatory tinea capitis, also known as kerion celsi, with a dermatophytid reaction caused by *M. canis*.

### CASE REPORT

A 6-year-old, otherwise healthy girl, with tender, infiltrated, 6×4 cm large plaque in the occipital

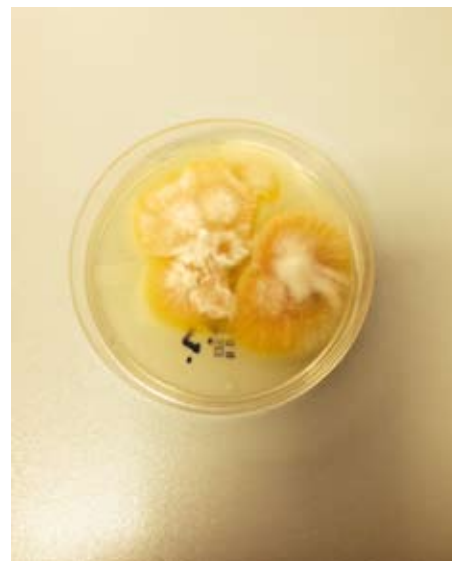

**Figure 1.** Acute inflammation with tumorous mass, pustules, and loss of hair in the occipital region.

region of the scalp was examined at our Department. Almost complete loss of hair, a few satellite plaques with pustules on the surface, and exudation from some of the follicular orifices could be observed (Figure 1). Multiple annular lesions were spread over the neck and shoulders. Additionally, papular exanthema of the trunk and bilateral cervical lymphadenopathy were present. The patient was in otherwise good condition, and routine laboratory investigations were all within the normal limits.

The first lesion was reported to have started 2.5 months before the visit as a small 1 cm large nodus. The girl had no pets, but had contact with a stray cat during vacation. No one else in the home was affected with any skin or scalp problems.

The previously prescribed treatment by the patient's general physician, consisting of topical corticosteroids (alclometasonum dipropionate, betamethasone), topical mupirocinum, and clotrimazole, was not successful. Furthermore, new satellite infiltrated plaques appeared at the site of infection. Further examination had been performed at the Reference Centre for Dermatological Mycology and Parasitology of the Ministry of Health of Republic of Croatia. Fungal culture on a modified Sabouraud dextrose medium showed flat, white to creamy, spread-out colonies with a cottony surface and golden brownish-yellow reversed pigment (Figure 2). Diagnosis of kerion due to *M. canis* was established. *M. canis* was also confirmed in the isolate by the use of the polymerase chain reaction-restriction fragment length polymorphism (PCR-RFLP) molecular methods. For this purpose, ITS1 and ITS4 universal primers were used to amplify the ITS1-5.8S ITS2 of rDNA region. The RFLP analysis of the PCR products of the isolated strain and



**Figure 2.** Culture of *M. canis* on modified Sabouraud dextrose agar.

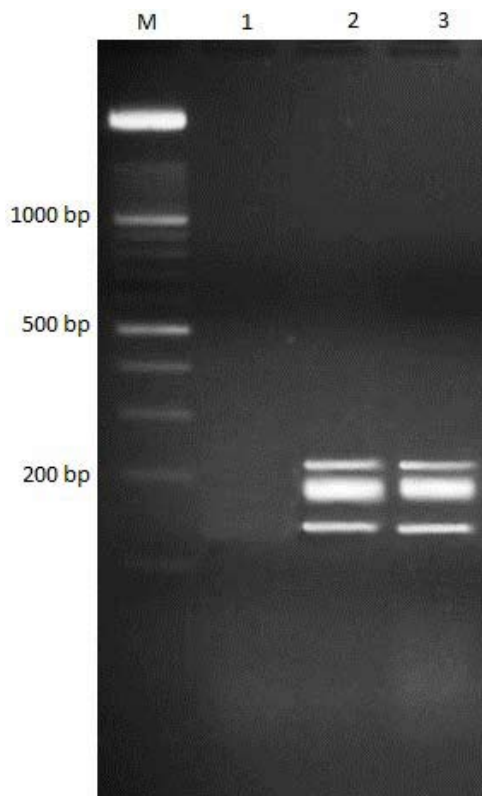
reference strain of *M. canis* ATCC 36299, using a *Hinf*I restriction enzyme, a unique pattern of *M. canis* was revealed (Figure 3).

Mycological examination of the papular lesions of the trunk was negative, and we considered papular exanthema of the trunk to be a dermatophytid reaction related to the *Microsporum* infection of the scalp. Bacterial culture from the throat was negative, but *Hemophilus influenzae* was isolated in the nose.

Treatment with oral terbinafine 125 mg/day was prescribed together with antibacterial and antimycotic topical treatment in order to reduce the tumorous mass and to heal the bacterial secondary infection caused by *Staphylococcus aureus*, which had also been isolated from the involved scalp lesion. This treatment consisted of gyrodalate ointment followed with miconazole cream. Because of very severe inflammation and in order to relieve symptoms of "id" reaction and to prevent scarring to the maximal possible extent, systemic prednisolone 10 mg/day for 7 days was administered, including topical betamethasone cream for the papular lesions on the trunk. *Hemophilus influenzae* was treated with systemic cefalexin over 5 days. After 12 weeks of therapy, complete clinical and mycological regression had been observed. Symptoms of Id reaction resolved after one week of therapy.

## DISCUSSION

Fungal infections caused by *Microsporum* species involving both the skin and its appendages (hair in particular) represent a challenging problem in derma-



**Figure 3.** Gel electrophoresis of polymerase chain reaction (PCR) products digested with the *HinfI* restriction enzyme. M: molecular marker; bp: base pair; line 1: negative control; line 2: reference strain *M. canis* ATCC; line 3: *M. canis* case strain.

tology. Over the last few decades, significant changes in the epidemiology, etiology, and clinical patterns of mycotic infections due to *Microsporum* spp. have been observed (4,5). The frequency of *M. canis* infections in Croatia ranged from 1 case in the year 1978 to 328 positive cultures in 2008 based on data from the Reference Laboratory for Dermatological Mycology and Parasitology of the Ministry of Health and Social Welfare of the Republic of Croatia of the Department of Dermatology and Venereology in Zagreb (6). Since 2008, the number of isolates of *M. canis* has remained at about the same level of annual frequency. Fungal scalp infections caused by *M. canis* tend to be non-inflammatory, but in recent decades cases of deep-seated, inflammatory tinea capitis due to *M. canis* and *M. gypseum* have been observed. During a period of 8 years (2001- 2008), 58 cases of deep-seated tinea capitis due to *Microsporum* spp. have been observed in the Reference Laboratory (5). The question arises as to why the same fungus might cause both superficial (non-inflammatory) and deep-seated (inflammatory) tinea capitis and whether all lineages of *M. canis* are equally virulent to humans. The results of Sharma

*et al.* suggest that some *M. canis* strains have an increased infective potential for humans, but they did not find an association between genotypes and the type of tinea caused by a genotype (7). Other studies using molecular methods found that *M. canis* is very unique in comparison with other dermatophytes (8), and these results are in conflict with the results obtained by Cano *et al.* who found 21 genotypes among 24 human isolates of *M. canis* (9). The other problem that has arisen is resistance to therapy. Infections caused by *Microsporum* spp. generally represent a greater therapeutic problem than infections due to *Trichophyton* spp., especially when therapy of tinea capitis is considered (10). Some reports have indicated that higher dose of terbinafine than indicated by the label might sometimes be needed in the therapy of *Microsporum* spp.-related tinea capitis (11,12).

The other species of the *Microsporum* genus can cause deep-seated tinea capitis. Cases caused by the geophilic fungus *M. gypseum* (13,14) or the anthropophilic *M. audouini* (15) have been also reported.

Recent data show that secondary immunologic eruptions in response to tinea capitis are not rare (16,17). The German dermatologist Josef Jadassohn was the first to report a dermatophytid reaction related to trichophytic kerion in 1918 (18). The reaction can occur before or after initiation of systemic therapy, and its occurrence does not seem to be drug-dependent. These immunologic reactions can differ in clinical presentation, ranging from papular exanthema to erythema nodosum. In our patient, papular exanthema on the trunk was related to kerion of the scalp due to *Microsporum canis*.

## CONCLUSION

Scalp infections due to *M. canis* are a growing problem in dermatological practice. Changes in epidemiology and clinical pattern of fungal infections due to *M. canis* have been significant in recent years. *M. canis* can also be responsible for dermatophytid reactions, not only *Trichophyton* spp. as previously reported. Greater awareness of this problem is needed in order to establish proper diagnosis and successful treatment strategy.

## References:

1. Elewski BE. Tinea capitis: a current perspective. *J Am Acad Dermatol* 2000;42:1-20.
2. Ginter-Hanselmayer G, Weger W, Ilkit M, Smolle J. Epidemiology of tinea capitis in Europe: current state and changing patterns. *Mycoses* 2007;50(suppl 2):6-13.

3. Gupta AK, Summerbell RC. Tinea capitis. *Med Mycol* 2000;38:255-87.
4. Lipozenčić J, Skerlev M, Pašić A. Overview: changing face of cutaneous infections and infestations. *Clin Dermatol* 2002;20:104-8.
5. Skerlev M. Kerion Celsi: the changing face of *Microsporum* species infection. 2nd. Trends in medical mycology, Oct 23-26, 2005, Berlin, Germany. (Abstract) *Mycoses* 2005;48(suppl 2):69.
6. Skerlev M, Miklič P. The changing face of *Microsporum* spp infections. *Clin Dermatol* 2010;28:146-50.
7. Sharma R, de Hoog S, Presber W, Graser Y. A virulent genotype of *Microsporum canis* is responsible for the majority of human infections. *J Clin Microbiol* 2007;56:1377-85.
8. Dobrowolska A, Debska J, Kozłowska M, Staczek P. Strains differentiation of *Microsporum canis* by RAPD analysis using (GACA)<sub>4</sub> and (ACA)<sub>5</sub> primers. *Pol J Microbiol* 2011;60(2):145-8.
9. Cano J, Rezusta A, Sole M, Gil J, Rubio MC, Revillo MJ, et al. Inter-single-sequence-repeat-PCR typing as a new tool for identification of *Microsporum canis* strains. *J Dermatol Sci* 2005;39:17-21.
10. Krafchik B. The clinical efficacy of terbinafine in the treatment of tinea capitis. *Rev Contemp Pharmacother* 1997;8:313-24.
11. Koumantaki E, Kakourou T, Rallis E, Riga P, Georgala S. Double dose of terbinafine is required for *Microsporum canis* tinea capitis. *Pediatr Dermatol* 2001;18:339-42.
12. Lipozenčić J, Skerlev M, Orofino-Costa R, Zaitz VC, Horvath A, Chouela E, et al. A randomized, double-blind, parallel-group, duration-finding study of oral terbinafine and open-label, high-dose griseofulvin in children with tinea capitis due to *Microsporum* species. *Br J Dermatol* 2002;146:816-23.
13. Torres-Guerrero E, Martinez-Herrera E, Arroyo-Camarena S, Porras C, Arenas R. Kerion Celsi: A report of two cases due to *Microsporum gypseum* and *Trichophyton tonsurans*. *Our Dermatol Online* 2015;6:424-7.
14. Zhang R, Ran Y, Dai Y, Zhang H, Lu Y. A case of kerion Celsi by *Microsporum gypseum* in a boy following dermatoplasty for a scalp wound from a road accident. *Med Mycol* 2011;49:90-3.
15. Fernandez S, Amaro C, da Luz Martinz M, Inacio J, Araujo T, Viera R, et al. Kerion caused by *Microsporum audouinii* in a child. *Med Mycol Case Rep* 2013;2:52-4.
16. Cheng N, Rucker WD, Cohen BA. Dermatophytid in tinea capitis: rarely reported common phenomenon with clinical implications. *Pediatrics* 2011;128:453-7.
17. Demir FT, Karadag AS. Are dermatophytid reactions in patients with kerion Celsi much more common than previously thought? A prospective study. *Pediatr Dermatol* 2015;32(5):635-40.
18. Ilkit M, Durdu M, Karakas M. Cutaneous id reactions: A comprehensive review of clinical manifestations, epidemiology, etiology, and management. *Crit Rev Microbiol* 2012;38(3):191-202.