

Izvantjelesna membranska oksigenacija u odraslih bolesnika

Extracorporeal Membrane Oxygenation in Adults

Gordana Bačić¹*,
Vjekoslav Tomulić¹,
Igor Medved¹,
Luka Zaputović¹,
Teodora Zaninović
Jurjević¹,
David Gobić¹

Medicinski fakultet
Sveučilišta u Rijeci, Klinički
bolnički centar Rijeka,
Rijeka, Hrvatska

University of Rijeka School
of Medicine, University
Hospital Centre Rijeka,
Rijeka, Croatia

RECEIVED:
April 11, 2017

UPDATED:
May 18, 2017

ACCEPTED:
May 20, 2017



SAŽETAK: Izvantjelesna membranska oksigenacija (engl. *Extracorporeal Membrane Oxygenation*, ECMO) postupak je izvantjelesne mehaničke cirkulacijske ili respiracijske potpore koji se primjenjuje primarno u bolesnika sa životno ugrožavajućim oblicima zatajivanja rada srca ili pluća. Dva su osnovna oblika ECMO potpore: vensko-venski (V-V) i vensko-arterijski (V-A) ECMO. V-V ECMO osigurava funkciju izmjene plinova u krvi i primjenjuje se u slučaju teške reverzibilne respiracijske insuficijencije. V-A ECMO podržava funkciju rada srca i pluća, a, osim pri reverzibilnim oblicima oštećenja srčane funkcije, može se rabiti i pri njezinu ireverzibilnom oštećenju, kao premoštenje do transplantacije srca ili ugradnje uređaja za mehaničku cirkulacijsku potporu. ECMO je invazivan i tehnički složen postupak koji se obavlja u kritično bolesnih pa stoga nosi visok rizik od pojave komplikacija. Rezultati liječenja ECMO-om razlikuju se ovisno o indikaciji za sam postupak. Bolesnici u kojih je ECMO primijenjen radi respiracijske potpore imaju bolje ishode u usporedbi s onima s kardiogenim šokom ili zastojem srca. Iako nedostaju dokazi temeljeni na velikim randomiziranim studijama koji bi poduprli njegovu primjenu, ECMO je u kliničkoj praksi spasonosna metoda liječenja u dobro odabranih, kritičnih bolesnika.

SUMMARY: Extracorporeal membrane oxygenation (ECMO) is a procedure that provides extracorporeal mechanical circulatory or respiratory support and is used primarily in patients with life-threatening forms of heart or respiratory failure. There are two basic types of ECMO support: veno-venous (VV) and veno-arterial (VA) ECMO. VV ECMO ensures blood gas exchange and is applied in cases of severe reversible respiratory insufficiency. VA ECMO supports the function of the heart and lungs; other than in reversible forms of damaged heart function, it can also be used in irreversible forms of heart failure as a bridge to heart transplantation or to the implantation of mechanical circulatory support device. ECMO is an invasive and technically complex procedure that is performed in critically ill patients and thus has a high risk of complications. Results of ECMO treatment vary depending on the indications for the procedure itself. Patients in whom ECMO was applied for respiratory support show better outcomes compared with those with cardiogenic shock or cardiac arrest. Despite a lack of evidence based on large randomized studies to support its application, in clinical practice ECMO represents a life-saving method of treatment in well-selected critical patients.

KLJUČNE RIJEČI: izvantjelesna membranska oksigenacija, kardiogeni šok, respiracijska insuficijencija.

KEYWORDS: extracorporeal membrane oxygenation, cardiogenic shock, respiratory insufficiency.

CITATION: *Cardiol Croat.* 2017;12(5-6):216-225. | <https://doi.org/10.15836/ccar2017.216>

***ADDRESS FOR CORRESPONDENCE:** Gordana Bačić, Klinički bolnički centar Rijeka, Krešimirova 42, HR-51000 Rijeka, Croatia. / Phone: +385-91-534-2225 / E-mail: bacic_gordana@hotmail.com

ORCID: Gordana Bačić, <http://orcid.org/0000-0002-9050-5314> • Vjekoslav Tomulić, <http://orcid.org/0000-0002-3749-5559>
Igor Medved, <http://orcid.org/0000-0002-2029-200X> • Luka Zaputović, <http://orcid.org/0000-0001-9415-9618>
Teodora Zaninović Jurjević, <http://orcid.org/0000-0001-8359-3910> • David Gobić, <http://orcid.org/0000-0001-9406-1127>

Uvod

Izvantjelesna membranska oksigenacija (engl. *Extracorporeal Membrane Oxygenation*, ECMO) postupak je izvantjelesne cirkulacijske ili respiracijske potpore tijekom kojeg se s pomoću posebnog uređaja venska krv odvodi iz organizma, oksigenira i zatim vraća u organizam. Osnovni cilj ECMO-a jest zadovoljavajuća opskrba tkiva

Introduction

Extracorporeal membrane oxygenation (ECMO) is a procedure that provides extracorporeal mechanical circulatory or respiratory support in which a special device is used to extract venous blood from the organism, oxygenate it, and then return it to the organism. The basic goal of ECMO is achieving satisfactory oxygen supply

kisikom i odstranjivanje ugljikova dioksida u bolesnika s teškim oblicima zatajivanja rada srca ili pluća, kada su refraktarni na konvencionalno liječenje¹.

Postupak je izvantjelesne membranske oksigenacije prvi put primijenjen 1971. godine². Tijekom idućih desetljeća postaje općeprihvaćena metoda u liječenju teških oblika zatajivanja srca i pluća u dječjoj dobi, a tek posljednjih godina uobičajeni modalitet liječenja i u kritičnih bolesnika odrasle dobi³⁻⁵. Zahvaljujući razvoju tehnologije i stjecanju iskustva rezultati liječenja ECMO-om sve su bolji, a indikacije postupno proširene⁶⁻¹⁰. Posljedično tomu, broj bolesnika liječenih ECMO-om svake godine znatno raste. Prema podatcima ELSO (*Extracorporeal Life Support Organisation*) registra, do siječnja 2017. godine ECMO je primijenjen u 86 287 bolesnika diljem svijeta, među kojima je 26 813 bolesnika (31 %) bilo odrasle dobi¹¹.

Kako bi rezultati liječenja ECMO-om bili što bolji, važno je pravodobno prepoznati bolesnika kojemu je potrebna izvantjelesna cirkulacijska ili respiracijska potpora, utvrditi postoje li kontraindikacije te odabrati odgovarajući oblik liječenja. Stoga je cilj ovoga preglednog članka prikazati osnovne principe liječenja ECMO-om u odrasloj populaciji, indikacije i kontraindikacije prema postojećim smjernicama te moguće komplikacije postupka.

Način rada i osnovni oblici ECMO potpore

Osnovni dijelovi ECMO sustava jesu crpka koja omogućuje protok krvi, oksigenator i kanile (**Slika 1**). Deoksigenirana venska krv odvodi se iz organizma preko „pristupne“ kanile postavljene u venski dio cirkulacije zahvaljujući negativnom tlaku koji stvara crpka. Crpka zatim potiskuje krv prema ok-

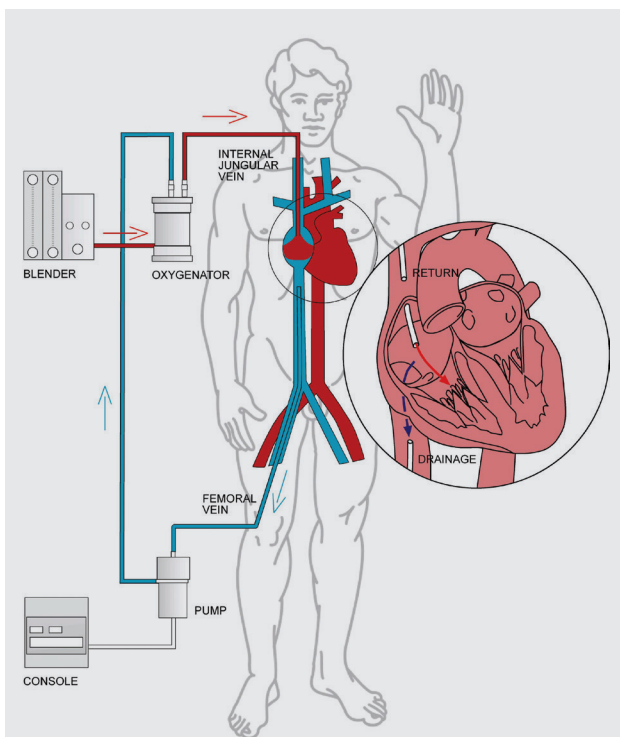


FIGURE 1. Extracorporeal membrane oxygenation circuit configuration.

to the body and removal of carbon dioxide in patients with severe forms of heart or respiratory failure, when they are refractory to conventional treatment¹.

The procedure of extracorporeal membrane oxygenation was used for the first time in 1971². Over the following decades, it became an universally accepted method in the treatment of severe forms of heart and respiratory failure in childhood; only in recent years has it become a common treatment modality in adult critical patients³⁻⁵. Thanks to the technical developments and growing experience, the results of ECMO treatment have been increasingly improving, and the indications were gradually extended⁶⁻¹⁰. Consequently, the number of patients treated with ECMO has been growing significantly every year. According to the ELSO (*Extracorporeal Life Support Organisation*) registry, by January 2017 ECMO had been applied in 86 287 patients all over the world, of whom 26 813 (31%) were adult patients¹¹.

In order to make the results of ECMO treatment as favorable as possible, timely recognition of patients who require extracorporeal circulatory or respiratory support is important, as well as determining whether any contraindications are present and choosing the appropriate form of treatment. Thus, the goal of this review is to present the basic principles of ECMO treatment in the adult population, the indications and contraindications based on current guidelines, and the possible complications from this procedure.

The procedure and basic forms of ECMO support

The basic parts of the ECMO system are a pump that allows blood flow, an oxygenator, and cannulae (**Figure 1**). Deoxy-

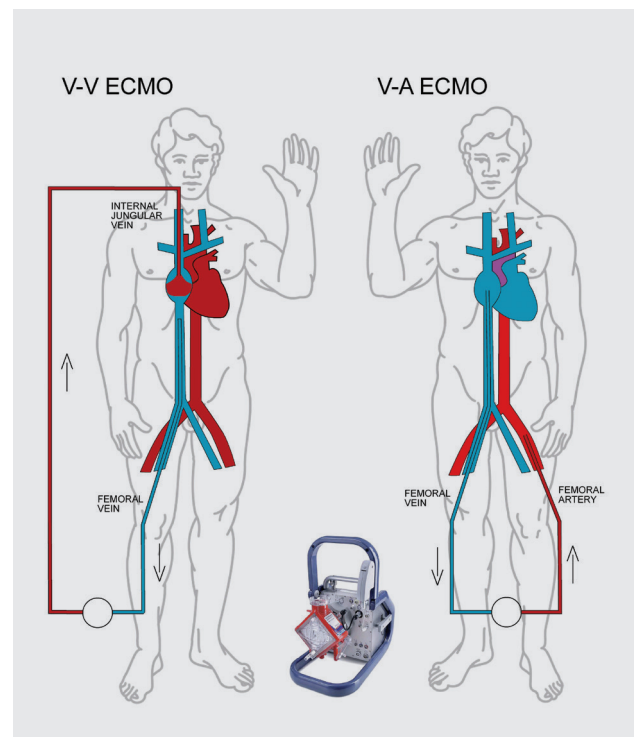


FIGURE 2. Veno-venous and peripheral veno-arterial extracorporeal membrane oxygenation.

sigeneratoru u kojem se krv obogaćuje kisikom, uz istodobno odstranjivanje ugljikova dioksida. Ako je potrebno održavati temperaturu krvi i tijela na određenoj vrijednosti, krv zasićena kisikom usmjeruje se u izmjenjivač topline, gdje se zagrijava ili hladi, a onda preko „povratne“ kanile vraća u arterijski ili venski dio cirkulacije. Upravo na temelju „povratnoga“ vaskularnog pristupa razlikujemo dva oblika ECMO potpore, vensko-venski (V-V) i vensko-arterijski (V-A) ECMO (**Slika 2**). Koji će se modalitet primijeniti u pojedinog bolesnika, ovisi o funkciji srca.

Vensko-venski ECMO

Prilikom primjene V-V ECMO-a venska se krv iz bolesnika odvodi preko „pristupne“ kanile, najčešće postavljene u femoralnu venu, a zatim oksigenirana vraća u venski sustav „povratnom“ kanilom u unutarnjoj jugularnoj veni. V-V ECMO na taj način osigurava oksigenaciju i uklanjanje ugljikova dioksida iz venske krvi, a ujedno smanjuje razinu potrebne mehaničke ventilacijske potpore i minimizira rizik od ozljede pluća uzrokovane ventilacijom¹². S obzirom na to da se oksigenirana krv ponovno vraća u venski dio cirkulacije, V-V ECMO ne osigurava hemodinamsku potporu i primjenjuje se u bolesnika bez znatnog oštećenja funkcije srca kojima je potrebna isključivo respiracijska potpora. Za razliku od V-A ECMO-a, omogućuje provedbu fiziološke hemodinamike uz minimalni rizik od sustavne tromboembolije i bez potrebe za kanilacijom arterija. Stoga je učestalost komplikacija tijekom V-V ECMO-a mnogo manja¹³.

Vensko-arterijski ECMO

Tijekom primjene V-A ECMO-a oksigenirana se krv se vraća u organizam preko „povratne“ kanile postavljene u jednu od velikih arterija. Na taj način, poput standardnoga kardiopulmonalnoga premoštenja, V-A ECMO zaobilazi srce i pluća te preuzima ili podržava cirkulacijsku funkciju srca, a može istodobno preuzeti ili poduprijeti funkciju izmjene plinova u krvi. Sustavni arterijski protok rezultat je protoka u cirkulacijskome krugu i vlastita izbačaja lijeve klijetke. Može se primjenjivati pri lijevostranom i desnostranom zatajivanju srca¹⁴. Postoje dva oblika V-A ECMO-a, centralni i periferni. Centralni V-A ECMO podrazumijeva postavljanje kanila u centralne strukture (desna pretklijetka i uzlazna aorta) otvorenim kirurškim pristupom, a primjenjuje se nakon kardiokirurških zahvata u slučaju otežanog odvajanja bolesnika od stroja za izvantjelesni krvotok ili pak pri teškim oblicima kardiorespiratornog zatajivanja, kada su potrebni visoki protoci za postizanje dostatne perfuzije tkiva¹⁵. Kod perifernog V-A ECMO-a kanuliraju se velike periferne krvne žile (najčešće u femoralnoj regiji), perkutanom pristupom ili kirurškom preparacijom. Takav modalitet osigurava pretežno cirkulacijsku potporu i ne primjenjuje se u bolesnika s respiratornom insuficijencijom¹⁶. Periferni V-A ECMO s malim kanilama koje se postavljaju perkutanom putom, tzv. niskoprotocni vensko-arterijski ECMO, omogućuje vrlo brzi početak hemodinamske potpore u bolesnika u kardiorespiratornom arestu¹⁷.

Indikacije za primjenu ECMO-a

Od samog početka, ECMO se najčešće primjenjuje u bolesnika s potencijalno reverzibilnim, životno ugrožavajućim oblicima srčanog ili respiracijskog zatajivanja, koji ne reagiraju na kon-

genated venous blood is led outside the organism using an “access” cannula placed in the venous part of the circulation using the negative pressure created by the pump. The pump then pushes blood towards the oxygenator, where it is enriched with oxygen while carbon dioxide is simultaneously removed. If it is necessary to keep the blood and body temperatures at a specific level, the blood saturated with oxygen is directed to a heat exchanger where it is heated or cooled, after which the blood is returned to the arterial or venous part of the circulation via the “return” cannula. The choice between these two return approaches is what differentiates the two types of ECMO support, veno-venous (VV) and veno-arterial (VA) ECMO (**Figure 2**). Which modality will be applied in a particular patient depends on heart function.

Veno-Venous ECMO

When applying VV ECMO, venous blood is extracted through the “access” cannula, usually placed in the femoral vein; the oxygenated blood is returned to the venous system through the “return” cannula in the internal jugular vein. In this way, VV ECMO ensures oxygenation and the removal of carbon dioxide from the venous blood, while at the same time reducing the necessary level of mechanical ventilation support and thus minimizing the risk of ventilator-induced lung injury¹². Since the oxygenated blood returns to the venous part of the circulation, VV ECMO does not ensure hemodynamic support and is used in patients with no significant damage to heart function who only need respiratory support. As opposed to VA ECMO, it allows physiological hemodynamics to take place with a minimal risk of systemic thromboembolism and without artery cannulation being necessary. Thus the incidence of complications during VV ECMO is significantly lower¹³.

Veno-arterial ECMO

In VA ECMO, the oxygenated blood is returned to the organism via a “return” cannula placed in one of the great arteries. In this way, as in standard cardiopulmonary bypasses, VA ECMO circumvents the heart and lungs and takes over or supports the circulatory function of the heart and can simultaneously take over or support the function of gas exchange in the blood. Systemic arterial flow is a result of the flow in the circulatory system and left ventricular ejection. It can be used for left-sided and right-sided heart failure¹⁴. There are two forms of VA ECMO: central and peripheral. In central VA ECMO, the cannulae are placed in the central structures (the right atrium and ascending aorta) by using an open surgical approach; this is used after cardiac surgery procedures in cases of inability to wean the patient from an external blood flow device or in cases of severe cardiorespiratory failure when there is high flow needed to achieve sufficient tissue perfusion¹⁵. In peripheral VA ECMO, the great peripheral blood vessels (usually in the femoral region) are cannulated using either a percutaneous approach or surgical preparation. This modality ensures predominantly circulatory support and is not used in patients with respiratory insufficiency¹⁶. Peripheral VA ECMO with small cannulae placed with a percutaneous approach, the so-called low-flow veno-arterial ECMO, allows very rapid initiation of hemodynamic support for patients in cardiorespiratory arrest¹⁷.

vencionalno liječenje. Međutim, u današnje vrijeme indikacije za ECMO potporu mnogo su šire i obuhvaćaju određene bolesnike s ireverzibilnim oštećenjem ciljnih organa, zastoje srca, kao i bolesnike podvrgnute rizičnim postupcima u intervencijskoj kardiologiji¹.

Indikacije za V-A ECMO

V-A ECMO najčešće se primjenjuje nakon kardiokirurških zahvata, pri otežanom odvajanju bolesnika od stroja za izvantjelesnu cirkulaciju. Sljedeća najvažnija indikacija jest kardiogeni šok, bilo koje etiologije, koji perzistira unatoč odgovarajućoj nadoknadi intravaskularnog volumena, visokim dozama inotropnih lijekova i primjeni intraaortne balonske pumpe¹⁸⁻²⁰. Kardiogeni je šok definiran srčanim indeksom $< 2 \text{ L/min/m}^2$ i perzistirajućom hipotenzijom (sistolčki tlak $< 90 \text{ mmHg}$), unatoč normalnim ili povišenim tlakovima punjenja klijetki²¹. Mogući su uzroci akutna zbijavanja poput velikog infarkta miokarda, fulminantnog miokarditisa ili pak masivne plućne tromboembolije s akutnim zatajivanjem desnoga srca. Uloga ECMO-a u navedenim situacijama može biti premošćivanje vremena do definitivnoga zbrinjavanja u obliku revaskularizacije miokarda ili embolektomije (engl. *bridge to therapy*) ili pak do oporavka (engl. *bridge to recovery*). V-A ECMO također se primjenjuje u bolesnika s kroničnim, ireverzibilnim oštećenjem srčane funkcije. U terminalnoj fazi kroničnog zatajivanja srca može poslužiti kao prenosno liječenje do transplantacije srca (engl. *bridge to transplantation*) ili ugradnje uređaja za mehaničku potporu cirkulaciji (engl. *ventricular assist device*, VAD), koja pak može biti privremena (engl. *bridge to device*) ili konačna metoda liječenja (engl. *destination therapy*)²⁰.

Jedna od novijih indikacija za primjenu ECMO-a jest zastoj srca. Prema ELSO smjernicama, ECMO potporu treba razmotriti u slučaju zastoja srca s potencijalno reverzibilnim uzrokom, koji perzistira dulje od 10 minuta unatoč primjeni naprednih mjera oživljavanja²². U usporedbi s konvencionalnom kardiopulmonalnom resuscitacijom, bolesnici u kojih je primijenjen ECPR (engl. *Extracorporeal Cardiopulmonary Resuscitation*) imaju veću stopu preživljenja i bolji neurološki ishod²³⁻²⁶.

Cirkulacijska potpora V-A ECMO-om danas je neizostavna pomoćna metoda u području intervencijske kardiologije. Osim toga što omogućuje izvođenje perkutane koronarne intervencije (engl. *percutaneous coronary intervention*, PCI) u bolesnika koji su već hemodinamski nestabilni, ECMO se primjenjuje i kao preventivna mjera pri visokorizičnim PCI postupcima, kada postoji veliki rizik od hemodinamskog urušaja zbog same intervencije²⁷⁻²⁹. Najčešće je riječ o intervencijama na glavnom deblu lijeve koronarne arterije, teškim stenozama svih triju koronarnih arterija ili o intervenciji na jedinoj prohodnoj arteriji. Sve su indikacije za cirkulacijsku potporu sažete u **Tablici 1**.

Indikacije za V-V ECMO

Prema ELSO smjernicama, primjenu V-V ECMO-a treba razmotriti u bolesnika s potencijalno reverzibilnom hipoksičnom respiracijskom insuficijencijom bilo koje etiologije, kada je rizik od smrti jednak ili veći od 50 %, a indicirana je u slučaju rizika od smrti jednakog ili većeg od 80 % (**Tablica 2**)³⁰. Rizik od smrti procjenjuje na temelju vrijednosti omjera parcijalnog arterij-

Indications for the application of ECMO

Since the very beginning, ECMO has been most commonly used in patients with potentially reversible, life-threatening forms of heart or respiratory failure refractory to conventional treatment. However, today the indications for ECMO support are much broader and encompass certain patients with irreversible damage to target organs, cardiac arrest, and also patients undergoing high-risk procedures in interventional cardiology¹.

Indication for VA ECMO

VA ECMO is most commonly applied after cardiac surgery procedures, in cases of inability to wean the patient from the external blood flow device. The next most important indication is cardiogenic shock of any etiology that persists despite appropriate supplementation of intravascular volume, high doses of inotropic medications, and application of an intra-aortic balloon pump¹⁸⁻²⁰. Cardiogenic shock is defined as a heart index $< 2 \text{ L/min/m}^2$ and persistent hypotension (systolic pressure $< 90 \text{ mmHg}$) despite normal or elevated ventricular filling pressures²¹. Possible causes are acute events such as large myocardial infarction, fulminant myocarditis, or massive pulmonary thromboembolism with acute right-sided heart failure. The role of ECMO in the above situations can be to serve as a bridge to therapy in the form of myocardial revascularization or embolectomy or to serve as a bridge to recovery. VA ECMO is also used in patients with chronic, irreversible heart failure. In advanced chronic heart failure, it can serve as a bridge to heart transplantation or to implantation of a ventricular assist device (VAD), which can be temporary (bridge to bridge) or the destination therapy²⁰.

Cardiac arrest is one of the newer indications for ECMO application. According to ELSO guidelines, ECMO support should be considered in cases of cardiac arrest with a potentially reversible cause that persists for longer than 10 minutes despite the application of advanced resuscitation measures²². In comparison with conventional cardiopulmonary resuscitation, patients in which ECPR (extracorporeal cardiopulmonary resuscitation) was applied have a higher rate of survival and better neurological outcomes²³⁻²⁶.

Using VA ECMO for circulatory support has become an indispensable auxiliary method in the field of interventional cardiology. In addition to allowing the performance of percutaneous coronary interventions (PCI) in patients with ex-

TABLE 1. Indications for veno-arterial extracorporeal membrane oxygenation.

Cardiogenic shock: acute coronary syndrome, fulminant myocarditis, sepsis with profound cardiac depression, massive pulmonary embolism
Post-cardiotomy: inability to wean from cardiopulmonary bypass
Post-heart transplant: primary graft failure
End-stage heart failure: as a bridge to heart transplantation, implantation of VAD support or as a bridge to decision
Refractory cardiac arrest (>10 min)
Periprocedural support for high-risk percutaneous coronary interventions

TABLE 2. Indications for veno-venous extracorporeal membrane oxygenation.

Hypoxic respiratory failure with $\text{PaO}_2/\text{FiO}_2 < 100$ on $\text{FiO}_2 > 90\%$ and/or Murray score 3-4 despite optimal care for >6 hours
 CO_2 retention on mechanical ventilation despite high plateau pressure (>30 cm H_2O)
 Severe air leak syndromes
 Need for intubation in a patient on lung transplant list
 Immediate cardiac or respiratory collapse (pulmonary embolism, blocked airway unresponsive to optimal care)

skog tlaka kisika i udjela kisika u udahnutoj smjesi, $\text{PaO}_2/\text{FiO}_2$ (engl. *partial arterial pressure of oxygen/fraction of inspired oxygen ratio*) ili zbroja Murrayjeva bodovnog sustava:

- 50 %-tni rizik od smrti udružen je s $\text{PaO}_2/\text{FiO}_2 < 150$ uz $\text{FiO}_2 > 0,9$ i/ili s Murrayjevim zbrojem 2 – 3;
- 80 %-tni rizik od smrti udružen je s $\text{PaO}_2/\text{FiO}_2 < 100$ uz $\text{FiO}_2 > 0,9$ i/ili s Murrayjevim zbrojem 4 – 6 tijekom 6 sati i dulje.

Murrayjev je zbroj bodovni sustav koji se temelji na četiri parametrima (omjeru $\text{PaO}_2/\text{FiO}_2$, PEEP-u (pozitivan tlak na kraju izdisaja, engl. *positive end-expiratory pressure*), dinamičkoj popustljivosti pluća, broju plućnih kvadranta s alveolarnom infiltracijom na radiogramu prsnih organa), a upućuje na težinu respiracijske insuficijencije³¹. Pri procjeni je li riječ o reverzibilnom oštećenju plućne funkcije u obzir treba uzeti etiologiju osnovne bolesti, dob, prethodno bolesnikovo stanje i trajanje mehaničke ventilacije. Liječenje ECMO-om u pojedinim stanjima poput aspiracijske upale pluća, potapanja ili astme, postiže vrlo dobre rezultate. Trajanje mehaničke ventilacije dulje od sedam dana i starija životna dob povezani su s velikim rizikom od nepovoljnog ishoda unatoč primjeni ECMO-a, zbog čega se smatraju relativnim kontraindikacijama³².

Kontraindikacije za ECMO

S obzirom na to da je postupak ECMO visoko rizičan i skup, prije donošenja odluke o početku liječenja u svakog je bolesnika prijeko potrebno individualno procijeniti rizik i korist od primjene samog postupka. Prema postojećim smjernicama, vrlo je malo apsolutnih kontraindikacija za primjenu ECMO-a i većina stanja relativne su kontraindikacije^{1,33}.

Apsolutnu kontraindikaciju za ECMO imaju:

- bolesnici s ireverzibilnim oštećenjem ciljnih organa koji nisu kandidati za transplantaciju srca ili pluća, odnosno neki drugi oblik potpore, jer nije vjerojatan nastavak kvalitetnog života nakon oporavka (npr. terminalna maligna bolest, neposvjedočeni kardiorespiratorni arrest, teško oštećenje središnjega živčanog sustava)
- nesuradljivi bolesnici.¹

Najčešće relativne kontraindikacije vezane su za primjenu antikoagulantne terapije, manifestno krvarenje i visoku dob. U slučaju nemogućnosti primjene nefrakcioniranog heparina (engl. *unfractionated heparin*, UFH), primjerice zbog heparinom inducirane trombocitopenije (engl. *heparin induced thrombocytopenia*, HIT), mogu se rabiti drugi antikoagulansi poput bivalirudina ili argatrobana. Zahvaljujući sustavu kanila i dijelovima uređaja obloženima antikoagulantnim agensom ECMO se kratkotrajno može provoditi i bez upotrebe sustavne

isting hemodinamičnu nestabilnost, ECMO je također primijenjen kao preventivna mjera u visokorizičnim PCI postupcima kada postoji visok rizik od hemodinamičnog kolapsa zbog same intervencije²⁷⁻²⁹. Ove su najčešće intervencije na glavnom stablu lijeve koronarne arterije, teške stenozirane koronarne arterije, ili intervencije na jedinoj koronarnoj arteriji. Sve indikacije za cirkulatornu podršku su sažeto navedene u **Table 1**.

Indications for VV ECMO

Prema ELSO smjernicama, primjena VV ECMO treba se razmotriti kod bolesnika s potencijalno reverzibilnom hipoksičnom respiracijskom insuficijencijom bilo koje etiologije kada je rizik od smrti jednak ili veći od 50%, a indikacija je u slučajevima kada je rizik od smrti jednak ili veći od 80% (**Table 2**)³⁰. Rizik od smrti procjenjuje se na temelju vrijednosti $\text{PaO}_2/\text{FiO}_2$ (partial arterial pressure of oxygen/fraction of inspired oxygen) omjera ili Murrayjevog bodovnog sustava:

- 50 %-tni rizik od smrti udružen je s $\text{PaO}_2/\text{FiO}_2 < 150$ uz $\text{FiO}_2 > 0,9$ and/or Murray score 2-3;
- 80 %-tni rizik od smrti udružen je s $\text{PaO}_2/\text{FiO}_2 < 100$ uz $\text{FiO}_2 > 0,9$ and/or Murray score 4-6 during 6 hours and longer.

Murrayjev bodovni sustav temelji se na četiri parametara ($\text{PaO}_2/\text{FiO}_2$ omjer, PEEP (Positive End Expiratory Pressure), dinamička plućna complijanca, broj plućnih kvadranta s alveolarnom infiltracijom na prsnom radiogramu) i označava težinu respiracijske insuficijencije³¹. Pri procjeni je li riječ o reverzibilnom oštećenju plućne funkcije u obzir treba uzeti etiologiju osnovne bolesti, dob, prethodno bolesnikovo stanje i trajanje mehaničke ventilacije. Liječenje ECMO-om u pojedinim stanjima poput aspiracijske upale pluća, potapanja ili astme, postiže vrlo dobre rezultate. Trajanje mehaničke ventilacije dulje od sedam dana i starija životna dob povezani su s velikim rizikom od nepovoljnog ishoda unatoč primjeni ECMO-a, zbog čega se smatraju relativnim kontraindikacijama³².

Contraindications for ECMO

Since ECMO is a high-risk and costly procedure, it is crucial to individually assess the risk and benefit of the procedure before deciding to commence the treatment. According to current guidelines, there are very few absolute contraindications for ECMO applications, and most conditions represent only relative contraindications^{1,33}.

Absolute contraindications for ECMO are:

- Patients with irreversible damage to target organs who are not suitable for heart or lung transplantation or other forms of support, since continued quality life after recovery is not likely (e.g. terminal malignant disease, unwitnessed cardiorespiratory arrest, severe damage to the central nervous system)
- Noncompliant patients¹

The most common relative contraindications are related to the application of anticoagulation therapy, manifest bleeding, and advanced age. When the application of unfractionated heparin (UFH) is not possible, for instance due to heparin-induced thrombocytopenia (HIT), other anticoagulants such as bivalirudin or argatroban can be used. Thanks to the system of cannulae and parts of the device coated in an antico-

antikoagulacije, što omogućuje njegovu primjenu u bolesnika s manifestnim krvarenjem koje se ne može zaustaviti odgovarajućim postupcima³³. Dobna granica nakon koje se ne preporučuje primjena potpore ECMO-om nije jasno definirana, a rizik od nepovoljnog ishoda povećava se razmjerno dobi³².

Pojedini oblici ECMO-a imaju specifične kontraindikacije. Periferni V-A ECMO kontraindiciran je kod teške periferne vaskularne bolesti, kao i u slučaju aneurizme abdominalne aorte s trombotskim masama. V-V ECMO ne smije se primjeniti pri teškom desnostranom ili lijevostranom zatajavanju srca i kod teške plućne hipertenzije (srednji tlak u plućnoj arteriji > 50 mmHg)³³.

Komplikacije postupka ECMO

ECMO je invazivan, tehnički vrlo složen postupak koji narušava cjelovitost krvožilnih stijenki i upleće se u brojne fiziološke procese. Bolesnici u kojih je indiciran, već zbog same osnovne bolesti imaju veliku predviđenu stopu smrtnosti². Stoga su komplikacije vezane za ECMO još uvijek česte i znatno povećavaju pobol i smrtnost^{5,34-39}. Prema dosadašnjim studijama, V-V ECMO ima manje komplikacija u usporedbi s V-A ECMO-om. Djeca u odnosu prema odraslim bolesnicima imaju manji ukupni broj komplikacija, no veću učestalost neuroloških komplikacija^{32,40}. Komplikacije liječenja ECMO-om možemo podijeliti u dvije glavne kategorije:

- komplikacije vezane za cirkulacijski krug (mehaničke),
- komplikacije vezane za bolesnika (medicinske).

Komplikacije vezane za cirkulacijski krug

Mehaničke komplikacije vezane za sam ECMO sustav uključuju trombozu, zračnu embolizaciju, disfunkciju pojedinih dijelova cirkulacijskoga kruga i prenizak ili potpuni prekid protoka krvi. Prisutnost malih ugrušaka (veličine 1 – 5 mm) unutar sustava česta je pojava i najčešće ne zahtijeva intervenciju, nego kontinuirano praćenje. Ako je riječ o većim ili rastućim ugrušcima, potrebno je zamijeniti pojedine ili sve sastavnice cirkulacijskoga kruga jer mogu uzrokovati poremećaj rada crpke ili oksigenatora, sustavnu tromboemboliju ili pak razvoj diseminirane intravaskularne koagulopatije. Prodor zraka u cirkulacijski krug rijetka je, ali životno ugrožavajuća komplikacija koja zahtijeva trenutačno klemanje kanila i zaustavljanje protoka³¹.

Komplikacije vezane za bolesnika

Najčešća komplikacija vezana za bolesnika jest krvarenje koje se pojavljuje u 10 – 30 % slučajeva^{32,41}. Čimbenici koji uz sustavnu heparinizaciju pridonose povećanom riziku od krvarenja jesu trombocitopenija, poremećaj funkcije trombocita i relativni nedostatak faktora zgrušavanja, kao posljedica kontakta krvi s umjetnim materijalom unutar cirkulacijskoga kruga. Liječenje klinički značajnih krvarenja temelji se na smanjivanju ciljnih vrijednosti aktiviranoga vremena zgrušavanja (engl. *activated clotting time*, ACT) ili na privremenom ukidanju heparina te, ako je potrebno, transfuzijom krvi, nadoknadom trombocita i faktora zgrušavanja⁴².

Zbog sustavne primjene UFH-a moguća je pojava heparinom inducirane trombocitopenije praćene sklonošću trombozi. Tada se UFH mora zamijeniti drugim antikoagulantnim

agulant agent, short-term ECMO application is possible even without systemic anticoagulation therapy, which allows its use in patients with manifest bleeding that cannot be stopped with the appropriate procedures³³. The age limit after which application of ECMO is not recommended has not been clearly defined, but the risk of adverse outcomes grows proportionately to the age of the patient³².

Particular ECMO types have specific contraindications. Peripheral VA ECMO is contraindicated in severe peripheral vascular disease and in cases of aneurysm of the abdominal aorta with thrombotic masses. VV ECMO should not be applied in severe right-sided or left-sided heart failure and in severe pulmonary hypertension (mean pressure in the pulmonary artery >50 mmHg)³³.

Complications in ECMO procedures

ECMO is an invasive and technically very complex procedure that compromises the integrity of the blood vessel walls and interferes with numerous physiological processes. Patients in which it is indicated already have a high predicted mortality rate due to their primary illness². Consequently, the complications associated with ECMO are still common and significantly increase the morbidity and mortality^{5,34-39}. According to currently completed studies, VV ECMO has fewer complications in comparison with VA ECMO. Children have a lower total number of complications in comparison with adults, but have a higher incidence of neurological complications^{32,40}. Complications due to ECMO treatment can be divided into two main categories:

- Complications related to the ECMO circuit (mechanical)
- Complications related to the patient (medical)

Complications related to the ECMO circuit

Mechanical complications associated with the ECMO system itself include thrombosis, air embolism, dysfunction of individual parts of the circuit, and loss or reduction of circuit flow. The presence of small blood clots (1-5 mm in size) within the system is a common occurrence and usually does not require intervention but just continuous monitoring. If the clots are larger or growing, it is necessary to replace some or all parts of the circuit since the clots can cause a disturbance in the function of the pump or oxygenator, systemic thromboembolism, or the development of disseminated intravascular coagulopathy. Air entrainment into the circuit is a rare, but life-threatening complication that requires immediate clamping of the cannulae and stopping the flow³¹.

Complications related to the patient

The most common complication related to the patient is bleeding which is present in 10-30% of cases^{32,41}. In addition to systemic heparinization, the factors that contribute to the increased risk of bleeding are thrombocytopenia, thrombocyte function disorder, and relative lack of clotting factors as a consequence of blood contacting the artificial material within the circuit. Treatment of clinically significant bleeding is based on reducing target activated clotting time (ACT) values or temporary stoppage of heparin and, if necessary, blood transfusion, reconstitution of thrombocytes, and clotting factors⁴².

lijekom poput direktnih inhibitora trombina bivalirudina ili argatrobana⁴³.

Uz krvarenje, infekcije su sljedeća najvažnija skupina komplikacija. Rizik od infekcije povećava se trajanjem potpore ECMO-om zbog prisutnosti intravaskularnih kanila, a teško stanje bolesnika, kojemu je najčešće potrebna dugotrajna potpora, dodatno povećava ovaj rizik³⁸.

Učestalost neuroloških komplikacija varira između 4 i 37 %, ovisno o bolesnikovoj dobi⁴⁴. Prema podacima ELSO registra, najčešće su u novorođenčadi, u obliku intrakranijalnoga krvarenja (11 %), epileptičnih napadaja (7 %) i ishemijskoga moždanog udara (3,5 %). U odrasloj je dobi češća pojava ishemijskoga moždanog udara (4 %), a zatim slijede epileptični napadaji te intrakranijalno krvarenje s podjednakom učestalošću (2 %)⁴⁵. Neurološke komplikacije u svim dobnim skupinama povećavaju stopu bolničke smrtnosti⁴⁴.

Specifične komplikacije V-A ECMO-a

Tijekom primjene V-A ECMO-a moguća je pojava specifičnih komplikacija. Zbog kanulacije može nastati ozljeda arterije (perforacija ili disekcija), ishemija ekstremiteta distalno od kanile ili se razviti pseudoaneurizma na mjestu postavljanja. Također su zabilježeni slučajevi stvaranja tromba u srčanim šuplinama zbog zastoja (staze) krvi u slučajevima slabe kontraktibilnosti².

Rezultati liječenja

Prema godišnjem izvješću ELSO registra, do siječnja 2017. godine ECMO je primijenjen u 86 287 bolesnika. Među 26 813 odraslih bolesnika, njih 15 875 (59,2 %) uspješno je odvojeno od ECMO-a, a 12 616 (47,1 %) preživjelo je do otpusta ili premještaja u drugu ustanovu. Rezultati liječenja razlikuju se u pojedinim skupinama bolesnika, ovisno o indikaciji za sam postupak. Preživljenje do otpusta ili premještaja u bolesnika u kojih je ECMO primijenjen radi respiracijske potpore iznosi 57 %, među bolesnicima s kardiogenom šokom 40 %, a uz ECPR 28 %¹¹.

Prve randomizirane studije provedene u odraslih bolesnika s teškom respiracijskom insuficijencijom nisu dokazale prednost ECMO-a u usporedbi s konvencionalnim metodama liječenja⁴⁶. Tek 2009. godine objavljivanje rezultata studije CESAR (*Conventional ventilatory support versus ECMO for Severe Adult Respiratory failure*), kao i rezultati liječenja tijekom pandemije H1N1 virusne upale pluća u Australiji i na Novom Zelandu, ponovno su potaknuli interes za primjenu ECMO-a u odraslih bolesnika. Navedena multicentrična studija pokazala je bolje preživljenje i manju onesposobljenost nakon šest mjeseci u bolesnika s ARDS-om upućenih u ECMO centar u usporedbi s konvencionalnim pristupom^{5,47}. Do danas veći broj pretežno opservacijskih i kontroliranih studija također pokazuje bolje ishode u bolesnika s respiracijskom insuficijencijom liječenih ECMO-om nego u konvencionalno liječenih^{31,35,36,48-55}.

U bolesnika s indikacijom za cirkulacijsku potporu nema provedenih randomiziranih studija te se podatci o ishodima temelje pretežno na opservacijskim studijama i serijama slučajeva. Stope preživljenja bolesnika liječenih V-A ECMO-om zbog kardiogenog šoka, zastoja srca ili nemogućnosti odvajanja od stroja za izvantjelesnu cirkulaciju nakon kardiokirur-

Due to systemic UFH application, the appearance of heparin-induced thrombocytopenia with concomitant predisposition to thrombosis is a possibility. In such cases, UFH must be replaced by different anticoagulant medication such as direct thrombin inhibitors bivalirudin or argatroban⁴³.

After bleeding, infections are the next most significant group of complications. The risk of infection rises with the duration of ECMO support due to the presence of intravascular cannulae, and the critical condition of patients who most commonly need long-term support further exacerbates this risk³⁸.

The incidence of neurological complications varies between 4-37% depending on the age of the patient⁴⁴. According to data from the ELSO registry, complications are most common in newborns in the form of intracranial bleeding (11%), epileptic seizures (7%), and ischemic stroke (3.5%). Ischemic stroke is more common in adulthood (4%), followed by epileptic seizures and intracranial bleeding, both with comparable incidence (2%)⁴⁵. Neurological complications in all age groups increase the rate of hospital mortality⁴⁴.

VA ECMO-specific complications

Specific complications are possible during the application of VA ECMO. Cannulation can lead to injury to the artery (perforation or dissection), ischemia of the extremities distally from the cannula, or to development of pseudoaneurysm at the insertion site. In addition, cases of thrombus formation in heart cavities have been reported, caused by blood stasis in cases of low ventricular output².

Treatment results

According to the annual report from the ELSO registry, ECMO was applied in 86 287 patients by January 2017. Among the 26 813 adult patients, 15 875 (59.2%) were successfully weaned from ECMO, and 12 616 (47.1%) survived until discharge or transfer to another institution. Treatment results differ in individual groups of patients depending on the indications for the procedure. Survival until discharge or transfer for patients in whom ECMO was applied for respiratory support was 57%, 40% for patients with cardiogenic shock, and 28% with ECPR¹¹.

The first randomized studies undertaken on adult patients with severe respiratory insufficiency did not demonstrate the advantage of ECMO in comparison with conventional methods of treatment⁴⁶. It was only in 2009 that the publication of the results of the CESAR study (*Conventional ventilatory support versus ECMO for Severe Adult Respiratory failure*) as well as treatment results during the H1N1 viral pneumonia epidemic in Australia and New Zealand once again sparked interest for the application of ECMO in adult patients. This multicentric study demonstrated better survival and lower disability after six months in patients with ARDS referred to an ECMO center in comparison with the conventional approach^{5,47}. In the meantime, the majority of mostly observational and controlled studies also showed better outcomes in patients with respiratory insufficiency treated with ECMO in comparison with conventional treatment^{31,35,36,48-55}.

There have been no randomized studies conducted on patients with indications for circulatory support, and outcome

ških zahvata, u navedenim studijama iznose 24 – 53 %⁵⁶⁻⁶³. Kada je indikacija za ECMO bio fulminantni miokarditis, stopa je preživljenja čak 71 – 80 %⁶⁴. Lošiji ishodi liječenja u skupini bolesnika s kardiogenim šokom u usporedbi s bolesnicima s respiracijskom insuficijencijom posljedica su osnovne bolesti, ali i veće učestalosti komplikacija tijekom primjene V-A ECMO-a. Skupina bolesnika sa zastojem srca ima očekivano najlošije ishode liječenja^{65,66}.

Zaključak

ECMO je oblik mehaničke izvantjelesne cirkulacijske ili respiracijske potpore koji se primarno primjenjuje u bolesnika s teškim oblicima zatajivanja srca i pluća s visokom predviđenom smrtnošću. Iako nedostaju dokazi temeljeni na velikim randomiziranim studijama, ECMO je u kliničkoj praksi spasonosna metoda liječenja u dobro odabranih bolesnika odrasle dobi.

data are mostly based on observational studies and case series. The survival rates of patients treated with VA ECMO due to cardiogenic shock, cardiac arrest, or inability to wean from an external blood flow device after surgical procedures in these studies were 24-53%⁵⁶⁻⁶³. When fulminant myocarditis was the indication for ECMO, the survival rate was as high as 71-80%⁶⁴. Poorer treatment outcomes in the patient group with cardiogenic shock in comparison with patients with respiratory insufficiency were a consequence of the primary disease, but also of the higher incidence of complications during VA ECMO application. The patient group with cardiac arrest had the worst treatment outcomes, as expected^{65,66}.

Conclusion

ECMO is a form of extracorporeal mechanical circulatory or respiratory support that is primarily used in patients with severe forms of heart and respiratory failure with high predicted mortality. Although evidence based on large randomized studies is lacking, in clinical practice ECMO represents a life-saving method of treatment in well-selected adult patients.

LITERATURE

1. Extracorporeal Life Support Organisation. ELSO Guidelines for Cardiopulmonary Extracorporeal Life Support. 2013. Available from: <https://www.else.org/resources/guidelines.aspx> (18 November 2016)
2. Makdasi G, Wang IW. Extra Corporeal Membrane Oxygenation (ECMO) review of a lifesaving technology. *J Thorac Dis.* 2015 Jul;7(7):E166-76. <https://doi.org/10.3978/j.issn.2072-1439.2015.07.17>
3. MacLaren G, Combes A, Bartlett RH. Contemporary extracorporeal membrane oxygenation for adult respiratory failure: life support in the new era. *Intensive Care Med.* 2012;38:210-20. <https://doi.org/10.1007/s00134-011-2439-2>
4. Shekar K, Mullany DV, Thomson B, Ziegenfuss M, Platts DG, Fraser JF. Extracorporeal life support devices and strategies for management of acute cardiorespiratory failure in adult patients: a comprehensive review. *Crit Care.* 2014 May 9;18(3):219. <https://doi.org/10.1186/cc13865>
5. Peek GJ, Mugford M, Tiruvoipati R, Wilson A, Allen E, Thalanany MM, et al; CESAR trial collaboration. Efficacy and economic assessment of conventional ventilatory support versus extracorporeal membrane oxygenation for severe adult respiratory failure (CESAR): a multicentre randomised controlled trial. *Lancet.* 2009;374:1351-63. [https://doi.org/10.1016/S0140-6736\(09\)61069-2](https://doi.org/10.1016/S0140-6736(09)61069-2)
6. Marasco SF, Esmore DS, Negri J, Rowland M, Newcomb A, Rosenfeldt FL, et al. Early institution of mechanical support improves outcomes in primary cardiac allograft failure. *J Heart Lung Transplant.* 2005;24:2037-42. <https://doi.org/10.1016/j.healun.2005.06.007>
7. Acker MA. Mechanical circulatory support for patients with acute-fulminant myocarditis. *Ann Thorac Surg.* 2001 Mar;71(3 Suppl):S73-6. [https://doi.org/10.1016/S0003-4975\(00\)02628-X](https://doi.org/10.1016/S0003-4975(00)02628-X)
8. McFadden PM, Greene CL. The evolution of intraoperative support in lung transplantation: Cardiopulmonary bypass to extracorporeal membrane oxygenation. *J Thorac Cardiovasc Surg.* 2015;149:1158-60. <https://doi.org/10.1016/j.jtcvs.2014.12.020>
9. Gulack BC, Hirji SA, Hartwig MG. Bridge to lung transplantation and rescue post-transplant: the expanding role of extracorporeal membrane oxygenation. *J Thorac Dis.* 2014;6:1070-9. <https://doi.org/10.3978/j.issn.2072-1439.2014.06.04>
10. Bermudez CA, Shiose A, Esper SA, Shigemura N, D'Cunha J, Bhamra JK, et al. Outcomes of intraoperative venoarterial extracorporeal membrane oxygenation versus cardiopulmonary bypass during lung transplantation. *Ann Thorac Surg.* 2014 Dec;98(6):1936-42. <https://doi.org/10.1016/j.athoracsur.2014.06.072>
11. Extracorporeal Life Support Registry Report. Available from: <https://www.else.org/Registry/Statistics/InternationalSummary.aspx> (3 April 2017)
12. Acute Respiratory Distress Syndrome Network, Brower RG, Matthay MA, Morris A, Schoenfeld D, Thompson BT, Wheeler A. Ventilation with lower tidal volumes as compared with traditional tidal volumes for acute lung injury and acute respiratory distress syndrome. *N Engl J Med.* 2000;342:1301-8. <https://doi.org/10.1056/NEJM200005043421801>
13. Hung V, Vuylsteke A, Valchanov K. Extracorporeal membrane oxygenation: coming to an ICU near you. *Journal of the Intensive Care Society.* 2012;13(1):31-38. <https://doi.org/10.1177/175114371201300110>
14. Berman M, Tsui S, Vuylsteke A, Snell A, Colah S, Latimer R, et al. See comment in PubMed Commons below Successful extracorporeal membrane oxygenation support after pulmonary thromboendarterectomy. *Ann Thorac Surg.* 2008 Oct;86(4):1261-7. <https://doi.org/10.1016/j.athoracsur.2008.06.037>
15. Rastan AJ, Dege A, Mohr M, Doll N, Falk V, Walther T, et al. Early and late outcomes of 517 consecutive adult patients treated with extracorporeal membrane oxygenation for refractory postcardiotomy cardiogenic shock. *J Thorac Cardiovasc Surg.* 2010;139:302-11. <https://doi.org/10.1016/j.jtcvs.2009.10.043>
16. Sidebotham D, McGeorge A, McGuinness S, Edwards M, Willcox T, Beca J. Extracorporeal membrane oxygenation for treating severe cardiac and respiratory disease in adults: Part 1--overview of extracorporeal membrane oxygenation. *J Cardiothorac Vasc Anesth.* 2009 Dec;23(6):886-92. <https://doi.org/10.1053/j.jvca.2009.08.006>
17. Arlt M, Philipp A, Zimmermann M, Voelkel S, Aman M, Bein T, et al. Emergency use of extracorporeal membrane oxygenation in cardiopulmonary failure *Artif Organs.* 2009 Sep;33(9):696-703. <https://doi.org/10.1111/j.1525-1594.2009.00860.x>
18. Abrams D, Combes A, Brodie D. Extracorporeal membrane oxygenation in cardiopulmonary disease in adults. *J Am Coll Cardiol.* 2014 Jul 1;63(25 Pt A):2769-78. <https://doi.org/10.1016/j.jacc.2014.03.046>
19. Takayama H, Truby L, Koekort M, Uriel N, Colombo P, Mancini DM, et al. Clinical outcome of mechanical circulatory support for refractory cardiogenic shock in the current era. *J Heart Lung Transplant.* 2013;32:106-11. <https://doi.org/10.1016/j.healun.2012.10.005>
20. Extracorporeal Life Support Organization. ELSO Guidelines for Adult Cardiac Failure. Supplement to the ELSO General Guideline. 2013. Available from: <https://www.else.org/resources/guidelines.aspx> (20 November 2016)
21. Reynolds HR, Hochman JS. Cardiogenic shock: current concepts and improving outcomes. *Circulation.* 2008;117(5):686-97. <https://doi.org/10.1161/CIRCULATIONAHA.106.613596>
22. Extracorporeal Life Support Organization. ELSO Guidelines for ECP Cases. Supplement to the ELSO General Guidelines. 2013. Available from: <https://www.else.org/resources/guidelines.aspx> (20 November 2016)

23. Shin TG, Jo IJ, Sim MS, Song YB, Yang JH, Hahn JY, et al. Two-year survival and neurological outcome of in-hospital cardiac arrest patients rescued by extracorporeal cardiopulmonary resuscitation. *Int J Cardiol.* 2013;168:3424-30. <https://doi.org/10.1016/j.ijcard.2013.04.183>
24. Maekawa K, Tanno K, Hase M, Mori K, Asai Y. Extracorporeal cardiopulmonary resuscitation for patients with out-of-hospital cardiac arrest of cardiac origin: a propensity-matched study and predictor analysis. *Crit Care Med.* 2013;41:1186-96. <https://doi.org/10.1097/CCM.0b013e31827ca4c8>
25. Chen YS, Lin JW, Yu HY, Ko WJ, Jerng JS, Chang WT, et al. Cardiopulmonary resuscitation with assisted extracorporeal life-support versus conventional cardiopulmonary resuscitation in adults with in-hospital cardiac arrest: an observational study and propensity analysis. *Lancet.* 2008;372:554-61. [https://doi.org/10.1016/S0140-6736\(08\)60958-7](https://doi.org/10.1016/S0140-6736(08)60958-7)
26. Ortega-Deballon I, Hornby L, Shemie SD, Bhanji F, Guadagno E. Extracorporeal resuscitation for refractory out-of-hospital cardiac arrest in adults: A systematic review of international practices and outcomes. *Resuscitation.* 2016;101:12-20. <https://doi.org/10.1016/j.resuscitation.2016.01.018>
27. Teirstein PS, Vogel RA, Dorros G, Stertzer SH, Vandormael MG, Smith SC Jr, et al. Prophylactic versus standby cardiopulmonary support for high risk percutaneous transluminal coronary angioplasty. *J Am Coll Cardiol.* 1993;21:590-6. [https://doi.org/10.1016/0735-1097\(93\)90089-J](https://doi.org/10.1016/0735-1097(93)90089-J)
28. Arlt M, Philipp A, Voelkel S, Schopka S, Husser O, Hengstenberg C, et al. Early experiences with miniaturized extracorporeal life-support in the catheterization laboratory. *Eur J Cardiothorac Surg.* 2012 Nov;42(5):858-63. <https://doi.org/10.1093/ejcts/ezs176>
29. O Taub JO, L'Hommedieu BD, Raihel SC, Vieth DG, Vieth PJ, Barner HB, et al. Extracorporeal membrane oxygenation for percutaneous coronary angioplasty in high risk patients. *ASAIO Trans.* 1989 Jul-Sep;35(3):664-6. <https://www.ncbi.nlm.nih.gov/pubmed/2597559>
30. Extracorporeal Life Support Organization. ELSO Guidelines for Adult respiratory failure. Supplement to the ELSO General Guidelines. 2013. Available from: <https://www.else.org/resources/guidelines.aspx>
31. Hemmila MR, Rowe SA, Boules TN, Miskulin J, McGillicuddy JW, Haft JW, et al. Extracorporeal life support for severe acute respiratory distress syndrome in adults. *Ann Surg.* 2004 Oct;240(4):595-605. <https://doi.org/10.1097/01.sla.0000141159.90676.2d>
32. Prankoff T, Hirschl RB, Steimle CN, Anderson HL 3rd, Bartlett RH. Mortality is directly related to the duration of mechanical ventilation before the initiation of extracorporeal life support for severe respiratory failure. *Crit Care Med.* 1997 Jan;25(1):28-32. <https://www.ncbi.nlm.nih.gov/pubmed/8989172>
33. Schmid C, Philipp A. Extracorporeal Membrane Oxygenation (ECMO). In: Schmid C, Philipp A, editors. *Guidelines for Extracorporeal Circulation.* Heidelberg: Springer Medizin; 2011. p. 84-95.
34. Schmidt M, Zogheib E, Rozé H, Repesse X, Lebreton G, Luyt CE, et al. The PRESERVE mortality risk score and analysis of long-term outcomes after extracorporeal membrane oxygenation for severe acute respiratory distress syndrome. *Intensive Care Med.* 2013 Oct;39(10):1704-13. <https://doi.org/10.1007/s00134-013-3037-2>
35. Pham T, Combes A, Rozé H, Chevret S, Mercat A, Roch A, et al; REVA Research Network. Extracorporeal membrane oxygenation for pandemic influenza A(H1N1)-induced acute respiratory distress syndrome: a cohort study and propensity-matched analysis. *Am J Respir Crit Care Med.* 2013 Feb 1;187(3):276-85. <https://doi.org/10.1164/rccm.201205-0815OC>
36. Brogan TV, Thiagarajan RR, Rycus PT, Bartlett RH, Bratton SL. Extracorporeal membrane oxygenation in adults with severe respiratory failure: a multi-center database. *Intensive Care Med.* 2009 Dec;35(12):2105-14. <https://doi.org/10.1007/s00134-009-1661-7>
37. Aubron C, Cheng AC, Pilcher D, Leong T, Magrin G, Cooper DJ, et al. Factors associated with outcomes of patients on extracorporeal membrane oxygenation support: a 5-year cohort study. *Crit Care.* 2013 Apr 18;17(2):R73. <https://doi.org/10.1186/cc12681>
38. Schmidt M, Bréchof N, Hariri S, Guiguet M, Luyt CE, Makri R, et al. Nosocomial infections in adult cardiogenic shock patients supported by venoarterial extracorporeal membrane oxygenation. *Clin Infect Dis.* 2012;55(12):1633-41. <https://doi.org/10.1093/cid/cis783>
39. Hodgson CL, Hayes K, Everard T, Nichol A, Davies AR, Bailey DJ, et al. Long-term quality of life in patients with acute respiratory distress syndrome requiring extracorporeal membrane oxygenation for refractory hypoxaemia. See comment in PubMed Commons below *Crit Care.* 2012 Oct 19;16(5):R202. <https://doi.org/10.1186/cc11811>
40. Sidebotham D, McGeorge A, McGuinness S, Edwards M, Willcox T, Beca J. Extracorporeal membrane oxygenation for treating severe cardiac and respiratory failure in adults: Part 2-technical considerations. *J Cardiothorac Vasc Anesth.* 2010 Feb;24(1):164-72. <https://doi.org/10.1053/j.jvca.2009.08.002>
41. Bartlett RH, Gattinoni L. Current status of extracorporeal life support (ECMO) for cardiopulmonary failure. *Minerva Anestesiol.* 2010;76:534-40. <https://www.ncbi.nlm.nih.gov/pubmed/20613694>
42. Peek G, Wittenstein B, Harvey C. Management of bleeding during ECLS. In: Van Meurs K, Lally KP, Peek G, et al. (eds). *ECMO in Critical Care.* Extracorporeal life support organization, Ann Arbor, 2005.
43. Cornell T, Wyrick P, Fleming G, Pasko D, Han Y, Custer J, Haft J, et al. A case series describing the use of argatroban in patients on extracorporeal circulation. *ASAIO J.* 2007 Jul-Aug;53(4):460-3. <https://doi.org/10.1097/MAT.0b013e31805c0d6c>
44. Mateen FJ, Muralidharan R, Shinohara RT, Parisi JE, Schears GJ, Wijdicks EF. Neurological injury in adults treated with extracorporeal membrane oxygenation. *Arch Neurol.* 2011;68(12):1543-9. <https://doi.org/10.1001/archneurol.2011.209>
45. Mehta A, Ibsen LM. Neurologic complications and neurodevelopmental outcome with extracorporeal life support. *World J Crit Care Med.* 2013 Nov 4;2(4):40-7. <https://doi.org/10.5492/wjccm.v2.i4.40>
46. Lewandowski K, Metz J, Deutschmann C, Preiss H, Kühlen R, Artigas A, et al. Incidence, severity, and mortality of acute respiratory failure in Berlin, Germany. *Am J Respir Crit Care Med.* 1995;151(4):1121-5. <https://doi.org/10.1164/ajrccm.151.4.7697241>
47. Australia and New Zealand Extracorporeal Membrane Oxygenation (ANZ ECMO) Influenza Investigators, Davies A, Jones D, Bailey M, Beca J, Bellomo R, Blackwell N, et al. Extracorporeal Membrane Oxygenation for 2009 Influenza A(H1N1) Acute Respiratory Distress Syndrome. *JAMA.* 2009 Nov 4;302(17):1888-95. <https://doi.org/10.1001/jama.2009.1535>
48. Peek GJ, Moore HM, Moore N, Sosnowski AW, Firmin RK. Extracorporeal membrane oxygenation for adult respiratory failure. *Chest.* 1997 Sep;112(3):759-64. <https://doi.org/10.1378/chest.112.3.759>
49. Lewandowski K, Rossaint R, Pappert D, Gerlach H, Slama KJ, Weidemann H, et al. High survival rate in 122 ARDS patients managed according to a clinical algorithm including extracorporeal membrane oxygenation. *Intensive Care Med.* 1997;23:819-35. <https://doi.org/10.1007/s001340050418>
50. Ullrich R, Lorber C, Röder G, Urak G, Faryniak B, Sladen RN, et al. Controlled airway pressure therapy, nitric oxide inhalation, prone position, and extracorporeal membrane oxygenation (ECMO) as components of an integrated approach to ARDS. *Anesthesiology.* 1999 Dec;91(6):1577-86. <https://www.ncbi.nlm.nih.gov/pubmed/10598597>
51. Rich PB, Awad SS, Kolla S, Annich G, Schreiner RJ, Hirschl RB, et al. An approach to the treatment of severe adult respiratory failure. *J Crit Care.* 1998;13:26-36. [https://doi.org/10.1016/S0883-9441\(98\)90026-0](https://doi.org/10.1016/S0883-9441(98)90026-0)
52. Kolla S, Awad SS, Rich PB, Schreiner RJ, Hirschl RB, Bartlett RH. Extracorporeal life support for 100 adult patients with severe respiratory failure. *Ann Surg.* 1997 Oct;226(4):544-64. <https://www.ncbi.nlm.nih.gov/pubmed/9351722>
53. Noah MA, Peek GJ, Finney SJ, Griffiths MJ, Harrison DA, Sadique MZ, et al. Referral to an extracorporeal membrane oxygenation center and mortality among patients with severe 2009 influenza A(H1N1). *JAMA.* 2011;306:1659-68. <https://doi.org/10.1001/jama.2011.1471>
54. Bartlett RH. Clinical Research in Acute Fatal Illness: Lessons From Extracorporeal Membrane Oxygenation. *J Intensive Care Med.* 2016;31:456-65. <https://doi.org/10.1177/088506614550278>
55. Posluszny J, Rycus PT, Bartlett RH, Engoren M, Haft JW, Lynch WR, et al; ELSO Member Centers. Outcome of Adult Respiratory Failure Patients Receiving Prolonged (≥14 Days) ECMO. *Ann Surg.* 2016;263:573-81. <https://doi.org/10.1097/SLA.0000000000001176>

56. Masetti M, Tasle M, Le Page O, Deredec R, Babatasi G, Buklas D, et al. Back from irreversibility: extracorporeal life support for prolonged cardiac arrest. *Ann Thorac Surg.* 2005;79:178-83. <https://doi.org/10.1016/j.athoracsur.2004.06.095>
57. Smedira NG, Blackstone EH. Postcardiotomy mechanical support: risk factors and outcomes. *Ann Thorac Surg.* 2001 Mar;71(3 Suppl):S60-6. [https://doi.org/10.1016/S0003-4975\(00\)02626-6](https://doi.org/10.1016/S0003-4975(00)02626-6)
58. Kelly RB, Porter PA, Meier AH, Myers JL, Thomas NJ. Duration of cardiopulmonary resuscitation before extracorporeal rescue: how long is not long enough? *ASAIO J.* 2005 Sep-Oct;51(5):665-7. <https://doi.org/10.1097/01.mat.0000171596.39362.7a>
59. Combes A, Leprince P, Luyt CE, Bonnet N, Trouillet JL, Leger P, et al. Outcomes and long-term quality-of-life of patients supported by extracorporeal membrane oxygenation for refractory cardiogenic shock. *Crit Care Med.* 2008 May;36(5):1404-11. <https://doi.org/10.1097/CCM.0b013e31816f7c77>
60. Pagani FD, Aaronson KD, Swaniker F, Bartlett RH. The use of extracorporeal life support in adult patients with primary cardiac failure as a bridge to implantable left ventricular assist device. *Ann Thorac Surg.* 2001 Mar;71(3 Suppl):S77-81. [https://doi.org/10.1016/S0003-4975\(00\)02620-5](https://doi.org/10.1016/S0003-4975(00)02620-5)
61. Kagawa E, Dote K, Kato M, Sasaki S, Nakano Y, Kajikawa, M, et al. Should we emergently revascularize occluded coronaries for cardiac arrest?: rapid-response extracorporeal membrane oxygenation and intra-arrest percutaneous coronary intervention. *Circulation.* 2012 Sep 25;126(13):1605-13. <https://doi.org/10.1161/CIRCULATIONAHA.111.067538>
62. Bednarczyk JM, White CW, Ducas RA, Golian M, Nepomuceno R, Hiebert B, et al. Resuscitative extracorporeal membrane oxygenation for in hospital cardiac arrest: a Canadian observational experience. *Resuscitation.* 2014;85:1713-9. <https://doi.org/10.1016/j.resuscitation.2014.09.026>
63. Chang CH, Chen HC, Caffrey JL, Hsu J, Lin JW, Lai MS, et al. Survival Analysis After Extracorporeal Membrane Oxygenation in Critically Ill Adults: A Nationwide Cohort Study. *Circulation.* 2016 Jun 14;133(24):2423-33. <https://doi.org/10.1161/CIRCULATIONAHA.115.019143>
64. Asami Y, Yasuda S, Morii I, Kakuchi H, Otsuka Y, Kawamura A, et al. Favourable clinical outcome in patients with cardiogenic shock due to fulminant myocarditis supported by percutaneous extracorporeal membrane oxygenation. *Eur Heart J.* 2005 Oct;26(20):2185-92. <https://doi.org/10.1093/eurheartj/ehi411>
65. Shin TG, Choi JH, Jo IJ, Sim MS, Song HG, Jeong YK, et al. Extracorporeal cardiopulmonary resuscitation in patients with inhospital cardiac arrest: A comparison with conventional cardiopulmonary resuscitation *Crit Care Med.* 2011 Jan;39(1):1-7. <https://doi.org/10.1097/CCM.0b013e3181feb339>
66. Chen YS, Lin JW, Yu HY, Ko WJ, Jerng JS, Chang WT, et al. Cardiopulmonary resuscitation with assisted extracorporeal life-support versus conventional cardiopulmonary resuscitation in adults with in-hospital cardiac arrest: an observational study and propensity analysis. *Lancet.* 2008;372:554-61. [https://doi.org/10.1016/S0140-6736\(08\)60958-7](https://doi.org/10.1016/S0140-6736(08)60958-7)