

## LAPAROSCOPIC TREATMENT OF MORGAGNI HERNIA: REPORT OF THREE CASES

Ivo Soldo<sup>1</sup>, Ivo Baća<sup>2</sup>, Marko Sever<sup>1</sup>, Ivan Zoričić<sup>1</sup>, Martin Grbavac<sup>1</sup>, Rosana Troškot Perić<sup>3</sup>,  
Zoran Čala<sup>1</sup>, Maja Karaman Ilić<sup>4</sup>, Anamaria Soldo<sup>5</sup> and Branko Bakula<sup>1</sup>

<sup>1</sup>Department of Hepatobiliary Surgery, Sveti Duh University Hospital, Zagreb, Croatia;

<sup>2</sup>Central Hospital Bremen Ost, Department of General and Trauma Surgery, Bremen, Germany;

<sup>3</sup>Department of Gastroenterology and Hepatology, <sup>4</sup>Department of Anesthesiology, Sveti Duh University Hospital, Zagreb, School of Medicine, Josip Juraj Strossmayer University of Osijek, Osijek, Croatia;

<sup>5</sup>School of Medicine, University of Mostar, Mostar, Bosnia and Herzegovina

**SUMMARY** – We report on three cases of diaphragmatic (Morgagni) hernia with different clinical presentation. It is important to consider the possibility of this rare but potentially very dangerous condition in patients with respiratory problems and pain in the upper abdomen. Before laparoscopy, two different approaches were used in diaphragmatic hernia operations (abdominal and thoracic approach). Laparoscopy has brought significant changes in the treatment of diaphragmatic hernia. It is important to stress that laparoscopic diaphragmatic surgical therapy uses stronger mesh than the mesh used to repair an inguinal hernia.

**Key words:** *Hernia, diaphragmatic; Hernias, diaphragmatic, congenital; Laparoscopy – methods*

### Introduction

Because of its location diaphragm can be considered as abdominal roof. Natural diaphragm orifices (aortal, esophageal, inferior vena cava) provide communication between abdominal and thoracic cavities. The diaphragm structure, consisting of costal, sternal, lumbar and membrane portions, can contribute to hernia development.

Diaphragmatic hernias are less common abdominal hernias. They can be acquired (posttraumatic) and congenital. Congenital defects of the diaphragm are Bodalek hernia, Morgagni hernia, central tendo defect, and diaphragmatic eventration<sup>1-3</sup>. Morgagni hernia accounts for only 2%-3% of all diaphragmatic hernias<sup>4</sup>.

Morgagni hernia was first described by Giovanni Battista Morgagni in 1769 while he was performing

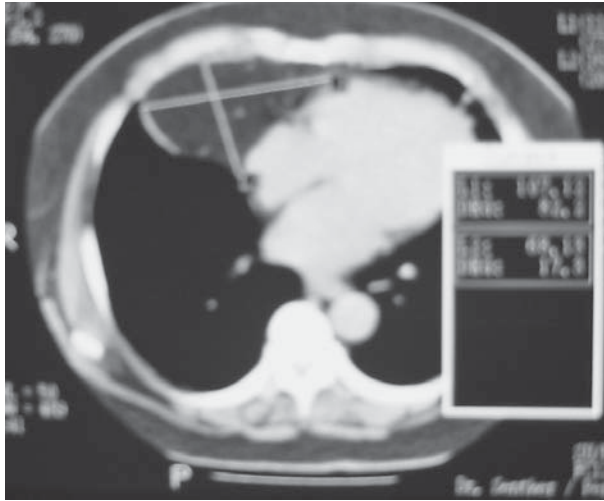
autopsy on a patient who died from head injuries<sup>5</sup>. The reason for the occurrence of this type of diaphragmatic hernia is congenital defect of the diaphragm between its sternal and costal parts. Right-sided Morgagni hernia (95%) is most common, left-sided Morgagni hernia is significantly less likely, and there are only few cases of bilateral Morgagni hernia<sup>6,7</sup>.

There are few review studies about diaphragmatic hernias. Horton *et al.*<sup>6</sup> found 128 papers between 1951 and 2008 reporting on 298 patients with diaphragmatic hernias. Of these, 72% of patients had symptoms that pointed to diaphragmatic hernia. Pulmonary complications were the most common symptom in 36% of patients. In the past, the incidence of Morgagni hernia was higher in young male patients than in female patients. The majority of Morgagni hernias were treated by thoracic approach (49%). Sixty-two percent of patients with Morgagni hernia are women with average age of 53 years. The average age of male patients is 50 years<sup>6</sup>. Most Morgagni hernias are diagnosed too late, as they are asymptomatic or present nonspecific respiratory or digestive symptoms.

Correspondence to: *Branko Bakula, MD*, Horvaćanska 164, HR-10000 Zagreb, Croatia

E-mail: bakulabranko@gmail.com

Received September 19, 2016, accepted December 14, 2016



*Fig. 1. Multi-slice computed tomography finding of Morgagni hernia, liposarcoma suspected.*

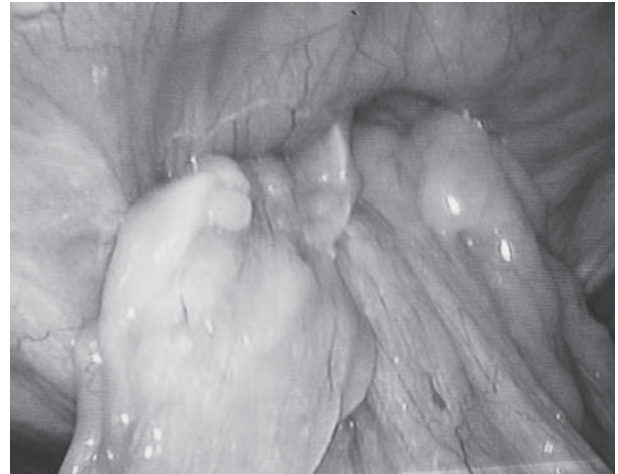
The first laparoscopic Morgagni hernia therapy was performed in 1992, and since then it has become standard therapy for Morgagni hernia. Surgeons usually use a mesh to close diaphragmatic gap (64%) without hernial sac reduction (69%)<sup>6,8-11</sup>. Laparoscopic approach has fewer complications (5%) and significantly shorter hospital stay (3 days).

We report on laparoscopic treatment of Morgagni hernia in three patients.

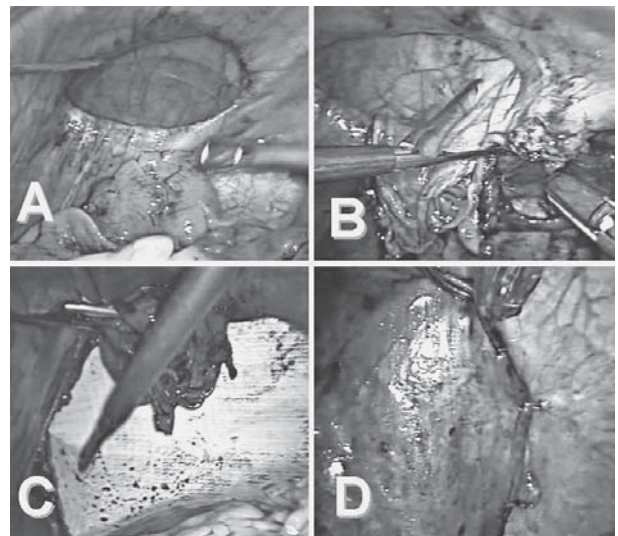
### Case Report 1

A 71-year-old male patient was admitted to our hospital due to pain in the right chest. Medical examination, laboratory findings, chest x-ray and multi-slice computed tomography (MSCT) of the thorax and abdomen were performed. MSCT indicated right chest tumor formation (liposarcoma suspected) (Fig. 1).

Abdominal surgeon suspected diaphragmatic hernia and laparoscopic exploration was proposed to the patient. After laparoscope introduction into the abdominal cavity, a defect of the right side of the diaphragm was noticed. Omentum had slipped into the right side of the chest through diaphragmatic defect (the reason why MSCT finding was suggestive of liposarcoma) (Fig 2). Omentum was gently released and pulled back to the abdominal cavity. Hernial sac was released and diaphragmatic defect was exposed. The mesh (Proceed Surgical Mesh PCDN1, Ethicon, Cincinnati, USA) was measured, adapted, placed on the



*Fig. 2. Omentum in hernial sac.*

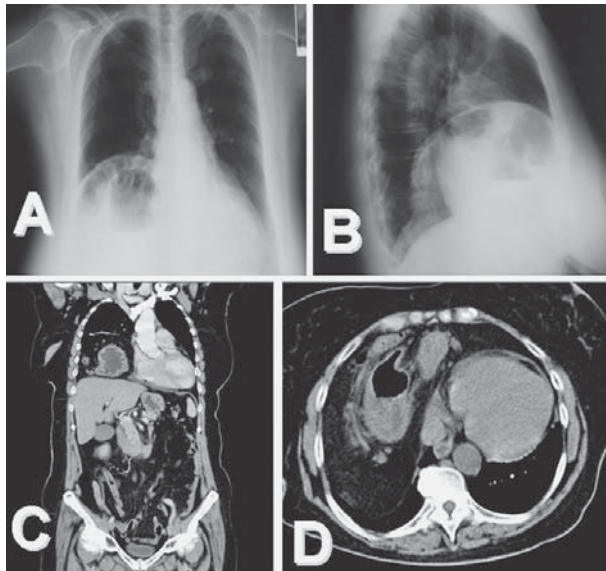


*Fig. 3. A: diaphragm defect; B: hernial sac preparation; C: mesh insertion; D: hernial sac covering the mesh.*

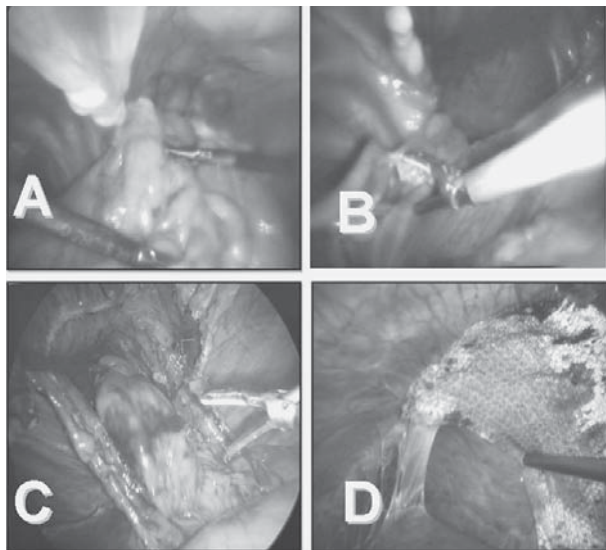
diaphragmatic defect and fixed by staples and sutures. The operation and postoperative period were free from complications (Fig. 3 A-D).

### Case Report 2

A 61-year-old woman was admitted to our emergency department with abdominal pain accompanied by nausea and vomiting persisting for 4 days. Clinical examination, routine laboratory testing, and abdominal and chest x-ray were performed. Radiologic finding showed unspecified changes in the right chest. On pro-

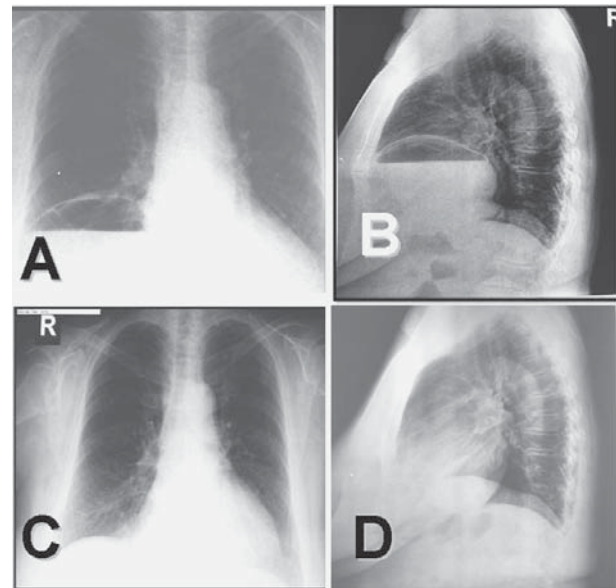


*Fig. 4. A: Chest x-ray showing unspecific changes of the right chest; B: profile chest x-ray showing tumor formation in the right chest, of unknown etiology; C and D: chest and abdominal multi-slice computed tomography showing Morgagni hernia.*

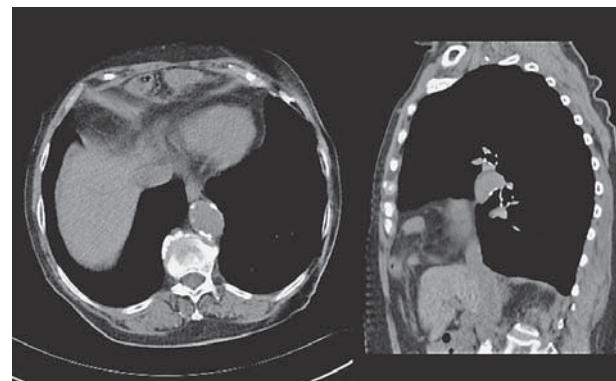

*Fig. 5. A: Contents of the sac (omentum, transverse colon and then the stomach) were released into the abdominal cavity; B: releasing the stomach into the abdominal cavity; C: hernial sac resection; D: mesh application and fixation.*

file chest x-ray, a tumor formation of unknown etiology in the right chest was suspected (Fig. 4 A-B). The patient stayed at gastroenterology department for addi-



*Fig. 6. A and B: Chest x-ray two weeks after the surgery showing cystic, oval formation in the right chest with liquid content; C and D: chest x-ray two months after the surgery, complete right lung re-expansion.*



*Fig. 7. Multi-slice computed tomography finding of Morgagni hernia.*

tional diagnostic work-up. Nasogastric tube was placed and parenteral therapy administered. Laboratory findings were within the normal range. Two attempts of gastroscopy failed. Thoracic and abdominal MSCT showed Morgagni hernia with right chest 'tumor' consisting of transverse colon, omentum and a greater part of the stomach (Fig. 4 C, D). A surgeon was consulted who proposed laparoscopic treatment. After laparoscope insertion, Morgagni hernia was confirmed. The contents of the hernia sac consisted of the omentum, transverse colon and strangulated larger part of the

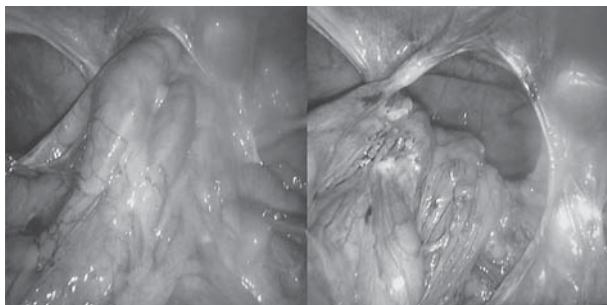


Fig. 8. Morgagni hernia with the content.

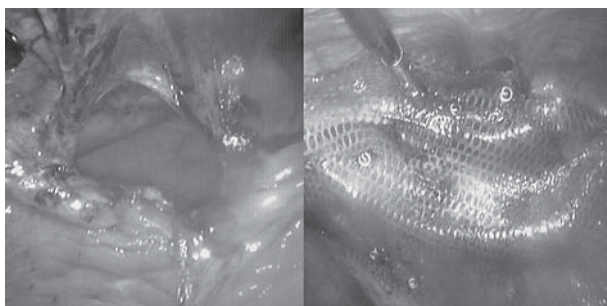


Fig. 9. Diaphragm gap of Morgagni hernia and mesh fixation.

stomach (Fig. 5A). The hernial sac and larger lipoma were resected and removed using the endobag. The size of the diaphragmatic defect was measured and the mesh (Proceed Surgical Mesh PCDN1, Ethicon, Cincinnati, USA) was placed covering defect edges by 2-3 cm. The mesh was fixed by staples (Fig. 5 B-D)

The operative procedure and postoperative period were without complications. Oral intake was initiated on postoperative day 2. On postoperative day 4, follow-up MSCT was performed showing sustained diaphragmatic line and abdominal cavity stomach position. The patient was discharged from the hospital for home care in good general condition on postoperative day 5.

The first follow up appointment was at two weeks after the surgery. The patient felt well and had no complaints. Laboratory parameters and chest x-ray were performed; x-ray findings showed a cystic, oval formation with liquid content in the right chest (Fig. 6 A, B). The patient was observed for another 2 weeks without cyst evacuation. She felt well and had normal abdominal clinical finding. Follow up chest x-ray was identical to previous finding. Thoracic surgeon suggested further follow up of the patient without intervention. As the patient clinical finding was normal, follow up ex-

amination was performed after 2 months. Chest x-ray showed complete right lung re-expansion (Fig. 6 C, D). Laboratory parameters were normal, and so was abdominal and chest clinical status.

### Case Report 3

A 76-year-old female patient was admitted to abdominal surgery department with MSCT finding of Morgagni hernia and respiratory insufficiency (Fig. 7). She had been treated for bronchitis, gastroesophageal reflux disease (GERD) and respiratory insufficiency for 10 years before Morgagni hernia was found. Laparoscopic exploration was performed and Morgagni hernia confirmed. The stomach, transverse colon, large omentum and 30 cm of small intestine were found in hernia sac (Fig. 8). Hernia sac was dissected and reduced. Composite mesh was used to close diaphragmatic gap (Fig. 9). The postoperative period was unremarkable. Respiratory insufficiency was reduced. Follow up examination at one month of the procedure showed better respiratory status, less GERD symptoms, without hernia recurrence on chest x-ray.

### Discussion

The pathophysiology of Morgagni hernia is not quite clear. Investigations suggest that these hernias can be acquired through congenital defects in the diaphragm (Larrey's space)<sup>6,12</sup>. The sequence of events implies herniation of abdominal organs through the existing diaphragmatic gap. Symptomatic Morgagni hernia cases in adults are rare and mostly described as respiratory problems or unclear abdominal pain<sup>13-16</sup>. Hernial content may be omentum, small and large intestine, or stomach<sup>6</sup>. The x-ray and ultrasound have proved to be useful in assessing diaphragmatic hernias, but computed tomography enables highest accuracy for correct diagnosis. It allows accurate assessment of anatomic relationships of organs in hernial sac and diaphragmatic gap<sup>17-20</sup>. Laparoscopic approach for solving Morgagni hernia is reasonable and better than classic abdominal or thoracic approach<sup>20-26</sup>.

In conclusion, our results show that laparoscopic treatment of diaphragmatic hernias using appropriate materials (Proceed Surgical Mesh pCDNA 1, Ethicon, Cincinnati, USA) is a successful and useful method with all advantages of minimal invasive surgery.

## References

1. Das PB, Neelaksh, Garg PK, Oswal SK, Dogra VK. Morgagni hernia: an interesting congenital defect of the diaphragm. *Indian J Chest Dis Allied Sci.* 1978;20:204-7.
2. Sinclair L, Klein BL. Congenital diaphragmatic hernia – Morgagni type. *J Emerg Med.* 1993;11:163-5.
3. Kashiwagi H, Kumagai K, Nozue M, Terada Y. Morgagni hernia treated by reduced port surgery. *Int J Surg Case Rep.* 2014;5(12):1222-4. doi:10.1016/j.ijscr.2014.11.047
4. Harrington SW. Clinical manifestations and surgical treatment of congenital types of diaphragmatic hernia. *Rev Gastroenterol.* 1951;18(4):243-56.
5. Morgagni GB. In: Millar A, Cardell T, editors. *Seats and Causes of Diseases.* Vol. 3. London:1769:205.
6. Horton JD, Hofmann LJ, Hetz SP. Presentation and management of Morgagni hernias in adults: a review of 298 cases, *Surg Endosc.* 2008;22:1413-20. doi: 10.1007/s00464-008-9754-x
7. Aabye R. Diaphragmatic hernia: right-sided sub-costosternal type in a patient with large gibbus. *Acta Chir Scand.* 1954;108:6-12.
8. Ackroyd R, Watson DI. Laparoscopic repair of a hernia of Morgagni using a suture technique. *J R Coll Surg Edinb.* 2000;45:400-2.
9. Akamine S, Kawahara K, Nakamura A, Takahashi T, Yamamoto S, Ayabe H, *et al.* Successful utilization of a video-assisted thoracic approach to repair Morgagni's hernia: report of a case. *Surg Today.* 1995;25(7):654-6.
10. Hussong RL Jr, Landreneau RJ, Cole FH Jr. Diagnosis and repair of a Morgagni hernia with video-assisted thoracic surgery. *Ann Thorac Surg.* 1997;63:1474-5.
11. Sirmali M, Türüt H, Gezer S, Findik G, Kaya S, Tastepe Y, *et al.* Clinical and radiologic evaluation of foramen of Morgagni hernias and the transthoracic approach. *World J Surg.* 2005;29:1520-4.
12. Thoman DS, Hui T, Phillips EH. Laparoscopic diaphragmatic hernia repair. *Surg Endosc.* 2002;16:1345-9.
13. Bhasin DK, Nagi B, Gupta NM, Singh K. Chronic intermittent gastric volvulus within the foramen of Morgagni. *Am J Gastroenterol.* 1989;84:1106-8.
14. Chin EF, Duchesne ER. The parasternal defect. *Thorax.* 1955;10:214-9.
15. Eren S, Gumus H, Okur A. A rare cause of intestinal obstruction in the adult: Morgagni's hernia. *Hernia.* 2003;7:97-9.
16. Ninos A, Pierrakakis S, Stavrianos V, Papaioanou G, Ajiazi A, Iordanou Ch. Bilateral congenital anterior diaphragmatic hernia: a case report. *Hernia.* 2006;10(6):525-7.
17. Sutro WH, King SJ. Computed tomography of Morgagni hernia. *N Y State J Med.* 1987;87:520-1.
18. Bufkin WJ. Chest discomfort and abnormal chest radiograph. *Proc Baylor Univ.* 2001;14:183-4.
19. Yamashita K, Tsunoda T. Three-dimensional computer images of Morgagni hernia. *Am J Surg.* 2004;187:109-10.
20. Collie DA, Turnbull CM, Shaw TR, Price WH. Case report: MRI appearances of left-sided Morgagni hernia containing liver. *Br J Radiol.* 1996;69:278-80.
21. Ikarashi M, Matsuda M, Murayama I, Fujii M, Takayama T. Laparoscopic repair of Morgagni hernia with composite mesh in an elderly woman: report of a case. *Asian J Endosc Surg.* 2015;May 8(2):216-8. doi: 10.1111/ases.12161
22. Shah RS, Sharma PC, Bhandarkar DS. Laparoscopic repair of Morgagni's hernia: an innovative approach. *J Indian Assoc Pediatr Surg.* 2015 Apr-Jun;20(2):68-71. doi: 10.4103/0971-9261.151547
23. Kashiwagi H, Kumagai K, Nozue M, Terada Y. Morgagni hernia treated by reduced port surgery. *Int J Surg Case Rep.* 2014;5(12):1222-4. doi: 10.1016/j.ijscr.2014.11.047
24. Kaida T, Ikeda A, Shimoda H, Sako H, Uchida H, Wada M, *et al.* Laparoscopic mesh repair of a Morgagni hernia using the double-crown technique: a case study. *Asian J Endosc Surg.* 2014 Nov;7(4):323-6. doi: 10.1111/ases.12120
25. Aydin Y, Altuntas B, Ulas AB, Daharlı C, Eroglu A. Morgagni hernia: transabdominal or transthoracic approach. *Acta Chir Belg.* 2014 Mar-Apr;114(2):131-5.
26. Abraham V, Myla Y, Verghese S, Chandran BS. Morgagni-Larrey hernia – a review of 20 cases. *Indian J Surg.* 2012 Oct;74(5):391-5. doi: 10.1007/s12262-012-0431-x

## Sažetak

## LAPAROSKOPSKI PRISTUP U LIJEČENJU MORGAGNIJEVE HERNIJE: TRI PRIKAZA SLUČAJA

*I. Soldo, I. Baća, M. Sever, I. Zoričić, M. Grbovac, R. Troskot Perić, Z. Čala, M. Karaman Ilić, A. Soldo i B. Bakula*

Prikazuju se tri bolesnika s dijafragmalnom, Morgagnijevom hernijom, ali s različitim kliničkim slikama. Važno je posumnjati na ovu rijetku, ali potencijalno vrlo opasnu bolest kod bolesnika s respiracijskim problemima i bolovima u gornjem dijelu trbuha. Prije uvođenja laparoskopije postojala su dva otvorena pristupa liječenju dijafragmalnih hernija, abdominalni i torakalni. Laparoskopija je donijela znatne promjene u liječenju dijafragmalne kile. Treba naglasiti da se u laparoskopskom pristupu koriste čvršće mrežice za pokrivanje kilnog otvora nego za preponske kile.

Ključne riječi: *Hernija, dijafragmalna; Hernije, dijafragmalne, prirođene; Laparoskopija – metode*