

# EXTENSIVE DEEP VENOUS THROMBOSIS IN A YOUNG MALE PATIENT AS THE FIRST MANIFESTATION OF A RARE VENOUS ANOMALY – INFERIOR VENA CAVA DUPLICATION: CASE REPORT

Dražen Pulanić<sup>1,2,3</sup>, Ena Ranković<sup>1</sup>, Marijo Vodanović<sup>1</sup>, Mario Lušić<sup>4</sup>, Ana Boban<sup>1,2</sup>,  
Silva Zupančić Šalek<sup>1,2,3</sup> and Damir Nemet<sup>1,2,3</sup>

<sup>1</sup>Division of Hematology, Department of Internal Medicine, Zagreb University Hospital Center;  
<sup>2</sup>School of Medicine, University of Zagreb, Zagreb; <sup>3</sup>School of Medicine, Josip Juraj Strossmayer  
University of Osijek, Osijek; <sup>4</sup>Department of Diagnostic and Interventional Radiology,  
Zagreb University Hospital Center, Zagreb, Croatia

**SUMMARY** – Although venous thromboembolism (VTE) including deep venous thrombosis (DVT) and pulmonary embolism is a major health problem in the world, it is an infrequent disease among young people. It is always mandatory to look at the underlying conditions for VTE, and in young patients, inherited prothrombotic factors should also be evaluated, especially in case of unprovoked VTE. Anomalies of inferior vena cava (IVC) are very rare in the general population. In this case report we describe rare occurrence of extensive DVT in a young male patient with rare anomaly of IVC – duplication of IVC – as a predisposition factor for DVT. Physicians need to be reminded of the IVC anomalies that should be considered in young patients with idiopathic DVT of lower extremity, which may require extended anticoagulant treatment.

**Key words:** *Venous thromboembolism; Venous thrombosis; Vena cava, inferior – abnormalities; Anticoagulants – therapeutic use; Case reports; Croatia*

## Introduction

Venous thromboembolism (VTE), including deep venous thrombosis (DVT) and pulmonary embolism (PE), is a frequent and important health problem in the world, as well as in Croatia, with estimated incidence between 1 and 2 *per* 1000 individuals *per* year<sup>1-8</sup>. VTE is a multicausal disease with many interactions between different acquired (immobilization, surgery, trauma, cancer, autoimmune disorders, pregnancy, oral contraceptive use, long distance airplane flight, etc.) and inherited prothrombotic factors (FV Leiden and FII 20210A mutations, deficiencies of protein C, S

and antithrombin, and elevations of procoagulant factors)<sup>8</sup>. Although it is in general a frequent disease, VTE is rare among young people; the incidence of VTE is less than 5 first-time VTE *per* 100,000 *per* year among people younger than 15 years but increases sharply to 450-600 *per* 100,000 *per* year among people aged 80 years or older<sup>1,3,5,8</sup>. In the most recent study of VTE incidence in the Croatian population, just 8.9% of all patients with newly diagnosed VTE were patients aged 45 years or younger<sup>8</sup>.

It is mandatory to look at the underlying main cause responsible for VTE occurrence. In younger patients, inherited thrombophilia screening should also be considered, especially if VTE occurs recurrently or without obvious acquired reason<sup>9</sup>.

Congenital anomalies of the inferior vena cava (IVC) such as hypoplasia, duplication of the IVC or

Correspondence to: *Assist. Prof. Dražen Pulanić, MD, PhD, Zagreb University Hospital Center, Kišpatićeva 12, HR-10000 Zagreb, Croatia*

E-mail: [dpulanic@yahoo.com](mailto:dpulanic@yahoo.com)

Received January 25, 2016, accepted August 24, 2016

the absence of the infrahepatic IVC are very rare in the general population, described in a proportion of 0.2%–1%<sup>10–12</sup>. These anomalies are usually asymptomatic and mostly an incidental finding. However, lower extremity ulcer with or without prior DVT might be frequent in later stages of this condition. In addition, in patients younger than 30 years presenting with DVT, the incidence of IVC anomalies increases to up to 5%<sup>13,14</sup>.

In this case report, we describe the unusual occurrence of extensive DVT in a young male patient, in association with duplicated IVC as a risk factor in the development of DVT.

### Case Report

A 31-year-old Caucasian male with no significant previous medical history was admitted to the hospital through the emergency service because of the color duplex ultrasound (US) confirmed extensive DVT of the left popliteal, femoral superficial and common femoral vein. Physical examination revealed a pitting edema of the left leg with tenderness, a significant size difference between circumferences of his legs, and normal arterial pulsations in both lower extremities. The rest of physical examination was normal. He subsequently started receiving low molecular weight heparin (LMWH) together with warfarin.

The patient denied recent immobilization, trauma, surgery or any other recent serious medical condition. He denied recent distant travel. The only known predisposing prothrombotic risk factor was tobacco use; he smoked about 20 cigarettes *per* day. His personal and family history of clotting disorders or peripheral vascular disease was negative. Therefore, the following extended diagnostic work-up was performed to rule out any underlying condition.

Due to nonspecific infiltration on chest radiography and in order to exclude a malignant disease, multislice computed tomography (MSCT) of the neck, chest, abdomen and pelvis with intravenous contrast was performed. The aforementioned imaging method showed duplication of the IVC. Both IVCs ran parallel to each other bordering the aorta, with the left-sided IVC ascending to the level of the left renal vein. The left IVC, the medial part of the left renal vein, the proximal part of the left suprarenal vein, the left common and external iliac vein, and also the left common femoral vein were found to be clotted (Fig. 1 a, b, c).

There was no other significant pathologic finding on MSCT scan. A vascular surgeon excluded angiosurgical treatment. Further work-up was performed. Esophagogastroduodenoscopy revealed a hiatal hernia, reflux esophagitis and chronic gastritis. Doppler US of the testicles excluded focal lesions or pathologic hypervascularization, and US of the neck and thyroid gland showed no pathologic findings either. Electrocardiogram and cardiac US were normal. Serum tumor markers (AFP, CEA, CA 19-9, PSA, NSE and CYFRA) were within the normal range. On the other hand, due to high blood glucose levels (9.2 mmol/L, normal 4.4–6.4 mmol/L), the patient underwent full endocrine work-up and was diagnosed with diabetes type 2. Also, serum cholesterol (5.2 mmol/L, normal <5 mmol/L) and low-density lipoprotein (LDL) (3.08 mmol/L, normal <3 mmol/L) concentrations were slightly elevated. At first, changes in diet and lifestyle were recommended, but later during the follow up period he started with oral therapy for diabetes (vidagliptin), with good control of glucose level.

In addition, thrombophilia work-up revealed a high level of homocysteine (16.2 µmol/L, normal <13.8 µmol/L) in the blood. Other thrombophilia markers such as protein C, protein S and antithrombin activities were normal. Polymerase chain reaction (PCR) analysis of Factor V Leiden, FII 20210A, MTHFR 677, and JAK2 V617F mutations did not show any alterations. Lupus anticoagulant and anticardiolipin antibodies were negative. Other routine laboratory tests for the most common autoimmune disorders were also negative. The level of beta2-microglobulin was also within the normal range. Control MSCT venography performed 11 days after the first MSCT revealed improvement with partial regression of the clot (Fig. 2).

The patient was kept on therapeutic dose of LMWH because therapeutic INR range could not be achieved despite high doses of warfarin (15 mg of warfarin *per* day). He also received folic acid and B-group vitamins because of hyperhomocysteinemia, and was recommended to take compressive stockings. He was followed-up in the outpatient unit regularly after discharge from the hospital, with further clinical improvement and partial recanalization of the veins of the left leg on control color Doppler US, without signs of postthrombotic syndrome or leg ulcer. He did not have any bleeding side effects of anticoagulant therapy

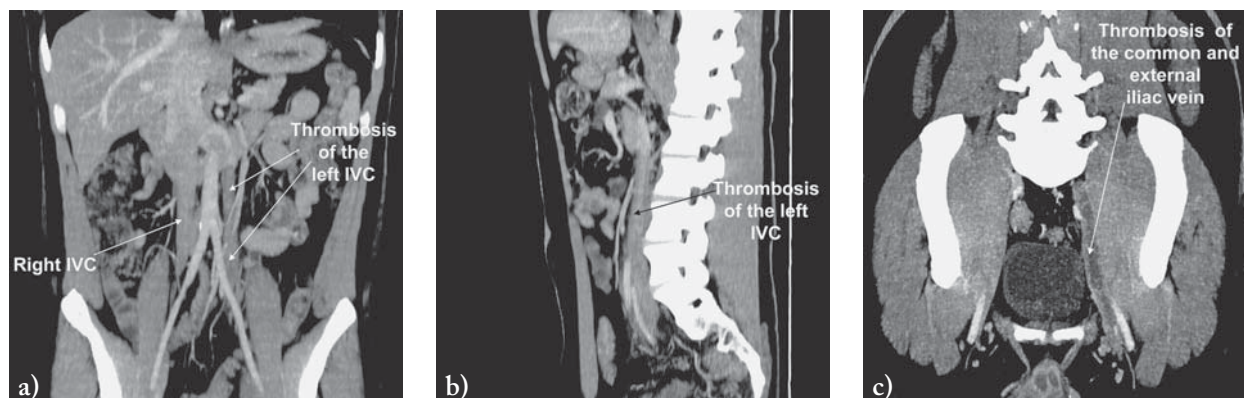


Fig. 1. (a) and b) Thrombosis of the left inferior vena cava (IVC); (c) thrombosis of the common and external iliac vein.

with LMWH during 2-year follow up, with excellent compliance to therapy. The homocysteine level normalized and D-dimers were continuously negative during the follow up period. However, because of the IVC anomaly as an irreversible prothrombotic risk factor, he was recommended to continue with extended anticoagulation therapy. Other anticoagulant modalities were discussed with the patient, but it was decided for now to continue with therapeutic doses of LMWH.

## Discussion

This case report describes extensive DVT in a young male patient, in association with a rare anomaly of duplicated IVC. Although it is possible that lifelong asymptomatic IVC malformations can occur<sup>15</sup>, Ruggeri *et al.* state that congenital anomalies of the IVC might be a risk factor for DVT<sup>14</sup>, and some authors believe that IVC malformation alone can provoke DVT, presumably by favoring venous stasis<sup>16,17</sup>.

Anomalies of IVC are rare in the general population, and duplications of the IVC are a very rare finding in radiologic studies, with an incidence of 0.2% to 3.0%<sup>18</sup>. The earliest reported case of duplication of the IVC was reported in 1912<sup>19</sup>, the majority of later cases were diagnosed accidentally by imaging for other reasons<sup>18</sup>, but during the last 100 years, there are just a few reported cases involving IVC duplication in association with DVT<sup>10,15,17,18,20</sup>.

In general, diagnosis of IVC anomaly was in most of the cases established by angio-computer tomography (angio-CT)<sup>5,21,22</sup>, and angio-CT and angio-mag-

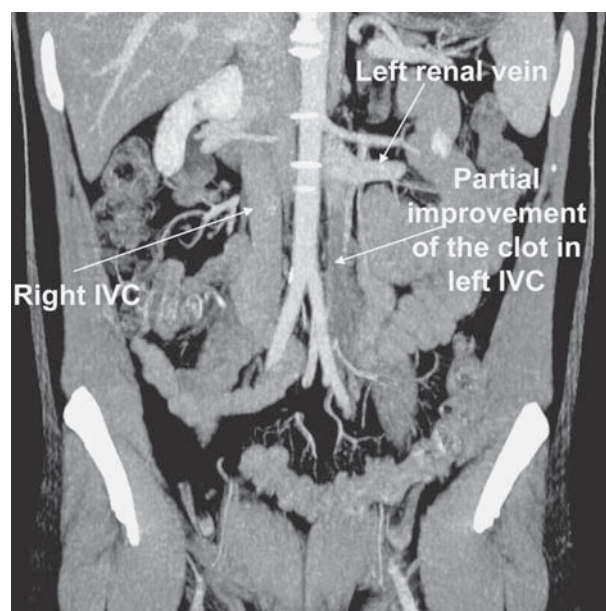


Fig. 2. Partial improvement of the clot in the left inferior vena cava (IVC).

netic resonance imaging (angio-MRI) are the imaging methods that can provide the diagnosis<sup>14,16,22</sup>. US is less used for detecting IVC anomalies and, according to some authors, the usefulness of US in the diagnosis of IVC anomalies is limited<sup>23,24</sup>, although others suggest US as the initial evaluation of IVC anomaly, and angio-CT or angio-MRI for confirmation of the diagnosis of IVC anomaly<sup>22</sup>.

Currently there are no precise guidelines available for the use of anticoagulation therapy in young people who develop VTE in association with a congenital IVC anomaly due to the inadequate number of pa-

tients with these anomalies and the lack of studies of VTE in such circumstances. Apparently, the most appropriate approach to treatment is extended anticoagulation because of the presence of an irreversible risk factor for development of VTE. The possibility of recurrent VTE is high in these patients when anticoagulation treatment is stopped<sup>17</sup>. Our case report is the first one with LMWH as extended anticoagulant therapy in a patient with IVC duplication and extensive DVT. Our patient was maintained on LMWH in therapeutic doses because he could not reach therapeutic INR even with high doses of warfarin and had extensive DVT requiring full anticoagulant treatment.

Studies assessing the potential complications, efficacy and safety of prolonged LMWH use were designed in different populations, such as cancer patients, pregnancy, and other<sup>25-34</sup>. Those studies addressed the possible side effects of extended LMWH use, such as bleeding and thrombocytopenia, and showed a low risk of major bleeding, rare heparin-induced thrombocytopenia, and infrequent allergic and skin reactions<sup>25-34</sup>. Transient elevations of aminotransferases may occur<sup>34</sup>, while an increased risk of fractures and osteoporosis is less clear<sup>32-34</sup>. For example, a systematic review and meta-analysis showed that the use of LMWH for 3-6 months did not increase the risk of fractures compared to unfractionated heparin or oral vitamin K antagonists (VKA), but longer exposure for up to 24 months was associated with a decrease in bone mineral density<sup>33</sup>. Another concern was patient compliance with daily subcutaneous administration of LMWH. However, published evidence shows that patient acceptance of LMWH is high<sup>25,35-36</sup>.

Regarding LMWH efficacy, in 11 trials conducted in different patient populations, LMWH was as effective as VKA in preventing recurrent VTE, and no consistent differences in bleeding complications were observed during long-term treatment<sup>37</sup>. Several studies showed that in patients with cancer, VTE recurrence was significantly reduced with LMWH compared to VKA<sup>25,37</sup>. Even in the newest and updated CHEST Antithrombotic Guideline published in 2016, for VTE and cancer, LMWH is suggested as long-term anticoagulant therapy over VKA or novel oral anticoagulants (NOAC – dabigatran, rivaroxaban, apixaban, and edoxaban)<sup>38</sup>. Moreover, for recurrent VTE on a non-LMWH anticoagulant, LMWH is suggested, and for recurrent VTE on LMWH, increased dose of

LMWH is suggested<sup>38</sup>. Therefore, LMWH is very effective anticoagulant option with reasonably low side effects.

However, other anticoagulant modalities were also discussed with our patient, including novel oral anticoagulant drugs (NOAC). Literature data on the usage of NOAC in such or similar settings are still very limited. Reviewing the literature, we found just one published case report describing a patient with IVC atresia who developed DVT and was discharged home using NOAC (rivaroxaban), but after catheter-directed thrombolysis and mechanical thrombectomy<sup>39</sup>. Therefore, it was decided for our patient to continue for now with therapeutic doses of LMWH, which he was taking with clinical and radiological (color Doppler US) improvement, and without any bleeding problems.

To conclude, our case report emphasizes that physicians need to be reminded about anomalies of the IVC, which should be considered and thoroughly investigated in young patients with idiopathic lower extremity DVT. Such anomalies of IVC may influence decision-making in patients who develop VTE with the need for extended anticoagulant treatment.

## References

1. Anderson FA Jr, Wheeler HB, Goldberg RJ, Hosmer DW, Patwardhan NA, Jovanovic B, *et al.* A population-based perspective of the hospital incidence and case-fatality rates of deep vein thrombosis and pulmonary embolism. The Worcester DVT Study. *Arch Intern Med.* 1991;151:933-8. doi:10.1001/archinte.1991.00400050081016
2. Kniffen WD Jr, Baron JA, Barrett J, Birkmeyer JD, Anderson FA Jr. The epidemiology of diagnosed pulmonary embolism and deep venous thrombosis in the elderly. *Arch Intern Med.* 1994;154:861-6. doi: 10.1001/archinte.1994.00420080053005
3. Silverstein MD, Heit JA, Mohr DN, Petterson TM, O'Fallon WM, Melton 3<sup>rd</sup> LJ. Trends in the incidence of deep vein thrombosis and pulmonary embolism: a 25-year population-based cohort study. *Arch Intern Med.* 1998;158:585-93. doi: 10.1001/archinte.158.6.585
4. Heit JA, Silverstein MD, Mohr DN, Petterson TM, Lohse CM, O'Fallon WM, *et al.* The epidemiology of venous thromboembolism in the community. *Thromb Haemost.* 2001;86:452-63.
5. White R. The epidemiology of venous thromboembolism. *Circulation.* 2003;107(Suppl 1):I4-8. <https://doi.org/10.1161/01.CIR.0000078468.11849.66>
6. Naess IA, Christiansen SC, Romundstad P, Cannegieter SC, Rosendaal FR, Hammerstrøm J. Incidence and mortality of ve-

- nous thrombosis: a population-based study. *J Thromb Haemost.* 2007;5(4):692-9. doi: 10.1111/j.1538-7836.2007.02450.x
7. Cushman M, Tsai AW, White RH, Heckbert SR, Rosamond WD, Enright P, *et al.* Deep vein thrombosis and pulmonary embolism in two cohorts: the longitudinal investigation of thromboembolism etiology. *Am J Med.* 2004;117:19-25. <https://doi.org/10.1016/j.amjmed.2004.01.018>
  8. Pulanić D, Gverić-Krečak V, Nemet-Lojan Z, Holik H, Coha B, Babok-Flegarić R, *et al.* Venous thromboembolism in Croatia – Croatian Cooperative Group for Hematologic Diseases (CROHEM) study. *Croat Med J.* 2015;56(6):550-7. doi: 10.3325/cmj.2015.56.550.
  9. Pulanić D, Zupančić Šalek S, Labar B. Thrombophilia-inherited and acquired susceptibility to thrombosis. *Lijec Vjesn.* 2009;131(7-8):236-7. (in Croatian)
  10. Chee YL, Culligan DJ, Watson HG. Inferior vena cava malformation as a risk factor for deep venous thrombosis in the young. *Br J Haematol.* 2001;114:878-80. doi: 10.1046/j.1365-2141.2001.03025.x
  11. Sakellaris G, Tilemis S, Papakonstantinou O, Bitsori M, Tsetis D, Charissis G. Deep venous thrombosis in a child associated with an abnormal inferior vena cava. *Acta Paediatr.* 2005;94:242-4.
  12. Sitwala PS, Ladia VM, Brahmabhatt PB, Jain V, Bajaj K. Inferior vena cava anomaly: a risk for deep vein thrombosis. *North Am J Med Sci.* 2014;6:601-3. doi: 10.4103/1947-2714.145486
  13. D'Aloia A, Faggiano P, Fiorina C, Vizzardi E, Bontempi L, Graziolo L, *et al.* Absence of inferior vena cava as a rare cause of deep venous thrombosis complicated by liver and lung embolism. *Int J Cardiol.* 2003;88:327-9.
  14. Ruggeri M, Tosoletto A, Castaman G, Rodeghiero F. Congenital absence of the inferior vena cava: a rare risk factor for idiopathic deep-vein thrombosis. *Lancet.* 2001;357:441. [https://doi.org/10.1016/S0140-6736\(00\)04010-1](https://doi.org/10.1016/S0140-6736(00)04010-1).
  15. Gayer G, Luboshitz J, Hertz M, Zissin R, Thaler M, Lubetsky A, *et al.* Congenital anomalies of the inferior vena cava revealed on CT in patients with deep vein thrombosis. *Am J Roentgenol.* 2003;180:729-32. doi: 10.2214/ajr.180.3.1800729
  16. Obernosterer A, Aschauer M, Schnedl W, Lipp RW. Anomalies of the inferior vena cava in patients with iliac venous thrombosis. *Ann Intern Med.* 2002;136:37-41. doi: 10.7326/0003-4819-136-1-20021010-00009
  17. Milani C, Constantinou M, Berz D, Butera JN, Colvin GA. Left sided vena cava duplication and venous thromboembolism. Case report and review of literature. *J Hematol Oncol.* 2008;1:24-8. doi: 10.1186/1756-8722-1-24
  18. Tamizifar B, Parisa S, Zadeh MR. Duplication of the inferior vena cava and thrombosis: a rare case. *J Res Med Sci.* 2013;18(10):911-3.
  19. Givens MH. Duplication of the inferior vena cava in man. *Anatomical Record.* 1912;6:475-86.
  20. Anne N, Pallapothu R, Holmes R, Johnson MD. Inferior vena cava duplication and deep venous thrombosis: case report and review of literature. *Ann Vasc Surg.* 2005;19:740-3. doi: <http://dx.doi.org/10.1007/s10016-005-5674-6>
  21. Malaki M, Willis AP, Jones RG. Congenital anomalies of the inferior vena cava. *Clin Radiol.* 2012;67:165-71. doi: 10.1016/j.crad.2011.08.006.
  22. Pop S, Iulianu O. Anomalies of the inferior vena cava in patients with deep venous thrombosis. Pictorial essay. *Med Ultrason.* 2012;14(1):53-9.
  23. Lambert M, Marboeuf P, Midulla M, Trillot N, Beregi JP, Mounier-Vehier C, *et al.* Inferior vena cava agenesis and deep vein thrombosis: 10 patients and review of the literature. *Vasc Med.* 2010;15:451-9. doi: 10.1177/1358863X10391355.
  24. O'Connor DB, O'Brien N, Khani T, Sheehan S. Superficial and deep vein thrombosis associated with congenital absence of the infrahepatic inferior vena cava in a young male patient. *Ann Vasc Surg.* 2011;25:697.e1-4. doi: 10.1016/j.avsg.2011.02.027.
  25. Lee AY, Levine MN, Baker RI, Bowden C, Kakkar AK, Prins M, *et al.* Low-molecular-weight heparin *versus* a coumarin for the prevention of recurrent venous thromboembolism in patients with cancer. *N Engl J Med.* 2003;349:146-53. doi: [full/10.1056/NEJMoa025313](http://full/10.1056/NEJMoa025313)
  26. Meyer G, Marjanovic Z, Valcke J, Lorcerie B, Gruel Y, Solal-Celigny P, *et al.* Comparison of low-molecular weight heparin and warfarin for the secondary prevention of venous thromboembolism in patients with cancer: a randomized controlled study. *Arch Intern Med.* 2002;162:1729-35. doi:10.1001/archinte.162.15.1729
  27. Iorio A, Guercini F, Pini M. Low-molecular-weight heparin for the long term treatment of symptomatic venous thromboembolism: meta-analysis of the randomized comparisons with oral anticoagulants. *J Thromb Haemost.* 2003;1:1906-13. doi:10.1046/j.1538-7836.2003.00364.x/pdf
  28. Kher A, Samama MM. Primary and secondary prophylaxis of venous thromboembolism with low-molecular-weight heparins: prolonged thromboprophylaxis, an alternative to vitamin K antagonists. *J Thromb Haemost.* 2005;3:473-81. doi: 10.1111/j.1538-7836.2005.01180.x
  29. Luk C, Wells PS, Anderson D, Kovacs MJ. Extended outpatient therapy with low molecular weight heparin for the treatment of recurrent venous thromboembolism despite warfarin therapy. *Am J Med.* 2001;111:270-3.
  30. Greer IA, Nelson-Piercy C. Low-molecular-weight heparins for thromboprophylaxis and treatment of venous thromboembolism in pregnancy: a systematic review of safety and efficacy. *Blood.* 2005;106:401-7. doi: <https://doi.org/10.1182/blood-2005-02-0626>
  31. Rodger MA, Hague WM, Kingdom J, Kahn SR, Karovitch A, Sermer M, *et al.* Antepartum dalteparin *versus* no antepartum dalteparin for the prevention of pregnancy complications in pregnant women with thrombophilia (TIPPS): a multinational open-label randomised trial. *Lancet.* 2014;384:1673-83. doi: 10.1016/S0140-6736(14)60793-5

32. Lefkou E, Khamashta M, Hampson G, Hunt BJ. Review: Low-molecular weight heparin-induced osteoporosis and osteoporotic fractures: a myth or an existing entity? *Lupus*. 2010;19:3-12. doi: 10.1177/0961203309353171
33. Gajic-Veljanoski O, Phua CW, Shah PS, Cheung AM. Effects of long-term low-molecular-weight heparin on fractures and bone density in non-pregnant adults: a systematic review with meta-analysis. *J Gen Intern Med*. 2016;31(8):947-57. doi: 10.1007/s11606-016-3603-8. Epub 2016 Feb 19
34. Bergqvist D. Low molecular weight heparins (Review). *J Intern Med*. 1996;240:63-72. doi:10.1046/j.1365-2796.1996.494834000.x/
35. Hull RD, Pineo GF, Brant R, Liang J, Cook R, Solymoss S, *et al.* Home therapy of venous thrombosis with long-term LMWH *versus* usual care: patient satisfaction and post-thrombotic syndrome. *Am J Med*. 2009;122:762-9. doi: 10.1016/j.amjmed.2008.12.023
36. Noble S, Finlay I. Is long-term low-molecular-weight heparin acceptable to palliative care patients in the treatment of cancer related venous thromboembolism? A qualitative study. *Palliat Med*. 2005;19:197-201. doi: 10.1191/0269216305pm1008oa
37. Hull RD, Townshend G. Long-term treatment of deep-vein thrombosis with low-molecular-weight heparin: an update of the evidence. *Thromb Haemost*. 2013;110(1):14-22. doi: 10.1160/TH12-12-0931
38. Kearon C, Akl EA, Ornelas J, Blaivas A, Jimenez D, Bounameaux H, *et al.* Antithrombotic therapy for VTE disease: CHEST Guideline and Expert Panel Report. *Chest*. 2016;149(2):315-52. doi: 10.1016/j.chest.2015.11.026
39. Koppisetty S, Smith AG, Dhillon RK. Incidental finding of inferior vena cava atresia presenting with deep venous thrombosis following physical exertion. *Case Rep Emerg Med*. 2015;2015:146304. Published online 2015 November 10. doi: 10.1155/2015/146304

#### Sažetak

### OPSEŽNA DUBOKA VENSKA TROMBOZA U MLADOG BOLESNIKA KAO PRVA MANIFESTACIJA RIJETKE VENSKE ANOMALIJE – DVOSTRUKE DONJE ŠUPLJE VENE: PRIKAZ SLUČAJA

*D. Pulanić, E. Ranković, M. Vodanović, M. Lušić, A. Boban, S. Zupančić Šalek i D. Nemet*

Iako su venske tromboembolije (VTE) koje uključuju duboku vensku trombozu (DVT) i plućnu emboliju značajan zdravstveni problem u svijetu, one su rijetke bolesti u mladih osoba. Uvijek je potrebno ispitati uzroke koji su doveli do nastanka VTE, a u mladih bolesnika potrebno je također evaluirati i nasljedne protrombotske čimbenike, osobito kod nastanka neprovocirane VTE. Anomalije donje šuplje vene su vrlo rijetke u općoj populaciji. U ovom prikazu slučaja opisujemo rijedak slučaj mladog bolesnika s opsežnom DVT i rijetkom anomalijom donje šuplje vene – dvostrukom donjom šupljom venom – kao čimbenikom rizika za nastanak DVT. Potrebno je podsjetiti liječnike na postojanje anomalija donje šuplje vene koje treba razmotriti u mladih bolesnika s idiopatskom DVT donjih ekstremiteta, što može zahtijevati dugotrajno antikoagulantno liječenje.

Ključne riječi: *Venska tromboembolija; Venska tromboza; Šuplja vena, donja – nenormalnosti; Antikoagulansi – terapijska primjena; Prikazi slučaja; Hrvatska*