

Rhonan Ferreira Silva^{1,5}, Fernando Fortes Picoli^{1,5}, Tessa de Lucena Botelho², Roberta Gomes Resende³, Ademir Franco⁴

Forenzička identifikacija raspadnutih humanih ostataka usporedbom prijesmrtnih i poslijesmrtnih CT prikaza frontalnih sinusa: prikaz slučaja

Forensic Identification of Decomposed Human Body through Comparison between Ante-Mortem and Post-Mortem CT Images of Frontal Sinuses: Case Report

¹ Stomatološki fakultet – Zavod za forenzičku stomatologiju Federalnog sveučilišta, Goiás, Brazil
Forensic Dentistry, Federal University of Goiás, Brazil

² Stomatološki fakultet – Zavod za maksilofacijalnu radiologiju Federalnog sveučilišta Goiás, Brazil
Maxillofacial Radiology, Federal University of Goiás, Brazil

³ Brazilska stomatološka udruga – Ogranak za maksilofacijalnu radiologiju
Maxillofacial Radiology, Brazilian Dental Association – State of Goiás, Brazil

⁴ Stomatološki fakultet – Zavod za forenzičku stomatologiju Katoličkog sveučilišta, Leuven, Belgija
Forensic Dentistry, Katholieke Universiteit Leuven, Belgium

⁵ Forenzička antropologija Policijske akademije, Goiás, Brazil
Forensic Anthropology, Scientific Police of Goiás, Brazil

Sažetak

Svrha: Izvijestiti o slučaju pozitivne identifikacije raspadnutog tijela nakon usporedbe prijesmrtnih (ante mortem - AM) i poslijesmrtnih (post mortem - PM) prikaza kompjutorizirane tomografije frontalnih sinusa. **Prikaz slučaja:** Nepoznato tijelo u visokom stupnju raspadanja, u dobi od 30 do 40 godina, pronađeno je u šumskom području Brazila. Dentalnom autopsijom otkrivena je djelomična proteza te da je neidentificirana osoba ostala bez nekoliko zuba još prije smrti. Potraga za podatcima o prijesmrtnom statusu rezultirala je slijedom od 20 aksijalnih slika paranazalnih sinusa dobivenih kompjutoriziranom tomografijom (MSCT). Provedeno je poslijesmrtno MSCT slikanje kako bi se usporedbom omogućila identifikacija. Neposredna usporedba prijesmrtnih i poslijesmrtnih MSCT podataka pokazala je morfološka poklapanja, posebno za lateralnu ekspanziju lijevog kraka, anteroposteriornu dimenziju i položaj medijalnog i dodatnih septa sinusa. **Zaključak:** U ovom tekstu istaknuto je koliko je važno čuvati medicinske podatke radi interpretacije radiografskih podataka i njihove primjene u pravosuđu.

Zaprimljen: 1. prosinca 2016.
Prihvaćen: 12. veljače 2017.

Adresa za dopisivanje

Rhonan Ferreira Silva
Federal University of Goiás
Av. Universitaria, Esquina com 1^a
Avenida s/n,
Setor Universitário
74605-220 Goiânia, Goiás, Brazil
tel: 00 55 62 3209 6051
rhonans@terra.com.br

Ključne riječi

forenzička antropologija; humana identifikacija; frontalni sinus; računalna tomografija rendgenskim zrakama; označavanje zubne proteze

Uvod

Forenzička radiologija grana je forenzičke znanosti u razvoju i ima posebno značenje kad je riječ o odgovaranju na pravna pitanja u vezi sa smrću (1) i identifikacijom nepoznatih žrtava (2). Općenito, identifikacija ljudi postupkom radiografskih dokaza sastoji se od usporedbe prijesmrtnih (AM) i poslijesmrtnih (PM) podataka (3) koji su zabilježeni uglavnom na konvencionalnim zubnim i maksilofacijalnim radiogramima (4). Posljednjih je godina tomografija (CT) postala uobičajena u medicinskoj praksi i prevladava kad su potrebni prijesmrtni podatci (5). U opisanom slučaju radi se o pozitiv-

Introduction

Forensic radiology as an emerging branch of forensic sciences plays a valuable role by providing answers about deceased individuals in court procedures, particularly those related to the cause of death (1) and identification of unknown victims (2). In general, it provides solid ante mortem (AM) radiographic evidence for comparison with postmortem findings in human identifications (3) which are registered mainly through conventional dental and maxillofacial radiographs (4). However, in the last few years, computed tomography (CT) has become popular in medical routines and has been

noj identifikaciji ljudskog tijela u visokom stupnju raspada-
nja nakon usporedbe prijesmrtnih i poslijesmrtne forenzič-
kih dokaza zabilježenih na CD slikama frontalnih sinusa.

Prikaz slučaja

Godine 2013. pronađeni su ljudski ostatci u visokom
stupnju raspada u šumskom području Brazila. Nakon za-
vršenog očevida truplo je preneseno u ovlaštenu lokalnu medi-
cinsko-patološki institut. Antropometrijskom analizom usta-
novljeno je da je riječ o ženskoj osobi u dobi od 30 do 40
godina (6, 7) i visokoj između 158 i 166 centimetara (8). Au-
topsijom zuba otkrivena je djelomična mobilna proteza, a ne-
koliko zuba bilo je izvađeno prije smrti.

Policijski su tijekom istrage otkrili i tko je potencijalna
žrtva – 33-godišnja žena koja je bila nestala prije sedam da-
na. Od njezine rodbine zatražen je bilo kakav prijesmrtni
medicinski ili zubni podatak kako bi se, radi napretka istra-
ge, omogućila komparativna identifikacija ljudskih ostataka.
To je rezultiralo s 20 aksijalnih snimaka paranazalnih sinu-
sa dobivenih *multi slice* kompjutoriziranom tomografijom
(MSCT) iz 2012. (slika 1.). Na trima snimkama jasno se vi-
djela anteroposteriorna i lateralna dimenzija frontalnih sinu-
sa, uključujući i njegove režnjeve i pregrade (medijane i do-
datne). Nakon toga zatraženi su kompletni DICOM podaci,
ali bez uspjeha jer u mjesnoj bolnici nisu pronađene arhivi-
rane MSCT slike.

Sličnost između antropološkog profila žrtve i nestale oso-
be potaknula je preliminarnu analizu poslijesmrtne fron-
talnog sinusa koristeći se postanterionalnom radiološkom sli-
kom lubanje (slika 2.). Pronađeni su frontalni sinusi malih
dimenzija i središnji septum pomaknut na desnu stranu te
lijevi lobul s većim bočnim proširenjem u usporedbi s nasu-
protnim. Nakon toga slijedio je poslijesmrtni pregled s pomo-
ću kompjutorizirane tomografije koničnom zrakom (CBCT)
uređajem CB500 Gendex[®] (KaVo Kerr Group[®], Njemačka),
što je omogućilo prijesmrtnu i poslijesmrtnu usporedbu CT
podataka (slika 3.). Za pronalazak najboljih poslijesmrtne
presjeka frontalnih sinusa za usporedbu s prijesmrtnima, ko-
rišten je preglednik DICOM-a (Osirix[®] (PixmeoSarl[®], Švicar-
ska). U neposrednoj usporedbi prijesmrtnih i poslijesmrtne
podataka podudarali su se morfološki nalazi frontalnih sinu-
sa žrtve i nestale osobe. Točnije, pronađena je sukladnost u
bočnom širenju lijevog režnja i anteroposteriornoj dimen-
ziji, te u smještaju središnje i akcesornih koštanih pregrada.
Na osnovi tih dokaza pronađeni ljudski ostatci pozitivno su
identificirani.

Rasprava

Sve više zahtjeva za CT preglede potaknulo je prilagod-
bu u usporedbi prijesmrtnih i poslijesmrtne podataka ko-
ja je, od uspoređivanja konvencionalnih radiograma, došla
do tehnološki naprednijih oblika. Od ove promjene najvi-
še je koristi imao postupak identifikacije ljudi jer se posti-
gla pouzdanija i realnija usporedba forenzičkih podataka (3,

most frequently used method for providing AM data in the
forensic routine (5). The present study reports on a case of
positive human identification of a heavily decomposed hu-
man body. A comparison was made between AM and PM fo-
rensic evidence registered from CT images of frontal sinuses.

Case report

In 2013, heavily decomposed human remains were found
in a forest region in Brazil. After the crime scene investiga-
tion, the remains were referred for forensic exams at the local
medico-legal institute. The anthropological analysis pointed
to a female victim aged between 30 and 40 years (6, 7), with
height ranging from 158mm to 166mm (8). The dental au-
topsy revealed the presence of removable partial prostheses
and several AM missing teeth.

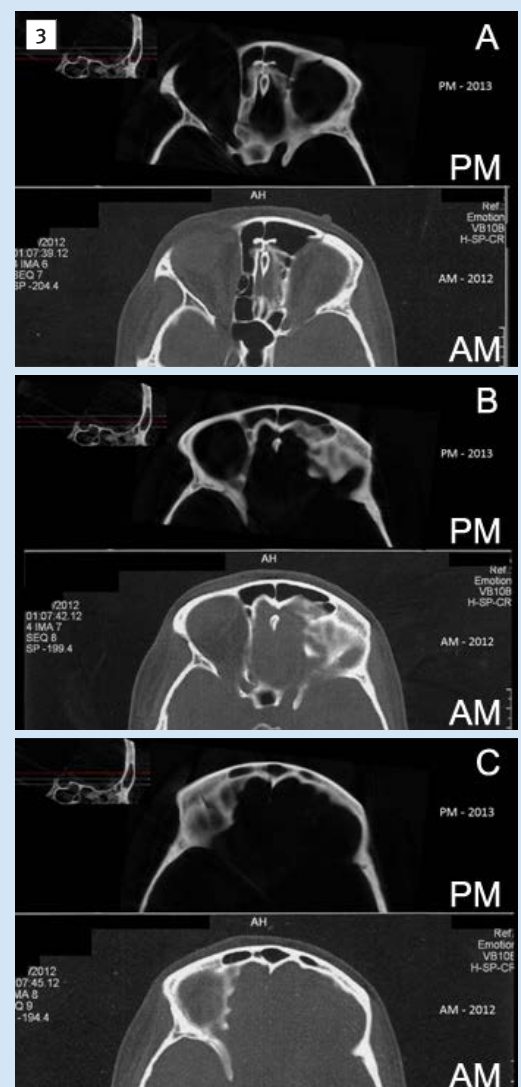
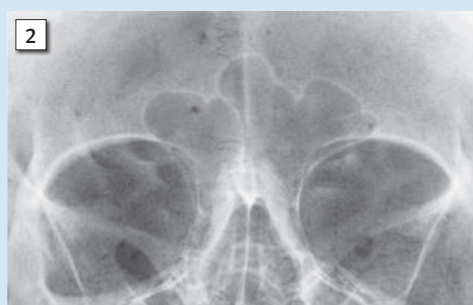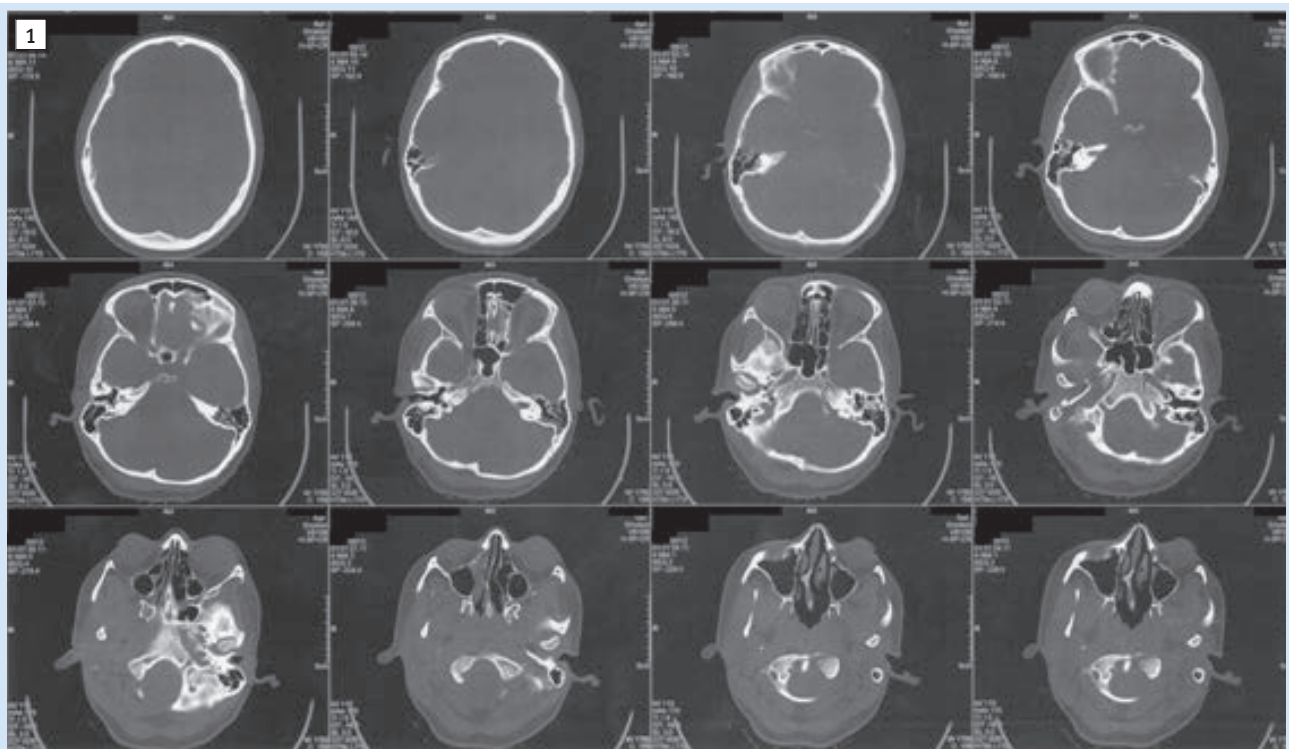
In parallel, Police acknowledged they believed that a
33-year-old woman who went missing for seven days was the
victim of a crime. The relatives of the missing person were
asked to provide any AM medical or dental records to sup-
port the evidence and enable a comparative human identi-
fication. The search resulted in a sequence of 20 axial imag-
es of the paranasal sinuses obtained by Multislice Computed
Tomography (MSCT) dating from 2012 (Figure 1). Three
images showed clearly the anteroposterior and lateral di-
mensions of the frontal sinuses, including its lobes and septa
(median and accessory). Complete DICOM files were re-
quested resulting unsuccessfully because no record of the
MSCT exam was found archived at the local hospital.

The similarity between the anthropological profile of the
victim and the missing person led to the PM preliminary
analysis of the frontal sinuses using a posteroanterior radio-
graph of the skull (Figure 2). Bilateral frontal sinuses of small
dimensions were observed, as well as a median septum dislo-
cated to the right side and a left lobe with larger lateral expan-
sion compared to the contralateral. Afterwards, a PM cone-
beam computed tomography (CBCT) exam was performed
using a CB500 Gendex[®] (KaVo Kerr Group[®], Germany) unit
enabling the AM/PM CT data comparison (Figure 3). In
Osirix[®] (PixmeoSarl[®], Switzerland) DICOM viewer, the PM
slices that reproduced the best AM images of the frontal si-
nuses were searched.

The direct comparison between AM/PM CT data was
made and morphological findings of the frontal sinuses of
the victim were shown to be consistent with those belonging
to the missing person. Specifically, the compatibility between
data was found on the lateral expansion of the left lobe, the
anteroposterior dimension, and the position of median and
accessory septa. An evidence-based positive identification of
human remains was established.

Discussion

The increasing demand for CT exams in the routine of
medical services triggers a modification in the contemporary
AM/PM data, which migrates from the conventional radio-
graphs to more technological imaging modalities. The hu-
man identification process benefits from this modification
achieving more realistic and reliable comparison of forensic



Slika 1. Aksijalni pogled prijesmrtnih MSCT slika - datirano 2012.

Figure 1 Axial view of the computed tomography images obtained ante-mortem, dating from 2012

Slika 2. Radiološka morfologija frontalnih sinusa dobivena poslijesmrtno vidljiva u posteroanteriornom radiogramu lubanje - datirano 2013.

Figure 2 Radiographic morphology of the frontal sinuses observed in the post-mortem posteroanterior radiograph of the skull, dating from 2013

Slika 3. Usporedba prijesmrtnih (AM) i poslijesmrtnih (PM) slika s prikazom donjih (A), srednjih (B) i gornjih (C) regija frontalnih sinusa

Figure 3 Comparison between ante-mortem (AM) and post-mortem (PM) images showing the inferior (A), intermediate (B) and superior (C) regions of the frontal sinuses

9). Korištenje slika visoke tehnološke razine važno je u složenim slučajevima raspadnutih/oštećenih tijela i tjelesnih ostataka kojima često nedostaju meka tkiva i otisci prstiju (5, 10). Znanstvena literatura podupire radiografsku analizu frontalnih sinusa u svrhu identifikacije na temelju karakterističnih morfoloških obilježja (11) te niske prevalencije njihove ageneze (12). Tradicionalno se frontalni sinusi procjenjuju s pomoću anteroposteriornih radiograma lubanje (11, 13), te se na njima obavljaju analize vertikalne i horizontalne dimenzije. Analiza anteroposteriornih dimenzija nije moguća zbog dvodimenzijskog prikaza (2D) tehnike (11, 13). Unatoč tomu što u ovom slučaju potpuni DICOM podatci CT pretrage nisu bili na raspolaganju, oni bi mogli omogućiti volumetrijsku (3D) dimenzijsku analizu (14, 15) te poboljšati interpretacijske dokaze u svrhu pozitivne identifikacije. Osim trodimenzijske analize (3D), važno je istaknuti i noviju literaturu u kojoj se istražuje potencijalno korištenje snimljenih radiograma (2D) paranasalnih sinusa (16). Tako su, na primjer, mjereni maksilarni sinusi radi razlikovanja spolova, kao korist pri rekonstruktivnoj identifikaciji u forenzičkoj antropologiji (16). Štoviše, takve procjene biološkog profila žrtava prijeko su potrebne zbog mogućeg sužavanja popisa nestalih osoba, posebno u složenim slučajevima poput nesreća s višestrukim smrtnima.

Dodatno područje relevantnosti prikazanog slučaja jest uspoređivanje prijesmrtnih MSCT slika s poslijesmrtim CBCT-om. Iako se MSCT uređaji uobičajeno koriste u medicinske svrhe, još nisu postali standardni sastavni dio ovlaštenih medicinsko-patoloških ustanova diljem svijeta. U opisanom slučaju CBCT se pokazao kao alternativa za dobivanje sličnih poslijesmrtih slika za analizu i usporedbu s dobivenim aksijalnim prijesmrtim slikama. Do ovog prikaza slučaja u literaturi nema izvještaja u kojem je provedena uspješna identifikacija ljudskih ostataka isključivo na temelju morfoloških forenzičkih dokaza dobivenih na CT aksijalnim slikama frontalnih sinusa.

Zaključak

Opisani slučaj pokazuje koliko je važno pravilno čuvati medicinske nalaze i koliko su nužni u pravosuđu. Dodatno, prikazana je važnost interpretacije CT prikaza frontalnih sinusa u slučaju kada su oni jedini izvor za forenzičke dokaze.

Sukob interesa

Autori nisu bili u sukobu interesa.

data (3, 9). The use of high-tech imaging techniques plays a valuable role in complex cases involving decomposed/charred bodies and skeletal remains, from which soft tissues and fingerprints are frequently damaged (5, 10).

The scientific literature supports the findings of the radiographic analysis of the frontal sinus for human identification purposes based on its distinctive morphological pattern (11) and low prevalence rate for agenesis (12). Traditionally, the frontal sinus is assessed with posteroanterior radiographs of the skull (11, 13) in which the analysis of vertical and horizontal dimensions is performed. The analysis of anteroposterior dimensions remains unfeasible due to the inherent bidimensional (2D) aspect of the technique (11, 13). Although they were not available in the present case, complete DICOM files from CT scans of the frontal sinuses could enable the analysis of volumetric (3D) dimensions (14, 15) and improve the interpretation of findings to support a positive identification. Apart from the three-dimensional (3D) analysis, it is important to highlight the recent literature that explores the potential use of the paranasal sinuses registered radiographically (2D) for human identification (16). For example, the maxillary sinuses can be measured for sex discrimination to aid reconstructive identifications via forensic anthropology (16). Moreover, these pathways for assessing the biological profile of the victims are essential especially in more complex situations, such as incidents involving multiple deaths, due to their potential for narrowing the lists of missing persons.

Another topic of relevance in the present case was the comparison between AM MSCT images and PM CBCT images. Despite being found in some medical services, MSCT units have not become commonly used in a large number of medico-legal facilities worldwide. In the present study, Cone Beam Computed Tomography (CBCT) was the available alternative to enable a similar image analysis and to properly reproduce PM axial images obtained from AM images. So far, there have been no studies in the literature which have reported a case of human identification based exclusively on morphological forensic evidence observed in CT axial images of the frontal sinuses.

Conclusion

The present case report points out that it is very important that the images are stored properly in order to be clinically useful. Also, it highlights the fact that such images need to be provided for court procedures. Additionally, it encourages the training on the interpretation of CT images of the frontal sinus to support cases in which they are the only available forensic evidence.

Conflict of interest

None declared

Abstract

Objective: The aim of this paper is to report on a case of positive human identification of a decomposed body after the comparison of ante-mortem (AM) and post-mortem (PM) computed tomography images of frontal sinus. **Case report:** An unknown, highly decomposed human body, aged between 30 and 40 years, was found in a forest region in Brazil. The dental autopsy revealed several teeth missing AM and the presence of removable partial prostheses. The search for AM data resulted in a sequence of 20 axial images of the paranasal sinuses obtained by Multislice Computed Tomography (MSCT). PM reproduction of the MSCT images was performed in order to enable a comparative identification. After a direct confrontation between AM/PM MSCT, the data were collected for morphological findings, specifically for the lateral expansion of the left lobe, the anteroposterior dimension, and the position of median and accessory septa of the sinuses. **Conclusion:** The importance of storing and interpreting radiographic medical data properly is highlighted in this text, thus pointing out the importance of application of forensic radiology in the field of law.

Received: December 1, 2016

Accepted: February 13, 2017

Address for correspondence

Rhonan Ferreira Silva
Forensic Dentistry
Federal University of Goiás
Av. Universitária, Esquina com 1^a
Avenida s/n,
Setor Universitário
Postal code: 74605-220
Goiania, Goiás, Brazil
Phone: 00 55 62 3209 6051
rhonans@terra.com.br

Key words

Forensic Anthropology; Human Identification; Frontal Sinus; X-Ray Computed Tomography; Forensic Dentistry; Denture Identification Marking

References

- Thali, MJ; Viner, MD; Brogdon, BG - editors. Brogdon's forensic radiology. 2nd ed. Boca Raton: CRC Press; 2010.
- Matoso RI, Benedicto Ede N, de Lima SH, Prado FB, Daruge E, Daruge Júnior E. Positive identification of a burned body using na implanted orthopedic plate. *Forensic Sci Int.* 2013 Jun 10;229(1-3):168.e1-5.
- Franco A, Thevissen P, Coudyzer W, Develter W, Van de Voorde W, Oyen R, et al. Feasibility and validation of virtual autopsy for dental identification using the Interpol dental codes. *J Forensic Leg Med.* 2013 May;20(4):248-54.
- Wood RE. Forensic aspects of maxillofacial radiology. *Forensic Sci Int.* 2006 May 15;159 Suppl 1:S47-55.
- Silva RF, Botelho TL, Prado FB, Kawagushi JT, Daruge Júnior E, Bérzin F. Human identification based on cranial computed tomography scan – a case report. *Dentomaxillofac Radiol.* 2011 May;40(4):257-61.
- McKern, TW; Stewart, TD - editors. Skeletal age changes in young American males. Natick: Quartermaster Research & Development Command; 1957.
- Watanabe S, Terazawa K. Age estimation from the degree of osteophyte formation of vertebral columns in Japanese. *Leg Med (Tokyo).* 2006 May;8(3):156-60.
- Trotter M, Gleser GC. Estimation of stature from long bones of American whites and negroes. *Am J Phys Anthropol.* 1952 Dec;10(4):463-514.
- Sakuma A, Saitoh H, Makino Y, Inokuchi G, Hayakawa M, Yajima D, et al. Three-dimensional visualization of composite fillings for dental identification using CT images. *Dentomaxillofac Radiol.* 2012 Sep;41(6):515-9.
- Silva RF, Franco A, Mendes SD, Picoli FF, de Azevedo Marinho DE. Human identification through the patella – report of two cases. *Forensic Sci Int.* 2014 May;238:e11-4.
- Patil N, Narjodkar FR, Sontakke SS, Sansare K, Salvi R. Uniqueness of radiographic patterns of the frontal sinus for personal identification. *Imaging Sci Dent.* 2012 Dec;42(4):213-7.
- Gotlib T, Kuzminska M, Held-Ziolkowska M, Osuch-Wojcikiewicz E, Niemczyk K. Hidden unilateral aplasia of the frontal sinus: a radioanatomic study. *Int Forum Allergy Rhinol.* 2015 May;5(5):441-4.
- Silva RF, Franco A, Dias PEM, Gonçalves AS, Paranhos LR. Interrelationship between forensic radiology and forensic odontology – a case report of identified skeletal remains. *J Forensic Radiol Imag.* 2013;1(4):201-6.
- Kim DI, Lee UY, Park SO, Kwak DS, Han SH. Identification using frontal sinus by three-dimensional reconstruction from computed tomography. *J Forensic Sci.* 2013 Jan;58(1):5-12.
- Beaini TL, Duailibi-Neto EF, Chilvarquer I, Melani RF. Human identification through frontal sinus 3D superimposition: pilot study with cone-beam computed tomography. *J Forensic Leg Med.* 2015 Nov;36:63-9.
- Queiroz CL, Terada ASSD, Dezem TU, Araújo LG, Galo R, Oliveira-Santos C, et al. Sex discrimination of adult human maxillary sinuses on panoramic radiographs. *Acta Stomatol Croat.* 2016 Sep;50(3):215-221.