

MRI IN GYNECOLOGICAL ONCOLOGY

KAROLNA BOLANČA ČULO, IVO PEDIŠIĆ and ŽELJKO HERCEG

Department of Radiology, University Hospital for Tumors,
University Hospital Center Sestre milosrdnice, Zagreb, Croatia

Summary

The use of magnetic resonance imaging (MRI) in gynecological oncology is rapidly expanding. Pelvic MRI has excellent soft tissue contrast and multiplanar imaging ability to demonstrate either normal or pathological processes. In gynecological oncology the rapidly evolving role of MRI includes not only diagnosis but also disease staging, planning of therapy and monitoring response to treatment. We perform around 350 preoperative gynecology MRI annually, mostly in patients with suspected malignancy. In this paper we review the role of MRI in endometrial, cervical and ovarian cancer.

KEY WORDS: *cervical cancer, endometrial cancer, ovarian cancer, gynecological malignancy, magnetic resonance imaging*

MRI U GINEKOLOŠKOJ ONKOLOGIJI

Sažetak

Svakodnevno raste uporaba magnetske rezonancije (MR) u ginekološkoj onkologiji. MR zdjelice ima odličnu prostornu i kontrastnu rezoluciju za prikaz kako fizioloških tako i patoloških procesa. Sve je veća uključenost MR pregleda ne samo u dijagnostici već i u određivanju stadija bolesti i praćenju terapije. U našem radiološkom odjelu obavi se oko 350 preoperativnih ginekoloških MR pregleda godišnje, najčešće kod pacijenata sa sumnjom na malignu bolest. U ovom radu osvrnuti ćemo se na ulogu MR u karcinomima endometrija, grlića maternice i jajnika.

KLJUČNE RIJEČI: *rak grlića maternice, karcinom endometrija, karcinom ovarija, ginekološka onkologija, magnetska rezonancija*

INTRODUCTION

Magnetic resonance imaging (MRI) in gynecology is now frequently used. MRI is the imaging technique with the highest contrast and anatomic resolution for soft tissues, becoming the modality of choice for morphological evaluation of pelvic disease. Diffusion-weighted imaging (DWI), provides information on the random motion of water molecules in tissue and dynamic contrast enhanced (DCE) MRI depicts the distribution of contrast agent by measuring tissue enhancement and variations in vessels. MRI is used in clinical staging in gynecological oncology, planning of therapy and monitoring response to treatment.

MRI OF ENDOMETRIAL CANCER

In endometrial cancer, MRI is used to identify myometrial invasion and extra uterine spreading, allowing preoperative surgical planning. Preoperative MRI helps in classifying tumors according to International association of gynecological oncology (FIGO) classification. Normal or thickened endometrial stripe with diffuse or focal abnormal signal and intact junctional zone is staged as FIGO IA stage, while in FIGO IB stage signal intensity of tumor extends into less than half endometrium with partial disruption of junctional zone. FIGO IC stage present when signal intensity of tumor extends into more than half of myome-

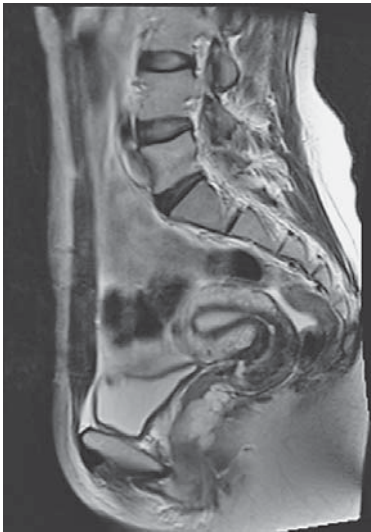

Figure 1.1.

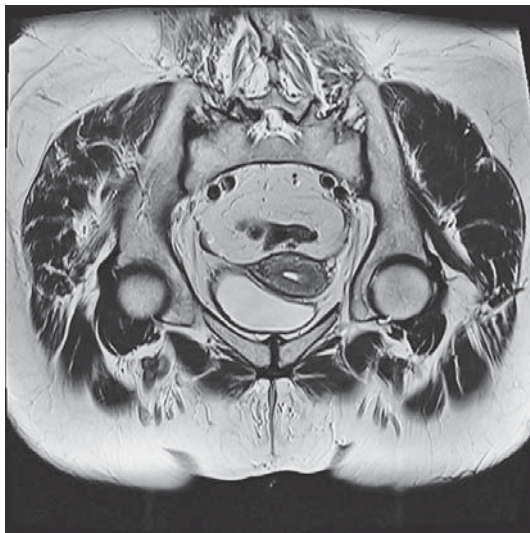


Figure 1.2.

trium and junctional zone is fully disrupted, while FIGO IIA stage shows widening of cervical canal with low signal of cervical stroma which presents invasion of endocervix. FIGO IIB stage shows cervical stromal invasion with disruption of low signal stroma. In FIGO IIIA stage we can see disruption of continuity of outer myometrium with or without irregular uterine configuration. FIGO IIB stage also shows invasion of vagina. Pelvic or para-aortic lymphadenopathy in FIGO IIIC stage presents as regional or para-aortic nodes larger than 1cm in short axis diameter. FIGO IVA stage

shows invasion of bladder or rectal mucosa and FIGO IVB stage shows distant metastases including intraabdominal lymphadenopathy. The overall staging accuracy of conventional MRI imaging was reported to be 83% to 92%, with 87% of sensitivity and 91% of specificity in assessing myometrial infiltration, 80% of sensitivity and 96 of specificity for cervical invasion, and 50% of sensitivity and 95% of specificity for lymph node assessment (1).

Figure 1.1. T2WI sagittal image presents normal uterus zonal anatomy where we can see a thin black line (arrow) that present junctional zone and white normal thick endometrium.

Figure 1.2. T2WI presents coronal view of small left-side endometrial cancer, staged as IB.

MRI OF CERVICAL CANCER

Uterine cervical cancer is one of the most common malignancies seen by gynecological radiologists. In cervical cancer MRI has a role in local staging. By assessing the proximal extension of tumors in young women, MRI determines the feasibility of fertility-preserving surgery (trachelectomy). It is also used to plan and administer radiotherapy. This optimises tumor irradiation while limiting unwanted irradiation of the intestines and other pelvic organs.

Cervical cancer can be endophytic, exophytic or infiltrative. It has high signal intensity on T2WI

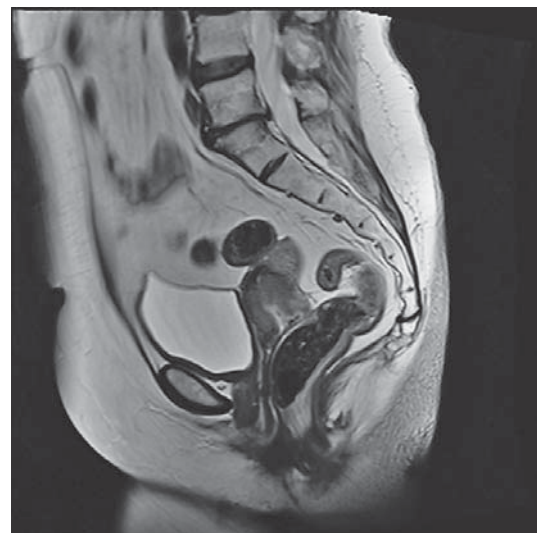

Figure 2.1.

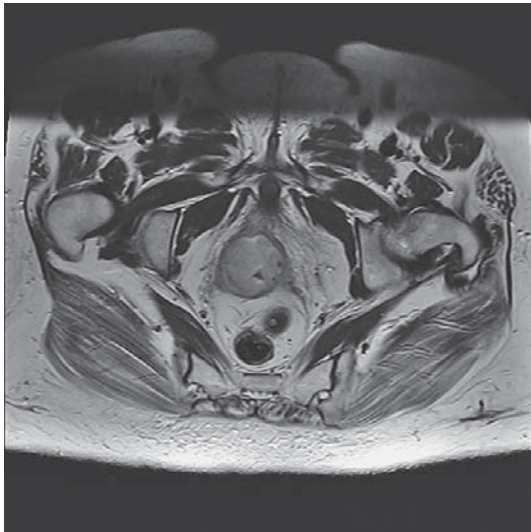

Figure 2.2.

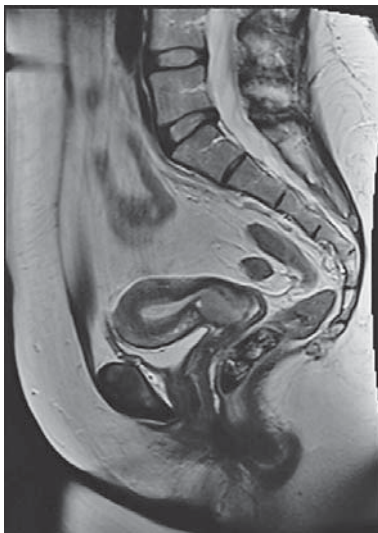

Figure 2.3.

sequence, while normal cervical stroma is low signal intensity. For detection of abdominal lymph nodes it is important to inspect all the structures up to the renal hilum. The most important for staging and FIGO classification is the description of parametrial or vaginal infiltration. The overall staging accuracy of MRI ranges from 77%-90% (2,3). The reported accuracy of MRI in detection of parametrial invasion ranges from 77% to 96% (2)

Figure 2.1. and 2.2 present infiltrative cervical cancer that spreads in parametrium. In the first image we can see dorsal spreading and exofitic

growth, while second image presents left side infiltrative spreading.

Figure 2.3. presents endophytic cervical tumor. This patient is candidate for fertility-preserving surgery.

MRI OF OVARIAN CANCER

Masses in ovaries can be solid, cystic or complex. In ovarian cancer MRI is useful in young women in diagnosing endometriomas, dermoids and fibroids, which can be misdiagnosed by ultra-

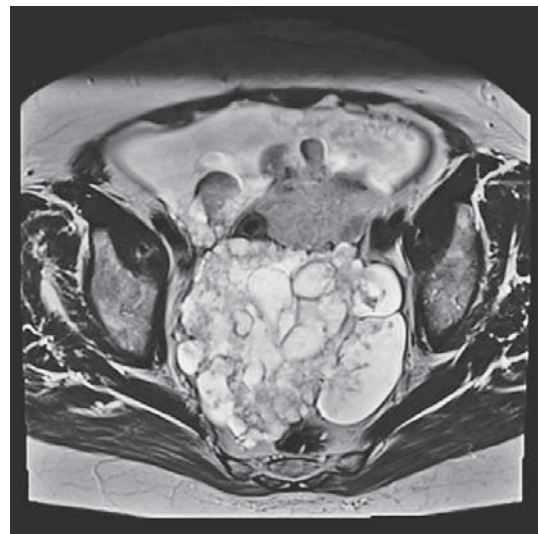


Figure 3.1.

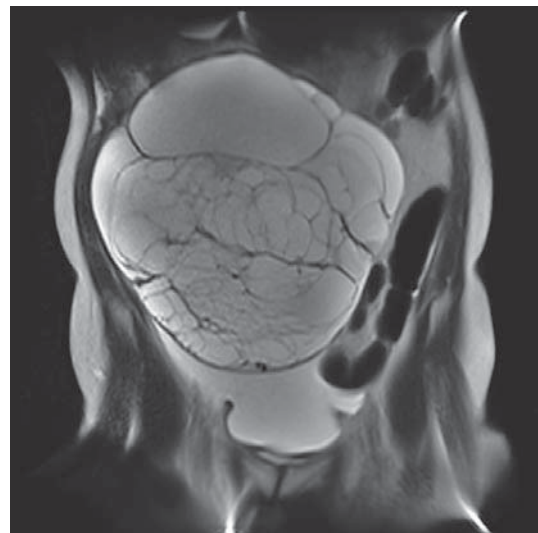


Figure 3.2.

sound as malignant lesions. Features that can be seen in an adnexal mass on MRI that are associated with malignancy are: a mixed solid–cystic lesion, irregularity and vegetation of the wall or septa in a cystic lesion, larger than 4 cm, early enhancement on dynamic contrast-enhanced MR images, and the presence of ascites, peritoneal disease or adenopathy. In patients with clinically or sonographically detected complex or adnexal masses, MRI imaging was shown to have 91% accuracy for the diagnosis of malignancy (4).

In 3.1. image we can see a large bilateral mostly cystic process which represents bilateral serous cystadenocarcinoma of ovary, while on 3.2. image we can see also a large cystic process that is well demarcated lesion that represents cystadenoma of right ovary. Ascites is present because of the mass effect and not as a sign of malignancy.

CONCLUSION

This article reviews the role of MRI in the three most common gynecological malignancies. Owing to its superior soft tissue delineation and multiplanar capability, MRI is considered the most accurate imaging modality for preoperative evaluation of gynecological cancers. The role of MRI is increasing both due to its ability to show the pelvic structure with high precision showing also their vascularisation patterns. The increasing availability of MR technology should benefit patients with pelvic malignancies in diagnosis, preoperative staging and follow up.

REFERENCES

1. R. Manfredi, P. Mirk, G. Maresca et al. Local-regional staging of endometrial carcinoma: role of MR imaging in surgical planning. *Radiology*. 2004;231:372–378.
2. H. Hricak, C. G. Lacey, L. G. Sandles, Y. C. F. Chang, M. L. Winkler, and J. L. Stern. Invasive cervical carcinoma: comparison of MR imaging and surgical findings. *Radiology*. 1988 Mar;166(3):623-631.
3. S. Bipat, A. S. Glas, J. Van Der Velden, A. H. Zwinderman, P. M. M. Bossuyt, and J. Stoker. Computed tomography and magnetic resonance imaging in staging of uterine cervical carcinoma: a systematic review. *Gynecol Oncol*. 2003 Oct;91(1):59-66
4. Knopp MV, Giesel FL, Marcos H, et al. Dynamic contrast-enhanced magnetic resonance imaging in oncology. *Top Magn Reson Imaging*. 2001;12:301-308.
5. Hricak H. Widespread use of MRI in gynecology: a myth or reality? *Abdom Imaging*. 1997;22:579-588.
6. Deshmone A, Gulani V, Griswold MA, Seiberlich N. Parallel MR imaging. *J Magn Reson Imaging*. 2012;36:55–72.
7. Bharwani N, Reznick RH, Rockall AG. Ovarian cancer management: the role of imaging and diagnostic challenges. *Eur J Radiol*. 2011;78:41–51.
8. Hricak H, Mendelson E, Bohm-Velez M, et al. Role of imaging in cancer of the cervix. American College of Radiology. ACR appropriateness criteria. *Radiology*. 2000;215[suppl]:925–930.
9. Hricak H, Mendelson E, Bohm-Velez M, et al. Endometrial cancer of the uterus. American College of Radiology, ACR appropriateness criteria. *Radiology*. 2000;215 [suppl]:947–953.
10. Reznick RH, Sahdev A. MR imaging in cervical cancer: seeing is believing. The 2004 Mackenzie Davidson Memorial Lecture. *Br J Radiol*. 2005;78:S73-85.
11. El Haddad KS, Padhani AR. Recent advances in oncological imaging. *Clin Med*. 2003;3:318-322.
12. Knopp MV, von Tengg-Kobligh H, Choyke PL. Functional magnetic resonance imaging in oncology for diagnosis and therapy monitoring. *Mol Cancer Ther*. 2003;2:419-426.
13. Manfredi R, Mirk P, Maresca G, et al. Local-regional staging of endometrial carcinoma: role of MR imaging in surgical planning. *Radiology*. 2004;231:372-378.
14. Seki H, Takano T, Sakai K. Value of dynamic MR imaging in assessing endometrial carcinoma involvement of the cervix. *AJR Am J Roentgenol*. 2000;175:171-176.
15. Alvarez Moreno E, Jimenez de la Peña M, Cano Alonso R. Role of New Functional MRI Techniques in the Diagnosis, Staging, and Follow up of Gynecological Cancer: Comparison with PET-CT. *Radiology Research and Practice* 2012. doi.org/10.1155/2012/219546. Accessed on 21.12.2015.
16. H. Hricak, P. S. Swift, Z. Campos, J. M. Quivey, V. Gildengorin, and H. Goranson. Irradiation of the cervix uteri: value of unenhanced and contrast-enhanced MR imaging. *Radiology*. 1993;189(2):381-388

Author's address: Karolina Bolanča Čulo, Department of Radiology, University Hospital for Tumors, University Hospital Center Sestre milosrdnice, Ilica 197, 10000 Zagreb, Croatia. e-mail: karolinabol@yahoo.com