

Ferial Perjuci¹, Resmije Ademi-Abdyli¹, Yll Abdyli², Enesë Morina², Ali Gashi¹, Zana Agani¹, Jehona Ahmed¹

Procjena spontanog zacjeljivanja kosti nakon enukleacije velike rezidualne ciste u maksili bez korištenja presadaka: prikaz slučaja

Evaluation of Spontaneous Bone Healing After Enucleation of Large Residual Cyst in Maxilla without Graft Material Utilization: Case Report

¹ Zavod za oralnu kirurgiju Medicinskog fakulteta Sveučilišta u Prištini – Odsjek za dentalnu medicinu, 10000 Priština, Kosovo
Department of Oral Surgery, Medical Faculty, University of Prishtina, Dental Branch, 10000 Prishtina, Kosovo

² Student poslijediplomskog studija na Sveučilištu u Prištini – Odsjek za dentalnu medicinu, 10000 Priština, Kosovo
Postgraduate student, University of Prishtina, Dental Branch, 10000 Prishtina, Kosovo

Sažetak

Cistične lezije čeljusti kao što su keratociste (naziv je vraćen i smatra se boljim negoli keratocistični odontogeni tumori, iako su pojmovi i dalje prihvatljivi sinonimi), folikularne i radikularne ciste te rezidualne ciste mogu dosegnuti velike razmjere i uzrokovati znatnu razgradnju kosti. E nukleacija cističnih lezija u čeljusti oštećuje kosti koje se mogu regenerirati spontano ili nakon intervencije korištenjem autogenih koštanih transplantata ili drugih materijala za njihovo nadomještanje. U ovom kliničkom istraživanju opisuje se spontana regeneracija kosti nakon enukleacije rezidualne ciste u distalnom dijelu maksile. Njezin napredak praćen je na temelju kliničkog pregleda, rendgenske procjene i subjektivnih simptoma pacijenta. Regeneracija kosti i smanjenje cistične šupljine dokumentirani su nakon šest mjeseci i poslije jedne godine na panoramskoj rendgenskoj snimci. Fiziološki proces koagulacije osnova je za spontano stvaranje kosti, čak ako je koštani defekt velik, pod uvjetom da je okružen s dovoljno koštanih stijenki.

Zaprimljen: 4. rujna 2017.

Prihvaćen: 28. siječnja 2018.

Adresa za dopisivanje

Resmije Ademi-Abdyli
University of Prishtina
Medical Faculty
Department of Oral Surgery
resmijea@yahoo.com

Ključne riječi

odontogene ciste; kost, obnavljanje; čeljust, ciste; gornja čeljust

Uvod

Cistične lezije čeljusti razmjerno su česta patološka pojava. Srećom, oko 86 posto njih su periapikalne, pa liječenje nije složeno (1). Velike ciste u čeljusti rijetke su i uglavnom su posljedica folikularnih cista i keratocista. Znanstvena zajednica i dalje se više koristi terminom „odontogena keratocista” negoli „keratocistični odontogeni tumor”, premda su oba pojma prihvatljiva (2). No, radikularne i rezidualne ciste također mogu značajno rasti, što uzrokuje velike koštane defekte (3).

Rezidualne (radikularne) ciste razvijaju se od epitelnih ostataka čiju proliferaciju stimulira upalni odgovor koji nastaje iz nekrotične pulpe prije toga izvađenih avitalnih zuba (4). Zapravo, to su radikularne ciste koje ostaju u čeljusti nakon vađenja zuba i nastavljaju autonomno rasti. S vremenom se može pojaviti regresija cista, stagnacija ili daljnji rast, ali nažalost malo se zna o njihovoj evoluciji i ekspanziji i zašto se uopće razvijaju (3). U usporedbi s drugim velikim cistama kao što su radikularne i folikularne ciste te keratociste, rezi-

Introduction

Cystic lesions of the jaws are a relatively commonly encountered pathology. Fortunately, approximately 86% of them are periapical lesions and their treatment is not complex (1). Large cysts of the jaws are rare and mainly result to be follicular cysts and keratocysts. Scientific community still continues to use the term ‘odontogenic keratocyst’ more favorably than ‘keratocystic odontogenic tumor’ although both terms remain acceptable synonyms (2). However, radicular and residual cysts can also grow substantially in size, thus causing considerable osseous defects (3).

Residual (radicular) cysts develop from epithelial remnants which are stimulated to proliferate by the inflammatory response originating from the necrotic pulp of previously extracted non-vital teeth (4). In fact, these are radicular cysts that remain in the jaw after removal of the affected tooth and continue to grow in an autonomous manner. In the course of time, the cysts may undergo regression, remain static in size, or grow, but unfortunately little is known about their evolu-

dualne su rijetke i čine samo 10 do 18 posto dentalnih cista (1). Često se otkrivaju slučajno tijekom rutinskih rendgenskih pretraga ili ako se inficiraju (5, 6).

Kirurško liječenje cističnih lezija u čeljusti može se obavljati enukleacijom ili marsupijalizacijom (7). Marsupijalizacija ili dekompresija tehnika je kojom se oslobađa pritisak s ciste te tako omogućuje stvaranje kosti i smanjenje cistične šupljine kako bi poslije enukleacija protekla lakše i manje rizično za vitalne strukture. Ova tehnika zahtijeva suradnju pacijenata, česte posjete, održavanje higijene cistične šupljine i enukleaciju najranije tri mjeseca nakon inicijalnog zahvata (8). Metoda izbora za liječenje cističnih lezija čeljusti je enukleacija lezije i biološka terapija zgrušavanjem i poticanjem stvaranja nove kosti. Liječenje se provodi u cijelosti u jednom posjetu, nakon čega se cistična šupljina brzo smanjuje zbog centripetalnog zacjeljivanja kosti (4). To se obično događa nakon enukleacije malih cista, a enukleacija velikih cista u čeljusti stvara velike koštane defekte.

Svrha ovoga rada bila je prikazati spontanu koštanu regeneraciju nakon enukleacije velike rezidualne ciste u maksili, a praćena je kliničkim pregledom i panoramskom rendgenskom snimkom.

Prikaz slučaja

Tridesetšestogodišnja pacijentica upućena je u Zavod za oralnu kirurgiju Sveučilišnog stomatološkog kliničkog centra Sveučilišta u Prištini, zbog otekline u području gornjih desnih kutnjaka nastale mjesec dana prije. U medicinskoj anamnezi nisu otkriveni nikakvi zdravstveni problemi. Stomatološkim pregledom ustanovljeno je da joj nedostaje prvi kutnjak (zub 16) te zadebljanje bukalno u području desnoga gornjeg kutnjaka. Zabilježena je promjena boje agonističkih zuba, drugog kutnjaka i drugog pretkutnjaka. Tijekom intraoralne palpacije zadebljanja duboko u fornixu otkriven je Dupuytrenov fenomen.

Na panoramskoj snimci otkrivena je radiolucentna lezija na desnoj strani u području gornjih kutnjaka veličine približno 35 milimetara u anteroposteriornom i 50 milimetara u kraniokaudalnom smjeru (slika 1.). Da bi se primijenio niz dijagnostičkih kriterija, provedena je aspiracija sterilnom štrcaljkom i dobivena je obojena tekućina bogata kristalima kolesterola karakterističnima za cističnu tekućinu (slika 2.).

Test vitaliteta pulpe (električno ispitivanje pulpe – Parkell Inc, Edgewood, New York) drugog kutnjaka i drugog pretkutnjaka pokazao je da su oba zuba vitalna.

Kirurški zahvat obavljen je u lokalnoj anesteziji (Lidocain - adrenalin, 40 mg/0,025, 2 ml, Alkaloid Skoplje). Odignut je mukoperiostealni režanj nakon čega je slijedilo uklanjanje bukalne kortikalne kosti koja je bila jako tanka, te je izložena cistična membrana. Cistična membrana pažljivo je odvojena od okolne kosti i potpuno uklonjena. Pregledom preosta-

tion and expansion and why they develop in the first place (3). Compared to other large cysts such as radicular cysts, follicular cysts and keratocysts, residual cysts are rare amounting only to 10% to 18% of dental cysts (1). The diagnosis of a residual cyst is often established inadvertently, either during routine radiography or when the cyst is infected (5,6).

Surgical treatment of cystic lesions of the jaws can be accomplished by means of enucleation or marsupialization (7). Marsupialization or decompression is a technique that releases pressure from the cyst, allowing for bone formation and reduction of the cystic cavity in order that later in the course of treatment enucleation can be accomplished more easily and with less risk to vital structures. This technique requires close patient cooperation, frequent visits, maintenance of cystic cavity hygiene and subsequent enucleation not earlier than three months after the initial surgery (8). The method of choice for the treatment of cystic lesions of the jaws is enucleation of the lesion and biological treatment with organization of coagula and new bone formation. The treatment is carried out completely in one session, which accounts for faster cystic cavity reduction due to centripetal healing of bone (4). This usually happens after enucleation of small cysts, while enucleation of large cysts of the jaws creates substantial osseous defects.

The aim of this case report was to present spontaneous bone regeneration after enucleation of a large sized residual cyst in the maxilla, evaluated by clinical examination and panoramic radiography.

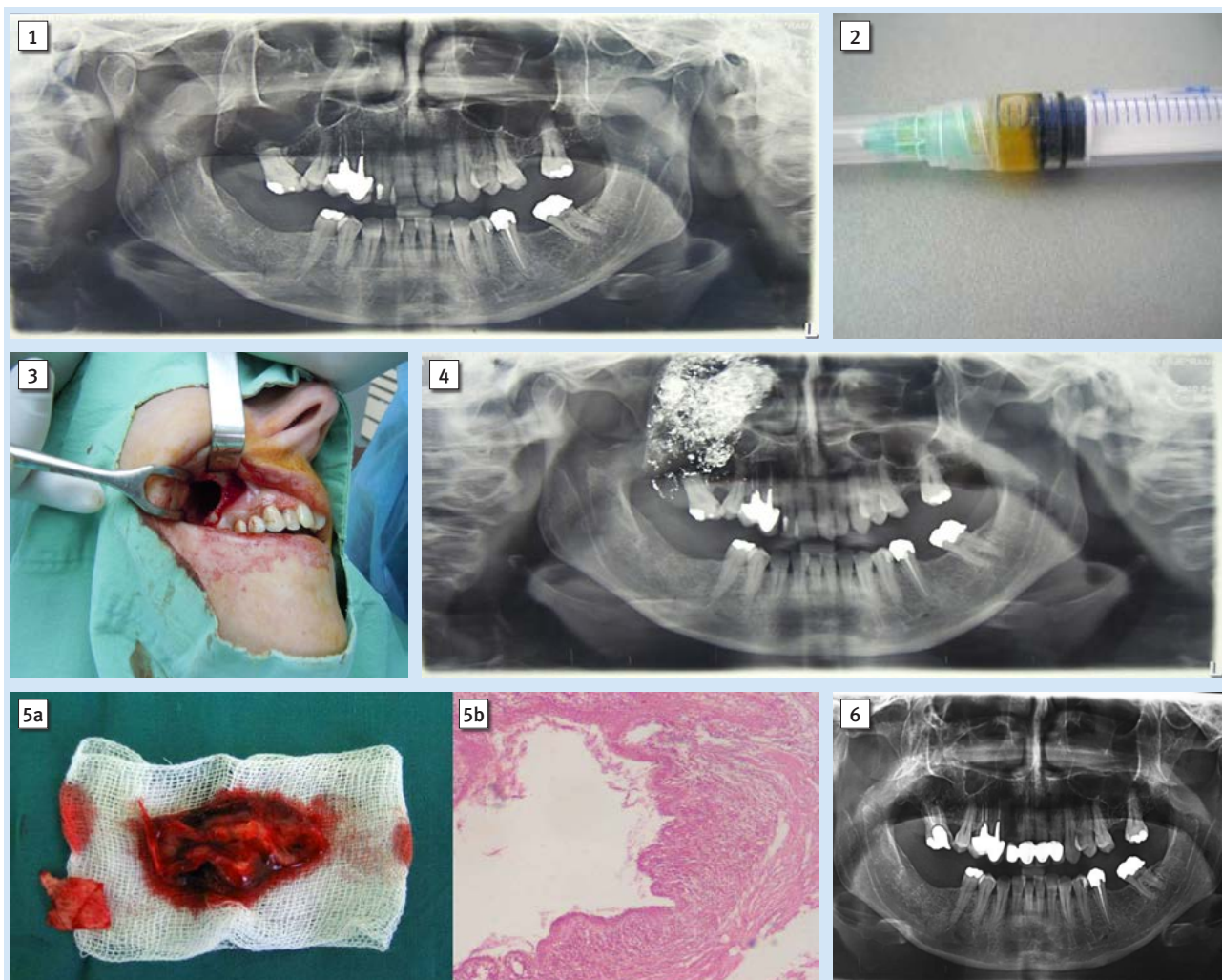
Case report

A 36 year- old female patient was referred to the Department of Oral Surgery, University Dental Clinical Center of Kosovo – Prishtina with a chief complaint of swelling in the right upper molar region, observed before one month. Her medical history did not reveal any health problems. Dental examination revealed the absence of the first molar (tooth 16 FDI) accompanied with a firm tumefaction located buccally to the molar region of the right maxilla. Discoloration of the agonist teeth was noted, namely second molar and second premolar. During intraoral palpation of the tumefaction deep in the fornix, Dupuytren's phenomenon was detected.

Panoramic radiography revealed a radiolucent lesion on the right side of the maxillary molar region, approximately 35 mm in size in antero-posterior and 50 mm in cranio-caudal direction (Figure 1). In order to fulfill the complete set of diagnostic criteria, aspiration with sterile syringe was performed and straw colored fluid, rich in cholesterol crystals, a characteristic of cystic fluid, was acquired (Figure 2).

Pulp vitality testing (by electric pulp tester – Parkell Inc., Edgewood, New York) of the second molar and second premolar revealed that both of them were vital.

The surgical procedure was performed under local anesthesia (Lidocaine-Adrenalin, 40mg/0.025, 2ml, Alkaloid Skoplje). Reflection of the mucoperiosteal flap, followed by removal of buccal cortical bone which was considerably thin, and exposure of the cystic membrane was carried out. The cystic membrane was carefully separated from the surrounding bone and



Slika 1. Preoperativna rendgenska snimka – radiolucencija na desnoj strani maksile

Figure 1 Preoperative radiographic view - radiolucence on the right side of maxilla

Slika 2. Obojena tekućina aspirirana iz lezije

Figure 2 Straw colored fluid aspirated from the lesion

Slika 3. Intraoperativni prikaz koštanog kaviteta nakon enukleacije ciste

Figure 3 Intraoperative view of the bone cavity after cyst enucleation

Slika 4. Neposredno nakon operacije gaza natopljena jodoformom u rezidualnom koštanom defektu

Figure 4 Immediate postoperative view of iodoform gauze tape inside the remaining cystic bone defect

Slika 5. a) makroskopski prikaz cistične lezije, b) patohistološki mikroskopski nalaz

Figure 5 a) Macroscopic view of cystic lesion, b) Histopathological microscopic view

Slika 6. Panoramska snimka koštanog defekta nakon godinu dana; povećana gustoća kosti na mjestu cistične lezije upućuje na stvaranje nove kosti, čime se smanjuje defekt

Figure 6 Panoramic imagery of bone defect after one year. Increased bone density at the site of cystic lesion suggests new bone formation resulting with reduced osseous defect.

le koštane srži i nakon cistektomije uočena je ekspanzija ciste u svim smjerovima, vestibularno te u smjeru sinusa, uzrokujući tako izlaganje (intaktna) Schneiderove membrane intaktnoga maksilarnog sinusa (slika 3.). Veliki koštani defekt koji je nastao nakon enukleacije cistične lezije ispran je sterilnom fiziološkom otopinom (0,9-postotni natrijev klorid). S obzirom na nedostatak usisnih alata za drenažu nakupljenih tekućina, kao što su krv i serum u koštanom defektu nastalom cistektomijom, koristili smo se ručno izrađenim zavojem od gaze s jodoformom, a sastojao se od trake pamučne gaze uronjene u sterilnu fiziološku otopinu (0,9-postotni natrijev klorid) i impregnirane jodnim prahom (PPH Cerkamed - Varna, Bugarska).

was completely removed. Inspection of the remaining osseous defect following cystectomy displayed expansion of the cyst in all directions, buccally as well as in the direction of the sinus, thus causing exposure of the intact Schneiderian membrane of the intact maxillary sinus (Figure 3). The large osseous defect produced after enucleation of the cystic lesion was rinsed with sterile saline solution (0.9% Sodium Chloride). Considering our lack of suction tools for the drainage of the accumulated fluids such as blood and serum in the cystectomy osseous defect, we used handmade wound dressing of iodoform gauze tape, consisting of a cotton gauze strip immersed in sterile saline solution (0.9% Sodium Chloride) and impregnated with iodoform powder (PPH Cerkamed – Varna, Bulgaria) .

Gaza s jodoformom presavijena je i umetnuta u koštani defekt kako bi se postigla kompresija (slika 4.), s jednim labavim krajem za komunikaciju s usnom šupljinom kroz primarno zatvoren repositionirani i zašiveni mukoperiostealni režanj (3 – 0, obloženi VICRYL®, poliglaktin 910, Suture-Ethicon-GMBH, Njemačka). Ova gaza ostala je unutar defekta dva dana nakon operacije te je djelovala kompresivno radi hemostaze unutar preostalog koštanog defekta, a istodobno je služila i za drenažu nakupljene tekućine.

Propisani su antibiotici (Amoksiklav tablete 625 mg, Lek, Ljubljana) svakih osam sati tijekom šest dana te je pacijentici savjetovano da se suzdrži od vrućih napitaka i čvrste hrane 24 sata nakon kirurškog zahvata. Sljedećeg dana tijekom rutinske poslijeoperacijske kontrole gaza je djelomično uklonjena, a dan poslije (48 sati nakon operacije) uklonjena je potpuno. Postoperativni edem bio je mali i pacijentica je navela da osjeća laganu bol, pa je uzimala samo jednu tabletu ibuprofena od 400 mg (Farmavita, Sarajevo). Šavovi su uklonjeni sedmi dan poslije zahvata. Patohistološko mikroskopsko ispitivanje bioptičkog materijala (enukleata cistične lezije) pokazalo je cističnu stijenkicu prevučenu slojevitim pločastim epitelom i izljevom fibrotičnog tkiva, gustog infiltrata te upalnih i hijalnih čestica uz prisutnost ekstravaziranih eritrocita (slika 5. a, b). Stoga je patohistološki nalaz konačno potvrdio dijagnozu radikularne ciste.

Postoperativni tijek praćen je uobičajenim kontrolnim posjetima u određenim vremenskim razmacima kako slijedi: nakon 24 sata, zatim poslije dva dana, tjedan dana, mjesec dana, te šest i dvanaest mjeseci.

Tijekom rutinskog pregleda mjesec dana nakon kirurškog zahvata pacijentica nije navela nikakve probleme ili tegobe, ali je test vitaliteta pulpe (Electric Pulp Tester, Parkell Inc, Edgewood, New York) susjednih zuba otkrio gubitak vitaliteta drugog kutnjaka koji je nakon toga liječio specijalist endodoncije. Nakon jednogodišnjeg praćenja nije se žalila ni na kakve probleme. Panoramska slika pokazala je intenzivnu neprozirnost kostiju, što upućuje na dovoljnu formiranost nove kosti s margina prema središtu defekta, značajno smanjujući preostalu koštanu šupljinu u usporedbi s preoperativnim radiografom (slika 6).

Rasprava

Nakon enukleacije kostiju ostaju defekti različitih veličina i oblika. Preostali mali kirurški defekti obično spontano zacjeljuju fiziološkim apozicijskim mehanizmom rasta kosti. Preostala koštana šupljina puni se krvnim ugruškom koji postaje okosnica za formiranje nove kosti. No u slučaju velikih kirurških defekata uzrokovanih enukleacijom, krvni ugrušak u defektu itekako je rizičan jer se lako može inficirati ili potaknuti stvaranje velikog hematoma kao posljedice nekontroliranog nakupljanja krvi u koštanoj šupljini.

Kako bi se smanjio postoperativni volumen koštanog defekta i spriječila spomenute komplikacije, koristimo se različitim kirurškim metodama i drenažom velikih čeljusnih cista, ovisno o iskustvu i sklonosti kirurga.

The iodoform gauze tape was inserted and folded with compression inside the bone defect (Figure 4) with one loose end for communication with the oral cavity through the primary closure of the repositioned and sutured mucoperiosteal flap (3-0, Coated VICRYL®, polyglactin 910, Suture-Ethicon-GMBH, Germany). This gauze tape remained inside the defect for 2 (two) days postoperatively, accomplishing the effect of compressive hemostasis inside the remaining bone defect and, simultaneously, serving for drainage of the accumulated fluids inside the osseous defect.

Antibiotics were administered (Amoksiklav 625mg tablets, Lek, Ljubljana) every 8 hours for 6 days and the patient was advised to refrain from hot beverages and solid foods for 24 hours after the surgical procedure. During the routine postoperative follow up visit next day, the gauze tape was partially removed and the day after (48 hours postoperatively) it was removed completely. Postoperative edema was minor and the patient declared that she had slight pain; hence she used only one tablet of Ibuprofen 400 mg (Farmavita, Sarajevo). The sutures were removed on the seventh postoperative day. Histopathological microscopic examination of the bioptic material (enucleated cystic lesion) displayed a cystic wall coated with stratified squamous epithelium and effusion of fibrotic tissue, dense infiltrates of inflammatory and hyaline particles, and presence of extravasated erythrocytes. (Figure 5.a, b) Hence, the final histopathological report with diagnosis of “radicular cyst” was confirmed.

The postoperative course of the case was followed with routine visits made at certain time intervals as follows: after 24 hours, two days, one week, one month, six months and twelve months.

During routine examination one month after the surgical procedure, the patient did not report any problems or concerns, but the pulp vitality test (Electric Pulp Tester, Parkell Inc, Edgewood, New York) of the neighboring teeth revealed loss of the second molar vitality, which was afterwards treated by an endodontist. On a follow-up examination after one year, the patient did not report any particular problems. Panoramic image revealed intense bone opacity indicating sufficient formation of new bone from the margins to the center of the defect, significantly reducing the remaining osseous cavity when compared to the preoperative radiograph. (Figure 6)

Discussion

Defects of various sizes and shapes remain after enucleation of bone cysts. The remaining small surgical defects after enucleation of cysts commonly heal spontaneously by the physiological appositional mechanism of bone growth. The residual bone cavities are replenished with blood clots, which become the scaffold for new bone formation. However, in case of large surgical defects caused by enucleation, a blood clot in the bone defect is a considerable risk as it can easily become infected or lead to the formation of a large hematoma as a result of uncontrolled accumulation of blood in the bone cavity.

Aiming to reduce the postoperative osseous defect volume and to prevent the above mentioned complications, dif-

Jedna od metoda liječenja je zatvorena cistektomija s postoperativnom drenažom koštane šupljine s pomoću trake jedne gaze kao u našem slučaju, ili usisavanjem koje djeluje negativno na tlak stvoren u koštanoj šupljini u razdoblju od pet do sedam postoperativnih dana. Usisavanjem se povlači meko tkivo prema središtu koštanog defekta, što smanjuje njegov volumen i potiče primarno zacjeljivanje rana, kao u slučaju malih koštanih šupljina. Ova metoda jednostavna je u slučaju liječenja velikih koštanih cista jer rezultira kraćom rehabilitacijom i potpunom regeneracijom koštanoga tkiva u razdoblju od dva do šest mjeseci (9).

Hern i Milijavec (10) otkrili su da se veliki koštani defekti nastali nakon enukleacije velikih čeljusnih cista postoperativno sporije spontano regeneriraju od onih malih. Njihovi rezultati pokazuju da je konačna gustoća kosti formirane nakon 12 mjeseci u malim defektima (20 – 30 mm) 97 posto, a u velikim defektima 84 posto, u usporedbi s gustoćom susjedne zdrave kosti (10). Stoga enukleacija velikih cističnih defekata otvara dilemu o tome treba li koštane defekte ispunjavati nadomjescima kosti ili ne.

Postoje različita mišljenja o primjeni koštanih presadaka kosti u liječenju koštanih defekata nakon enukleacije velikih cista čeljusti (11 – 13). Mnogi autori zaključili su da korištenje autogenih koštanih transplantata (3, 14) i aloplastičnih materijala (15) može pomoći u liječenju koštanih defekata smanjujući rizik od mogućih prijeloma čeljusti, a smanjuje i razdoblje oporavka.

Iako su autogeni koštani transplantati *zlatni standard* za rekonstrukciju defekata u maksilofacijalnoj regiji, s obzirom na to da su biološki kompatibilni, vaskulariziraju se i oseointegriraju s okolnom kosti uz minimalni rizik od infekcija i odstupanja, njihova uporaba ima nedostatke i ograničenja. Nedostaci uključuju produljeno trajanje operacije s obzirom na vrijeme potrebno za uzimanje transplantata, morbiditet donorskog mjesta, resorpciju transplantata, ograničenu dostupnost te male količine koje su nedostatne za nadoknadu velikih defekata itd. (16).

Slijedom toga, aloplastični materijali i ksenogena kost za popunjavanje koštane šupljine nakon enukleacije ciste koriste se kao alternativa autogenim transplantatima (14,17 – 19). Dakle, istraživanje Khaleda (15) pokazuje da je gustoća kosti tri i šest mjeseci nakon enukleacije ciste, s lezijama dimenzija od 1,5 do 3,5 cm, bila veća u skupini pacijenata čiji je koštani defekt bio ispunjen granulama *Agipore* (koralji) i u onoj koja je bila tretirana laserom nižeg intenziteta, negoli u kontrolnoj skupini u kojoj su oštećenja kosti ostala prazna. Unatoč činjenici da upotreba aloplastičnog materijala smanjuje morbiditet i komplikacije, a njihova količina je neograničena (16), ti su materijali pokazali smanjenu osteogenu aktivnost jer se najprije moraju resorbirati i zamijeniti novim osteogenim tkivom (8, 19). Odgođeni oporavak također se opaža zbog usporene resorpcije ili izloženosti transplantata te infekcije nakon toga (9). Horowitz i Bodner (19) otkrili su neuspjeh u 20 posto slučajeva s velikim defektima kosti povezanih s ksenogenom kosti preporučenom za poticanje regeneracije kostiju. Smatra se da uporaba koštanih transplantata smanjuje opasnost od spontanog prijeloma nakon enukleacije velikih cista (3, 14, 20).

ferent methods of surgical treatment and drainage of the large jaw cysts are used, depending on the experience and preference of the surgeon.

One of the treatment methods is closed method cystectomy with postoperative bone cavity drainage by iodine gauze tape, which was used in our case, or by suction which works by means of negative pressure created in the bone cavity within a period of 5-7 postoperative days. The suction acts by pulling the soft tissue towards the center of the osseous defect, which decreases the volume of the defect and supports primary wound healing as in cases of small bone cavities. This method of treatment is simple for treating large bone cysts, resulting in a shorter rehabilitation time and complete regeneration of the bone tissue within 2-6 months (9).

Hern and Milijavec (10) have found that large osseous defects created after enucleation of large jaw cysts show slower postoperative spontaneous regeneration than small osseous defects. Their results show that the final bone density formed after 12 months, in small defects (20-30mm) was 97%, while in large defects it was 84%, compared with healthy neighboring bone density (10). Therefore, enucleation of large cystic defects creates a dilemma of whether to fill the osseous defect with bone substitutes or not.

There are different views about the application of bone grafts for the treatment of osseous defects after enucleation of large cysts of the jaws (11-13). Many authors have concluded that the use of autogenous bone grafts (3, 14), and alloplastic grafts (15) can help with healing of osseous defects by reducing the risk of possible fractures of the jaws and shorten the recovery period.

Although autogenous bone grafts are considered the gold standard for the reconstruction of defects in the maxillofacial region, considering they are biologically compatible, they become vascularized and osseointegrated with surrounding bone with minimal risk of infection and dislodgement, their use has disadvantages and limitations. These disadvantages include: prolonged time of operation considering the time for graft harvesting, donor site morbidity, graft resorption, limited availability with the small amounts being insufficient for replenishing large defects etc. (16).

Consequently, alloplastic graft materials and xenograft bone for filling bone defects after cyst enucleation are used as an alternative to autogenous grafts (14, 17-19). Thus, the study of Khaled (15) shows that bone density 3 and 6 months after cyst enucleation, with lesions measuring from 1.5 to 3.5 cm, was higher in the group of patients whose osseous defect was filled with *Agipore* granules (corals) and in the group treated with lower laser intensity, than in the control group where the bone defects remained empty. Despite the fact that usage of alloplastic material lowers morbidity and complications, and their usage is unlimited (16), these materials have shown reduced osteogenic activity since they first have to be resorbed and then replaced with new osteogenic tissue (8,19). Recovery delays are also observed due to slow resorption or exposure of graft and infection afterwards (9). Horowitz and Bodner (19) have found failure in 20% of cases with large bone defects associated with xenograft bone recommended for promotion of bone regeneration. It is considered that the

Ettl i suradnici (12) utvrdili su da uporaba koštanih transplantata u lezijama nakon enukleacije cista nije imala prednosti, a jednostavna enukleacija cista sa zacjeljivanjem preko krvnog ugruška pokazuje nisku stopu komplikacija i dovoljnu regeneraciju kosti čak i u slučaju velikih defekata. Chiapasco i suradnici (11) te Wagdargi i njegovi kolege (21) također su ustanovili da spontana regeneracija kosti može nastati u velikim mandibularnim cistama bez primjene materijala za punjenje.

U mnogim istraživanjima dokumentirano je spontano zacjeljivanje koštanih defekata nakon enukleacije velikih cista bez uporabe koštanog presatka (10, 13, 22). Shokier i suradnici (22) uočili su spontano zacjeljivanje bez uporabe koštanih presadaka kod 20 pacijenata, od kojih su deset bile keratociste, pet folikularne ciste i pet radikularne ciste s monokortikalnim defektima kosti veličine od 2,5 do 6 cm. Autori su procijenili gustoću kostiju u intervalima od 6, 12 i 24 mjeseca te otkrili postupno smanjenje veličine koštanih defekata u svim slučajevima, a gustoća kosti značajno se povećavala. Povećanje gustoće kosti bilo je znatno veće u prvih šest mjeseci u usporedbi s idućim mjesecima (23).

Wagdargi i suradnici (21) također su otkrili povećanje gustoće kosti sa statističkom značajnošću od 90,8 posto i to šest mjeseci nakon enukleacije i primarnog zatvaranja 16 odontogenih cista veličine od 3 do 10 cm. Autori su zabilježili veću gustoću kosti u mandibularnim koštanim šupljinama od onih u maksili.

Schmitz i Hollinger (24) koštane defekte dijele na one kritične i nekritične veličine, ovisno o broju stijenki koje ih okružuju. Autori su otkrili da su defekti s dvjema stijenkama koje nedostaju nekritične veličine i mogu spontano zacijeliti bez obzira na veličinu defekta, a defekti koji imaju samo jednu stijenkicu, a sve druge nedostaju, kritične su veličine i rekonstrukcija je prijeko potrebna. U istraživanju provedenom na zečevima opaženo je da je spontano zacjeljivanje koštanih defekata bilo moguće kad je defekt bio unikortikalni i ne veći od osam milimetara, a nije uspjelo kada su defekti bili bikortikalni i u promjeru veći od 15 milimetara (25).

Podatci iz literature pokazuju da su se preostali koštani defekti nakon enukleacije ciste regenerirali spontano unatoč veličini šupljine, histološkom tipu, spolu i dobi, kad god je bilo moguće sačuvati rezidualne koštane ploče koje su činili perioist i endost (10, 23, 26).

Suprotno tomu, N. Hern i M. Miljavec (2008.) ustanovili su da povećana dob negativno utječe na liječenje, a oblik koštanog defekta bio je važniji čimbenik cijeljenja od volumena (10).

Naš slučaj prikazuje subjektivnu i rendgensku procjenu zacjeljivanja rezidualnih koštanih defekata veličine od 35 do 50 milimetara, okruženih dovoljnom količinom koštanih stijenki i primarno zatvorenih mukoperiostealnim režnjem nakon enukleacije velike ciste u maksili, bez uporabe nadomjesnog koštanog materijala.

Panoramska snimka godinu dana nakon cistektomije otkrila je povećanu neprozirnost kosti. To upućuje na novu formaciju kosti od rubova prema središtu koštanog defekta, što pokazuje značajno smanjenje veličine preostalog koštanog defekta u usporedbi s preoperativnom rendgenskom slikom.

use of bone grafts reduces the risk of spontaneous fractures after enucleation of large cysts (3, 14, 20).

Ettl et al. (12) found that the use of bone grafts in lesions after cyst enucleation showed no superiority and that simple cyst enucleation with blood clot healing shows low complication rates and sufficient bone regeneration even in large defects. Chiapasco et al. (11) and Wagdargi SS et al. (21) also found that spontaneous bone regeneration could occur in large mandibular cysts without the aid of any filling materials.

Numerous investigations have documented spontaneous healing of bone defects after large cyst enucleations, without the use of bone graft (10, 13, 22). Shokier et al. (22) have observed spontaneous healing without the use of bone grafts in 20 patients, out of which 10 were keratocysts, 5 follicular cysts and 5 radicular cysts, with monocortical bone defects ranging from 2.5 to 6 cm. The authors evaluated bone density formed at intervals of 6, 12 and 24 months and found gradual reduction of the size of osseous defects in all cases, with bone density increasing significantly. The bone density increase was significantly higher in the first 6 months compared to the subsequent months (23).

Also, Wagdargi et al. (21) have found a bone density increase with statistical significance of 90.8%, 6 months after enucleation and primary closure of 16 odontogenic cysts ranging from 3 to 10 cm in size. Authors have noted higher bone density in mandibular osseous cavities than those in the maxilla.

Schmitz and Hollinger (24) divided bone defects into critical and non-critical size defects, depending on the number of walls that surround them. The authors found that defects with two missing walls are uncritical sized defects and can heal spontaneously regardless of the size of the defect, while the defects that have only one wall with all the other walls missing are critical size defects, reconstruction of which is necessary. From a study performed in rabbits, it was observed that spontaneous healing of osseous defects was superior when the defect was unicortical and not greater than 8mm, and failed when defects were bicortical and greater than 15mm in diameter (25).

Results in the literature show that residual bone defects after cystic enucleation regenerated spontaneously despite the size of the cavity, histological type, gender and age, whenever it was possible to conserve residual bone plates provided by periosteum and endosteum (10,23,26).

In contrast, Hern and Miljavec (2008) found that increased patient age had a negative effect on healing and that the shape of the osseous defect was a more important healing factor than the volume (10).

Our study case presents the subjective and radiographic assessment of healing of residual bone defect sized 35 to 50mm, surrounded by sufficient bone plates and primarily closed with mucoperiosteal flap after enucleation of large cyst in maxilla, without using any graft material.

One year after cystectomy, the panoramic image revealed increased bone opacity suggestive of new bone formation from the margins to the center of the bone defect, showing significant reduction in size of the residual bone defect when compared to the preoperative radiograph.

Prikazani slučaj opisuje uspješno spontano zacjeljivanje koštanog defekta nakon enukleacije velike ciste bez uporabe bilo kojeg materijala za punjenje, čime se potvrđuju rezultati iz literature o spontanom zarastanju velikih koštanih defekata bez koštanih nadomjestaka (21, 22, 26, 27).

Tijek prikazanog slučaja i rezultati iz literature daju uvjerljive dokaze koji podupiru kirurški pristup liječenju velikih radikularnih cista metodom primarnog zatvaranja, bez uporabe koštanih nadomjestaka.

Zaključak

Na temelju našega kliničkog slučaja i podataka iz literature može se zaključiti da spontano zacjeljivanje kosti nakon enukleacije velikih cista treba biti terapija izbora, čak i u slučaju velikih cističnih šupljina kod kojih je rezidualni koštani defekt omeđen dovoljnom količinom kosti. Ova metoda kirurškog liječenja nije složena i jeftina je, a i biološki je vrlo malo rizična. Njome se smanjuje ukupni trošak terapije te opasnost od postoperativnih komplikacija povezanih s transplantacijom.

Sukob interesa

Nije bilo sukoba interesa.

The presented case depicts successful spontaneous healing of osseous defect after large cyst enucleation without the use of any filling materials, thus confirming the results from the literature relating to spontaneous healing of large osseous defects without bone substitutes (21, 22, 26, 27).

The course of the presented case and results from the literature provide compelling evidence in support of the surgical approach of treating large radicular cysts with the primarily closed method without use of any graft materials.

Conclusion

Based on our clinical case and data from the literature, it can be concluded that spontaneous bone healing after enucleation of large cysts should be the treatment of choice even in large cystic cavities where the residual bone defect is walled with sufficient amount of bone. This surgical treatment modality is noncomplex, with low financial and biological costs. It decreases the overall cost of surgery and reduces the risk of postoperative complications associated with grafting.

Conflict of interest

None declared

Abstract

Cystic lesions of the jaws such as keratocysts (scientific community still continues to use the term 'odontogenic keratocyst' more favourably than 'keratocystic odontogenic tumour' although both terms remain acceptable synonyms), follicular cysts, radicular cysts, and residual cysts may reach large proportions, causing considerable bone destruction. Enucleation of cystic lesions in the jaw produces bone defects, which may recover spontaneously or with assisted healing with the use of autogenous bone graft or other bone substitute materials. This clinical study presents a spontaneous bone regeneration after residual cyst enucleation in the distal part of the maxilla. The progress of recovery is followed by clinical and radiographic examination and subjective data obtained from the patient. Bone regeneration and cystic cavity reduction was observed in the panoramic image after six months and after one year. The physiological process of coagulation provides the basic process for the spontaneous bone formation even if an osseous defect is considerably large, provided that the defect is surrounded by adequate bony walls.

Received: September 4, 2017

Accepted: January 28, 2018

Address for correspondence

Resmije Ademi-Abdyli
University of Prishtina
Medical Faculty
Department of Oral Surgery
resmijea@yahoo.com

Key words

Odontogenic Cysts; Bone Regeneration; Jaw Cysts; Maxilla

References

1. Dia-Tine S, Diallo B, Ba A, Yam AA, Secc O, Ndiaye CF. Clinical study of cysts jaw bones. *Dakar Med*. 2004;49(3):196-202
2. Kennedy RA. WHO is in and WHO is out of the mouth, salivary glands, and jaws sections of the 4th edition of the WHO classification of head and neck tumours. *Br J Oral Maxillofac Surg*. 2018 Feb;56(2):90-95.
3. Dimitroulis G, Curtin J. Massive residual dental cyst: Case report. *Aust Dent J*. 1998 Aug;43(4):234-7.
4. Neville, B; Damm, D; Allen, C; Bouquot, J - editors. *Oral and maxillofacial pathology*. Philadelphia: WB Saunders; 1995. p. 107-8.
5. Main DMG. Epithelial jaw cysts: a clinicopathological reappraisal. *Br J Oral Surg*. 1970 Nov;8(2):114-25.
6. Pechalova PF, Bakardjiev AG. Cysts of the Jaws: a Clinical Study of 621 Cases, *Acta Stomatol Croat*. 2009; 43(3):215-224.
7. Bodner L, Woldenberg Y, Bar-Ziv J. Radiographic features of large cystic lesions of the jaws in children. *Pediatr Radiol*. 2003 Jan;33(1):3-6.
8. Bodner L, Bar-Ziv J. Characteristics of bone formation following marsupialization of jaw cyst. *Dentomaxillofac Radiol*. 1998 May;27(3):166-71.
9. Sokler K, Sandev S, Grgurevic J. Surgical Treatment of Large Mandibular Cysts. *Acta Stomatol Croat*. 2001; 35(2):253-7.
10. Hern N, Milijavec M. Spontaneous bone healing of large bone defect in mandible. *Int J Oral Maxillofac Surg*. 2008 Dec;37(12):1111-6.
11. Chiapasco M, Rossi A, Motta JJ, Crescentini M. Spontaneous bone regeneration after enucleation of large mandibular cyst: radiographic computed analysis of 27 consecutive cases. *J Oral Maxillofac Surg*. 2000 Sep;58(9):942-8; discussion 949.
12. Ettl T, Gosau M, Sader R, Reichert TE. Jaw cysts - Filling or no filling after enucleation? A review. *J Craniomaxillofac Surg*. 2012 Sep;40(6):485-93.
13. Yüzügüllü B, Araz K. Validity of conventional surgical treatment methods for mandibular dentigerous cysts. Two case reports. *N Y State Dent J*. 2011 Mar;77(2):36-9.
14. Barry CP, Kearns GJ. Case report—odontogenic keratocysts enucleation, bone grafting and implant placement: an early return to function. *J Ir Dent Assoc*. 2003;49(3):83-8.
15. Khaled A. Elhayes. Low Intensity Laser versus Synthetic Bone Graft to Increase Bone Density After Enucleation Of Large Cystic Lesions Of Jaws. *Journal of American Science*. 2011; 7(6):1101-8.
16. Rogers GF, Greene AK. Autogenous bone graft: basic science and clinical implications. *J Craniomaxillofac Surg*. 2012 Jan;23(1):323-7.
17. Jensen SS, Broggini N, Hjorting-Hansen E, Schenk R, Buser D. Bone healing and graft resorption of autograft, anorganic bovine bone and beta-tricalcium phosphate. A histologic and histomorphometric study in the mandibles of minipigs. *Clin Oral Implants Res*. 2006 Jun;17(3):237-43.
18. Pradel W, Eckelt U, Lauer G. Bone regeneration after enucleation of mandibular cysts: Comparing autogenous grafts from tissue-engineered bone and iliac bone. *Oral Surg Oral Med Oral Pathol Oral Radiol Endod*. 2006 Mar;101(3):285-90.
19. Horowitz I, Bodner L. Use of xenograft bone with aspirated bone

- marrow for treatment of cystic defect of the jaws. *Head Neck*. 1989 Nov-Dec;11(6):516-23.
20. Etzias A, Sugar W. Pathological fractures of the mandible: A diagnostic end treatment dilemma. *Br J Oral Maxillofac Surg*. 1994 Oct;32(5):303-6.
 21. Wagdargi SS, Rai KK, Arunkumar KV, Katkol B, Arakeri G. Evaluation of Spontaneous Bone Regeneration after Enucleation of Large Cysts of the Jaws using Radiographic Computed Software. *J Contemp Dent Pract*. 2016 Jun 1;17(6):489-95.
 22. Shokier HM, Khalifa GA. Assessment of bone healing in large bony defects after enucleation of jaw cysts without using any graft material using direct digital radiography and C.T.scan (clinical study). *C. D. J*. 2009; 25:35–42.
 23. Zhao Y, Liu B, Wang SP, Wang YN. Computed densitometry of panoramic radiographs in evaluation of bone healing after enucleation of mandibular odontogenic keratocysts. *Chin J Dent Res*. 2010;13(2):123-6.
 24. Schmitz J, Hollinger J. The critical size defect as an experimental model for craniomandibular non junction. *Clin Orthop Relat Res*. 1986 Apr;(205):299-308.
 25. Doddell R, Yavuzer R, Bier UC, Alkadri A, Jackson T. Spontaneous bone healing in the rabbit. *J Craniofac Surg*. 2000 Jul;11(4):346-9.
 26. Rubio ED, Mombrú CM. Spontaneous Bone Healing after Cysts Enucleation without Bone Grafting Materials: A Randomized Clinical Study. *Craniofac Trauma Reconstr*. 2015 Mar;8(1):14-22.
 27. Chacko R, Kumar S, Paul A, Arvind. Spontaneous Bone Regeneration after Enucleation of Large Jaw Cysts: A Digital Radiographic Analysis of 44 Consecutive Cases. *Journal of Clinical and Diagnostic Research : JCDR*. 2015;9(9):ZC84-ZC89.