

Repair of recurrent peritoneopericardial hernia in a dog, using polypropylene mesh and an autologous pericardial flap - a case report

Ozren Smolec^{1*}, Dražen Vnuk¹, Nika Brkljača Bottegaro¹, Bojan Toholj², Marko Pećin¹, Andrija Musulin¹, Nikica Daraboš³, and Josip Kos¹

¹*Clinic for Surgery, Orthopedics and Ophthalmology, Faculty of Veterinary Medicine, University of Zagreb, Zagreb, Croatia*

²*Department for Surgery, Orthopedics and Ophthalmology, Faculty of Agriculture, University of Novi Sad, Novi Sad, Republic Serbia*

³*Faculty of Medicine, Josip Juraj Strossmayer University of Osijek, Osijek, Croatia*

SMOLEC, O., D. VNUK, N. BRKLJAČA BOTTEGARO, B. TOHOLJ, M. PEĆIN, A. MUSULIN, N. DARABOŠ, J. KOS: Repair of recurrent peritoneopericardial hernia in a dog, using polypropylene mesh and an autologous pericardial flap. Vet. arhiv 88, 427-435, 2018.

ABSTRACT

Peritoneopericardial hernia is a malformation which allows the protrusion of abdominal organs into the pericardial sac. Several methods of herniorrhaphy had been described in human and veterinary medicine, such as the usage of prosthetic patches, allografts and autologous grafts. The purpose of this study was to describe a new technique of herniorrhaphy, which combines two different materials for defect closure (nonautologous-polypropylene mesh and autologous-pericardial flap) in a case of recurrent peritoneopericardial hernia in a dog. A two-year-old, intact female Rhodesian Ridgeback was presented with an eight week history of respiratory problems, occasional coughing, vomiting, lethargy, body mass loss and icteric mucous membrane. The reason for using this technique was tension at hernial ring, which could have caused recurrence of the peritoneopericardial hernia. Polypropylene mesh was used in order to reinforce the herniorrhaphy and an autologous flap served as a barrier against mesh exposure to the epicardial surface. In our opinion, this method is safe with no complications observed, so therefore, it could be a suitable method for peritoneopericardial reherniation repair.

Key words: dog; mesh; peritoneopericardial hernia; pericardial flap; repair

Introduction

Peritoneopericardial diaphragmatic hernia (PPDH) is the most common congenital defect involving the pericardium of dogs and cats (ROSENSTEIN et al., 2001; EVANS

*Corresponding author:

Assist. Prof. Ozren Smolec, PhD, DVM, Clinic for Surgery, Orthopedics and Ophthalmology, Faculty of Veterinary Medicine, University of Zagreb, Heinzelova 55, 10000 Zagreb, Croatia, Phone: +385 1 2390 385; Fax: +385 1 2390 380; E-mail: osmolec@vef.hr

ISSN 0372-5480

Printed in Croatia

and BIERY, 1980; BELLAH et al., 1989). Peritoneopericardial diaphragmatic hernia has also been reported in rabbits, in a donkey, and a calf (KHEIRANDISHI et al., 2014). In this anomaly, abdominal contents are herniated into the pericardial sac because of direct communication between the peritoneal and the pericardial cavities. An embryonic development defect of the dorsolateral septum transversum in the so-called sternocostal triangle structure can cause this developmental abnormality. Peritoneopericardial diaphragmatic hernia occurs in both sexes, and an autosomal recessive mode of inheritance has been postulated. The defect consistently involves the left dorsolateral and central portions of the diaphragm, with herniation of abdominal organs into the thoracic cavity. This malformation allows the passage of abdominal contents through the diaphragmatic defect into the pericardial sac. Passage of the liver, spleen, stomach, or intestines into the pericardial sac may result in cardiac tamponade, compromised function of the respiratory tract, gastrointestinal tract obstruction, gallbladder torsion, and splenic or hepatic entrapment (SCHULMAN et al., 1985; REIMER et al., 2004).

Persistent communication between the peritoneal and pericardial cavities allows the abdominal contents to herniate into the pericardial sac. Peritoneopericardial hernia is frequently associated with supraumbilical hernia, and malformation or absence of the sternbrae and pectus excavatum. Other potential causes for PPDH include malformations and teratogen-induced factors (BERRY et al., 1990).

The present case represents an, until now, undescribed method of surgical management of a large, recurrent peritoneopericardial hernia. A combination of autologous pericardial tissue and polypropylene mesh was used in the surgical repair of this complicated PPDH reherniation.

Case report

History. A two-year-old, intact female Rhodesian Ridgeback was presented with an 8-week history of respiratory problems, occasional coughing, vomiting, lethargy, kyphosis, body mass loss and icteric mucous membranes (10 days). Peritoneo-pericardial and supraumbilical hernioraphies had been performed in this dog 5 months before, with a standard technique. Blood tests, thoracic and abdominal radiography (native and contrast) were performed. The biochemistry results revealed elevated ALT 1891 U/L (20-156 U/L) and bilirubin 143.3 $\mu\text{mol/L}$ (1.71-8.55 $\mu\text{mol/L}$). Thoracic and abdominal radiographs revealed a contrast agent filled mass, protruding cranially through the diaphragm. The cardiac silhouette and the pericardium were enlarged. The lesion was consistent with a PPDH, with herniation of the pyloric part of the stomach and proximal duodenum (Fig. 1).

Pre-anaesthetic preparation and anaesthesia. The patient was treated with an intravenous infusion of lactated Ringer's solution at 2 mL/kg/h, and esomeprazole (Nexium, Astra Zeneca) in a dose of 0.5 mg/kg i/v for three days. The dog was premedicated with midazolam (0.3 mg/kg i/m) (Dormicum, Roche) and fentanyl (3 $\mu\text{g/kg}$ i/v) (Fentanyl,

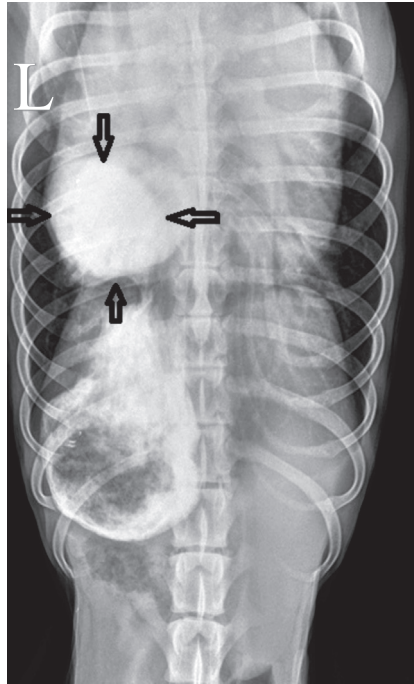


Fig. 1. Dorsoventral projection of the thoracic and abdominal radiograph, revealing a contrast agent filled mass, protruding cranially through the diaphragm. The cardiac silhouette is enlarged. The lesion is consistent with a peritoneopericardial diaphragmatic hernia with herniation of the pyloric part of the stomach and the proximal duodenum (arrows).

Janssen). Anaesthesia was induced with propofol (Propofol MCT; Fresenius) in dose of 4 mg/kg i/v, and maintained with sevoflurane (Sevorane, Abbot) in oxygen under controlled ventilation, and a constant rate infusion of fentanyl in dose of 0.3 µg/kg/min i/v was provided. Amoxicillin and clavulonic acid (Augmentin, Glaxo Smith Kline) were used before and after surgery, in a dose 20 mg/kg i/v.

The surgical procedure. After preparation of the ventral part of the chest and abdomen, a skin incision and a ventral midline coeliotomy were performed from just caudal to the xiphoid to the umbilicus. On abdominal exploration, a well-margined 7x7 cm defect was identified in the ventral right muscular part and the central tendinous part of the diaphragm. All liver lobes were in the abdominal cavity. The pericardium was filled with 200 mL of serous fluid. A round-shaped part of the spleen, as well as the pyloric part of the stomach with the cranial part of duodenum, were found to be herniated through the diaphragmatic defect in the pericardium (Fig. 2).

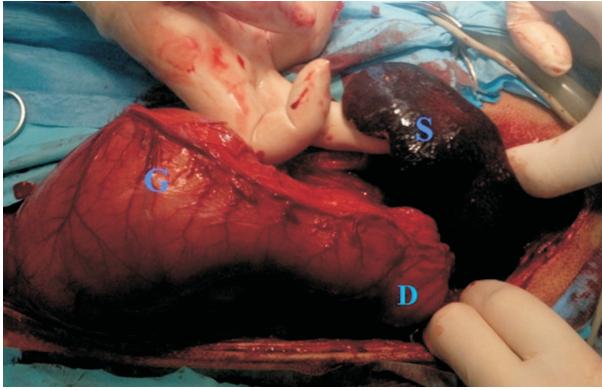


Fig. 2. Surgical procedure of herniorraphy; abdominal organs within the pericardium. A tail of the spleen (S) as well as the pyloric part of the stomach (G) with the proximal part of the duodenum (D) were found to be herniated through the diaphragmatic defect into the pericardium.

The gall bladder was enlarged. The base of the planned pericardial flap was attached at the left side of the diaphragm laterally. A stay suture was used to hold the pericardium. A part of pericardium was cut (7×7 cm) and rotated across the diaphragmatic defect on the right side. The pericardial flap was taken carefully and the mechanical ventilation stopped a few times for 30 seconds each during the pericardial incision to prevent iatrogenic lung laceration. Polypropylene mesh (Surgipro, Covidien) of the same dimension was cut (Fig. 3).

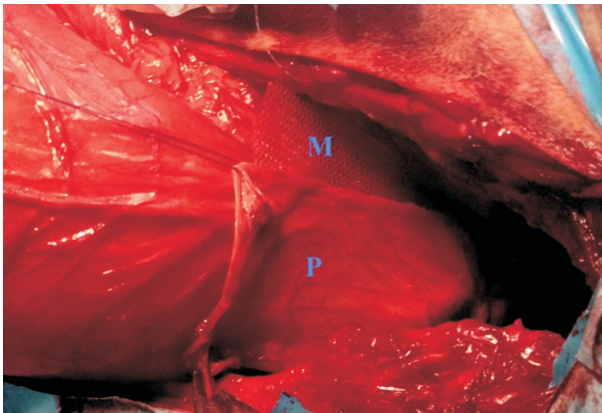


Fig. 3. Surgical procedure of herniorraphy; positioning of the pericardial flap and polypropylene mesh. Part of the pericardium (adjacent to the hernial ring) was cut, with dimensions of 7×7 centimetres, and rotated across the defect at the right side (P). A polypropylene mesh of the same dimensions was cut (M). Cranial to the right.

A diaphragmatic herniorrhaphy was performed using a simple continuous pattern with nonabsorbable suture material (Dermalon 2-0, Covidien). The pericardial flap and the polypropylene mesh were sutured to the diaphragm. The polypropylene mesh was positioned on the abdominal diaphragmatic side and the pericardial flap on the thoracic diaphragmatic side (Fig. 4).

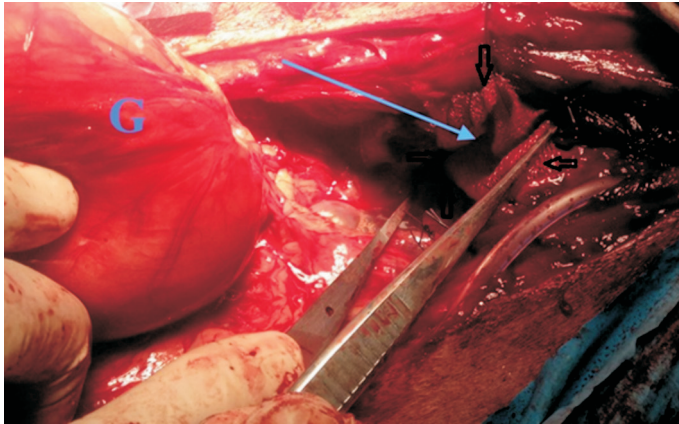


Fig. 4. Surgical procedure of herniorrhaphy. The pericardial flap and polypropylene mesh were sutured to the diaphragm. The polypropylene mesh was positioned on the abdominal diaphragmatic side (long blue arrow) and the pericardial graft on the thoracic diaphragmatic side. Stomach (G). Diaphragmatic borders (black short arrows). Cranial to the right.

A prophylactic incisional gastropexy was performed (Maxon 2-0, Covidien). The abdomen was lavaged with warm sterile saline, and closed routinely. Fentanyl was used for postoperative analgesia in a dose of 0.05 $\mu\text{g}/\text{kg}/\text{min}$ next 24 hours. A transdermal fentanyl patch (Durogesic patch, 75 $\mu\text{g}/\text{h}$, Janssen) was also used for postoperative analgesia. Meloxicam was administered in a dose 0.1 mg/kg for the first three days i/v (Meloxidolor, Genera), followed by peroral syrup. The following day, the patient had improved ambulation and was willing to eat. The owner was instructed to restrict her activity for four weeks. The signs of icterus gradually disappeared. One month after surgery, the patient had gained 1.5 kg body mass.

Discussion

In the present case, an autologous pericardial tissue and polypropylene mesh technique was used successfully as surgical treatment of a recurrent PPDH.

Most diaphragmatic defects in dogs not involving the pericardial sac are traumatic, with just occasional reports of congenital primary diaphragmatic hernia (BETH et al., 1988). On the other hand, the majority of PPDH cases are identified within the first years

of life, but a few cases have also been diagnosed after 8 years of age (EVANS and BIERY, 1980). In this case, the first clinical signs were noted after 1 year of age. The first surgery was performed when the dog was one and a half years old. The first herniorrhaphy was performed using a polypropylene mesh. Failure of the first surgery could probably be attributed to the large diaphragmatic defect, with excessive tissue tension on the margins of the hernia ring. An additional cause of herniorrhaphy failure could have been the uncontrolled activity of the dog, causing repetitive extensive tension on the hernial ring. The second surgical procedure was mandatory in order to avoid the potential risk of ventilatory impairment and strangulation of the herniated abdominal content (BURNS et al., 2013).

Animals with PPDH may have various clinical signs attributable to the types and amount of abdominal organs and tissues herniated into the thorax. The clinical signs of peritoneopericardial hernia may be absent or vary from mild to sufficiently severe to cause death, as a consequence of cardiac, respiratory, or gastrointestinal tract compromise (SCHMIEDT et al., 2009). Peritoneopericardial hernia commonly contains omentum, liver lobes, gallbladder and small intestine, as a result of the simple communication between the peritoneal and pericardial cavities. Herniation of the stomach, colon, falciform ligament, and spleen have also been reported (LIPTAK et al., 2000). Large defects in the diaphragm allow organs to pass freely into the pericardial sac, which may result in adhesions of abdominal organs to the pericardium and entrapment of the organs in the pericardium, leading to respiratory, cardiac, or gastrointestinal tract problems. However, small diaphragmatic defects may be occluded with falciform fat or omentum; therefore, animals with such defects may never have clinical signs of peritoneopericardial hernia (REIMER et al., 2004).

In this case, the pyloric part of the stomach, the proximal part of the duodenum with the common bile duct and spleen were found in the peritoneopericardial hernial sac. The icteric mucous membranes, elevated ALT and hyperbilirubinemia observed in our case were the consequence of the kinked common bile duct, due to the abnormal position of the pyloric part of the stomach and duodenum. Proximal gastrointestinal segment entrapment potentially caused nausea and vomiting due to delayed gastric emptying. The intrathoracic splenic position could have caused mesenteric tension, resulting in abdominal pain manifested by kyphosis (MINIHAN et al., 2004).

The diagnosis of the peritoneopericardial hernia is based on radiographic, ultrasonograph and surgical findings. Radiographic features typical of peritoneopericardial hernia include enlargement of the cardiac silhouette, with dorsal elevation of the trachea, overlapping of the diaphragm and the caudal aspect of the cardiac silhouette. Additionally, differential opacities or bowel within the cardiac silhouette and the presence of a dorsal peritoneopericardial mesothelial remnant extending from the caudal pericardium to the

diaphragm are noted (EVANS and BIERY, 1980; BERRY et al., 1990). In the present case, the diagnosis was obtained by contrast radiographs (barium sulphate administered per orally) since parts of the gastrointestinal organs were positioned in the thoracic cavity. An alternative method could be injecting contrast material into the abdominal cavity and following its migration into the thoracic cavity or pericardial sac (KOPER et al., 1982). We opted for the less invasive method, which confirmed the diagnosis.

Several methods of diaphragmatic herniorrhaphy had been described in veterinary medicine, such as usage of prosthetic patches (polytetrafluoroethylene, collagen coated vicryl mesh) (LALLY et al., 1996), and autologous flaps/grafts (fascia lata, flaps using the latissimus dorsi muscle, serratus muscle, internal oblique muscle and transversus abdominis muscle, pericardium) (WALLACE et al., 1992; SUZUKI et al., 2002; LIPTAK and BREBNER, 2006). Similar methods can also be used for large defects in which closure tension is a problem, and the pericardium can be transected cranially to its diaphragmatic attachments and used as a flap or free graft to close the defect (BJORLING and KEENE, 1989). In the present case, the tensile strength on the hernial ring was extensive, which could have caused disruption of the repaired hernia. Therefore, we decided to strengthen and bridge the repaired defect layers with polypropylene mesh, combined with pericardial flap.

In the first 24 hours after surgery, death may be caused by haemothorax, pneumothorax, pulmonary oedema, shock, pleural effusion, and sudden cardiac arrest. Deaths occurring later after surgery tend to be a result of rupture, obstruction, or strangulation of the gastrointestinal tract, secondary changes in the herniated organs, or diseases unrelated to hernia. Mortality may occur in up to 14% of dogs and cats undergoing surgery for PPDH (REIMER et al., 2004).

The pericardial flap is a strong fibrous tissue and its location close to the hernial ring, together with use of polypropylene mesh provided a suitable method of herniorrhaphy. We did not observe any intra- or postoperative complications in the present case, and therefore this surgery could represent a good choice for PPDH repair, especially in a case of recurrence.

References

- BELLAH, J. R., D. L. WHITTON, G. W. ELLISON, L. PHILIPS (1989): The surgical correction of concomitant cranioventral abdominal wall, caudal sternal, diaphragmatic, and pericardial defects in dogs. *J. Am. Vet. Med. Assoc.* 195, 1722-1726.
- BERRY, C. R., P. D. KOBLIK, J. W. TICER (1990): Dorsal peritoneopericardial mesothelial treatment as an aid to the diagnosis of feline congenital peritoneopericardial diaphragmatic hernia. *Vet. Radiol.* 31, 239-245.

- BETH, A. V., B. J. COOPER, A. E. DIETZE, D. M. NODEN (1988): Canine congenital diaphragmatic hernia. *J. Vet. Int. Med.* 2, 109-112.
- BURNS, G. C., M. S. BERGH, M. A. McLOUGHLIN (2013): Surgical and nonsurgical treatment of peritoneopericardial diaphragmatic hernia in dogs and cats: 58 cases (1999-2008). *J. Am. Vet. Med. Assoc.* 242, 643-650.
- BJORLING, D. E., B. W. KEENE (1989): Canine pericardial disease. *Companion Anim. Pract.* 19, 9-15.
- EVANS, S. M., D. N. BIERY (1980): Congenital peritoneopericardial diaphragmatic hernia in the dog and cat: a literature review and 17 additional case histories. *Vet. Radiol.* 21, 108-116.
- KHEIRANDISHI, R., M. SABERI, D. VOSOUGH, N. ASKARI (2014): Congenital peritoneopericardial diaphragmatic hernia in terrier dog. *Vet. Res. Forum* 5, 153-155.
- KOPER, S., M. MUNCHA, P. SILMANOWICZ, J. KARPIOSKI, T. ZIOZOT (1982): Selective abdominal angiography as a diagnostic method for diaphragmatic hernia in the dog: an experimental study. *Vet. Radiol.* 23, 50-55.
- LALLY, K. P., H. W. CHEU, W. D. VAZUEZ (1996): Prosthetic diaphragm reconstruction in the growing animals. *J. Vet. Med. Sci.* 28, 685-687.
- LIPTAK, J. M., S. A. BISSETT, G. S. ALLAN, S. ZAKI, R. MALIK (2000): Hepatic cysts incarcerated in a peritoneopericardial diaphragmatic hernia. *J. Fel. Med. Surg.* 4, 123-125.
- LIPTAK, J. M., N. S. BREBNER (2006): Hemidiaphragmatic reconstruction with a transversus abdominis muscle flap after resection of a solitary diaphragmatic mesothelioma in a dog. *J. Am. Vet. Med. Assoc.* 228, 1204-1208.
- MINIHAN, A. C., J. BERG, K. L. EVANS (2004): Chronic diaphragmatic hernia in 34 dogs and 16 cats. *J. Am. Vet. Med. Assoc.* 40, 51-63.
- REIMER, S. B., A. E. KYLES, D. E. FILIPOWICZ, R. G. CLARE (2004): Long-term outcome of cats treated conservatively or surgically for peritoneopericardial diaphragmatic hernia: 66 cases (1987-2002). *J. Am. Vet. Med. Assoc.* 224, 728-732.
- ROSENSTEIN, D. S., U. REIF, R. L. STICKLE, G. WATSON, W. SCHALL, P. AMSELLEM (2001): Radiographic diagnosis: Pericardioperitoneal diaphragmatic hernia and cholelithiasis in a dog. *Vet. Radiol. Ultrasound* 2001, 42, 308-310.
- SCHMIEDT, C. W., K. F. WASHABAUGH, D. B. RAO, R. L. STEPIEN (2009): Chylothorax associated with a congenital peritoneopericardial diaphragmatic hernia in a dog. *J. Am. Anim. Hosp. Assoc.* 45, 134-137.
- SCHULMAN, A. J., R. LUSK, C. L. LIPPINCOTT, S. J. ETTINGER (1985): Congenital peritoneopericardial diaphragmatic hernia in a dog. *J. Am. Anim. Hosp. Assoc.* 21, 655-662.
- SUZUKI, K., T. TAKAHASHI, Y. ITOU, K. ASAI, H. SHIMOTA, T. KAZUI (2002): Reconstruction of diaphragm using autologous fascia lata: an experimental study in dogs. *Ann. Thorac. Surg.* 74, 209-212.

WALLACE, J., H. S. MULLEN, M. B. LESSER (1992): A technique for surgical correction of peritoneal pericardial diaphragmatic hernia in dogs and cats. *J. Am. Anim. Hosp. Assoc.* 28, 503-510.

Received: 30 March 2017

Accepted: 3 November 2017

SMOLEC, O., D. VNUK, N. BRKLJAČA BOTTEGARO, B. TOHOLJ, M. PEĆIN, A. MUSULIN, N. DARABOŠ, J. KOS: Kirurško liječenje povratne peritoneoperikardijalne dijafragmatske kile u psa polipropilenskom mrežicom i autolognim perikardijalnim presatkom - prikaz slučaja. *Vet. arhiv* 88, 427-435, 2018.

SAŽETAK

Peritoneoperikardijalna kila jest defekt dijafragme koji dopušta prolazak abdominalnih organa u perikardijalnu vreću. Liječenje zahtijeva kirurški zahvat, herniorafiju. Nekoliko je metoda opisano u humanoj i veterinarskoj medicine, poput raznih sintetičkih materijala i mrežica, autolognih i alogernih presadaka. Svrha ovoga rada jest prikaz herniorafije u psa koja obuhvaća dva načina zatvaranja ponovljenog defekta dijafragme, polipropilenskom mrežicom i autolognim perikardijalnim presatkom. Dvije godine stara nekastrirana kuja rozezijskog goniča lavova zaprimljena je zbog povremenih respiratornih problema, kašlja i povraćanja koja su trajala 8 tjedana te letargije, gubitka tjelesne mase i žutice. Razlog primjene herniorafije bila je prevelika napetost okrajaka prstena kile uz veliku mogućnost popuštanja šava herniorafije te povratka bolesnog stanja. Kombinacija umjetnog materijala (mrežice) i autolognog presatka korištena je u svrhu ojačavanja mjesta herniorafije. Ishod zahvata ukazuje da je to prikladna metoda kirurškog liječenja povratka peritoneoperikardijalne kile, a komplikacija i povratka nije bilo.

Ključne riječi: peritoneoperikardijalna kila; kirurško liječenje; perikardijalni presadak; polipropilenska mrežica; pas
