

Adenotonsillectomy in a two-year-old boy with extremely severe obstructive sleep apnea

Zlatko Kljajić¹, Željka Roje², Petar Ivanišević¹, Kristijan Bečić³

While there is a variety of surgical and non-surgical treatment options for obstructive sleep apnoea (OSA) in adults, surgery remains the option of choice in paediatric patients due to the fact that more than 90% of childhood OSA is associated with adenotonsillar hypertrophy. Age under three years is often described as one of the most common risk factors for developing postoperative complications. The most important additional risk factor is severity of the disease as measured by polysomnography (PSG). The authors report a case of a 20-month-old boy with extremely severe OSA and a history of repeated respiratory cessation during sleep lasting for up to 30 seconds and lowest recorded saturation during PSG of 67% with the apnoea-hypopnoea index 58.43/h. As classical adenotonsillectomy is recommended only after the child has reached three years, due to the small circulating volume of the blood, several solutions were considered but, ultimately, classical 'cold steel' adenotonsillectomy was performed when the child reached two years. This case shows the importance of surgical treatment in severe cases of OSA even in very small children, despite the recommendations, due to the increased risks in neurocognitive and behavioural development.

Key words: SLEEP APNEA, OBSTRUCTIVE; CHILD

INTRODUCTION

Obstructive sleep apnoea (OSA) is characterized by increasing limitation of airflow through the upper airway, sometimes resulting in complete obstruction of the airway. According to epidemiological studies, 1% to 4% of children in the United States have OSA (1).

The criteria for OSA severity in adults are well established. On the contrary, in paediatric population, interpretation may differ from study to study. Current standards for OSA severity in children commonly define mild OSA when the obstructive apnoea-hypopnoea index (AHI) is between one and less than five events *per* hour, moderate OSA if the AHI is five to less than 10, and severe OSA when the AHI is greater than 10 (1).

Over the last decade, studies have sought to identify long-term complications associated with sleep-disordered breathing (SDB) and OSA in children.

Behavioural problems that can occur as a result of untreated OSA include hyperactivity, attention-deficit disorder, ag-

gression, and poor socialization. Neurocognitive disorders linked to OSA include poor school performance and variable learning disorders, such as deficits in memory and problem-solving skills (2).

Polysomnography (PSG) is currently considered the preferred method in the evaluation and diagnosis of OSA in children (3).

While there is a variety of surgical and non-surgical treatment options for OSA in adults, surgery remains the option of choice in paediatric patients due to the fact that more than 90% of childhood OSA is associated with adenotonsillar hypertrophy (1).

¹ University of Split, University Hospital Center Split, Department of Otorhinolaryngology, Spinčićeva 1, 21000 Split, Croatia

² Private ENT Practice dr. Željka Roje, Split, Croatia

³ University of Split, University Hospital Center Split, Spinčićeva 1, 21000 Split, Croatia

Correspondence to:

Zlatko Kljajić, MD, Split University Hospital Centre, Spinčićeva 2, HR-21000 Split, Croatia

Primljeno/Received: 30. 7. 2018., Prihvaćeno/Accepted: 5. 9. 2018.

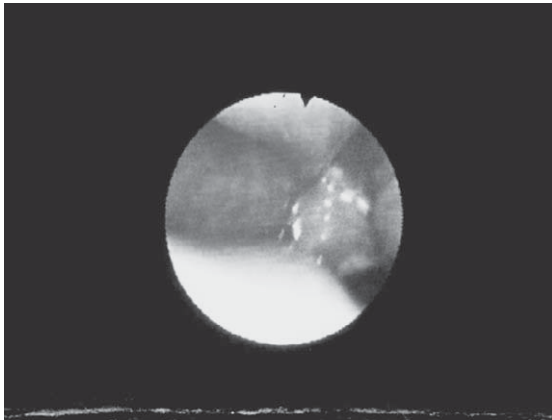


FIGURE 1. Flexibile endoscopy of the epipharynx (adenoid size- grade IV)

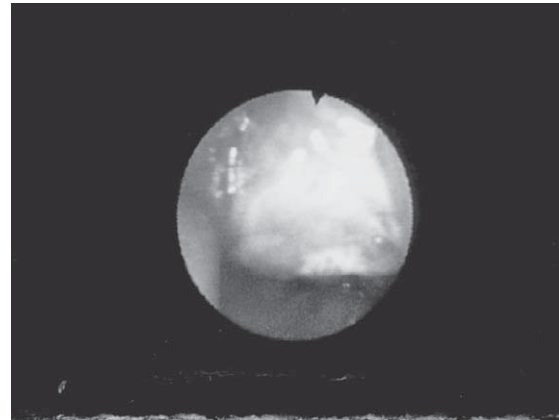


FIGURE 2. 'Kissing' tonsils during operation (grade IV).

Adenoidectomy alone for OSA is used when palatine tonsils are not enlarged. Nasal and oral steroids are often used for the treatment of snoring and OSA in children but data on this treatment modality are relatively limited. Positive airway pressure (PAP) is primarily used as adjunct therapy, especially in children that have persistent OSA after adenotonsillectomy.

Age under three years is often described as one of the most common risk factors for developing postoperative complications. Additional risk factors include severity of disease as measured by PSG, obesity, presence of medical comorbidities, and syndrome conditions affecting the central nervous and neuromuscular systems (4).

The aim of this case report is to present a 20-month-old boy with severe OSA that was successfully treated by adenotonsillectomy.

CASE REPORT

A 20-month-old Caucasian boy was presented to the ENT clinic by his parents with a history of repeated respiratory cessation during sleep lasting for up to 30 seconds. They also reported persistent, clear rhinorrhoea, and failure to thrive with poor weight gain. The patient had no known comorbidities and was born at term after uncomplicated pregnancy. Hearing was reported to be normal by the parents and the newborn hearing screening using otoacoustic emissions (OAE) was normal. There was no history of allergy or atopy.

On initial assessment, the child was found to weigh 10 kg (5th percentile) and was 85 cm in height (a little over 50th percentile) (5). He had large, hypertrophic, 'kissing' tonsils (grade IV) with modified Mallampati score III. Anterior rhinoscopy revealed clear nasal secretions, normal mucosa and no clinically significant septal deviation. Examination of the epipharynx using flexible nasendoscopy confirmed

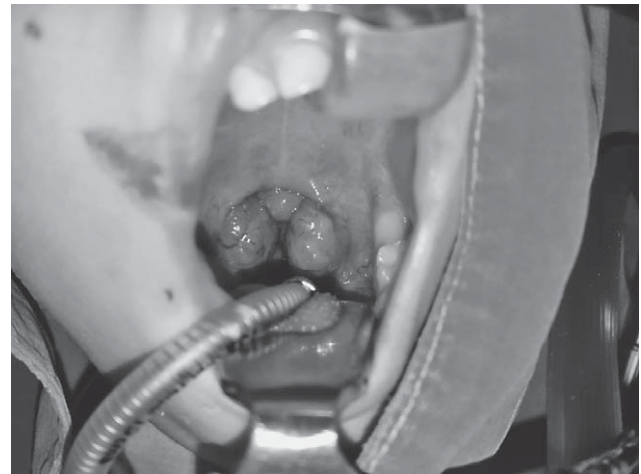

FIGURE 3. Palatine tonsils and adenoids sent for histopathologic analysis.

significant adenoid enlargement (grade IV) (6). Otoloscopic findings were unremarkable.

The patient was subsequently referred for PSG, allergy testing, and assessment by a neuro-paediatrician.

Polysomnography confirmed the diagnosis of severe OSA with AHI 58.42/h. During PSG, 70 apnoeas (40 obstructive, 22 mixed and eight central) and 390 hypopnoeas (326 obstructive and 64 mixed) were recorded. The longest obstructive hypopnoea lasted for 89 seconds with a mean oxygen saturation of 86%. The lowest recorded saturation of 67% was due to obstructive hypopnoea lasting for 10 seconds. Average O₂ saturation was 93%. Desaturation index was 60.1/h. A total of 200 awakenings, 17 related to sleep apnoea and 130 to hypopnoea were recorded. Electrocardiography (ECG) often recorded tachycardia with a maximum of 158/min. Electroencephalography (EEG) recorded no epileptogenic discharges.

Skin prick testing for inhalant and nutritive allergens, nasal swab for eosinophils, radioimmunosorbent test, radioallergosorbent test and eosinophil cationic protein were negative. Neurological assessment was completely normal for his age.

At this point, we felt that surgery would be the most appropriate intervention for this young child when reaching two years of age. Surgery was initially delayed due to an acute upper respiratory tract infection but then it was performed when the patient was 26 months old.

On the day of surgery, the child weighed 11 kg (5th percentile) and was 86 cm high (25th percentile). Laboratory findings (complete blood count, C-reactive protein) and coagulation parameters were all within the normal limits. Classical 'cold steel' adenotonsillectomy with electrocautery under general anaesthesia using an endotracheal tube was performed and the tissue was sent for histologic analysis (Figure 3). The child was observed for 24 hours in hospital following surgery with no postoperative complications noted. He was then discharged home with routine instructions and recommendations for parental care. Three postoperative appointments (7 days, 14 days and 30 days) were made.

At the first postoperative visit, the parents reported improvement in the child's sleep with what appeared to be complete resolution of the periods of apnoea. Histopathologic results showed reactive follicular hyperplasia. Control PSG was performed three months after the operation and AHI was 4.8/h with only two obstructive, one mixed and six central apnoeas. Additional PSG was performed two years after surgery with no sign of OSA (AHI was 0,7).

According to the parents, three months after the surgery, the child had no problems while sleeping, had no periods of apnoea, had good appetite and was growing well. This was confirmed on repeat anthropometry with his body weight of 14 kg (60th percentile) and height of 90 cm (40th percentile).

DISCUSSION

Due to the small volume of circulating blood, adenotonsillectomy is recommended only after the child has reached the age of three years (7). It has also been reported that the perioperative and postoperative risk of complications is significantly greater in younger children, and is therefore only performed in certain exceptional conditions (7).

We initially considered performing adenoidectomy in an attempt to at least in part resolve respiratory obstruction, with tonsillectomy postponed until the age of three years. However, this option would have subjected the child to two separate operations and general anaesthetics (8). But, considering that there is also evidence that adenotonsillectomy in children under the age of three years is not necessarily associated with a higher risk of complications, we decided to proceed as planned.

As an alternative and in discussion with neuropaediatricians, we also considered the use of continuous positive airway pressure (CPAP) as a temporizing measure. Unfortunately, the child did not tolerate the trial of CPAP and we could not use it as a reliable intervention.

Third was the option of conservative treatment (of acute respiratory infections) with regular nasal irrigation until the age of three years.

In terms of planning definitive surgical treatment, we considered two options. The first was adenoidectomy with tonsillectomy, and the other was classic adenotonsillectomy. After reviewing the literature, including a systematic review and meta-analysis showing comparable improvement in symptoms and similar safety rate between tonsillectomy and tonsillectomy in the treatment of OSA in children we decided to perform adenotonsillectomy (9). We also had more experience with traditional tonsillectomy at our institution.

As described above, both subjective and objective outcome measures were significantly improved in this young child postoperatively. Despite successful treatment, especially in view of the extremely severe OSA, there is always the possibility of adenoid regrowth and thus the necessity to inform parents of this possibility (10). In our case, there was no recurrence within the six-month follow-up period.

CONCLUSION

In this case report, we would like to emphasize the important role of surgery in the treatment of OSA even in very small children (under three years of age). Despite recommendations that such a small child is not a candidate for surgery, there are some exceptions when it has to be done, as

in this case. A child of two years old with severe OSA should not be left untreated for more than a year and a half, as it would affect his neurocognitive development in the future. It was evident that there was nothing else that we could treat (allergy, neurological conditions) but adenotonsillar hypertrophy. Considering all the risk factors (postoperative infection, dehydration, postoperative bleeding and adenoid regrowth), we decided to perform adenotonsillectomy and we strongly suggest this procedure in case of severe OSA in small children.

Abbreviations:

OSA – Obstructive sleep apnoea
 AHI – apnoea-hypopnoea index
 SDB – sleep-disordered breathing
 PSG – Polysomnography
 PAP – Positive airway pressure
 OAE – otoacoustic emissions
 ECG – Electrocardiography
 CPAP – continuous positive airway pressure

REFERENCES

1. Johnson J, ed. *Bailey's Head and Neck Surgery: Otolaryngology*. Lippincott Williams & Wilkins, Philadelphia; 2000.
2. Mitchell RB. Sleep-disordered breathing in children: are we underestimating the problem? *Eur Respir J*. 2005;25(2):216-7. doi: 10.1183/09031936.05.00124704
3. American Academy of Pediatrics, Section of Pediatric Pulmonology. Clinical Practice Guideline: diagnosis and management of childhood obstructive sleep apnea syndrome. *Pediatrics*. 2002;109(4):704-12.
4. Spencer DJ, Jones JE. Complications of adenotonsillectomy in patients younger than 3 years. *Arch Otolaryngol Head Neck Surg*. 2012 Apr;138(4):335-9. doi: 10.1001/archoto.2012.1
5. WHO Growth Standards Are Recommended for Use in the U.S. for Infants and Children 0 to 2 Years of Age. [http://www.cdc.gov/growthcharts/who_charts.htm].
6. Cassano P, Gelardi M, Cassano M, Fiorella ML, Fiorella R. Adenoid tissue rhinopharyngeal obstruction grading based on fiberoptic findings: a novel approach to therapeutic management. *Int J Pediatr Otorhinolaryngol*. 2003;67(12):1303-9.
7. Cheng J, Elden L. Outcomes in children under 12 months of age undergoing adenotonsillectomy for sleep-disordered breathing. *Laryngoscope*. 2013 Sep;123(9):2281-4. doi: 10.1002/lary.23796
8. Stipic SS, Carev M, Kardum G, Roje Z, Litre DM, Elezovic N. Are postoperative behavioural changes after adenotonsillectomy in children influenced by the type of anaesthesia? A randomised clinical study. *Eur J Anaesthesiol*. 2015 May;32(5):311-9. doi: 10.1097/EJA.000000000000104
9. Gorman D, Ogston S, Hussain SS. Improvement in symptoms of obstructive sleep apnoea in children following tonsillectomy versus tonsillotomy: a systematic review and meta-analysis. *Clin Otolaryngol*. 2016 Aug 10. doi: 10.1111/coa.12717
10. Kang KT, Weng WC, Lee CH, Lee PL, Hsu WC. Discrepancy between objective and subjective outcomes after adenotonsillectomy in children with obstructive sleep apnea syndrome. *Otolaryngol Head Neck Surg*. 2014 Jul;151(1):150-8. doi: 10.1177/0194599814529534

SAŽETAK

Adenotonzilektomija u dvogodišnjeg dječaka s vrlo teškom opstruktivnom apnejom u snu

Zlatko Kljajić, Željka Roje, Petar Ivanišević, Kristijan Bečić

Postoje razne kirurške i ne-kirurške mogućnosti liječenja opstruktivne apneje u snu (OSA) kod odraslih, dok je kod djece kirurško liječenje jedina mogućnost zbog činjenice da je više od 90% slučajeva OSA u djetinjstvu povezano s hipertrofijom adenoida i tonzila. Dob ispod tri godine često se opisuje kao jedan o najčešćih čimbenika rizika za razvoj poslijeoperacijskih komplikacija. Najvažniji dodatni rizični čimbenik je težina bolesti mjerena polisomnografijom (PSG). Opisuje se slučaj 20-mjesečnog dječaka s iznimno teškom OSA i anamnezom opetovanog prestanka disanja u snu u trajanju do 30 sekunda i najnižom zabilježenom zasićenošću tijekom PSG od 67%, uz indeks AHI od 58,43/h. Kako se zbog niskog cirkulirajućeg volumena krvi klasična adenotonzilektomija preporuča tek nakon što dijete navrš tri godine, razmatrali su se različiti pristupi, no na koncu je izvedena klasična adenotonzilektomija tehnikom "cold steel" kad je dijete navršilo dvije godine. Ovaj slučaj ukazuje na važnost kirurškog liječenja teških slučajeva OSA-e čak i kod vrlo male djece usprkos preporukama, i to zbog povećanih rizika za neurokognitivni razvoj i smetnje ponašanja.

Ključne riječi: APNEJA U SNU, OPSTRUKTIVNA; DIJETE