

Hepatotoksičnost antituberkulotika u majke i djeteta s tuberkulozom pluća – Prikaz slučaja

Hepatotoxicity of antituberculosis drugs in a mother and a child affected by pulmonary tuberculosis - A case report

Slavica Dodig, Miljenko Raos, Ivka Zoričić-Letoja

Dječja bolnica „Srebrnjak“, Zagreb Referentni centar Ministarstva zdravstva za kliničku alergologiju djece, Zagreb
Reference Center for Clinical Pediatric Allergology of the Ministry of Health and Welfare, Zagreb, Croatia

Sažetak

Cilj: Prikazati rezultate praćenja hepatotoksičnosti antituberkulotika u majke i djeteta primljenih na bolničko liječenje zbog tuberkuloze pluća.

Ispitanici i metode: Majka (23 godine) i dijete (2 godine i 4 mjeseca) liječeni su izoniazidom, rifampicinom, pirazinamidom, etambutolom, odnosno streptomycinom. U svrhu praćenja hepatotoksičnosti antituberkulotika određivana je katalitička aktivnost aspartat-aminotransferaze (AST), alanin-aminotransferaze (ALT), alkalne fosfataze (ALP), gamaglutamiltransferaze (GGT), laktat-dehidrogenaze (LD) i bilirubina.

Rezultati: U majke je najveće povećanje enzimskih aktivnosti postojalo 2. tjedna od primjene terapije: aktivnost AST bila je 34 puta, ALT 43 puta, ALP 1,2 puta, GGT 5,5 puta i LD 1,7 puta veća od gornjih referentnih granica. U djeteta je najveće povećanje enzimskih aktivnosti bilo 1. tjedna od primjene terapije: povećanje AST bilo je 28,1 puta, ALT 29,2 puta, GGT 2,5 puta i LD 3,3 puta od gornjih referentnih granica prema dobi. Nakon privremenog prekida terapije katalitička aktivnost enzima vratila se unutar referentnih granica, a terapija je postupno ponovno uvedena do pune doze. U daljnjem tijeku do izlječenja i majka i dijete dobro podnose terapiju antituberkuloticima bez povećanja enzimskih aktivnosti.

Zaključak: Izrazito povećane katalitičke aktivnosti AST i ALT u majke i djeteta tijekom liječenja antituberkuloticima ukazuju na moguću predispoziciju za pojavu teškog stupnja hepatotoksičnosti. U prvim tjednima primjene antituberkulotika aktivnost jetrenih enzima potrebno je pratiti svakih tjedan dana kako bi se otkrila njihova moguća hepatotoksičnost te terapija pravodobno evaluirala.

Ključne riječi: antituberkulotici, hepatotoksičnost, tuberkuloza, dijete

Abstract

Aim: To present results of monitoring hepatotoxicity of antituberculosis drugs in a mother and a child admitted for hospital treatment due to pulmonary tuberculosis.

Patients and methods: A mother (23 yrs) and a child (2 yrs and 4 months) were on isoniazid, rifampicin, pyrazinamide, ethambutol and streptomycin therapy. To monitor the hepatotoxicity of these antituberculosis drugs, catalytic activities of aspartate aminotransferase (AST), alanine aminotransferase (ALT), alkaline phosphatase (ALP), gamma glutamyltransferase (GGT), lactate dehydrogenase (LD) and bilirubin were determined.

Results: The highest increase in enzyme activity in the mother was recorded two weeks since the institution of therapy: AST, ALT, ALP, GGT and LD activities were 34-fold, 43-fold, 1.2-fold, 5.5-fold and 1.7-fold higher, respectively, than the upper normal values. In the child, the highest rise in enzyme activity occurred during the 1st week since the application of therapy; compared to the upper reference range values, AST, ALT, GGT and LD were 28.1-, 29.2-, 2.5- and 3.3-fold higher, respectively. After temporary discontinuation of therapy, the catalytic activity levels returned within the reference range limits, and the therapy was gradually reintroduced until full dose was achieved. During the subsequent period until recovery, both the mother and the child tolerated the antituberculosis drug therapy well, i.e. without elevation of enzyme activity.

Conclusion: Markedly elevated catalytic activities of AST and ALT in the mother and the child during antituberculosis drug therapy indicate the occurrence of a possible predisposition for severe hepatotoxicity. During initial weeks of antituberculosis drug administration, it is necessary to monitor the activity of liver enzymes every week in order to detect their possible hepatotoxicity and carry out prompt therapy evaluation.

Pristiglo: 26. lipnja 2007.

Prihvaćeno: 29. rujna 2007.

Received: June 26, 2007

Accepted: September 15, 2007

Uvod

Tuberkuloza pluća podrazumijeva upalu plućnog parenhima uzrokovanu unutarstaničnom bakterijom, mikobakterijem tuberkuloze (*My. tuberculosis*). Iako se antituberkulotici primjenjuju već 60-ak godina, tuberkuloza je i dalje vodeći uzrok smrtnosti u svijetu (1). Antituberkulotika kemoterapija može uzrokovati oštećenje jetara, kako u bolesnika s aktivnom tuberkulozom (primjenjuju se izonijazid – INH, rifampicin – RIF, pirazinamid – PZA, etambutol – EB, streptomycin – SM), tako i u osoba s latentnom tuberkuloznom infekcijom (primjenjuje se izonijazid). Hepatotoksičnost se može očitovati prolaznim asimptomatskim povećanjem katalitičkih koncentracija nekih jetrenih enzima (2), ali i pojavom hepatitisa sa smrtonosnim posljedicama (3).

Glavni lijek u terapiji i profilaksi tuberkuloze je izonijazid. U biotransformaciji izonijazida osim N-acetil transferaze (NAT) sudjeluju citokrom CYP2E1 (P450 2E1) i glutation-S-transferaza (GST) (4). Polimorfizam gena koji kodiraju spomenute enzime može utjecati na aktivnost tih enzima. Zbog povezanosti polimorfizma gena s hepatotoksičnošću izonijazida (5), u zadnje se vrijeme najviše istražuju sljedeći genotipovi: NAT2 spori acetalator (engl. *slow acetylator*), homozigotni genotip CYP2E1 (1A/1A), te homozigotni genotip GSTM1 (*null GSTM1*) (5-8), a prema rezultatima ispitivanja na životinjama čini se da je za hepatotoksičnost INH odgovoran njegov metabolit hidrazin (9).

Katalitička aktivnost aspartat-aminotransferaze (AST) može biti triput veća od gornje referentne vrijednosti kod asimptomatske hepatotoksičnosti, odnosno pet i više puta veća kod simptomatske hepatotoksičnosti (10). Prema povećanju katalitičke aktivnosti AST, hepatotoksičnost se može stupnjevati kao blaga (AST povećana manje od 5 puta), umjerena (povećanje AST 5 do 10 puta), odnosno teška (AST povećana više od 10 puta, odnosno > 500 IU/L) (2). Osim povećanja AST povremeno se može uočiti povećanje katalitičke aktivnosti alkalne fosfataze (ALP) i koncentracije bilirubina, što se pripisuje djelovanju RIF (2). Jetrena disfunkcija uzrokovana antituberkuloticima obično se očituje prvih nekoliko tjedana od početka primjene lijekova (11). U svrhu praćenja aktivnosti tuberkuloze i otkrivanja moguće hepatotoksičnosti antituberkulotika u svakodnevnoj se praksi u bolesnika svakih 14 dana određuju upalni biomarkeri te katalitička aktivnost jetrenih enzima i koncentracija bilirubina.

Ovim smo radom htjeli prikazati rezultate praćenja hepatotoksičnosti antituberkulotika u majke i djeteta liječenih zbog plućne tuberkuloze. Prema našem znanju ovo je u Hrvatskoj prvi prikaz obiteljske pojave hepatotoksičnosti kao posljedice antituberkulotiske terapije.

Key words: antituberculosis drugs, hepatotoxicity, tuberculosis, child

Introduction

Pulmonary tuberculosis implicates the inflammation of lung parenchyme caused by intracellular bacteria, *Mycobacterium tuberculosis*. Although antituberculosis drugs have been administered for about sixty years, tuberculosis has persisted as a leading cause of death worldwide (1). Antituberculosis chemotherapy may cause liver damage both in patients with active tuberculosis (isoniazid - INH, rifampicin - RIF, pyrazinamide - PZA, ethambutol - EB, streptomycin - SM are applied) and in individuals with latent tuberculosis infection (isoniazide is administered). Hepatototoxicity may manifest by transient asymptomatic increase in the catalytic concentrations of some liver enzymes (2), but also by the occurrence of hepatitis with fatal outcome (3).

The major medication in tuberculosis therapy and prophylaxis is isoniazide. In addition to N-acetyl transferase (NAT), CYP2E1 cytochrome (P450 2E1) and glutathione S-transferase (GST) are involved in isoniazid biotransformation (4). Polymorphism of the genes that encode these enzymes may affect enzyme activity. Due to the association of gene polymorphisms with isoniazid hepatotoxicity (5), the following genotypes have recently been most investigated: NAT2 slow acetylator, CYP2E1 (1A/1A) homozygous genotype, and GSTM1 (*null GSTM1*) homozygous genotype (5-8). Based on animal studies, it appears that INH hepatotoxicity is caused by its metabolite hydrazine (9).

The catalytic activity of aspartate aminotransferase (AST) may be 3-fold that of the upper normal value in symptomatic hepatotoxicity, and 5-fold or even higher in asymptomatic hepatotoxicity (10). Based on the rise in catalytic activity, AST hepatotoxicity may be graded as mild (less than 5-fold AST elevation), moderate (5-10-fold AST increase), and severe (more than 10-fold AST elevation, or > 500 IU/L) (2). Apart from AST elevation, increased catalytic activity of alkaline phosphatase (ALP) and elevated bilirubin concentration may be occasionally observed and ascribed to the action of RIF (2). Liver dysfunction due to antituberculosis drugs usually manifests during initial weeks since drug administration (11). In order to monitor tuberculosis activity and detect possible hepatotoxicity of antituberculosis drugs, biomarkers of inflammation are in routine practice determined in patients every 14 days together with catalytic activity of liver enzymes and bilirubin concentration.

In this report, we present the results of monitoring hepatotoxicity of antituberculosis drugs in a mother and a child treated for pulmonary tuberculosis. According to

Prikaz bolesnika

Majka

IK, u dobi od 23 godine, do ove bolesti nije bila teže bolesna. Besežirana je i ima ožiljak. Razboljela se mjesec dana prije prijma na bolničko liječenje uz kašalj, vrućicu u popodnevnom satima do 38,5°C, malaksalost te gubitak tjelesne mase. Kod prijma auskultacijski rijetki hropci lijevo. Rezultat tuberkulinskog kožnog testa s 2 jedinice PPD – infiltrat od 15 mm. Na radiogramu pluća uočavaju se infiltrativno-destruktivne promjene u lijevom gornjem plućnom režnju. Traheobronhoskopski nalaz pokazuje hiperemiju ušća za lijevi gornji režanj. U aspiratu bronha i u iskašljaju dokazan je mikobakterij tuberkuloze.

Terapija: INH 5 mg/kg, RIF 10 mg/kg, PZA 25 mg/kg, piridoksin (vitamin B6) 20 mg/kg.

Prije primjene antituberkulotika ubrzana je sedimentacija eritrocita (78 mm), bolesnica ima limfopeniju ($0,26 \times 10^9/L$), smanjenu koncentraciju hemoglobina (117 g/L) i željeza ($5,7 \mu\text{mol/L}$), povećanu koncentraciju CRP (65 mg/L) (tablica 1); ostali nalazi su unutar referentnih granica. Tjedan dana od početka terapije povećavaju se vrijednosti jetrenih enzima s daljnjom tendencijom porasta (tablica 1, slika 1). Indeks maksimalnog povećanja enzimskih aktivnosti zabilježen je 2. tjedna od primjene terapije (slika 2), a povećanje AST bilo je 34 puta, ALT 43 puta, ALP 1,2 puta, GGT 5,5 puta i LD 1,7 puta od gornjih referentnih granica. Istodobno je koncentracija ukupnog bilirubina iznosila $56,8 \mu\text{mol/L}$ (povećanje 2,8 puta od gornje referentne granice). Nakon prekida terapije uočava se smanjenje ispitivanih biomarkera pa se postupno uvode lijekovi u smanjenoj dozi te postupno povećanje do pune doze. U daljnjem liječenju lijekovi se dobro podnose, mikobakterij tuberkuloze uspješno se negativizira.

Dijete

MK, dijete u dobi od 2 godine i 4 mjeseca, sin bolesnice IK, ranije nije bolovalo. Besežiran je i ima ožiljak. Dva tjedna prije prijma na bolničko liječenje počinje kašljati uz vrućice u popodnevnom satima do 39 °C. Kod prijma auskultacijski normalan šum disanja. Rezultat tuberkulinskog kožnog testa s 2 jedinice PPD – bulozan infiltrat od 15 mm. Na radiogramu pluća uočava se izrazito uvećanje limfnih čvorova hilusa, atelektaza srednjeg režnja. Traheobronhoskopski nalaz pokazuje endobronhalni granulom u desnom glavnom bronhu. U želučanom soku dokazan mikobakterij tuberkuloze.

Terapija: INH 5 mg/kg, RIF 10 mg/kg, PZA 30 mg/kg, SM 20 mg/kg, piridoksin (vitamin B6) 20 mg/kg.

Prije primjene antituberkulotika ubrzana je sedimentacija eritrocita (63 mm), pacijent ima umjerenu leukocitozu ($16,86 \times 10^9/L$), limfopeniju ($0,44 \times 10^9/L$), smanjenu koncentraciju hemoglobina (101 g/L) i željeza ($2,1 \mu\text{mol/L}$), povećanu koncentraciju CRP (26,5 mg/L), IgG (14,7 g/L),

our knowledge, this is the first overview of hepatotoxicity of antituberculosis drugs in a Croatian family.

Case history

Mother

IK, 23 years old, had not been severely ill until affected by this disease. She was vaccinated and had a BCG scar. She fell ill a month before being admitted to hospital, with coughing, fever in afternoon hours reaching 38.5 °C, exhaustion, and weight loss. On admission and auscultation, rattle was heard in the left side of her chest. Tuberculin skin test with 2 tuberculin units of PPD revealed 15 mm infiltrate. Lung X-ray revealed infiltrative destructive changes in the left upper lung lobe. Tracheoscopic examination indicated hyperemia in the left upper lobe. Mycobacterium tuberculosis was detected in bronchial aspirate and sputum.

Therapy: INH 5 mg/kg, RIF 10 mg/kg, PZA 25 mg/kg, pyridoxine (vitamin B6) 20 mg/kg.

Erythrocyte sedimentation rate was increased prior to administration of antituberculosis drugs (78 mm), the patient had lymphopenia ($0.26 \times 10^9/L$), decreased concentration of hemoglobin (117 g/L) and iron ($5.7 \mu\text{mol/L}$) and increased CRP concentration (65 mg/L) (Table 1); other results were within reference ranges. A week after therapy initiation, the levels of liver enzymes increased, showing further rising tendency (Table 1, Fig. 1). Index of maximum increase in enzyme activities was recorded during the 2nd week since therapy institution (Fig. 2), and AST, ALT, ALP, GGT and LD levels were 34-, 43-, 1.2-, 5.5- and 1.7-fold those of the upper normal limits, respectively. At the same time, total bilirubin concentration was $56.8 \mu\text{mol/L}$ (2.8-fold increase compared to the upper normal limit). Upon discontinuation of therapy, decreased values for the investigated biomarkers were observed so that the drugs were gradually reintroduced in a reduced dose until reaching the full dose. The drugs were well tolerated during continued treatment, and *Mycobacterium tuberculosis* was successfully eliminated.

The child

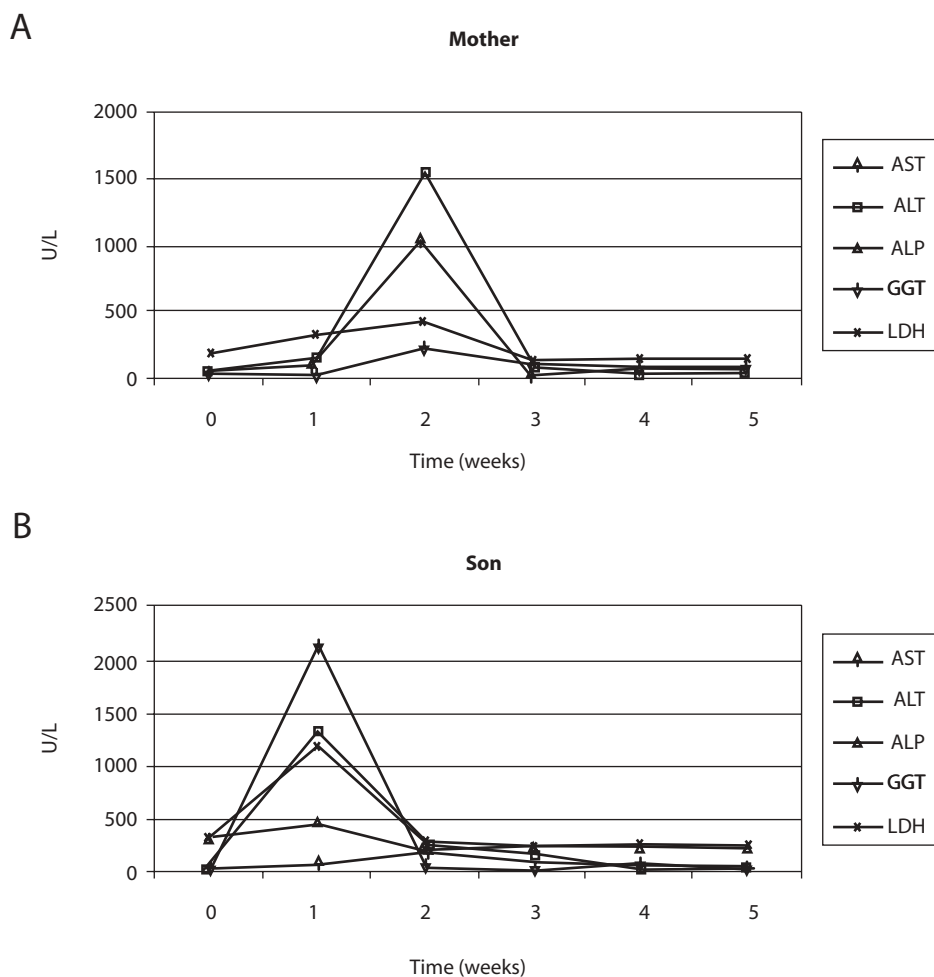
MK, a child at the age of 2 years and 4 months, the son of the patient IK, had not been ill before. He was vaccinated and had a BCG scar. Two weeks before admission for hospital treatment he had begun coughing, with fever in the afternoon hours reaching 39 °C. Normal breathing sound was detected by auscultatory examination on admission. The result of tuberculin skin test with 2 tuberculin units of PPD was 15 mm bullous infiltrate. Lung X-ray showed pronounced enlargement of the hili of lymph nodes and medium lobe atelectasis. Tracheobronchoscopy examination revealed endobronchial granuloma in the right

IgA (2,15 g/L) (tablica 1); ostali nalazi su unutar referentnih granica prema dobi. Tjedan dana od početka terapije povećavaju se katalitičke aktivnosti aminotransferaza, GGT i LD (tablica 1, slika 1). Indeks maksimalnog povećanja enzimskih aktivnosti zabilježen je 1. tjedna od primjene terapije (slika 2), a povećanje AST bilo je 28,1 puta, ALT 29,2 puta, GGT 2,5 puta i LD 3,3 puta od gornjih referentnih granica dob prema dobi. Katalitička aktivnost ALP nije se povećavala iznad referentnih vrijednosti. Istodobno je koncentracija ukupnog bilirubina iznosila 36,6 $\mu\text{mol/L}$ (povećanje 1,8 puta od gornje referentne granice). Nakon prekida terapije uočava se smanjenje ispitivanih biomarkera pa se postupno uvode lijekovi u smanjenoj dozi te postupno povećavaju do pune doze. U daljnjem liječenju lijekovi se dobro podnose, mikobakterij tuberkuloze uspješno se negativizira.

major bronchus. *Mycobacterium tuberculosis* was confirmed in the gastric fluid.

Therapy: INH 5 mg/kg, RIF 10 mg/kg, PZA 30 mg/kg, SM 20 mg/kg, pyridoxine (vitamin B₆) 20 mg/kg.

Prior to antituberculosis drug administration: erythrocyte sedimentation rate 63 mm, the patient had moderate leukocytosis ($16.86 \times 10^9/\text{L}$), lymphopenia ($0.44 \times 10^9/\text{L}$), decreased concentrations of hemoglobin (101 g/L) and iron ($2.1 \mu\text{mol/L}$), elevated CRP concentration (26.5 mg/L), IgG (14.7 g/L), IgA (2.15 g/L) (Table 1); other results were within age-adjusted reference ranges. AST, ALT, GGT and LD activities were increasing a week since the commencement of therapy (Table 1, Fig. 1). The index of maximum elevation of enzyme activities was recorded during the 1st week since therapy initiation (Fig. 2), while elevations of AST, ALT, GGT, and LD were 28.1-, 29.2-, 2.5-, and 3.3-fold those of the age-adjusted upper normal limits, respec-

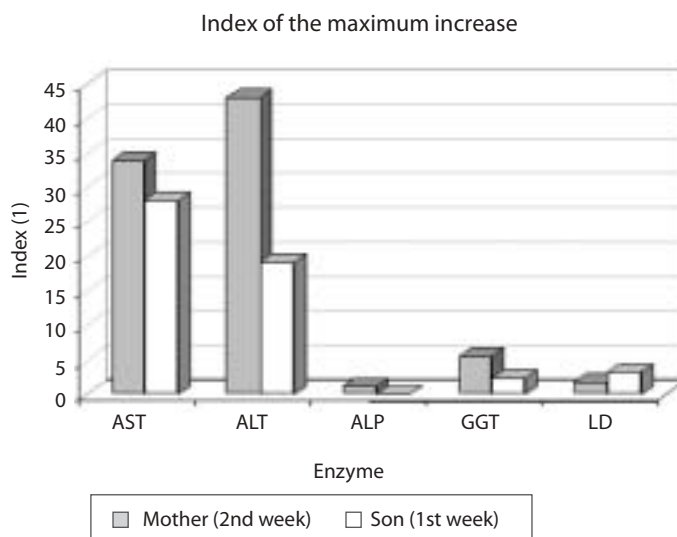


SLIKA 1. Usporedba promjena enzimskih aktivnosti u serumu majke (A) i djeteta (B). U serumu majke maksimalno povećanje očitivalo se drugog tjedna, a u serumu djeteta prvog tjedna od početka terapije.

FIGURE 1. Comparison of changes in enzyme activities in the sera of the mother (A) and the child (B). Maximum increase in the mother's serum manifested during the second week, and in the child's serum during the first week since therapy initiation.

TABLICA 1. Katalitičke aktivnosti AST, ALT, ALP, GGT i LD za vrijeme prvih 5 tjedana terapije

Week	AST (U/L)	ALT (U/L)	ALP (U/L)	GGT (U/L)	LD (U/L)
Mother					
0	19	15	67	22	201
1	163	109	90	28	310
2	1020	1547	145	194	403
3	22	81	121	89	152
4	21	19	99	73	144
5	20	18	83	60	137
Son					
0	33	20	333	16	335
1	2108	1345	450	54	1182
2	53	233	216	171	290
3	50	87	220	154	266
4	47	39	224	82	243
5	40	19	238	35	264

TABLE 1. Catalytic activities of AST, ALT, ALP, GGT and LD during first 5 weeks of therapy**SLIKA 2.** Indeks maksimalnog povećanja katalitičke aktivnosti AST, ALT, ALP, GGT i LD u serumu majke i djeteta. U serumu majke najveće povećanje aktivnosti zabilježeno je za ALT (43 puta od gornje referentne granice), a u serumu djeteta za aktivnost AST (28,1 puta od gornje referentne granice prema dobi).**FIGURE 2.** Index of the maximum increase in catalytic activity of AST, ALT, ALP, GGT and LD in the mother and son's sera. The highest activity increase in the mother's serum was observed for ALT (43-fold that of the upper normal limit), and in the child's serum for AST (28.1-fold that of the age-adjusted upper normal limit)

Rasprava

Prikazani su majka i dijete s tuberkulozom pluća kod kojih je primjena antituberkulotika na samom početku liječenja rezultirala oštećenjem jetre. Težak stupanj hepatotoksičnosti u majke i djeteta ukazuju na moguću obiteljsku predispoziciju za takav način odgovora na antituberkulotiku terapiju, o čemu u dostupnoj literaturi nismo našli podataka. Prema kriterijima Američkoga torakalnog društva i majka i dijete imali su teški stupanj hepatotoksičnosti (2). Nakon privremenog prestanka terapije te ponovnog uvođenja smanjenih pa rastućih doza lijekova do pune doze, vrijednosti ispitivanih biomarkera ostale su tijekom cijelog liječenja unutar referentnih vrijednosti.

Asimptomatsko povećanje katalitičke aktivnosti AST pojavljuje se u oko 16–20% osoba koje primaju standardnu antituberkulotiku terapiju s četiri lijeka (12,13). Pojava hepatotoksičnosti češća je u starijih osoba, u žena, osobito ako imaju teži oblik tuberkuloze (12). U ranijem prikazu hepatotoksičnosti antituberkulotika u djece utvrđeno je da je u polovine djece koja su bila na terapiji s INH, RIF i PZA postojalo povećanje katalitičkih aktivnosti jetrenih enzima, pri čemu je porast aktivnosti bio prosječno manji od 2 puta (14), što znači da je u postojao blagi stupanj hepatotoksičnosti. U većine bolesnika asimptomatsko povećanje aktivnosti aminotransferaza prolazi spontano. Ipak, ako su vrijednosti povećane više od pet puta (sa simptomima ili bez njih), odnosno više od tri puta (uz simptome) potrebno je prekinuti terapiju. Povećanje aktivnosti ALP, odnosno povećanje koncentracije bilirubina zahtijeva trenutnu evaluaciju terapije (2). Terapija se nastavlja nakon što se aktivnosti AST vrate na vrijednosti manje od dvostruke gornje referentne vrijednosti. Najprije se uvodi RIF (13), potom se nakon jednog tjedna provjerava aktivnost AST. Ako se aktivnost AST nije povećala, u terapiju se uvodi INH. Ako nakon tjedan dana nema ponovnog povećanja aktivnosti AST, u terapiju se može dodati i PZA. Slijedom toga protokola vrijednosti jetrenih enzima i bilirubina u naših bolesnika nisu se više povećavale, pa se terapija mogla primijeniti do potpunog izlječenja. Pereira i suradnici (15) su opisali pojavu jetrenih ozljeda kod primjene antituberkulotika u 5-mjesečnog dojenčeta, kod kojeg se hepatotoksičnost pojavila već petog dana od primjene INH, RIF i PZA. Corrigan i suradnici (16) opisali su u djece prosječne dobi 7,6 godina najviše dvostruko povećanje vrijednosti jetrenih enzima u drugom tjednu terapije antituberkuloticima. Ti autori smatraju da terapiju treba privremeno prekinuti samo ako se pojavi žutica, a da će se kod asimptomatskog povećanja aktivnosti enzima njihove vrijednosti vratiti spontano unutar referentnih granica i bez prekida terapije.

Može se pretpostaviti da je hepatotoksičnost u majke i djeteta uzrokovana s INH odnosno njegovim metabolitima. U dostupnoj literaturi nismo našli podataka o tako

tively. ALP values did not increase beyond normal values. At the same time, total bilirubin concentration was 36.6 $\mu\text{mol/L}$ (1.8-fold increase compared to the upper normal limit). Upon therapy discontinuation, decreased levels of the investigated biomarkers were observed so that decreased drug doses were progressively reintroduced and increased until reaching the full dose. During continued therapy, the drugs were well tolerated and *Mycobacterium tuberculosis* was effectively eliminated.

Discussion

We report of a mother and a child with pulmonary tuberculosis in whom antituberculosis drug administration at the very beginning of treatment resulted in liver damage. Severe degree of hepatotoxicity in the mother and the child indicate the presence of a possible predisposition for such response during antituberculosis drug therapy, yet we found no related information in the available literature. According to the criteria of the American Thoracic Society, both the mother and the child suffered from severe hepatotoxicity (2). After a temporary discontinuation of therapy, reintroduction of lowered and then increasing drug doses until full dose, the values of the analyzed biomarkers remained during the entire course of treatment within the reference range.

Asymptomatic elevation of the catalytic activity of AST occurs in approximately 16%–20% of individuals administered standard four-drug antituberculosis therapy (12,13). The incidence of hepatotoxicity is more frequent in elderly persons and women, particularly if they suffer from a more severe type of tuberculosis (12). In a previous report of hepatotoxicity of antituberculosis drugs in children, a rise in catalytic activity of liver enzymes was established in half of the children on INH, RIF and PZA therapy, with enzyme activity increase on average lower than twofold (14), which indicates a mild degree of hepatotoxicity. In most patients, asymptomatic elevation of aminotransferase activity resolves spontaneously. Still, if the increase in values is higher than 5-fold (with symptoms or without them), or higher than 3-fold (with symptoms), the therapy should be discontinued. An increase in ALP activity or bilirubin concentration requires immediate therapy evaluation (2). The therapy continues after AST levels return to the values that are lower than 2-fold upper normal limit. RIF therapy is reintroduced first (13), and then, after a week, AST activity is checked. If AST activity has not risen, INH is introduced in the therapy. Provided that there is no rise in AST activity after a week, PZA can also be included in the therapy. According to this protocol, the levels of liver enzymes and bilirubin did not increase any more in our patients, and the therapy could be administered until complete recovery. Pereira et al. (15) described the occurrence of hepatic lesions during administration of

teškom stupnju hepatotoksičnosti. Obično se radilo o blagom (14,16) ili umjerenom (17) stupnju hepatotoksičnosti. U djece s umjerenim oštećenjem jetre brzi acetilatori INH imali su prosječno trostruko povećanje aktivnosti AST, odnosno šesterostruko povećanje ALT; u sporih je acetilatora INH aktivnost AST bila sedam puta veća, a aktivnost ALT 18 puta veća od početnih vrijednosti (17).

Nedostatak je ovog prikaza hepatotoksičnosti to što nije ispitan polimorfizam NAT, odnosno GST i CYP2E1, što bi u budućem istraživanju trebalo učiniti. Rezultati su pokazali da je u prvim tjednima primjene antituberkulotika aktivnost jetrenih enzima potrebno pratiti tjedno, kako bi se otkrila njihova moguća hepatotoksičnost, a terapija pravedno evaluirala.

Adresa za dopisivanje:

Slavica Dodig
Dječja bolnica Srebrnjak
Srebrnjak 100
10000 Zagreb
e-pošta: slavica.dodig@zg.t-com.hr
tel: 01 6391 100
faks: 01 2430 784

Literatura/References

1. Cegielski JP, Chin DP, Espinal MA, Frieden TR, Cruz RR, Talbot EA, et al. The global tuberculosis situation. Progress and problems in the 20th century, prospects for the 21st century. *Infect Dis Clin North Am* 2002;16:1-56.
2. Treatment of Tuberculosis. American Thoracic Society, CDC, and Infectious Diseases Society of America. Recommendations and Reports. June 20, 2003. 52(RR11);1-77.
3. Israel HL, Gottlieb JE, Maddrey WC. Perspective: preventive isoniazid therapy and the liver. *Chest* 1992;101:1298-301.
4. Huang Yi-Shin. Genetic polymorphism of drug-metabolizing enzymes and the susceptibility to antituberculosis drug-induced liver injury. *Expert Opinion on Drug Metabolism and Toxicology* 2007;3:1-8.
5. Vuilleumier N, Rossier MF, Chiappe A, Dagoumois F, Dayer P, Mermillod B, et al. CYP2E1 genotype and isoniazid-induced hepatotoxicity in patients treated for latent tuberculosis. 2006;62:423-9.
6. Ohno M, Yamaguchi I, Yamamoto I, Fukuda T, Yokota S, Maekura R, et al. Slow N-acetyltransferase 2 genotype affects the incidence of isoniazid and rifampicin-induced hepatotoxicity. *Int J Tuberc Lung Dis* 2000;4:256-61.
7. Huang Y-S, Chern HD, Su WJ, Wu JC, Chang SC, Chiang CH, et al. Cytochrome P450 2E1 genotype and the susceptibility to antituberculosis drug-induced hepatitis. *Hepatology* 2003;37:924-30.
8. Huang Y-S. Genetic polymorphism of drug-metabolizing enzymes and the susceptibility to antituberculosis drug-induced liver injury. *Expert Opinion on Drug Metabolism and Toxicology* 2007;3:1-8.
9. Yue J, Peng RX, Yang J, Kong R, Liu J. CYP2E1 mediated isoniazid-induced hepatotoxicity in rats. *Acta Pharmacol Sin* 2004;25:699-704.
10. Ormerod LP. Hepatotoxicity of antituberculosis drugs. *Thorax* 1996;51:111-3.
11. Yew WW, Leung CC. Antituberculosis drugs and hepatotoxicity. *Respirology* 2006;11:699-707.

antituberculosis drugs in a 5-month-old infant in whom hepatotoxicity occurred already on day 5 after INH, RIF and PZA administration. In children with the average age of 7.6 years, Corrigan et al. (16) described maximum two-fold elevation of liver enzymes during the second week of antituberculosis drug therapy. These authors believe that the therapy should be temporarily discontinued only if jaundice occurs, and that - in case of asymptomatic elevation of enzyme activity - enzyme levels will spontaneously return to baseline values even without therapy discontinuation.

It may be assumed that hepatotoxicity in the mother and the child was caused by INH or its metabolites. We found no information in the available literature on such severe hepatotoxicity. Literature search commonly resulted in records of mild (14,16) or moderate (17) degree of hepatotoxicity. In children with moderate liver damage, INH fast acetylators demonstrated on average 3-fold increase in AST activity and 6-fold increase in ALT activity, while in INH slow acetylators AST activity was 7-fold and ALT activity was 18-fold that of the initial levels (17).

The shortcoming of this report on hepatotoxicity is the fact that NAT polymorphism and GST and CYP2E1 were not investigated, which should be done in a future study. The results demonstrated that the activity of liver enzymes should be monitored every week during initial weeks of antituberculosis drug administration in order to detect their possible hepatotoxicity and perform prompt therapy evaluation.

Corresponding author:

Slavica Dodig
Srebrnjak Children's Hospital
Srebrnjak 100
10000 Zagreb
Croatia
e-mail: slavica.dodig@zg.t-com.hr
phone: +385 1 6391 100
fax: +385 1 2430 784

12. Døssing M, Wilcke JT, Askgaard DS, Nybo B. Liver injury during antituberculosis treatment: an 11-year study. *Tuber Lung Dis* 1996;77:335-40.
13. Steele MA, Burk RF, DesPrez RM. Toxic hepatitis with isoniazid and rifampin: a meta-analysis. *Chest* 1991;99:465-71.
14. Dodig S, Medar-Lasić M, Čepelak I, Zimić L: Procjena hepatotoksičnosti antituberkulotika u dječjoj dobi. *Paediatrica Croatica* 1995;39:163-5.
15. Pereira RM, Tresoldi AT, Hessel G. Isoniazid-induced hepatic failure. Report of a case. *Arq Gastroenterol* 2000;37:72-5.
16. Corrigan D, Platon J. Hepatic enzyme abnormalities in children on triple therapy for tuberculosis. *Pediatr Pulmonol* 1999;27:37-42.
17. Dodig S, Medar-Lasić M, Zimić L, Živčić J, Čepelak I. Enzymes in serum of children characterized by fast and slow isoniazid acetylation. *Acta Pharm* 1995;45:69-74.