



Danica Vidović Juras^{1,2}, Ivana Škrinjar², Spomenka Manojlović³, Igor Blivajs⁴, Dalibor Frančeski⁵, Luka Manojlović³, Vanja Vučićević Boras^{1,2}

Case of Unrecognised of Maxillary Adenoid Cystic Carcinoma

Slučaj neprepoznatog adenoidnoga cističnog karcinoma u gornjoj čeljusti

¹ Department of Oral Medicine, School of Dental Medicine, University of Zagreb, Croatia
Zavod za oralnu medicinu Stomatološkog fakulteta Sveučilišta u Zagrebu, Hrvatska

² Dental Clinic, Clinical Hospital Center Zagreb, Croatia
Klinika za stomatologiju Kliničkoga bolničkog centra Zagreb, Hrvatska

³ Department of Pathology, Clinical Hospital Dubrava, Zagreb, Croatia
Zavod za patologiju Kliničke bolnice Dubrava, Zagreb, Hrvatska

⁴ Department of Maxillofacial Surgery, Clinical Hospital Dubrava, Zagreb, Croatia
Klinika za kirurgiju lica, čeljusti i usta Kliničke bolnice Dubrava, Zagreb, Hrvatska

⁵ Department of Radiology, Clinical Hospital Dubrava, Zagreb, Croatia
Klinički zavod za dijagnostičku i intervencijsku radiologiju Kliničke bolnice Dubrava, Zagreb, Hrvatska

Abstract

Adenoid cystic carcinoma is a less commonly diagnosed cancer that may affect the major or minor salivary glands. We present a 70 year old male patient who was admitted to the Department of Oral Medicine, School of Dental Medicine in Zagreb, Croatia due to pain in the right maxilla. In this case we report a case of the patient with unilateral pain in the maxilla & eye which lead to the diagnosis of adenoid cystic cancer without any visible oral lesions.

Received: March 28, 2018

Accepted: November 21, 2018

Address for correspondence

Ivana Škrinjar
Clinical Hospital Center Zagreb, Croatia
Dental Clinic
skrinjar.ivana@gmail.com

Key words

Carcinoma, Adenoid Cystic; Salivary Gland Neoplasms; Unilateral Pain in the Maxilla & Eye

Introduction

Adenoid cystic carcinoma is a rare malignant tumor with an incidence rate of less than 1% of all head and neck malignancies (1). It constitutes approximately 29.6% of minor salivary gland tumors (2) and affects both males and females, without any sex predilection, and usually occurs after the fifth decade of life (3). The palate is the most common site of intra-oral lesions. In the major salivary glands, adenoid cystic carcinoma most commonly affects the parotid and submandibular glands, while palate is most frequently affected in the area of minor salivary glands, followed by the floor of the mouth, tongue and lip. In some cases it can present in the jaws as a primary intraosseous tumor (4). Characteristic signs of adenoid cystic carcinoma are slow growth pattern, tendency to local recurrences, postponed appearance of the distal metastases as well as neural invasion (5). The most important prognostic factors include tumor size, grade, stage, lymph node involvement, neural invasion and margin status (6). Diagnosis is based on clinical examination, histopathological analysis of a biopsy specimen and imaging techniques.

Uvod

Adenoidni cistični karcinom rijedak je zloćudni tumor s incidencijom manjom od 1 % među svim tumorima glave i vrata (1). Čini otprilike 29,6 % tumora malih žlijezda slinovnica (2) i podjednako zahvaća muškarce i žene, bez spolne predilekcije te se uglavnom pojavljuje u dobi nakon pedeset godina (3). Unutar usne šupljine najčešće zahvaćeno mjesto jest nepce. U velikim žlijezdama slinovnicama adenoidni cistični karcinom najčešće zahvaća parotidne i submandibularne žlijezde, a na nepcu područje malih slinovnica praćeno dnom usne šupljine, jezikom i usnicom. U pojedinim slučajevima nastaje u čeljustima kao primarni intrakostani tumor (4). Karakteristični znakovi adenoidnog cističnog karcinoma su spori rast, sklonost lokalnim recidivima, odgođena pojava udaljenih metastaza te neuralna invazija (5). Najvažniji prognostički čimbenici uključuju veličinu tumora, stupanj, stadij, zahvaćenost limfnih čvorova, neuralnu invaziju i status rubova (6). Dijagnoza se temelji na kliničkom pregledu, histopatološkoj analizi biopsijskog uzorka i slikovnim tehnikama.

In this report, we present a case of sharp unilateral pain in the maxilla & eye in whom diagnosis of adenoid cystic cancer was established albeit no visible oral lesions could be seen.

Case report

A 70 year old male patient was admitted to the Department of Oral Medicine, School of Dental Medicine in Zagreb, Croatia in April 2017 due to pain in the right maxilla. In March 2016, he went to an ear, nose and throat (ENT) specialist due to pain in the right maxilla and a CT scan of the paranasal sinuses was obtained. Speckled zones of bone demineralization of the distant part of the right side of the hard palate were found. Since no soft tissue pathology could be seen, the patient was sent to MRI examination of the head which he never did. Our clinical examination revealed a mild asymmetry of the hard palate, therefore a panoramic image was taken. It showed a mass on the right side of the maxilla and the cheek (Figure 1). Furthermore, the patient was admitted to the Emergency Ophthalmology Department due to pain in the right eye. The ophthalmologist treated the patient's glaucoma and recommended the use of ultrasound for diagnostic imaging of the eye, which the patient did not perform. Six months after the first examination at our Department, he was admitted again and tumorous thickening of the right maxilla could be noticed (Figure 2). He was immediately referred to a maxillofacial surgeon and a biopsy of palatal swelling was taken. A histopathological analysis revealed a tumor of a minor salivary gland, composed of both cribriform and tubular areas of atypical cuboidal epithelial cells with foci of central necrosis within the cribriform areas. The final diagnosis was established. It was an adenoid cystic carcinoma (Figure 3).

The MSCT of the head, neck, and thorax examination was performed by standard recording techniques with 3D reconstructions. On the transitions between the head and the neck in the projection of the maxillary antrum to the right, and on the right half of the nasal cavity, a soft neoplastic heterogeneous contrast-absorbed process of about 48 mm in diameter was shown. Craniocaudal dimension of the lesion was about 70 mm with invasion into the right orbit and the middle skull to the anterior part of the cavernous sinus. A dorsal lesion went to the right half of the sphenoidal sinus (Figure 4). On both sides of the neck, in region II, more oval lymph nodes without pathology were found.

Due to the size of the lesion and structures compromised, the tumor was inoperable, therefore, the patient was treated by radiotherapy. Radiation dose was 70 Gy divided at 35 fractions. After radiotherapy, the tumor has greatly reduced its size (Figure 5).

Discussion

The differential diagnosis of aggressive intraoral lesions should, among others, consider various salivary gland tumors. In case of an aggressive lesion which involves hard palate, differential diagnoses should involve adenoid cystic carcinoma of the minor salivary glands (2). Adenoid cystic

U ovom prikazu predstavljamo slučaj bolesnika s jednostranom oštrom boli u gornjoj čeljusti i oku kojem je postavljena dijagnoza adenoidnog cističnog karcinoma, a bez promjena u usnoj šupljini.

Prikaz slučaja

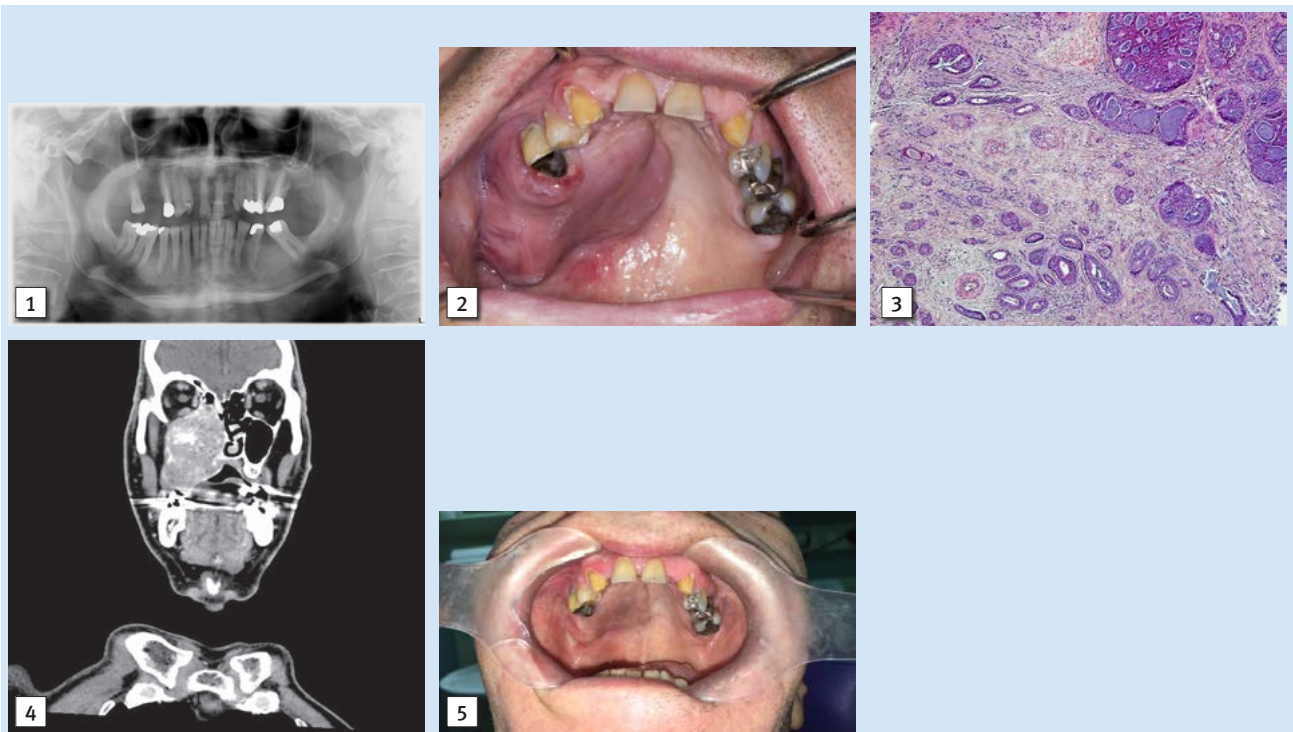
U Zavod za oralnu medicinu Stomatološkog fakulteta Sveučilišta u Zagrebu (Hrvatska) u travnju 2017. godine došao je 70-godišnjak zbog bolova u desnoj strani gornje čeljusti. U ožujku 2016. pregledao ga je otorinolaringolog zbog bolova s desne strane gornje čeljusti te je učinjen CT paranasalnih sinusa. U distalnom dijelu desne strane tvrdog nepca uočene su mrljaste zone demineralizacije kosti. S obzirom na to da na nalazu CT-a nije bilo vidljive patologije mekog tkiva, bolesnik je upućen na snimanje magnetskom rezonancijom koje nikad nije učinio. Naš klinički pregled otkrio je blagu asimetriju tvrdog nepca te je učinjen ortopantomogram (OPG). Na OPG-u bila je vidljiva masa na desnoj strani gornje čeljusti i obraza (slika 1.). Nadalje, bolesnik je hitno upućen na oftalmološki odjel zbog boli u desnom oku. Oftalmolog je liječio bolesnikov glaukom i preporučio ultrazvuk oka koji bolesnik nikad nije učinio. Šest mjeseci nakon prvog pregleda u našem zavodu, bolesnik je ponovno upućen te se uočilo tumorsko zadebljanje desne strane gornje čeljusti (slika 2.). Odmah je poslan maksilofacijalnom kirurgu te je učinjena biopsija oteklina na gornjoj čeljusti. Histopatološka analiza pokazala je tumor malih žlijezda slinovnica sastavljen od kribriformnih i tubularnih područja atipičnih kuboidalnih epitelnih stanica s jamicama središnje nekroze unutar kribriformnih područja. Postavljena je konačna dijagnoza – adenoid cističnog karcinoma (slika 3.).

Učinjen je MSCT glave, vrata i toraksa standardnim tehnikama snimanja s 3D rekonstrukcijom. Na presjecima glave i vrata u projekciji antruma maksile desno, te desne polovine nosne šupljine, vidljiv je mekotkivni neoplastični heterogeno kontrastno imbibiran proces od oko 48 mm u promjeru. Kraniokaudalna veličina lezije bila je otprilike 70 mm, s invazijom u desnu orbitu i srednju lubanjsku jamu do prednjeg dijela kavernoznog sinusa. Dorzalno se lezija pruža do desne polovine sfenoidnog sinusa (slika 4.). Na obje strane vrata u regiji II vidljivo je više ovalnih limfnih čvorova bez patoloških procesa.

Posljedično veličini lezije i kompromitiranim strukturama, tumor je bio inoperabilan te je bolesnik liječen zračenjem. Doza zračenja iznosila je 70 Gy i bila je raspodijeljena u 35 frakcija. Nakon liječenja zračenjem tumor se značajno smanjio (slika 5.).

Rasprava

Diferencijalna dijagnoza agresivnih intraoralnih lezija, između ostalog, uključuje različite tumore žlijezda slinovnica. Ako agresivna lezija obuhvaća tvrdo nepce, diferencijalna dijagnoza mora uključivati adenoidni cistični karcinom malih žlijezda slinovnica (2). Ta novotvorina sporo i podmuklo ra-



Slika 1. OPG je pokazao masu na desnoj strani gornje čeljusti

Figure 1 OPG showed a mass on the right side of the maxilla

Slika 2. Tumorsko zadebljanje na desnoj strani gornje čeljusti koje zahvaća alveolarni greben i tvrdo nepce od regije 11 do 18; na mekom nepcu mogu se uočiti teleangiektazije

Figure 2. Tumorous thickening of the right maxilla which involves alveolar ridge and the hard palate extending from the region 11 to 18. Teleangiectasia can be noticed on the soft palate.

Slika 3. Adenoidni cistični karcinom sastavljen od kribriformnih i tubularnih područja atipičnih kuboidalnih epitelnih stanica (HE x 100)

Figure 3 Adenoid cystic carcinoma composed of both cribriform and tubular areas of atypical cuboidal epithelial cells (HEx100).

Slika 4. MSCT glave i vrata; lezija na nepcu širi se u meko tkivo obraza, u desnu orbitu i prednji dio kavernoznog sinusa te u sfenoidni sinus

Figure 4 The MSCT of the head and neck. The palatal lesion extends to the soft tissue of the cheek, into the right orbit and into the anterior part of the cavernous sinus as well as into the sphenoid sinus.

Slika 5. Smanjenje tumora nakon liječenja zračenjem

Figure 5 Reduction of the tumor after radiotherapy.

carcinoma has a slow and often insidious growth pattern and most patients present at advanced stages of the disease. Based on tumor location, patients might have different signs and symptoms. Pain is a common clinical finding due to an early perineural invasion of the neoplastic cells (7). Adenoid cystic carcinoma develops frequently in minor salivary glands in comparison to the sublingual and parotid glands. Sometimes it starts as a jaw lesion (2).

It is a well known fact that the pain arising from non-dental causes might be confused as pain arising from the tooth, which leads to misdiagnosis. Park *et al.*, reported an adenoid cystic carcinoma of maxillary sinus misdiagnosed as chronic apical periodontitis (8). Therefore, pain associated to salivary gland malignant tumor may be misdiagnosed as pain from odontogenic origin.

In a recent study of 4004 periapical lesions which were diagnosed as endodontically associated pathoses, nine were found to be malignant processes, seven of which were squamous cell carcinoma, one Langerhans cell histiocytosis and one adenoid cystic carcinoma located in the mandible (9).

Perineural spread of the head and neck cancer was studied in a recent review (10). The results have shown that different types of head and neck tumors, including adenoid cystic

ste, pa većina oboljelih dolazi u napredovalim stadijima bolesti. Ovisno o mjestu tumora, bolesnici mogu imati različite znakove i simptome. Bol je čest klinički nalaz s obzirom na ranu perineuralnu invaziju neoplastičnim stanicama (7). Adenoidni cistični karcinom često se pojavljuje u malim žlijezdama slinovnicama u odnosu prema sublingvalnim i parotidnim žlijezdama. Katkad počinje kao lezija kosti (2).

Dobro je poznato da se bol koja potječe od nedentalnog uzorka može zamijeniti s boli koja potječe od zuba, što rezultira pogrešnom dijagnozom. Park i suradnici opisali su slučaj adenoidnog cističnog karcinoma maksilarnog sinusa koji je bio pogrešno dijagnosticiran kao bol koja potječe od zuba (8). Zato se bol povezana sa zloćudnim tumorom žlijezda slinovnica može pogrešno dijagnosticirati kao bol zubnog podrijetla.

U nedavnoj studiji u kojoj su praćene 4004 periapikalne lezije koje su dijagnosticirane kao endodontski povezane patoze, za devet je ustanovljeno da su zloćudni procesi od kojih su sedam bili planocelularni karcinomi, jedna histiocitoza Langerhansovih stanica i jedan adenoidni cistični karcinom smješten u donjoj čeljusti (9).

U nedavnoj studiji istraživano je perineuralno širenje karcinoma glave i vrata (10). Rezultati su pokazali da različiti

carcinoma, can result in complications involving the afferent or efferent visual system. The authors have also reported involvement of trigeminal nerve and atypical facial pain. According to these data, a strong correlation between adenoid cystic carcinoma and pain in the ophthalmic region, as was shown in our patient, could be implicated.

The patient was treated only with radiotherapy. This case report highlights the fact that although the oral cavity finding might be without any visible lesions, sharp unilateral pain might suggest underlying malignancy in the affected area as it was seen in this case.

ti tipovi tumora glave i vrata, uključujući adenoidni cistični karcinom, mogu rezultirati komplikacijama koje zahvaćaju aferentni ili eferentni vidni sustav. Autori su također zabilježili zahvaćenost trigeminalnog živca i atipičnu facijalnu bol. Prema tim podatcima, postoji snažna korelacija između adenoidnoga cističnog karcinoma i boli u oftalmičnom području, kao što je istaknuto u našem slučaju.

Bolesnik je mogao biti liječen jedino zračenjem. Ovaj prikaz slučaja ističe činjenicu da, iako usna šupljina može biti bez vidljivih lezija, oštra unilateralna bol može upućivati na podležeću zloćudnu promjenu u zahvaćenom području, kao što je bilo u ovom slučaju.

Sažetak

Adenoidni cistični karcinom rjede je dijagnosticirani tumor koji može zahvatiti velike i male žlijezde slinovnice. Prikazan je slučaj 70-godišnjeg bolesnika koji je upućen u Zavod za oralnu medicinu Stomatološkog fakulteta u Zagrebu zbog boli u desnoj strani gornje čeljusti. U ovom slučaju opisujemo kako jednostrana oštra bol u gornjoj čeljusti i oku može ukazivati na dijagnozu adenoidnog cističnog karcinoma, iako bolesnik nema u usnoj šupljini vidljivih promjena.

Zaprimljen: 28. ožujka 2018.

Prihvaćen: 21. studenoga 2018.

Adresa za dopisivanje

Ivana Škrinjar
Klinika za stomatologiju, KBC Zagreb
skrinjar.ivana@gmail.com

Ključne riječi

adenoidni cistični karcinom; tumori žlijezda slinovnica; jednostrana bol gornje čeljusti i oka

References

1. He S, Li P, Zhong Q, Hou L, Yu Z, Huang Z, et al. Clinicopathologic and prognostic factors in adenoid cystic carcinoma of head and neck minor salivary glands. A clinical analysis of 130 cases. *Am J Otolaryngol.* 2017 Mar - Apr;38(2):157-162.
2. Yaga US, Gollamudi N, Mengji AK, Besta R, Panta P, Prakash B, et al. Adenoid cystic carcinoma of the palate: case report and review of literature. *Pan Afr Med J.* 2016 May 31;24:106.
3. Andrade MF, De Faria PR, Cardoso SV, Santos MR, Dias FL, Eisenberg AL, et al. Adenoid cystic carcinoma of the maxillary sinus: a clinical-pathological report of 10 years of experience from a single institution. *Int J Oral Maxillofac Surg.* 2014 Nov;43(11):1313-8.
4. Mehta DN, Parikh SJ. Adenoid cystic carcinoma of palate. *J Nat Sci Biol Med.* 2013 Jan;4(1):249-52.
5. Ellis, GL, Auclair PL - editors. Adenoid cystic carcinoma, *Surgical Pathology of Salivary glands.* Philadelphia: WB Saunders; 1991. p. 333-46.
6. Rahmani K, Taghipour Zahir S, Baghi Yazdi M, Navabazam A. Aggressive Adenoid Cystic Carcinoma of Maxillary Sinus in a 43-Year-Old Male: Rare Case Report and Review of Literature. *Case Rep Med.* 2017;2017:2324717.
7. Ellington CL, Goodman M, Kono SA, Grist W, Wadsworth A, Chen AY, et al. Adenoid cystic carcinoma of the head and neck: incidence and survival trends based on 1973-2007 Surveillance, Epidemiology and Results data. *Cancer.* 2012 Sep 15;118(18):4444-51.
8. Park SY, Pi CY, Kim E, Lee Y. Adenoid Cystic Carcinoma of Maxillary Sinus Misdiagnosed as Chronic Apical Periodontitis. *J Oral Maxillofac Surg.* 2017 Jun;75(6):1303.e1-1303.e7.
9. Huang HY, Chen YK, KO EC, Chuang FH, Chen PH, Chen CY et al. Retrospective analysis of nonendodontic periapical lesions misdiagnosed as endodontic apical periodontitis lesions in a population of Taiwanese patients. *Clin Oral Investig.* 2017 Jul;21(6):2077-2082.
10. Abelman TB, Newman SA. Perineural Spread of Head and Neck Cancer: Ophthalmic Considerations. *J Neurol Surg B Skull Base.* 2016 Apr;77(2):131-9.