

Patent foramen ovale-management challenges: a case series

Alma Sijamija^{1*},
Nermir Granov²,
Alma Agačević¹,
Omer Perva²,
Nedžad Hadžić¹

¹Travnik General Hospital,
Travnik, Bosnia and
Herzegovina

²Clinical Center University of
Sarajevo, Sarajevo, Bosnia
and Herzegovina

KEYWORDS: patent foramen ovale, management.

CITATION: *Cardiol Croat.* 2019;14(3-4):92-3. | <https://doi.org/10.15836/ccar2019.92>

***ADDRESS FOR CORRESPONDENCE:** Alma Sijamija, J.U. Bolnica Travnik, Kalibunar bb, 72270 Travnik, Bosna and Herzegovina. / Phone: +387-61-780-085 / E-mail: alma.sijamija@hotmail.com

ORCID: Alma Sijamija, <http://orcid.org/0000-0003-2818-0501> • Nermir Granov, <http://orcid.org/0000-0002-6228-6230>
Alma Agačević, <http://orcid.org/0000-0003-4671-0991> • Omer Perva, <http://orcid.org/0000-0003-2645-1558>
Nedžad Hadžić, <http://orcid.org/0000-0002-7186-7803>

Background: Patent foramen ovale (PFO) is an anatomical interatrial communication with potential for right-to-left shunt. It is detected in 10-15% of the population by transthoracic echocardiography (TTE) and up to 27% by autopsy. Most patients with isolated PFO are asymptomatic. Patients may have a history of stroke or transient ischemic event of undefined etiology.^{1,2} The recurrence rate of stroke or TIA has been reported to be as high as 3.4-3.9% per year. In patients with atrial septal aneurysm and PFO, the risk of first recurrent stroke within 2 years has been reported to be as high as 9%, whereas the rate of subsequent stroke or TIA recurrence within 2 years increases to 22%. No consensus exists on treatment of PFO in patients with transient ischemic attack (TIA) or stroke. Traditional treatment has been antiplatelet therapy alone in low-risk patients or combined with warfarin in high-risk individuals to prevent cryptogenic stroke.^{3,4}

Case report: We represent three cases of PFO diagnosed in our hospital within past 14 months. *Case 1:* 34-year-old man hospitalized at the Neurology Department due to transient loss of consciousness. Echocardiography showed interatrial septal aneurysm, and two septal defects – subaortal, 11mm in diameter with left-to-right shunt and second one, 3mm in diameter.

There was also visible smaller thrombotic mass in left auricle. Patient underwent surgical closure. *Case 2:* 39-year-old woman presented at the routine echocardiographic examination after she was discharged from Neurology department where she was treated for stroke. Her brain MRI showed multiple ischemic infarctions with no focal deficit on neurological examination. TTE showed small PFO, 3mm in diameter with right-to-left shunt (**Figure 1**, **Figure 2**). Patient received percutaneous surgical closure. *Case 3:* 63-year-old man presented to the internist after loss of consciousness. ECG showed atrial fibrillation and TTE was subsequently performed. It showed atrial

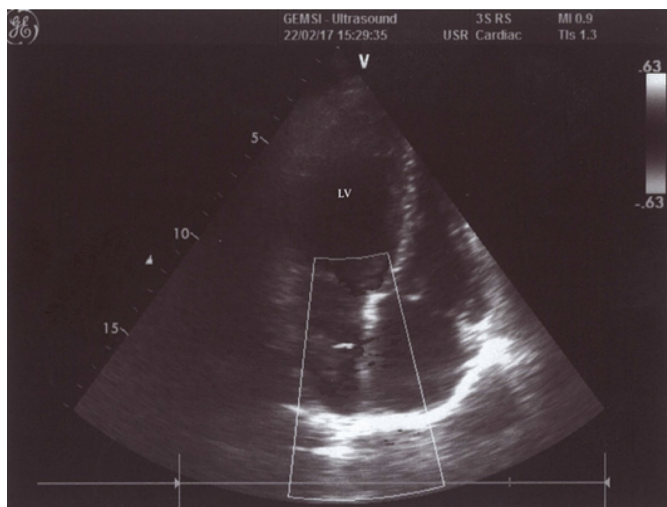


FIGURE 1. Patent foramen ovale.

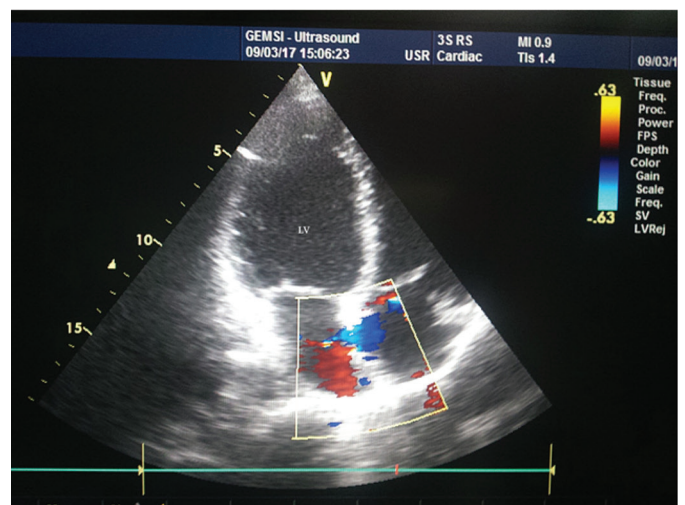


FIGURE 2. Patent foramen ovale with right-to-left shunt.

RECEIVED:
February 28, 2019

ACCEPTED:
March 24, 2019



