

Cutaneous Pseudolymphoma: A Case Report

Sandra Stanić Duktaj¹, Gaby Novak-Bilić¹, Mirna Bradamante²,
Iva Bukvić³, Liborija Lugović-Mihić^{3,4}

¹Dermatology and Venereology Unit, Zabok General Hospital, Zabok, Croatia; ²Zagreb University School of Medicine, University Department of Dermatology and Venereology, Zagreb University Hospital, Zagreb, Croatia; ³Clinical Department of Dermatovenerology, Sestre milosrdnice University Hospital Center, Zagreb, Croatia; ⁴School of Dental Medicine, University of Zagreb, Zagreb, Croatia

Corresponding author:

Professor Liborija Lugović Mihić, MD, PhD
Clinical Department of Dermatovenerology
Sestre milosrdnice University Hospital Center
Vinogradska c. 29
10000 Zagreb
Croatia
liborija@gmail.com

Received: February 6, 2018

Accepted: May 30, 2019

ABSTRACT Pseudolymphoma is a benign, reversible, inflammatory, reactive, and polyclonal lymphocyte proliferation, which regresses spontaneously or heals after elimination of the causal factor. A female patient, aged 33, presented with a painful, erythematous, radiant tumor formation on the skin in the temporal region. The patient had enlarged lymph nodes on the right side of the neck before the appearance of that tumor formation. The dermatoscopic finding was nonspecific. After the tumor biopsy was performed, the diagnosis of reactive lymphatic proliferation – pseudolymphoma or cutaneous lymphoma of B-cell immunophenotype – was established histologically. After we completely excised the skin change, the immunohistochemical finding indicated fluoride skin lymphocyte hyperplasia of B- and T-lymphocytes. The results of other findings were normal (serologic test for *Borrelia burgdorferi*, ultrasound of the cervical and supraclavicular lymph nodes, as well as ultrasound of the abdomen and axillary and inguinal regions). However, the etiology of the disease remains unknown. This case report confirms that the correlation between clinical presentation, dermatoscopic examination, histologic and immunohistochemical analysis, and the therapy response is crucial for diagnosis of pseudolymphoma and patient outcome.

KEY WORDS: pseudolymphoma, histology, immunohistochemical analysis, diagnostics

INTRODUCTION

Pseudolymphoma is a benign, reversible, inflammatory, reactive, and polyclonal lymphocyte proliferation, which regresses spontaneously or heals after the elimination of the causal factor (1,2). It refers to a heterogeneous group of T- or B-cell lymphoproliferative processes, which clinically and histologically simulate skin lymphomas. Therefore it is sometimes

hard to distinguish between them (3). Although there is no generally accepted classification, they are mostly classified by lymphocyte type as T-cell, B-cell, and combined T- and B-cell pseudolymphomas (4). T-cell pseudolymphomas encompass actinic reticuloid, lymphomatoid contact dermatitis, and lymphocytic infiltrations of skin; B-cell pseudolymphomas

encompass cutaneous lymphoid hyperplasia, inflammatory pseudotumor of the skin; combined T- and B-cell pseudolymphomas encompass lymphomatoid medication reactions (4-8). Etiologically, endogenous (genetic, immunologic) and exogenous factors (insect stings and bites, medication, vaccination, ultrasound, traumas, tattoos, acupuncture, infections, etc.) play an important role in their development (3). Clinically, they mostly appear as solitary or multiple red-purple nodules or plaques, which are most often located on the face, scalp, and torso (9). B-cell pseudolymphoma are also more common than T-cell lymphoma and they are more common in female patients (10,11).

Diagnosis is based on medical history, clinical presentation, histologic presentation, and immunophenotypic findings. With regard to T-cell pseudolymphomas, the infiltrate can be nodular or band-like, while B-cell pseudolymphomas typically present as nodular infiltrate (1-8). Generally, mixed inflammatory infiltrate (histiocytes, eosinophils, plasma cells, lymphocytes, macrophages, preserved and equally spaced out follicular dendritic cells, preserved germinal centers, and the lack of staining for BCL-2) indicate pseudolymphoma, although there are exceptions from these criteria (3,12,13). For pseudolymphomas of known etiology, removing the cause leads to spontaneous regression within 6 to 8 weeks. Regarding idiopathic cases, the clinical course is usually slow and chronic (14). The therapy of cutaneous pseudolymphoma includes complete formation excision, cryotherapy, local radiotherapy, immunomodulators such as tacrolimus, topical or intralesional use of corticosteroids, hydroxychloroquine, imiquimod, antibiotic

treatment for pseudolymphomas caused by *Borrelia burgdorferi*, subcutaneous injection of interferon alpha, and photodynamic therapy (14-19).

However, the study of literary data showed only a small number of published articles on this subject. Due to a lack of clinical experience resulting from work with patients with this disease, we present the case of our patient with pseudolymphoma.

CASE REPORT

A female patient, aged 33, was admitted to our hospital with a painful, erythematous, radiant tumor formation on the skin in the temporal region with a diameter of 0.39 inches, which had appeared 10 days before the visit (Figure 1). The patient reported enlarged lymph nodes on the right side of the neck before the appearance of that tumor formation. The tumor formation did not regress after topical corticosteroid and peroral antibiotic therapy which we initially introduced. As this was the solitary lesion on the face, differential diagnosis took into account basal cell carcinoma, clear cell acanthoma, Spitz nevus, granuloma, and lymphoma. The dermatoscopic examination was conducted during the dermatological investigation and the finding was nonspecific. A tumor formation biopsy was performed. The diagnosis of reactive lymphatic proliferation – pseudolymphoma or cutaneous lymphoma of B-cell immunophenotype – was established histologically (Figure 2). We then decided to completely excise the skin change and to send it to immunohistochemical analysis. The finding indicated fluoride skin lymphocyte hyperplasia of B- and T-lymphocytes (Figure 3, Figure 4). Immunohistochemical features revealed diffuse infiltrate of T-lymphocytes and nodular and diffuse infiltrate of B-lymphocytes

Furthermore, a serologic test for *Borrelia burgdorferi* was performed and the finding was negative.

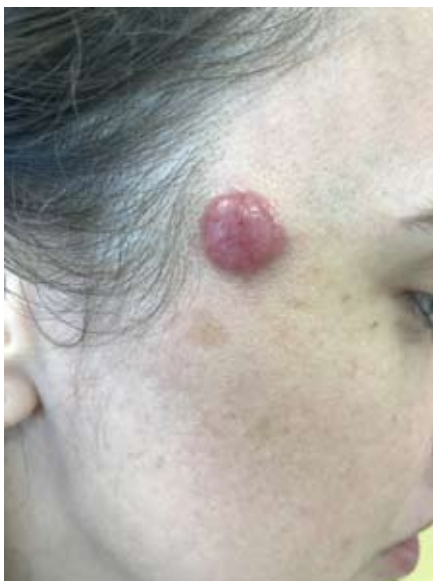

Figure 1. Clinical picture of our patient with pseudolymphoma.

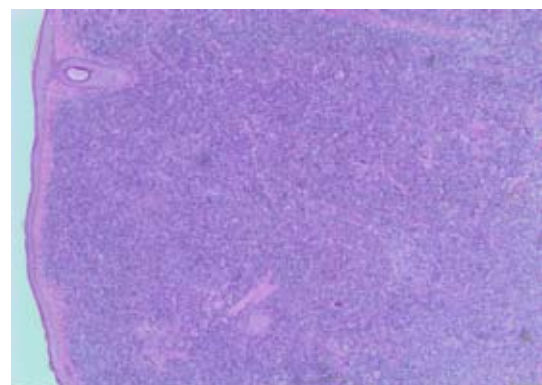


Figure 2. Histological features: normal epidermis and dense lymphoid infiltrate in the dermis (hematoxylin and eosin x20).

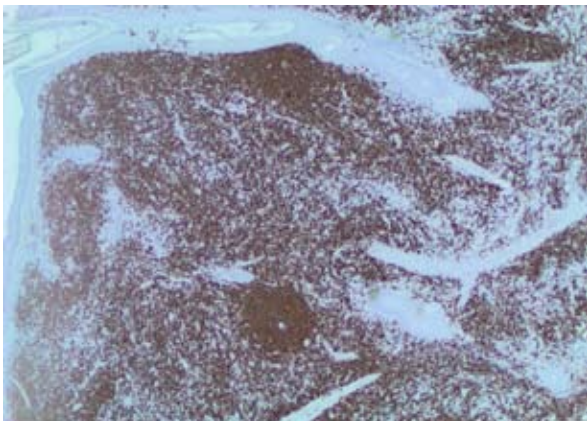


Figure 3. Immunohistochemical features: diffuse infiltrate of T-lymphocytes (immunohistochemistry CD3, original magnification $\times 40$).

Ultrasound of the cervical and supraclavicular lymph nodes showed no deviation, and neither did ultrasound of the abdomen, axillary, and inguinal regions. However, the etiology remains unknown because the patient denied the presence of potential etiological factor during the relevant timeframe (insect sting or bite, taking medications, injections, contact with physio-chemical factors).

A control examination after 3 months showed that scar cicatrized in an orderly manner, with no signs of recurrence and without appearance of new tumor formations.

DISCUSSION

Although pseudolymphomas can manifest as a broad spectrum of clinical presentations, timely identification of pseudolymphoma is of major importance, so it is necessary to perform the appropriate tests in order to establish a definite diagnosis (11). Even though there are some possible classifications of this group of diseases mentioned above, none of them have yet been clearly accepted. According to recent literature data, 4 main groups of cutaneous pseudolymphomas can be distinguished based on clinical and/or histologic presentation: nodular pseudolymphomas, pseudo-mycosis fungoides, other pseudolymphomas (representing distinct clinical entities), and intravascular pseudolymphomas (1). When considering the diagnosis of the skin pseudolymphoma and for differentiation between skin lymphomas, the most important is the correlation between the clinical presentation and the pathohistological findings. In our case there was a sharply delineated skin tumor formation in the temporal right region with a diameter of 0.39 inches, which did not regress after topical corticosteroids and peroral antibiotic therapy. We

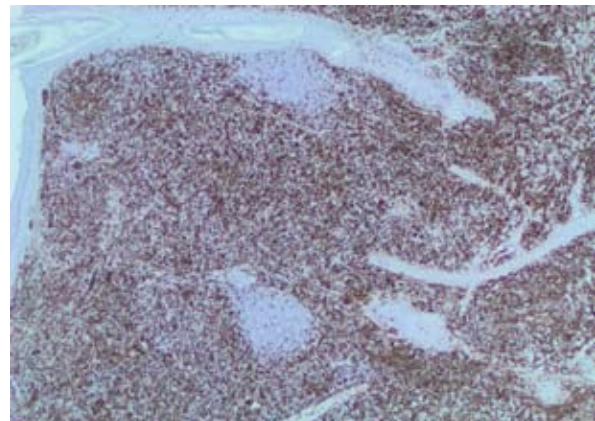


Figure 4. Immunohistochemical features: nodular and diffuse infiltrate of B-lymphocytes (immunohistochemistry CD20, original magnification $\times 40$).

therefore initially decided to perform a biopsy and afterwards tumor excision, which produced the histologic and immunohistochemical findings that were crucial for establishing the definite diagnosis (20,21).

Cutaneous pseudolymphoma affects all age groups; the pseudolymphoma caused by *B. burgdorferi* is more common in children and younger persons, whereas T-cell pseudolymphoma caused by medications is more common in adults (22). The pseudolymphoma induced by *B. burgdorferi* is mostly a self-limiting reversible lesion but can be the precursor of B-cell lymphoma, and its diagnosis is more common where lymphocytic infiltration of the skin was the initial suspected diagnosis (23,24). Research also showed that *B. burgdorferi*-associated pseudolymphoma can present with misleading histopathologic, immunophenotypic, and molecular features, which indicates that integration of all data is necessary for a correct diagnosis (23).

Given the diagnostics, significant progress has been made in histological classification, immunohistochemistry, and in molecular analysis of pseudolymphoma, which has enabled the establishment of more precise diagnosis. However, in some patients it is not possible to clearly differentiate between pseudolymphoma and lymphoma, which represents a serious problem. Furthermore, pseudolymphoma can progress into cutaneous lymphoma if there is a persistent antigenic stimulation, indicating the importance of clinicopathological monitoring (3,25). Since clinically benign inflammatory lesions sometimes look like a malignancy, further monitoring is necessary to distinguish between a benign/inflammatory/malignant lesions. This in turn influences the treatment plan and prognosis (26-28). Because of this lack of markers that can help predict the pseudolymphoma course and

lymphoma occurrence, patients should be monitored for the rest of their life (29). Furthermore, monitoring is especially necessary in idiopathic pseudolymphoma cases in order to discover any suspected tumor changes on time. Though therapy is mostly directed at controlling symptoms or minimizing recurrence frequency, none of the available treatment options disrupt the natural history of pseudolymphoma or reduce the risk of developing an associated lymphoma (29).

CONCLUSION

Pseudolymphoma encompasses a broad spectrum of various subtypes of diseases which have completely different presentations, etiology, and therapy. We hope that our pseudolymphoma case report, as well as other similar cases, can contribute to resolving future clinical dilemmas concerning this diagnosis.

References:

1. Mitteldorf C, Kempf W. Cutaneous pseudolymphoma. *Surg Pathol Clin*. 2017;10:455-76.
2. Hussein MR. Cutaneous pseudolymphomas: inflammatory reactive proliferations. *Expert Rev Hematol*. 2013;6:713-33.
3. Bergman R. Pseudolymphoma and cutaneous lymphoma: facts and controversies. *Clin Dermatol*. 2010;28:568-74.
4. Sander CA. Pseudolymphomas. In: Braun-Falco O, Burgdorf WHC, Plewig G, Wolff HH, Landthaler M. eds. *Braun Falco's Dermatology*. 5th ed. Heidelberg: Springer Medizin Verlag; 2009. pp. 1472-7.
5. Engin B, Songür A, Kutlubay Z, Serdaroğlu S. Lymphocytic infiltrations of face. *Clin Dermatol*. 2014;32:101-8.
6. Magro CM, Daniels BH, Crowson AN. Drug induced pseudolymphoma. *Semin Diagn Pathol*. 2018;35:247-59.
7. Miguel D, Peckruhn M, Elsner P. Treatment of cutaneous pseudolymphoma: a systematic review. *Acta Derm Venereol*. 2018;13:98:310-7.
8. Lugović-Mihić L, Duvančić T, Šitum M, Mihić J, Krolo I. Actinic reticuloid – photosensitivity or pseudolymphoma? *Coll Antropol* 2011;35(Suppl 2):325-9.
9. Nnebe NV, Woon C, Haines S, Dayton V, Weigel BJ. Cutaneous pseudolymphoma: an unusual presentation of a scalp mass. *Pediatr Blood Cancer*. 2009;52:283-5.
10. Kerl H, Ackerman AB. Inflammatory diseases that simulate lymphomas: Cutaneous pseudolymphomas. In: Fitzpatrick TB, Eisen AZ, Wolff K, Freedberg IM, Austen KF, eds. *Dermatology in general medicine*. 4th ed. New York: McGraw-Hill; 1993. pp.1315-27.
11. Laftah Z, Benton E, Bhargava K, Ross J, Millard T, Craig P, *et al.* Two cases of bilateral earlobe cutaneous pseudolymphoma. *Br J Dermatol*. 2014;171:1567-70.
12. Raymond L. Lymphoid, leucemic and other cellular infiltrates. In: Barnhill RL, eds. *Barnhill dermatopathology*. USA: McGraw Hill; 2010. pp. 928-35.
13. Houston M. Cutaneous infiltrates lymphomytous and leucemic. In: Weedon D, ed. *Weedon's skin pathology*. Australia: Elsevier; 2010. pp. 1000-12.
14. Tomar S, Stoll HL, Grassi MA, Cheney R. Treatment of cutaneous pseudolymphoma with interferon alfa-2b. *J Am Acad Dermatol*. 2009;60:172-4.
15. El-Dars LD, Statham BN, Blackford S, Williams N. Lymphocytoma cutis treated with topical tacrolimus. *Clin Exp Dermatol*. 2005;30:305-7.
16. Stoll DM. Treatment of cutaneous pseudolymphoma with hydroxychloroquine. *J Am Acad Dermatol*. 1983;8:696-9.
17. Braumgartner-Nielsen J, Lorentzen H. Imiquimod 5%: a successful treatment for pseudolymphoma. *Acta Derm Venerol*. 2014;94:469.
18. Singletary HL, Selim MA, Olsen E. Subcutaneous interferon alfa for the treatment of cutaneous pseudolymphoma. *Arch Dermatol*. 2012;148:572-4.
19. Mikasa K, Watanabe D, Kondo C, Tamada Y, Matsumoto Y. Topical 5-aminolevulinic acid-based photodynamic therapy for the treatment of a patient with cutaneous pseudolymphoma. *J Am Acad Dermatol*. 2005;53:911-2.
20. Kale TP, Singh AG, Shah P. Lymphocytoma cutis: diagnostic enigma for the maxillofacial surgeon. *J Korean Assoc Oral Maxillofac Surg*. 2016;42:379-82.
21. Romero-Pérez D, Blanes Martínez M, Encabo-Durán B. Cutaneous pseudolymphomas. *Actas Dermosifiliogr*. 2016;107:640-51.
22. Terada T. Cutaneous pseudolymphoma: a case report with an immunohistochemical study. *Int J Clin Exp Pathol*. 2013;6:966-72.
23. Colli C, Leinweber B, Müllegger R, Chott A, Kerl H, Cerroni L. *Borrelia burgdorferi*-associated lymphocytoma cutis: clinicopathologic, immunophenotypic, and molecular study of 106 cases. *J Cutan Pathol*. 2004;31:232-40.
24. Ziemer M, Eisendle K, Müller H, Zelger B. Lymphocytic infiltration of the skin (Jessner-Kanof) but

- not reticular erythematous mucinosis occasionally represents clinical manifestations of Borrelia-associated pseudolymphoma. *Br J Dermatol.* 2009;161:583-90.
25. Geller S, Markova A, Pulitzer M, Myskowski PL. Acral angiokeratoma-like pseudolymphoma in a middle-aged woman. *J Cutan Pathol.* 2017;44:878-81.
26. Shetty SK, Hegde U, Jagadish L, Shetty C. Pseudolymphoma versus lymphoma: An important diagnostic decision. *J Oral Maxillofac Pathol.* 2016;20:328.
27. Novak-Bilić G, Vučić M, Japundžić I, Meštrović-Štefekov J, Stanić Duktaj S, Lugović-Mihić L. Irritant and allergic contact dermatitis-skin lesion characteristics. *Acta Clin Croat.* 2018;57:713-20.
28. Radoš J, Jerković Gulin S, Dotlić S, Bašić Kinda S, Čeović R. Folliculotropic mycosis fungoides associated with autoimmune hepatitis. *Acta Dermatovenerol Croat.* 2017;25:248-50.
29. Balić A, Bartolić L, Ilić I, Radoš J. Long-term follow-up of a case of lymphomatoid papulosis with a benign course. *Acta Dermatovenerol Croat.* 2018;26:264-6.