

THE IMPLANTATION OF SINGLE-PIECE INTRAOCULAR LENS WITH BLUE-LIGHT FILTER

Robert Stanić, Igor Žuljan, Kajo Bućan, Milan Ivanišević and Željko Kovačić

University Department of Ophthalmology, Split University Hospital Center, Split, Croatia

SUMMARY – The aim of the study was to evaluate intraoperative and postoperative performance of the single-piece intraocular lens with blue light filter after cataract phacoemulsification. This prospective study included 18 patients (18 eyes) undergoing operation and implantation of a single-piece AcrySof SN60AT foldable acrylic lens (Alcon, Forth Worth, TX, USA) between December 2005 and February 2006. Intraocular lens (IOL) folding, operative and postoperative complications, easiness of IOL implantation through a 3.2-mm incision, haptic flexibility, IOL centration in the capsular bag, visual acuity, posterior capsular opacification and color test were analyzed. Lens folding was easy in all cases. In three cases, the leading haptic did not pass easy through the incision, but unfolding was also easy. After six months, the best corrected visual acuity was 0.85 (Snellen chart), which correlated with the preexisting posterior segment pathology. Color perception was not affected in patients without ocular pathology. Accordingly, implantation of the single-piece AcrySof Natural IOL was found to be easy. The implantation was the same as in other types of foldable lenses and there was no impairment of color perception or visual acuity.

Key words: *Lenses – intraocular; sight prosthesis fitting; Lens implantation – intraocular; Phacoemulsification; Biocompatible materials*

Introduction

The three-piece AcrySof MA30BA intraocular lens (IOL) was the first type of lens with several advantages over polymethyl methacrylate (PMMA) and silicone IOLs. The advantages included lower ratio of posterior capsular opacification (PCO) and lower inflammatory reaction on IOL surface^{1,4}. The AcrySof SA30AL single-piece IOL was designed to reduce PCO and increase biocompatibility^{3,5}. Human crystalline lens filters ultraviolet (UV) light rays and shorter wavelengths of blue light in the visible light spectrum, and protects retina from visible radiation⁶. The AcrySof Natural SN60AT IOL is designed to approximate the light filtering characteristics of the adult natural crystalline lens. The

AcrySof SN60AT is identical to AcrySof single-piece IOL except for the addition of the blue light chromophore to the IOL material⁷.

In this study we evaluated intraoperative and postoperative performance of the AcrySof Natural SN60AT IOL in 18 patients undergoing phacoemulsification and IOL implantation.

Patients and Methods

This prospective study included 18 patients (ten female and eight male; 18 eyes) operated on from December 2005 to February 2006. In all cases, a single-piece AcrySof Natural SN60AT lens was implanted. The mean age of study patients was 64 ± 9.7 (range 55-78) years. Two patients had nonproliferative diabetic retinopathy and two had age related macular degeneration (ARMD). There were 14 patients without ocular or systemic disease.

Surgery was performed under topical anesthesia. Maximum mydriasis was achieved by combining phe-

Correspondence to: *Robert Stanić, MD*, University Department of Ophthalmology, Split University Hospital Center, Spinčićeva 1, HR-21000 Split, Croatia
Received February 5, 2007, accepted in revised form December 10, 2007

nylephrine 10% with tropicamide 1.0% drops. Clear corneal incision was made with a 3.2-mm knife at 12 o'clock position. Hyaluronate sodium (Viscoat) was injected to protect corneal endothelium cells in the anterior chamber of the eye. Capsulorrhexis was performed with a 26-gauge needle. The phaco-chop technique was employed by using an Alcon Legacy machine in all cases. The settings were: power 60 U/S, flow 35-40 mL/min, vacuum 400 mmHg. We used a universal folder and holder for IOL insertion. The IOL was implanted through the 3.2-mm wound, which was not sutured.

Follow up assessment was made at 1 day, 1 week, 1 month, 3 months and 6 months, and included IOL folding and unfolding, centration in the capsular bag, intraoperative and postoperative complications, visual acuity, PCO and color perception.

Results

In all cases, the AcrySof Natural was easily folded, inserted and unfolded at room temperature. We used minimal force to fold the lense longitudinally, and in three cases the leading haptic did not pass easily through the incision because of its extreme flexibility, and the edge of the incision had to be elevated. Unfolding was controlled as well as the optics and haptics of the lens. Centration in the capsular bag was excellent. The lens was well visible during folding owing to its yellow tinting (Fig. 1).

There were no operative complications. In two cases, mild corneal edema developed postoperatively and resolved on topical steroids in a few days.

The mean best corrected visual acuity (BCVA) on day 1 after surgery was 0.4 (range 0.2-0.6; Snellen chart).

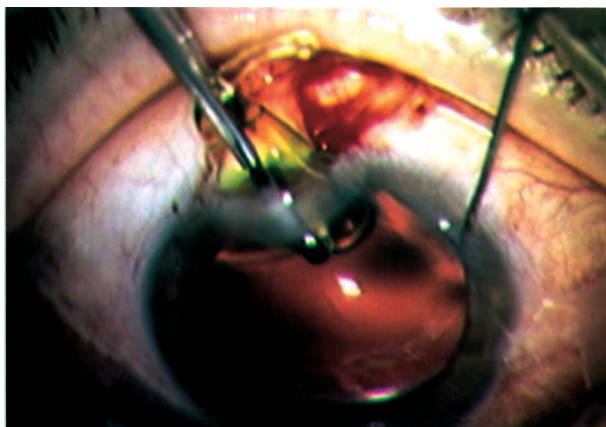


Fig. 1. Mean postoperative best corrected visual acuity.

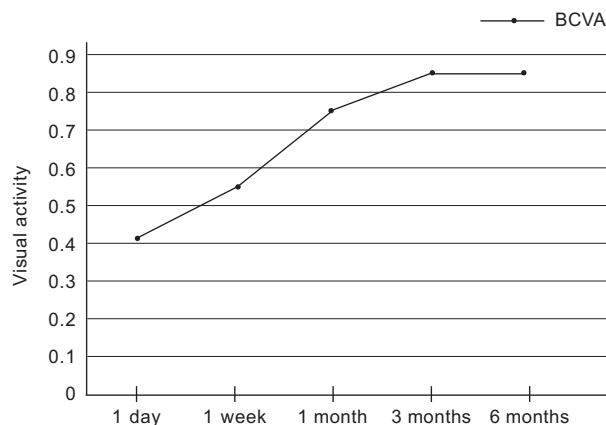


Fig. 2. Intraoperative view of the AcrySof Natural SN60AT intraocular lens implantation.

At one week it was 0.6 (range 0.3-0.8), at one month 0.75, at three months 0.85, and at six months 0.3 in three patients, 0.7 in one patient, 0.9 in two patients, and 1.0 in 12 patients, mean 0.85 (Fig. 2).

There was no PCO at six months. We did not observe any progression of diabetic retinopathy in patients with diabetes mellitus six months of the operation. Three months of the operation, 12 patients without ocular disease passed the Ishihara color test. The patients with diabetic retinopathy and ARMD were excluded from testing.

Discussion

The AcrySof Natural IOL was implanted without any complications in the capsular bag through the 3.2-mm corneal incision. The lens was extremely resilient and flexible allowing to be folded without any damage to the optics and haptics. We used a universal holder and folder, and there were no scratches or marks on the lens surface. Forceps to avoid grasping the center of the optic when folding have been recommended⁸. Low pressure was needed to fold the lens. The lens was well centered in the capsular bag; there was no decentration of the lens.

Nejima *et al.*⁹ report that single- and three-piece acrylic foldable IOLs are equally stable in the capsular bag. Davidson¹⁰ compared two types of single-piece acrylic IOL (SA30AL and SA60AT), and found that decentration was no greater than 1.0 mm nine months after surgery than it was on the day of surgery in either optic centration group.

The lower rate of PCO has been reported with the acrylic lens¹¹. PCO rates for acrylic lenses have been shown to range from 9.3% to 11.75% in two years^{11,12}. Mian *et al.*¹³ report the rates of Nd-YAG capsulotomy with one-piece IOL (SA30AL/SA60AT) of 2.1% at six months. In our patients, there was no PCO at six months.

Six months after surgery the best corrected visual acuity in 12 patients without preexisting pathology was 1.0 (86%). Only one of four patients with preexisting pathology achieved 0.7. These results were similar to those reported by Leibovich *et al.*¹⁴. In their study, the best corrected postoperative visual acuity at six months was 1.0 in 89% of the eyes with SN60 IOL.

In patients with diabetic retinopathy, we did not observe progression of retinopathy at six months of the operation. Romero-Aroca *et al.*¹⁵ report that phacoemulsification of the one diabetic eye compared to the fellow nonoperated eye showed no difference in the progression of diabetic retinopathy and macular edema, so uneventful phacoemulsification may not cause diabetic retinopathy progression.

Color perception was not affected in patients without ocular pathology. They all passed the Ishihara color test monocularly because the fellow eye was affected with age related cataract. We interviewed them about experiencing any problems with color vision before they had developed cataract. Marshall *et al.*¹⁶ report that no significant differences were recorded between AcrySof Natural and conventional AcrySof single-piece IOL in the proportion of patients that passed the color perception test. AcrySof Natural IOL protects the retina against UV light increase contrast sensitivity without affecting color perception^{14,17}.

Conclusion

The implantation of single-piece AcrySof Natural IOL was easy, without any damage to the optics and haptics. The implantation was the same as in other types of foldable lenses. It protects retina from UV light without disturbance of color perception and visual acuity. We need longer follow up to confirm the benefits of retinal protection and prevention of PCO.

References

- HAYASHI H, HAYASHI K, NAKAO F, HAYASHI F. Quantitative comparison of posterior capsule opacification after polymethylmethacrylate, silicone and acrylic intraocular lens implantation. *Arch Ophthalmol* 1998; 116:1579-82.
- AUFARRTH GU, BREZIN A, CAPOROSSI A, LAFUMA A, MENDICUTE J, BERDEAUX G, SMITH AF; European PCO Study Group. Comparison of Nd:YAG capsulotomy rates following phacoemulsification with implantation of PMMA, silicone, or acrylic intraocular lenses in four European countries. *Ophthalmic Epidemiol* 2004;11:319-29.
- OSHIKA T, SUZUKI Y, KIZAKI H, YAGUCHI S. Two year clinical study of a soft acrylic intraocular lens. *J Cataract Refract Surg* 1996;22:104-9.
- HOLLICK EJ, SPALATON DJ, URSELL PG, PANDE MV. Biocompatibility of poly(methylmethacrylate), silicone, and AcrySof intraocular lenses: randomized comparison of the cellular reaction on the anterior lens surface. *J Cataract Refract Surg* 1998;24:361-6.
- CAPOROSSI A, CASPINI F, TOSI GM, BAIOCCHI S. Preliminary results of cataract extraction with implantation of a single-piece AcrySof intraocular lens. *J Cataract Refract Surg* 2002;28:652-5.
- LEMAN S, BORKMAN R. Spectroscopic evaluation of classification of the normal aging and cataractous lens. *Ophthalmic Res* 1976;8:335-53.
- SPARROW JR, MILLER AS, ZHOU J. Blue light absorbing intraocular lens and retinal pigment epithelium protection *in vitro*. *J Cataract Refract Surg* 2004;30:873-8.
- MILLAZO S, TURU TP, BLIN H. Alteration to the AcrySof intraocular lens during folding. *J Cataract Refract Surg* 1996;22(Suppl 2):1351-4.
- NEJIMA R, MIYATA K, HONBOU M, TOKUNAGA T, TANABE T, SATO M, OSHIKA T. A prospective, randomised comparison of single- and three-piece foldable intraocular lens. *Br J Ophthalmol* 2004;88:746-9.
- DAVIDSON JA. Clinical performance of Alcon SA30AL and SA60AT single-piece acrylic intraocular lenses. *J Cataract Refract Surg* 2002;28:1112-23.
- URSELL PG, SPALATON DJ, PANDE MV, HOLLICK EJ, BARMAN S, BOYOCE J, TILLING K. Relationship between intraocular lens biomaterials and posterior capsule opacification. *J Cataract Refract Surg* 1998;24:352-60.
- MANGUAL E, GARCIA J, ELVIRA JC, HUESO JR. Clinical results of AcrySof intraocular lens implantation. *J Cataract Refract Surg* 1998;24:114-7.
- MIAN SI, FAHIM K, MARCOVITCH A, GADA H, MUSCH DC, SUGAR A. Nd:YAG capsulotomy rates after use of the AcrySof acrylic three-piece and one-piece intraocular lenses. *Br J Ophthalmol* 2005;89:1389-90.
- LEIBOVITCH I, LAI T, PORTER N, PIETRIS G, NEWLAND H, SELVA D. Visual outcomes with the yellow intraocular lens. *Acta Ophthalmol Scand* 2006;84:95-9.
- ROMERO-AROCA P, FERNANDEZ-BALLART J, ALMENA-GARCIA M, MENDEZ-MARIN I, SALVAT-SERRA M, BUIL-CALVO JA. Nonproliferative diabetic

- ic retinopathy and macular edema progression after phacoemulsification: prospective study. *J Cataract Refract Surg* 2006;32:1438-44.
16. MARSHALL J, CIONNI RJ, DAVISON J, ERNEST P, LEHMANN, MAXWELL A, SOLOMON K. Clinical results of the blue-light filtering AcrySof natural foldable acrylic intraocular lens. *J Cataract Refract Surg* 2005;31:2319-23.
17. RODRIGEZ-GALIETERO A, MONTES-MICO R, MUNOZ G, ALBARRAN-DIEGO C. Comparison of contrast sensitivity and color discrimination after clear and yellow intraocular lens implantation. *J Cataract Refract Surg* 2005;31:1736-40.

Sažetak

UGRADNJA JEDNODIJELNE INTRAOKULARNE LEĆE S FILTROM ZA PLAVO SVJETLO

R. Stanić, I. Žuljan, K. Bućan, M. Ivanišević i Ž. Kovačić

Cilj rada bio je ispitati intraoperacijske i poslijeoperacijske značajke kod ugradnje jednodijelne intraokularne leće s filtrom za plavo svjetlo nakon operacije katarakte fakoemulzifikacijom. Ova prospektivna studija je uključila 18 bolesnika (18 očiju) podvrgnutih operaciji i ugradnji jednodijelne savitljive akrilatne leće AcrySof SN60AT u razdoblju od prosinca 2005. do veljače 2006. godine. Analizirana je priprema leće za ugradnju, operacijske i poslijeoperacijske komplikacije, ugradnja leće kroz operacijski rez od 3,2 mm, centriranje leće, fleksibilnost haptika, vidna oštrina, zamućenje stražnje kapsule i test na boje. Prilikom pripreme leće za ugradnju nije bilo poteškoća. U tri slučaja vodeći haptik je teže ulazio u operacijski rez, a nakon ugradnje leća se vrlo brzo vraćala u prvobitan oblik. Nije bilo poteškoća s centriranjem unutar kapsularne vreće. Poslijeoperacijska korigirana vidna oštrina je bila 0,85 (Snellenova tablica), što je bilo u skladu s nalazom na fundusu. Bolesnici se nisu žalili na percepciju boje na operiranom oku. Ugradnja jednodijelne intraokularne leće AcrySof s filtrom za plavo svjetlo ne razlikuje se od ugradnje drugih savitljivih leća i ne utječe na percepciju boja i vidnu oštrinu.

Ključne riječi: *Leće – intraokularne, protetsko vidno pomagalo; Ugradnja leće – intraokularna; Fakoemulzifikacija; Biokompatibilni materijali*