

IS FOUR-DIMENSIONAL (4D) ULTRASOUND ENTERING A NEW FIELD OF FETAL PSYCHIATRY?

Asim Kurjak¹, Milan Stanojević¹, Aida Salihagić-Kadić², Lara Spalldi Barišić³ & Miro Jakovljević⁴

¹Department of Obstetrics and Gynecology, Clinical Hospital "Sveti Duh",
Medical School University of Zagreb, Zagreb, Croatia

²Department of Physiology, Medical School University of Zagreb, Zagreb, Croatia

³Outpatient Department „Veritas“, Zagreb, Croatia

⁴Department of Psychiatry, University Hospital Center Zagreb, Zagreb, Croatia

received: 26.3.2019;

revised: 7.5.2019.

accepted: 7.6.2019

SUMMARY

The aim of is to explore whether by observing the fetus by 4D US it is possible to enter fetal behavior, emotions, mental status, consciousness, awareness and other states connected with fetal mind and ability of self-regulation.

It is well known that fetal motoric activity is enabling the development of central and peripheral nervous system and the muscles. It is 4D US which enabled to investigate fetal movement patterns from the first trimester of pregnancy throughout the whole pregnancy. Based on the evaluation of fetal spontaneous motor activity by 4D US, a prenatal neurologic scoring test named Kurjak Antenatal Neurodevelopmental Test (KANET) was created. This test has been used to assess almost 2000 fetuses and our results have indicated that KANET has an ability to recognize normal, borderline, and abnormal behavior in fetuses from normal and abnormal pregnancies.

The fetus is able to process tactile, vestibular, taste, olfactory, auditory and visual sensations. The fetus responds to painful stimuli with a wide spectrum of reactions. Important external signs of emotion are facial expressions. The existence of a wide range of facial expressions, including grimacing, smiling, crying, similar to emotional expressions in adults, has been revealed by 4D sonography in the 2nd and 3rd trimesters of pregnancy.

It is questionable if mental, emotional and behavioral conditions of the fetus were covered in this paper and whether we are able to perceive the fetus as the patient who may develop communication or some other psychiatric disorders which we will be hopefully able to recognize prenatally. Although it seems as the speculation from the point of view of our recent diagnostic possibilities, it is apparent that the day when this will be a reality is rapidly approaching.

Key words: fetal behavior - fetal senses – consciousness – awareness - four-dimensional ultrasound

* * * * *

INTRODUCTION

Introduction of ultrasound more than seventy years ago into medical diagnostics was an important diagnostic tool in clinical medicine (Newman & Rozycki 1998, McNay & Fleming 1999). When more than sixty years ago ultrasound was introduced to the field of obstetrics and gynecology it has opened mysterious and unknown world of fetal life to the eyes of clinicians and the mothers (McNay & Fleming 1999). Advancement of ultrasound and computer technology almost thirty years ago enabled introduction of three- and four-dimensional ultrasound (3D and 4D US) which has made depiction of fetal anatomy more realistic with many details of normal and abnormal structures of many organs and organ systems (Baba et al. 1989, Merz 1995, Kurjak et al. 2000). Two dimensional ultrasound (2D US) has been used as the tool not only to depict fetal anatomical structures, but also it's function by introduction of assessment of Prechtl's fetal general movements (GMs), reflecting the development of fetal central nervous system (Prechtl 1990, Einspieler et al. 2004, Hadders-Algra 2004). Some fifteen years ago 4D US has been introduced in the field of fetal behavior with the

development of Kurjak Antenatal Neurodevelopmental Test (KANET) aiming to detect fetuses at high neurodevelopmental risk by the assessment not only of fetal GMs but also some other neurological signs like skull sutures, neurological thumb and facial movements (Kurjak et al. 2003, 2004, 2008, 2010, Amiel Tison et al. 2006, Amiel-Tison & Gosselin 2009). While studying fetal behavior, we have been speculating about the fetal awareness and fetal cognitive function, trying to become familiarized with fetal emotional life and its readiness to separate from the intrauterine environment and begin independent life as a new individual (Kurjak et al. 2005, Salihagic Kadic & Kurjak 2018). This concept of looking at the fetus as a complete person is very important, because only by putting together all aspects of ones health even in utero is enabling better results of treatment. This means that at that time we have been thinking in the way of so called personalized medicine, taking every fetus as a separate and unique individual. Problem with fetus is that not all postnatal diagnostic tools are available prenatally, and the influence of maternal environment which is quite different from one postnatally is also disturbing and complicating our diagnostic means and approach.

The aim of this paper is to explore whether by observing the fetus by 4D US we are able to enter fetal behavior, emotions, mental status, consciousness, awareness and other states connected with fetal mind and ability of self-regulation.

DEFINITION OF HUMAN AWARENESS

Linguistic definitions of awareness are available on the Internet. Webster dictionary defines awareness the quality or state of being aware: knowledge and understanding that something is happening or exists (<https://www.merriam-webster.com/dictionary/awareness> (accessed 21.6.2019.)), while MacMillan dictionary provides with two aspects of awareness:

1. knowledge or understanding of a subject, issue, or situation,

2. the ability to notice things (<https://www.macmillandictionary.com/dictionary/british/awareness> (accessed 21.6.2019.)). Awareness is the ability to directly know and identify, to feel, or to be aware of events, meaning that one is conscious of something, informing environment about it through specific behavioral process (<https://en.wikipedia.org/wiki/Awareness>). Weather awareness is synonymous with consciousness itself is not quite clear, although some investigators think about awareness in that way (Hussain et al. 2009). Many investigators believe that consciousness consists of two components: awareness which is a content of consciousness, and arousal describing the level of consciousness (Boly et al. 2008). Awareness and arousal are mostly positively correlated meaning that with decreased arousal awareness is decreasing as well (Boly et al. 2008). Concept of awareness has at least two aspects: the first focused on internal state which could be described as the intuitive feeling of something, and the second directed toward the external events by means of sensory perception, when the brain is activated in certain ways enabling sensing something, which is process distinguished from observation and perceiving (Locke 2002). When thinking about awareness, there can be at least two aspects of the state of awareness depending on the subject to which awareness is directed: one is self-awareness meaning that one is aware of one's own awareness state, and the other component is external awareness implicating how external world is perceived (Boly et al. 2008). The organization of self-awareness denotes the inner experience of the subject which has a central role in the self-regulation (Amadei & Bianchi 2012). One's awareness of internal and external world is defined as basic awareness and is dependent on the brain stem, while higher forms of awareness like self-awareness require cortical contribution (Amadei & Bianchi 2012). Primary consciousness means ability to integrate sensations from the environment which are transposed to certain behavior (Amadei & Bianchi 2012). This primary consciousness or basic awareness consists of the capacity to generate emotions

and awareness of surrounding without ability to talk, label or describe this experience (Amadei & Bianchi 2012). There are interconnected regions down the brain stem regulating the direction of the gaze, and organize the decisions about one's next activity (Amadei & Bianchi 2012).

DEVELOPMENT OF CONSCIOUSNESS AND AWARENESS

As it was pointed out before, consciousness has two main components: arousal which involves the activity of subcortical structures encompassing brain-stem reticular formation, hypothalamus, and basal forebrain, and awareness which is related to the activity of frontoparietal associative areas (Boly et al. 2008). While self-awareness networks include the posterior cingulate/pre-cuneal cortices, medial frontal cortex, and bilateral temporoparietal junctions, the external awareness network encompasses lateral frontal and parietal cortices (Boly et al. 2008).

Brain stem is formed around 7 weeks of gestation, while cerebral hemispheres and diencephalon develop by the end of 8 gestational week (Salihagić Kadić & Predojević 2012). Production of 250.000 neurons per minute starts at 7 weeks of gestation (Nelson 2011). Early in gestation neurons differentiate and migrate through the forming cortical layers. Migration of neurons to the cortical plate peaks around 12 to 20 weeks and is complete around 26 to 29 weeks (Anderson & Thomason 2013). Approximately between 24 and 34 weeks, cortical area differentiation begins and continues until the end of gestation (Kostovic et al. 1995). The peak period of synaptogenesis begins at 34 weeks and continues well into early postnatal life (Tau & Peterson 2010). Thalamo-cortical and cortico-cortical connections are fundamental for cortical processing of sensory information and mental processes. The first such connections grow at 24 to 26 weeks of gestation (Kostovic & Judas 2010). Between 26 and 28 weeks, evoked potentials can be registered from the cortex, indicating that the functional connection between periphery and cortex operates from that time onwards (Klimch & Cooke 1998).

DIAGNOSTIC TOOLS DEMONSTRATING BRAIN FUNCTION

As it was pointed out in the introduction not many diagnostic methods are available for prenatal use due to the technical and ethical constrains. Depicting fetal structural brain anatomy is much easier than assessment of fetal brain function. Methods like functional magnetic resonance imaging (fMRI), diffuse correlation spectroscopy and near-infrared spectroscopy, positron emission tomography (PET) or electroencephalography (EEG) can be used postnatally in premature infants and these data can be transposed to the fetuses of the same

gestational age, but this comparison is not quite plausible at least because fetus and neonate are living in quite different environments, which may have substantial influence on the findings (Laureys et al. 1999). Most methods rely on the idea to make assumptions about the timing or location of some activity pattern of the activated brain system (Boly et al. 2008, Heiss 2012, Arichi et al. 2017, Andersen et al. 2019, Giovannella et al. 2019, O'Sullivan et al. 2019).

The EEG is more and more routinely recorded alongside fMRI to study spontaneous brain activity (Salek-Haddadi et al 2003, Arichi et al. 2017). The EEG data provide access to very useful information regarding the timing of spontaneous brain activity. There are some differences between neonatal and adult brain activity shown by fMRI detecting the highest activity in the somatosensory, auditory, and visual cortex, whereas less activity is revealed in association area and the prefrontal cortex of the newborn brain as compared with adults (Lagercrantz 2014).

As we can learn from the data of sophisticated neuroimaging and neurophysiological data used postnatally, neither of them has been routinely used in fetuses due to different technical and ethical constrains. At the moment one of the available methods for functional assessment of fetal brain is 4D US.

Challenges of DOHaD models of mental health: Fetal origins of mental disorders

It is quite clear that proper fetal brain development requires appropriate combination of both genetic/epigenetic and environmental factors. Dysregulation of intrauterine environment may result in disturbances in fetal brain development which may be critical for different mental disorders (ADHD, autism, anxiety, bipolar disorder, depression, schizophrenia, and substance abuse) over the lifespan (O'Donell & Meaney 2017, Peterson et al. 2019, Sonmez et al. 2019). From the perspective of pre-emptive and preventive psychiatry studies of the fetal origins of mental health as well as mental disorders are formidable challenge. Mental disorders develop as a cascade of events functionally linked to each other (concept of staging), sometimes starting in prenatal period. Predictive diagnostics followed by targeted prevention before manifestation of pathology has been promoted as a new promising and challenging concept of precision medicine predicated on excellent science and info-technology. Staging as proven strategy in somatic medicine involves searching for the links between biomarkers, clinical phenotypes and disease development as the base for personalized pre-emptive treatment. The most challenging hypothesis of "developmental origins of health and disease" (DOHaD) suggests that the intrauterine signals which compromise fetal growth also act to "program" tissue differentiation in a manner that shapes individual differences in the risk for chronic illness and mental dis-

orders over the lifespan (O'Donell & Meaney 2017). According to integrative models of fetal neurodevelopment, antenatal maternal adversity operates through the biological pathways associated with fetal growth to program neurodevelopment. Compromised fetal development appears to establish a "meta-plastic" state that increases sensitivity to postnatal influences and consecutively to increased risk for mental disorders. DOHaD studies provide an empirical basis for multidisciplinary programs across obstetrics/gynecology, neonatology, pediatrics, neuroscience, psychiatry, and psychology and are essential for a comprehensive understanding of the relation between maternal health, fetal growth, and neurodevelopment.

POSSIBILITIES OF 4D US IN ASSESSMENT OF FETAL BEHAVIOR

Fetal motoric activity

It is well known that fetal motoric activity is enabling the development of central and peripheral nervous system and the muscles (Salihagić Kadić et al. 2009). General movements (GMs) are the earliest complex, well-organized movement pattern of the head, trunk and limbs appearing at the 7.5 gestational weeks. It is 4D US which enabled to investigate fetal movement patterns from the first trimester of pregnancy throughout the whole pregnancy (Kurjak et al. 2006, Andonotopo et al. 2005). At 10 weeks of gestation the fetus begins to show the earliest signs of right- or left-handed behavior. Stimulation of the brain influences its organization and fetal motor activity induces the brain to develop "handedness" and subsequent lateralization of the function (Salihagić Kadić & Predojević 2009). From 13 gestational weeks onwards, the fetus performs goal oriented targeted hand movements (Figure 1) (Kurjak et al. 2003). Early in the 2nd trimester sixteen different types of head movements can be observed, including retroflexion, anteflexion, and rotation of the head as well facial movements such as mouthing, yawning, hiccups, sucking, and swallowing (Salihagić Kadić & Predojević 2009) (Figure 2). The eye movements appear between 16 and 18 weeks of gestation (Figures 3 and 4). In the 2nd and the 3rd trimester gradual organization of fetal movement patterns is recognized with the periods of fetal quiescence lasting more than 90 per cent of the time during the day. Compared 2D, 4D US enabled the depiction of facial movements and mimics like isolated eye blinking, grimacing, sucking and swallowing appearing mostly after the 28 weeks of gestation (Kurjak et al. 2006). Before 28 weeks of gestation fetal mimics is almost not present (Figure 5). The fetus can alter the frequency, patterning, and coordination of movements in response to sensory stimuli, while the memory of the motor experience and motor learning may contribute to normal prenatal motor development (Robinson 2016).

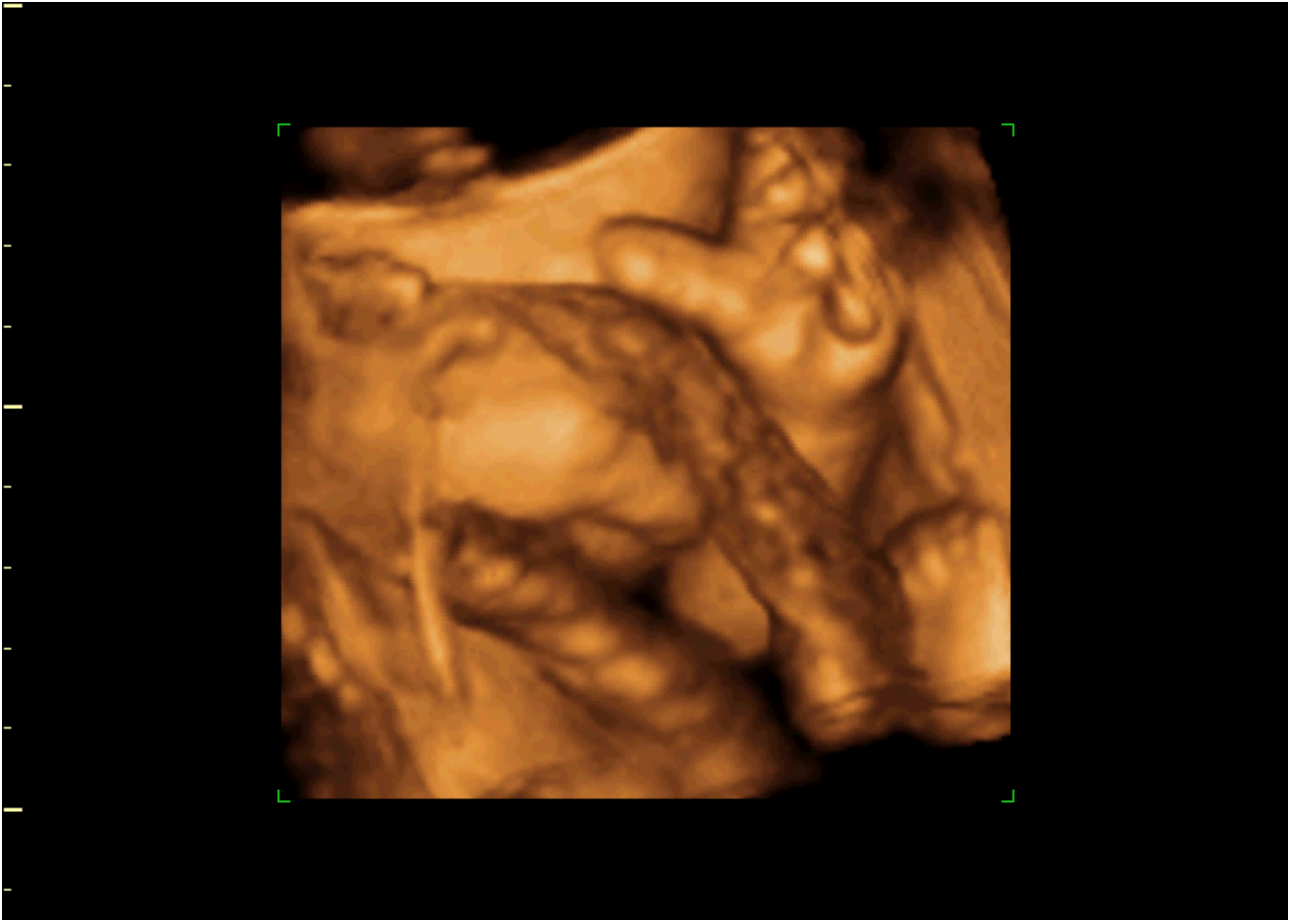

Figure 1. Goal directed movement of the hand towards the umbilical cord

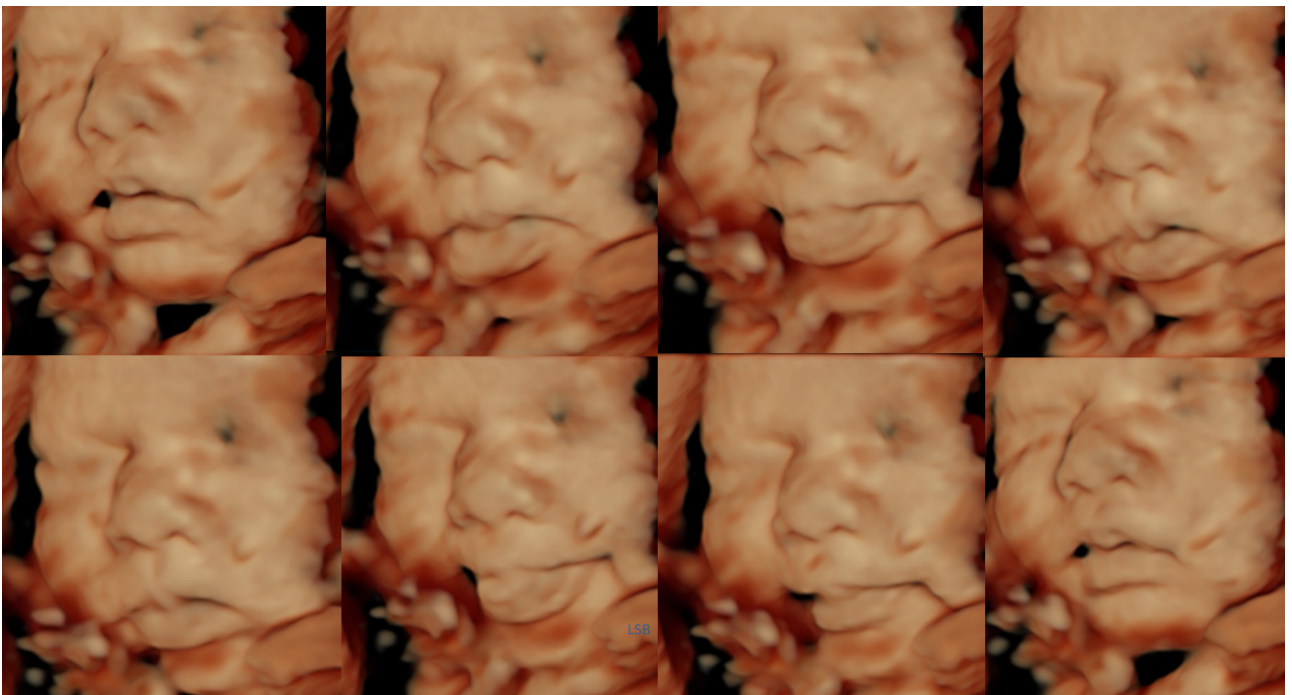


Figure 2. Fetus at 38 weeks of gestation. 4D HDlive surface, sequence view of the fetal face. Notice alternating mimics on the face such as tongue propulsion (tasting of the amniotic fluid) and smile on the face

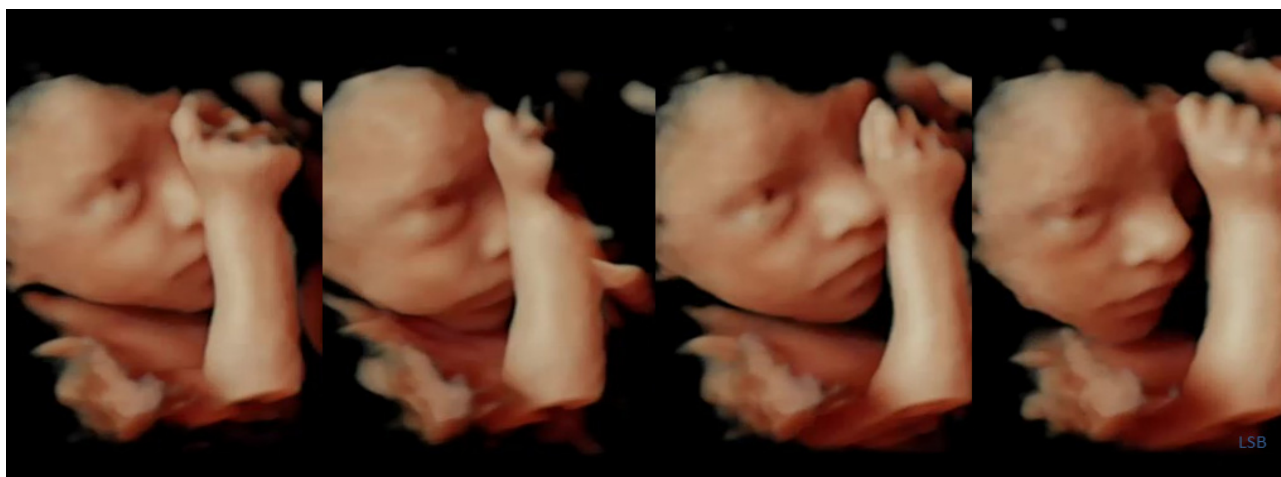

Figure 3. Fetus at 28 weeks of gestation. 4D HDlive surface mode, sequence view. Notice open eyes and alteration in eye movement. Fetus exploring surrounding environment

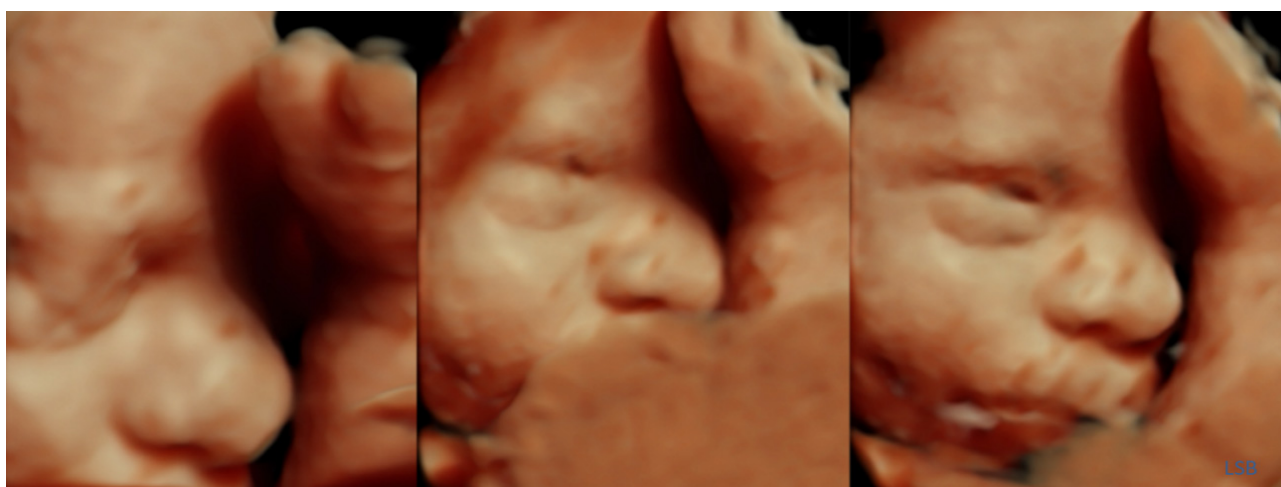


Figure 4. Images of the same fetus as in the previous Figure 3. 4D HDlive surface mode, sequence view of the fetal face. Notice fetus opening the eyes

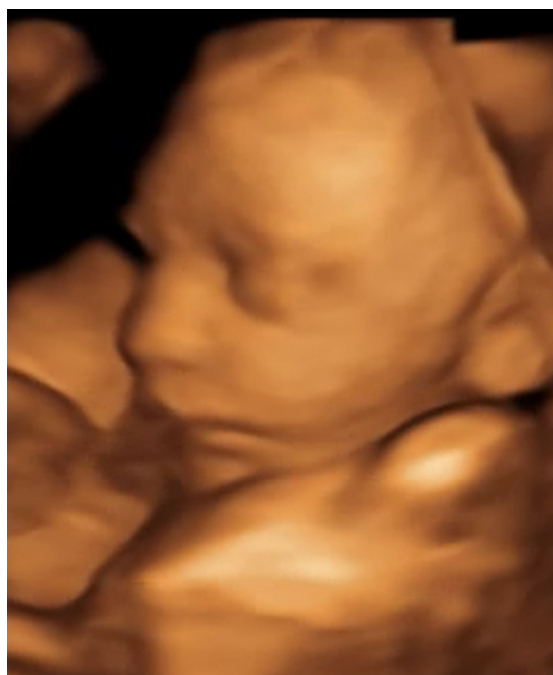

Figure 5. Fetus 24 weeks gestation. 4D surface view of the fetal face, no mimics

Kurjak Antenatal Neurodevelopmental Test (KANET)

Based on evaluation of fetal spontaneous motor activity by 4D US, a prenatal neurologic scoring test named KANET, was created (Kurjak et al. 2008). This test has been used to assess almost 2000 fetuses and our results have indicated that KANET has an ability to recognize normal, borderline, and abnormal behavior in fetuses from normal and abnormal pregnancies (Kurjak et al. 2012, 2017, Salihagić Kadić et al. 2016, Neto et al. 2017). KANET is used in everyday clinical practice as the screening tool to discriminate fetuses with normal motor development and those who are at risk for development of neurological disability after birth including cerebral palsy (CP) (Stanojevic et al. 2011, 2015). It has acceptable sensitivity and specificity, positive and negative predictive value and inter- and intra-observer reliability. KANET became a good screening tool for the selective screening of the fetuses with moderate and high neurological risk. It is still not easy to answer the question how application of KANET will affect the diagnosis and incidence of the huge group of heterogeneous, non-progressive neurological disorders defined as CP.

Fetal senses

The fetus is able to process tactile, vestibular, taste, olfactory, auditory and visual sensations (Salihagić Kadić & Predojević 2009). After establishing the thalamocortical connections, tactile experiences can be processed at a cortical level. It has been shown that body awareness develops after 25 weeks of gestation, which can be associated with the emergence of a minimum level of consciousness (Lagercrantz 2007). The fetus responds to painful stimuli with a wide spectrum of reactions (Salihagić Kadić & Predojević 2012). The first responses, motor reflexes appear at 7.5 weeks of gestation. Some of physiological reactions, such as activation of the hypothalamo-hypophysial axis and autonomic nervous system, do not reach the cerebral cortex. Sensing pain requires a developed neural pain system, from nociceptors to sensory areas in the cerebral cortex. After 24 to 26 weeks the fetus has the necessary connections to sense pain. Somatosensory evoked potentials can be registered from the cortex at 29 weeks and they may provide evidence of pain processing in the somatosensory cortex (Bellieni et al. 2018). According to recent findings, the cortical pain response has been recorded by near-infrared spectroscopy from about 25 weeks (Lagercrantz 2014). Facial expressions similar to those of adults sustaining pain have been observed in preterm infants after 25 weeks of gestation and these infants are probably conscious of pain. On the other hand, there is an opinion that the fetus may not be conscious of pain even after 25 weeks due to high endogenous sedatory and analgesic substances (Lagercrantz 2014). However, fetal facial expressions similar to those of children sustaining pain have been noticed by 4D sonography.

Fetal emotions

Important external signs of emotion are facial expressions. The existence of a wide range of facial expressions, including grimacing, smiling, crying, similar to emotional expressions in adults, has been revealed by 4D sonography in the 2nd and 3rd trimesters of pregnancy (Figure 2) (Salihagić Kadić & Predojević 2012). As the fetus matures, the complexity of facial expressions increases with appearance of “cry-face gestalt” or “laughter-face gestalt” in the third trimester. Are facial expressions a part of reflexive behavior of the fetus or are they signs of fetal awareness? In fact, smiling, as well as screaming and crying can be induced from the brainstem stimulation even with complete forebrain transection or destruction (Joseph 1999a). However, according to the observations obtained by 4D ultrasound, the facial expressions and emotion-like behaviors may represent some kind of fetal emotion and awareness (Hata et al. 2015). The limbic forebrain is responsible for the expression and experience of emotions (Joseph 1999b). One of the very important structures, the amygdala, mediates emotional memory, attention, arousal, and the experience of love, fear,

pleasure and joy (Salihagić Kadić & Predojević 2012). It contains facial recognition neurons which discern the emotional significance of different facial expressions (Salihagić Kadić & Predojević 2012). The evaluation of faces in social processing is an area of cognition specific to the amygdala (Salihagić Kadić & Predojević 2012).

Fetal memory and learning

Habituation, the decrement in response following repeated presentation of the same stimulus, was demonstrated from 22 weeks of gestation onwards (Leader et al. 1982). Some investigators have registered developmental trends in habituation to vibroacoustic stimuli, with younger fetuses requiring more presentations of the stimulus than older fetuses. It should be pointed out that maternal conditions, such as depression and stress, affect the fetal habituation in a negative way, indicating developmental delays (Salihagić Kadić & Predojević 2012). They may be linked to impaired function of the fetal cerebral cortex (Morokuma et al. 2004). Prefrontal and hippocampal regions are involved in rapid automatic detection and habituation to unexpected environmental events and are key elements of the orienting response in humans (Yamaguchi et al. 2004).

CONCLUSION

The fetus lives in a stimulating matrix of motion as well as tactile, chemical and auditory sensory information, and it is exposed to hundreds of specific and patterned stimuli each day. The structure and function of the brain are shaped by these stimuli (Salihagić Kadić & Predojević 2012). Fetus can identify, respond and remember for a relatively long time stimuli experienced during the prenatal period (Marx & Nagy 2017). Higher order sensory perception begins in fetal life when functional thalamocortical connections are present enabling fetal awareness of noxious stimuli. Fetus is capable of action planning and learning. Fetal movements are reflecting the development of the brain, but at the same time they are stimulating the brain to develop. As we have learned from 4D US study of fetal behavior, fetal motor function undoubtedly reflects development of diverse cognitive, sensory, and motor systems (Hata et al. 2015). The face is the mirror of the brain, many expressions can be depicted during fetal life which are proving that fetal life in utero is very dramatic and rich in different experiences (Kurjak et al. 2007, Reissland et al. 2013).

It is questionable if mental, emotional and behavioral conditions of the fetus were covered in this paper and whether we are able to perceive the fetus as the patient who may develop communication or some other psychiatric disorders which we will be hopefully able to recognize prenatally. Although it seems as the speculation from the point of view of our recent diagnostic possibilities, it is apparent that the day when this will be a reality is rapidly approaching.

Acknowledgements: None.

Conflict of interest: None to declare.

Contribution of individual authors:

Asim Kurjak: concept and design of the article, writing manuscript, approval of the final version, introduced 4D US to the investigation of fetal behavior, authored the KANET test.

Milan Stanojević: concept and design of the article, writing the manuscript, literature searches, approval of the final version, one of the co-authors of the KANET test, responsible for the pediatric follow up after prenatal investigation of fetal behavior.

Aida Salihagić Kadić: comments on concept and design of article, design writing the manuscript, literature searches, approval of the final version, responsible for interpretation of fetal behavior from the neuroscience point of view.

Lara Spalldi Barisic, comments on the concept and design of article, writing the manuscript, approval of the final version, literature searches, expert in KANET test performance and use of 4D US in the assessment of fetal behavior, she provided with 4D figures to the paper.

Miro Jakovljević, comments on the concept and design of article, writing the manuscript, the part dedicated to psychiatric aspect of fetal growth and behavior, literature searches, approval of the final version.

References

1. Amadei G & Bianchi I.: *Living systems, evolving consciousness, and the emerging person: a selection of papers from the life work of Louis Sander*. New York: Taylor & Francis, 2012; 162
2. Amiel Tison C et al.: *Neurosonography in the second half of fetal life: a neonatologist point of view*. *J Perinat Med* 2006; 34:437-46
3. Amiel-Tison C & Gosselin J: *From neonatal to fetal neurology: some clues for interpreting fetal findings*. In: Pooh RK, Kurjak A, editors. *Fetal neurology*. New Delhi: Jaypee Brothers Medical Publishers 2009; p. 373-404
4. Andersen JB, Lindberg U, Olesen OV, Benoit D, Ladefoged CN, Larsson HB, et al. *Hybrid PET/MRI imaging in healthy unsedated newborn infants with quantitative rCBF measurements using 15O-water PET*. *J Cereb Blood Flow Metab* 2019; 39:782-793. doi: 10.1177/0271678X17751835
5. Anderson AL & Thomason ME: *Functional plasticity before the cradle: A review of neural functional imaging in the human fetus*. *Neuroscience and Biobehavioral Reviews* 2013; 37:2220-2232
6. Andonotopo W et al.: *The assessment of fetal behavior in early pregnancy: comparison between 2D and 4D sonographic scanning*. *J Perinat Med* 2005; 33:406-414
7. Arichi T, Whitehead K, Barone G, Pressler R, Padormo F, Edwards AD et al.: *Localization of spontaneous bursting neuronal activity in the preterm human brain with simultaneous EEG-fMRI*. *Elife* 2017; 6:e27814. doi:10.7554/eLife.27814
8. Baba K et al.: *Development of an ultrasonic system for three-dimensional reconstruction of the fetus*. *J Perinat Med* 1989;17:19-24
9. Bellieni CV et al.: *Is fetal analgesia necessary during prenatal surgery?* *J Matern Fetal Neonatal Med* 2018; 31:1241-1245. doi:10.1080/14767058.2017.1311860
10. Boly M et al.: *Intrinsic brain activity in altered states of consciousness: how conscious is the default mode of brain function?* *Ann N Y Acad Sci* 2008; 1129:119-129. doi:10.1196/annals.1417.015
11. Einspieler C, et al.: *Prechtl's method on the qualitative assessment of general movements in preterm, term and young infants*. Cambridge: Mac Keith Press, 2004
12. Giovannella M, Contini D, Pagliuzzi M, Pifferi A, Spinelli L, Erdmann R, et al.: *BabyLux device: a diffuse optical system integrating diffuse correlation spectroscopy and time-resolved near-infrared spectroscopy for the neuro-monitoring of the premature newborn brain*. *Neurophotonics* 2019; 6:025007. doi: 10.1117/1.NPh.6.2.025007
13. Hadders-Algra M: *General movements: a window for early identification of children at high risk for developmental disorders*. *J Pediatr* 2004; 145:S12-8
14. Hata T et al.: *Fetal Consciousness: Four-dimensional Ultrasound Study*. *Donald School Journal of Ultrasound in Obstetrics and Gynecology* 2015; 9:471-474
15. Heiss WD: *PET in coma and in vegetative state*. *Eur J Neurol* 2012; 19:207-11. doi: 10.1111/j.1468-1331.2011.03489.x
16. Husain A et al.: *Brain inspired cognitive systems*. New York: Springer Science Business Media, 2009:298
17. Joseph R: *Environmental Influences on Neural Plasticity, the Limbic System, Emotional Development and Attachment: A Review*. *Child Psychiatry and Human Development* 1999a; 29:189-208
18. Joseph R: *Fetal brain and cognitive development*. *Dev Rev* 1999b; 20:81-98
19. Klimach VJ & Cooke RW: *Maturation of the neonatal somatosensory evoked response in preterm infants*. *Dev Med Child Neurol* 1988; 30:208-214
20. Kostović I & Judas M: *The development of the subplate and thalamocortical connections in the human foetal brain*. *Acta Paediatr* 2010; 99:1119-1127
21. Kostovic I et al.: *Ontogenesis of goal-directed behavior: anatomo-functional considerations*. *Int J Psychophysiol* 1995; 19:85-102
22. Kurjak A, Abo-Yaqoub S, Stanojevic M, Yigiter AB, Vasilj O, Lebit D et al.: *The potential of 4D sonography in the assessment of fetal neurobehavior – multicentric study in high-risk pregnancies*. *J Perinat Med* 2010; 38:77-82
23. Kurjak A, Andonotopo W, Hafner T, Salihagic Kadic A, Stanojevic M, Azumendi G et al.: *Normal standards for fetal neurobehavioral developments - longitudinal quantification by four-dimensional sonography*. *J Perinat Med* 2006; 34:56-65
24. Kurjak A, Antsaklis P, Stanojevic M, Vladareanu R, Vladareanu S, Neto RM et al. *Multicentric studies of the fetal neurobehavior by KANET test*. *J Perinat Med* 2017; 45:717-727. doi: 10.1515/jpm-2016-0409
25. Kurjak A, Azumendi G, Veccek N, Kupesic S, Solak M, Varga D et al.: *Fetal hand movements and facial expression in normal pregnancy studied by four-dimensional sonography*. *J Perinat Med* 2003; 31:496-508
26. Kurjak A et al.: *Behavioral pattern continuity from prenatal to postnatal life – a study by four-dimensional (4D) ultrasonography*. *J Perinat Med* 2004; 32:346-353
27. Kurjak A et al.: *Neurobehavior in fetal life*. *Semin Fetal Neonatal Med* 2012; 17:319-23. doi: 10.1016/j.siny.2012.06.005

28. Kurjak A et al.: The potential of four-dimensional ultrasonography in the assessment of fetal awareness. *J Perinat Med* 2005; 33:46–53
29. Kurjak A et al.: Three- and four-dimensional ultrasonography for the structural and functional evaluation of the fetal face. *Am J Obstet Gynecol* 2007; 196:16-28
30. Kurjak A et al.: Three-dimensional sonography in prenatal diagnosis: a luxury or necessity. *J Perinat Med* 2000; 28:194-209
31. Kurjak A, Miskovic B, Stanojevic M, Amiel-Tison C, Ahmed B, Azumendi G et al.: New scoring system for fetal neurobehavior assessed by three- and four-dimensional sonography *J Perinat Med* 2008; 36:73–81
32. Lagercrantz H: The emergence of consciousness: Science and ethics. *Semin Fetal Neonatal Med* 2014; 19:300-5. doi: 10.1016/j.siny.2014.08.003
33. Lagercrantz H: The emergence of the mind - a borderline of human viability? *Acta Paediatrica* 2007; 96:327-328
34. Laureys S, Goldman S, Phillips C, Van Bogaert P, Aerts J, Luxen A et al.: Impaired effective cortical connectivity in vegetative state: preliminary investigation using PET. *Neuroimage* 1999; 9:377-82
35. Leader LR et al.: The assessment and significance of habituation to a repeated stimulus by the human fetus. *Early Human Dev* 1982; 7:211-219
36. Locke D: Perception and our knowledge of the external world, Volume 3. London: Psychology Press, 2002; 27
37. Marx V & Nagy E: Fetal behavioral responses to the touch of the mother's abdomen: A Frame-by-frame analysis. *Infant Behav Dev* 2017; 47:83-91. doi: 10.1016/j.infbeh.2017.03.005
38. McNay MB & Fleming EE: Forty years of obstetric ultrasound 1957-1997: from A-scope to three dimensions. *Ultrasound Med Biol* 1999; 25:3-56
39. Merz E: Einsatz der 3D-Ultraschalltechnik in der pränatalen Diagnostik. *Ultraschall in Med* 1995; 16:154-61
40. Morokuma S et al.: Fetal habituation correlates with functional brain development. *Behav Brain Res* 2004; 153:459-463
41. Nelson CA: Neural development and lifelong plasticity. In: Keating DP (ed.): *Nature and Nurture in Early Child Development*. Cambridge: Cambridge University Press, 2011:45-69
42. Neto RM et al.: Clinical Study of Fetal Neurobehavior by the Kurjak Antenatal Neurodevelopmental Test. *Donald School Journal of Ultrasound in Obstetrics and Gynecology* 2017; 11:355-61
43. Newman PG & Rozycki GS: The history of ultrasound. *Surg Clin North Am* 1998; 78:179-195
44. O'Donnell KJ & Meaney MJ: Fetal origins of mental health: The developmental origins of health and disease hypothesis *Am J Psychiatry* 2017; 174:319–328. doi: 10.1176/appi.ajp.2016.16020138
45. O'Sullivan M, et al.: Analysis of a Low-Cost EEG Monitoring System and Dry Electrodes toward Clinical Use in the Neonatal ICU. *Sensors (Basel)* 2019; 19. pii: E2637. doi: 10.3390/s19112637
46. Pettersson E, Larsson H, D'Onofrio B, Almqvist C & Lichtenstein P: Association of fetal growth with general and specific mental health conditions. *JAMA Psychiatry* 2019; 76:536-543. doi:10.1001/jamapsychiatry.2018.4342
47. Prechtl HFR: Qualitative changes of spontaneous movements in fetus and preterm infant are a marker of neurological dysfunction. *Early Hum Dev* 1990; 23:151–8
48. Reissland N et al.: Can healthy fetuses show facial expressions of "pain" or "distress"? *PLoS One* 2013; 8:e65530. doi: 10.1371/journal.pone.0065530
49. Robinson RS: Yoke Motor Learning in the Fetal Rat: A Model System for Prenatal Behavioral Development. In: Reissland N, Kisilevsky BS. (eds.): *Fetal Development Research on Brain and Behavior, Environmental Influences, and Emerging Technologies*. Heidelberg, New York, Dordrecht, London: Springer International Publishing Switzerland, 2016; 43-67
50. Salek-Haddadi A et al.: Studying spontaneous EEG activity with fMRI. *Brain Res Brain Res Rev* 2003; 43:110-33
51. Salihagic Kadic A & Kurjak A.: Cognitive Functions of the Fetus. *Ultraschall in Med* 2018; 39:181-189. DOI: 10.1055/s-0043-123469
52. Salihagić Kadić A & Predojević M: Fetal neurophysiology according to gestational age. *Semin Fetal Neonatal Med* 2012; 17:256-60
53. Salihagić Kadić A et al.: Assessment of the Fetal Neuro-motor Development with the New KANET Test. In: Reissland N, Kisilevsky BS. (eds.): *Fetal Development Research on Brain and Behavior, Environmental Influences, and Emerging Technologies*. Heidelberg, New York, Dordrecht, London: Springer International Publishing Switzerland 2016; 177-189
54. Salihagic Kadic A et al.: Advances in Fetal Neurophysiology. In: Pooh RK, Kurjak A. (eds.). *Fetal Neurology*. New Delhi: Jaypee Brothers, 2009: 161-221
55. Sonmez EO, Uguz F, Sahingoz M, Sonmez G, Kaya K, Camkurt MA, Gokmen Z, Basaran M, Gezgin K, Erdem SS, Dulger HK & Tasyurek: Effect of maternal depression on brain-derived neurotrophic factor levels in fetal cord blood. *Clinical Psychopharmacology and Neuroscience* 2019; 17:308-313. <https://doi.org/10.9758/cpn.2019.17.2.308>
56. Stanojevic M, Antsaklis P, Salihagic Kadic A, Predojevic M, Vladareanu R, Vladareanu S, et al.: Is Kurjak Antenatal Neurodevelopmental test ready for routine clinical application: Bucharest consensus statement. *Donald School Journal of Obstetrics and Gynecology* 2015; 9:260-5. doi:10.5005/jp.journals-100009-1412
57. Stanojevic M et al.: An attempt to standardize Kurjak's Antenatal Neurodevelopmental Test: Osaka Consensus Statement. *Donald School Journal of Ultrasound in Obstetrics and Gynecology* 2011; 5:317-29
58. Tau GZ & Peterson BS: Normal Development of Brain Circuits. *Neuropsychopharmacology* 2010; 35:147-168
59. Yamaguchi S et al.: Rapid prefrontal-hippocampal habituation to novel events. *J Neurosci* 2004; 24:5356-63

Correspondence:

Prof. dr. sc. Asim Kurjak, MD
Ljubinkovac stube 1, 10 000 Zagreb, Croatia
E-mail: jadranka.cerovec@yahoo.com