

## CONTRAST SENSITIVITY IN STRABOLOGIC FUNCTIONAL TESTS

Ljubica Dorn and Jelena Petrinović-Dorešić

Department of Ophthalmology, Sv. Duh General Hospital, Zagreb, Croatia

**SUMMARY** – In physical meaning, contrast denotes the relationship between the luminance of an object and its immediate background. Retinal receptive fields and systems of P cell and M cell neurons are involved in contrast perception. P cells are thought to subserve light contrast and high spatial frequency resolution. M cells may be involved with information on high temporal and low spatial frequency. In amblyopia, considering developmental defect of spatial visual processing in the central nervous system, the main features are decreased recognition, Vernier and grating acuity, decreased contrast sensitivity and spatial localization. The aim of this report is to show how contrast sensitivity testing can contribute to functional examinations in strabismus and amblyopia. In our patients with different types of amblyopia and refractive errors we performed contrast sensitivity testing and comparison with visual acuity assessed by standard Snellen charts. On contrast sensitivity measuring we used Ginsburg method (Vistech VCTS and Vector Vision CSV-1000 charts). The results on each patient were recorded in an evaluation chart which gives the contrast sensitivity curve. The deficit in contrast sensitivity in anisometric amblyopia was most pronounced at high spatial frequencies. Strabismic amblyopia also showed the loss at high spatial frequencies but Snellen visual acuity was worse than grating acuity. Contrast sensitivity in strabismic amblyopia may be normal or abnormal at high frequencies. In visual deprivation amblyopia, both spatial localization and contrast sensitivity are affected. In comparison with standard Snellen visual acuity, contrast sensitivity testing is a more sensitive measure of visual function. Contrast sensitivity is also a sensitive tool to detect suppression even in patients with normal or near normal visual acuity. Preschool children can easily cooperate in this type of visual testing.

**Key words:** *Contrast sensitivity; Strabismology; Functional examinations*

### Introduction

In physical meaning, contrast denotes the relationship between the luminance of an object and its immediate background. Receptive fields and systems of P cell and M cell neurons are involved in contrast perception. P cells are thought to subserve light contrast and high spatial frequency resolution. M cells may be involved with information on high temporal and low spatial frequency<sup>1</sup>.

In amblyopia, considering developmental defect of spatial visual processing in the central nervous system,

the main features are decreased recognition, Vernier and grating acuity, decreased contrast sensitivity and spatial localization<sup>2</sup>. The defining feature of amblyopia is the loss of spatial vision – form sense. Form sense encloses visual acuity (central vision, i.e. the ability to discriminate fine high contrast details, and peripheral vision, i.e. field of vision) and contrast sensitivity, i.e. the ability to perceive a less sharply delineated pattern<sup>1,3</sup>.

Visual acuity is the resolving power of the eye measured by the recognition of the minimum visual angle (min/arc) at standardized distance, illumination (85 cd/m<sup>2</sup>) and high contrast (>85%). Grating visual acuity is expressed as cycles *per* degree, so that the cycle consists of one light band and one dark band. Spatial frequency means the number of cycles *per* degree. A grating of 30 cycles/degree has 60 alternating black-and-

Correspondence to: *Ljubica Dorn, MD, MS*, Department of Ophthalmology, Sv. Duh General Hospital, Sveti Duh 64, HR-10000 Zagreb, Croatia

E-mail: [ljubica.dorn@zg.htnet.hr](mailto:ljubica.dorn@zg.htnet.hr)




Fig. 1. Practical clinical examination of contrast sensitivity by Vector Vision CSV-1000.

white gratings *per* one degree of visual angle ( $1^\circ = 30$  cycles/degree). The highest frequency grating is the measure of visual acuity<sup>1,4</sup>.

Contrast sensitivity is the ability to perceive differences in contrast over the spectrum of spatial frequencies. Contrast sensitivity is measured using sinusoidal gratings, which show a gradual change from light to dark. Spatial frequency is the number of stripes *per* unit distance. The higher the frequency, the narrower the stripes. The contrast sensitivity threshold is the level of contrast at which the light and dark pattern is first discriminated. More contrast is required to identify higher frequency gratings. The setting out of the contrast threshold for each spatial frequency gives the contrast

sensitivity curve<sup>4</sup>. The normal contrast sensitivity curve has a peak at spatial frequencies of 5-6 cycles *per* degree<sup>1,4</sup>. Children and elderly have a higher contrast threshold for mild to high frequencies<sup>2-6</sup>.

In the 1960s, Campbell *et al.* found contrast sensitivity to be a much better tool to determine how people perceive images in everyday environments. They found it could be used to measure clinical visual problems much better than by the acuity test<sup>7</sup>. In 1978, Arden reported on the usefulness of contrast sensitivity testing for detection and evaluation of glaucoma, cataracts, optic neuritis, amblyopia, etc.<sup>8</sup>.

The aim of this study was to show how contrast sensitivity testing can contribute to functional examinations in strabismus and amblyopia.

## Patients and Methods

There are several tests for contrast sensitivity assessment. The Arden Plate test was one of the first contrast sensitivity tests designed for clinical use<sup>1,6,9</sup>. The Pelli-Robson chart contains 16 sets of letters printed in groups of three, each letter in a group having the same contrast. The contrast decreases from one triplet to the next one while the letter remains the same. Uniform illumination is important<sup>6,10</sup>. The Hiding Heidi Contrast Sensitivity Test according to Lea Hyvarinen is very useful for examination in small children<sup>6,11</sup>.

The Vistech (VCTS, Vision Contrast Test System) was developed in 1984 by Ginsburg<sup>12</sup>. The test consists of 45 small circles (set in 5 rows) containing sinusoidal-wave gratings randomly oriented in one of three directions (15 degrees to the left, 0° and 15 degrees slanted to the right). Spatial frequencies utilized, from the top row to the bottom row, are 1, 2, 4, 6 and 16 cycles *per* degree<sup>13</sup>. The task for the patient is to report the orientation of each grating in each row until the orientation cannot be determined. The data achieved are plotted in a given form and compared with the normal contrast sensitivity curve.

Very similar is Vector Vision CSV-100 contrast sensitivity test<sup>14</sup>. Test distance is 2.5 m (Fig. 1). This test is improved by automatic calibration of the light level to 85 cd/mm for each row of examination (Fig. 2) and use of remote control.

In our examination we used CSV-1000 Contrast Sensitivity Test. In this paper we present our first experiences.




Fig. 2. Sequences of the fields examined with contrast sensitivity test figures (lighter part of test table) presented to study subjects.



**Case 1**

A. I., a 10-year-old girl. History: she underwent school vision screening. Sometimes, she had difficulties in reading at near.

Ophthalmologic examination results:

Visual acuity (VA) at distance: o. dx: 1.0 s.c. (Snellen chart), o. sin: 1.0 ?? s.c. VA at near: o. dx: 1.0 s.c., o. sin: 0.8 s.c.

Motility, cover test and binocular functions (Worth, Lang I) were normal, there were no signs of strabismus. Trop-icamide retinoscopy: o. dx: +0.25 dsph; o. sin: em-metropia.

Fundus appeared normal, except for the macular region. We found loss of foveal reflex and macula around the fovea appeared as discrete "beaten bronze"; peripheral retina showed no characteristic yellow flecks. Color vision (Ishihara tables) was normal

Contrast sensitivity test (CSV-1000): right eye showed normal contrast sensitivity curve at low frequencies, whereas at frequencies of about 6 cycles *per* degree it was somewhat lower than normal. At high frequencies the curve was at the lower border of the normal curve. Left eye had the contrast sensitivity curve below the normal at all frequencies. After the sixth cycle, the curve showed highest distance from the normal curve at higher and highest frequencies.

Diagnosis: *Dystrophia maculae luteae incipiens o.u.*

**Case 2**

Đ. M., a 9-year-old boy. History: preschool screening indicated low vision at the right eye. From 2005 he had been treated and followed-up at our Children's Eye Center. Now he wore contact lens. Last follow up results: VA at distance: o. dx: -5.5 dsph=-3.0 dechl ax 70°=0.3-0.4 angular; o. sin: -0.5 dechl ax 100°=1.0. VA at near: o.dx. 0.63 c.c; o.sin.1.0 cc.

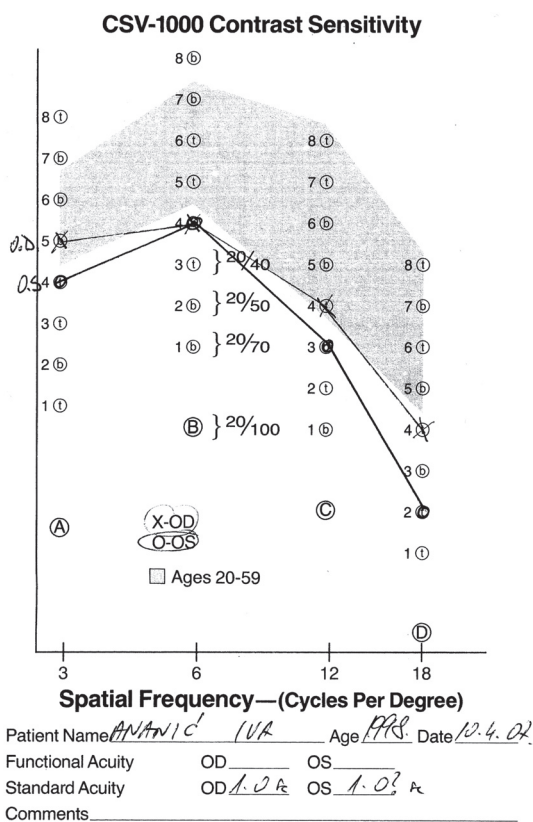


Fig. 3. A. I. Contrast sensitivity curve in early stage of macular dystrophy: both eyes curves are somewhat below the normal contrast sensitivity curve, particularly at frequencies after sixth cycle per degree.

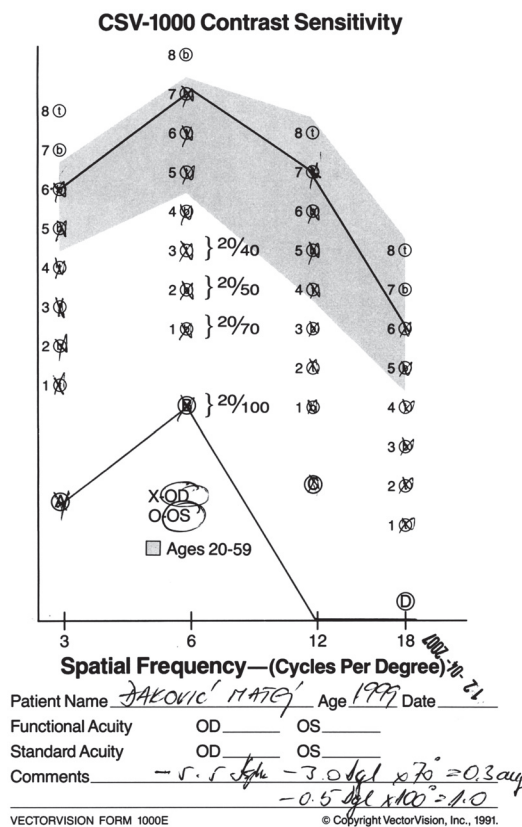


Fig. 4. Đ. M. Contrast sensitivity curve in deep amblyopia, myopic astigmatism and fibrae medullares on the disk of the right eye. The curve shows deep defect at all spatial frequencies.

Motility was normal, convergence ++, cover test at distance and at near was negative.

Binocular functions: Worth c.c.: right eye suppression. Stereovision: Titmus test: only house fly + with correction.

Biomicroscopy: no pathologic findings on anterior segment of the eye.

Fundus o. dx: optic disk was mainly covered with a white patch, of striated configuration, especially in the superotemporal part of the retina. The vessels were also obscured by this lesion. Macular region was in part involved. Otherwise, peripheral retina and vessels showed no pathologic signs. Fundus o. sin: optic disk, vessels, macula and retina had normal appearance.

Contrast sensitivity test (CSV-1000): o. dx: the contrast sensitivity curve showed deep defect in contrast sense in all spatial frequencies; o. sin: the curve was in the normal range.

Diagnosis: *Anisometropia; Astigmatismus myopicus compositus o. dx. et simplex o. sin; Amblyopia profunda o. dx; Fibrae medullares o. dx.*

### Case 3

D. M., a girl born in 1991. History: esotropia of the right eye operated in 1995, with rare follow up visits and inadequate treatment. Now, she presented merely for prescription for new glasses. Last control results: VA at distance with best correction: o. dx: 0.2 cc (+4.0 dsph = +0.75 ax 10°); o. sin: 1.0 (with +2.0 dsph = +0.5 ax 175°). VA at near: o. dx: 0.1 cc; o. sin: 1.0 cc. In primary position ortho position of the eyes (Hirschberg test), motility without incomitance, cover test negative. The angle of deviation at distance and at near was about 6 pd esotropia with correction.

Synoptophore: objective angle: +3 cc, subjective angle ??; fusion was absent.

Binocular functions: Worth and stereotests, Titmus and Lang I were defective.

Fundus: optic disk, retina and macula of both eyes were normal.

Contrast sensitivity test (CSV-1000): o. dx: the curve was very low at all frequencies and showed deep defect of contrast sense; o. sin: the curve was normal.

Diagnosis: *Esotropia operata o. dx.; Astigmatismus hyperopicus comp. ou.; Amblyopia o. dx.*

### Results

In the patient with incipient macular degeneration and good Snellen acuity, contrast sensitivity testing re-

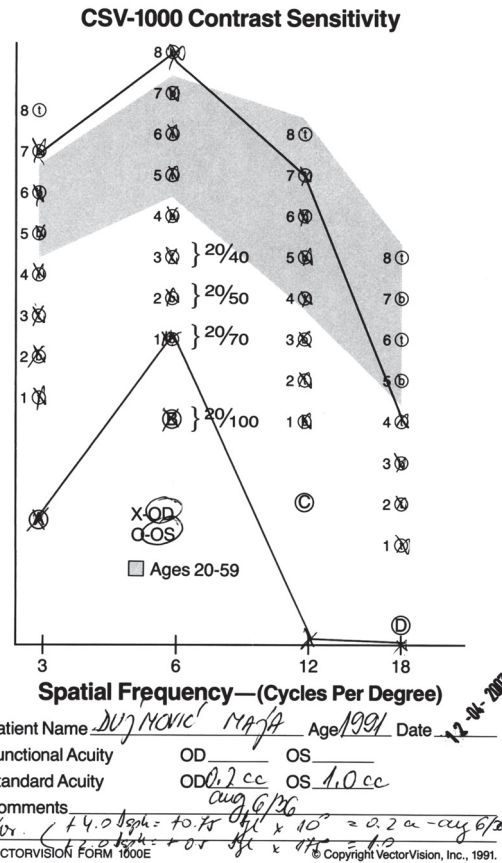


Fig. 5. D. M. Contrast sensitivity curve in operated esotropia and deep amblyopia of one eye. The curve shows deep defect of contrast sense at all spatial frequencies.

vealed normal curve at low frequencies in the right eye, but at frequencies of about 6 cycles per degree it was slightly below normal. At high frequencies the curve was at the lower border of normal. In the left eye, all frequencies were below the normal sensitivity curve. After the sixth cycle, the curve showed highest distance from the normal curve at higher and highest frequencies.

In the patient with deep amblyopia, myopic astigmatism and fibrae medullares in the right eye contrast sensitivity curve showed deep defect in contrast sense at all spatial frequencies. In the left eye contrast sensitivity was normal.

In the patient with amblyopia on the right eye, hyperopic astigmatism and operated esotropia of the right eye, the contrast sensitivity curve in the right eye was very low at all frequencies and showed deep defect of contrast sense. In the left eye, the contrast sensitivity curve was normal.

## Sažetak

## KONTRASTNA OSJETLJIVOST U STRABOLOŠKIM FUNKCIONALNIM ISPITIVANJIMA

*Lj. Dorn i J. Petrinović-Dorešić*

Kontrast u fizikalnom smislu označava odnos između svjetline objekta i njegove neposredne okoline. Pri opažanju kontrasta sudjeluju retinalna receptivna polja te sustavi P i M živčanih ganglijskih stanica. P stanice služe opažanju svjetlosnog kontrasta i rezolucije visokih prostornih frekvencija. M stanice su za informacije o visokim vremenskim i niskim prostornim frekvencijama. Kod ambliopije, s obzirom na razvojni poremećaj prostorne vidne obrade u središnjem živčanom sustavu, glavne su značajke smanjeno raspoznavanje, smanjena vernierska vidna oštrina, smanjena vidna oštrina ispitivana uzorkom rešetke, smanjenje kontrastne osjetljivosti i prostorne lokalizacije. Cilj rada je pokazati kako ispitivanje osjetljivosti kontrasta može pridonijeti funkcionalnim pretragama kod strabizma i ambliopije. Kod naših bolesnika s različitim oblicima ambliopije i refrakcijskih grešaka proveli smo ispitivanje kontrastne osjetljivosti te usporedbu s vidnom oštrinom dobivenom standardnom pretragom pomoću Snellenovih optotipa. U određivanju kontrastne osjetljivosti upotrebljavali smo Ginsburgov test (Vistech VCTS and Vector Vision CSV-1000 karte). Rezultati su uneseni u evaluacijski obrazac koji daje krivulju kontrastne osjetljivosti. Ispad kontrastne osjetljivosti kod anizotropne ambliopije najviše je bio izražen kod visokih prostornih frekvencija. Strabizmička ambliopija također je pokazala ispad visokih prostornih frekvencija, ali je vidna oštrina ispitivana Snellenovim optotipima bila lošija nego vidna oštrina ispitivana uzorkom rešetke. Kontrastna osjetljivost kod strabizmičke ambliopije može biti normalna ili patološka pri visokim frekvencijama. Kod vizualno deprivacijske ambliopije poremećene su i prostorna lokalizacija i kontrastna osjetljivost. U usporedbi sa standardnom vidnom oštrinom ispitivanom Snellenovim optotipima ispitivanje kontrastne osjetljivosti osjetljivija je mjera vidne funkcije. Kontrastna osjetljivost je osjetljiva metoda otkrivanja supresije i onda kada bolesnik ima normalnu ili približno normalnu vidnu oštrinu. Predškolska djeca mogu dobro sudjelovati u ovom ispitivanju vidne oštrine.

Ključne riječi: *Kontrastna osjetljivost; Strabologija; Funkcionalna ispitivanja*

