

## EARLY EFFECTS OF INTRAVITREAL BEVACIZUMAB (AVASTIN) FOR NEOVASCULAR GLAUCOMA

Smiljka Popović-Suić and Borna Šarić

University Department of Ophthalmology, Zagreb University Hospital Center, Zagreb, Croatia

**SUMMARY** – The aim of this study was to evaluate early treatment response following intravitreal bevacizumab therapy in 4 patients with neovascular glaucoma.

Four patients with neovascular glaucoma and pronounced congestion of anterior chamber received intravitreal bevacizumab injection (1.25 mg/0.05 mL). Intravitreal bevacizumab resulted in marked regression of anterior segment neovascularization documented by fluorescein angiography and iridography, and relief of symptoms within 24 hours. Cyclocryocoagulation was carried out only if pressure was insufficiently controlled by topical therapy. Follow up examination was performed at 1 month. In conclusion, intravitreal bevacizumab leads to rapid regression of iris and angle neovascularization in the early period of observation. Controlled randomized trial is needed to test whether intraocular injections of bevacizumab provide long term benefit to patients with neovascular glaucoma.

**Key words:** *Neovascular glaucoma; Bevacizumab*

### Introduction

Inhibition of vascular endothelial growth factor, which is a potent inducer of vascular permeability and plays an integral part in the formation of abnormal blood vessels, can be an effective treatment for a variety of ocular diseases<sup>1,2</sup>. Bevacizumab is a humanized monoclonal antibody to vascular endothelial growth factor designed for iv administration and approved for the treatment of colorectal cancer<sup>3</sup>. Recently, several studies have been published on the use of intravitreal bevacizumab for the treatment of cystoid macular edema<sup>4</sup>, diabetic macular edema<sup>5</sup>, neovascular age related macular degeneration<sup>6</sup> and neovascular glaucoma<sup>7,8</sup>.

Neovascularization of the anterior segment causes glaucoma by direct obstruction of the trabecular meshwork by the proliferating neovascular membrane. The most common cause of iris neovascularization is retinal ischemia. Ischemic central retinal vein occlusion and proliferative diabetic retinopathy are the two common

disorders associated with rubeosis iridis. Neovascular glaucoma is often recalcitrant to conservative and surgical therapy, thus posing a major therapeutic problem.

We report on a case series of four patients with neovascular glaucoma caused by central retinal vein occlusion, treated with intravitreal injection of bevacizumab.

### Material and Methods

Bevacizumab was administered to four patients with neovascular glaucoma caused by central retinal vein occlusion in a stage of pronounced iris congestion and intraocular pressure elevation refractive to conservative topical antiglaucoma therapy. Patients were prepared with standard surgical cleaning of the eyelids and peri-orbital region. The conjunctiva was irrigated with 5% povidone iodine. Intravitreal injection was administered under topical anesthesia according to the recommendations of the German Society of Ophthalmology<sup>9</sup>: 0.05 mL (1.25 mg) of sterile, undiluted, commercially available bevacizumab (Avastin; 100 mg/4 mL; Roche, Switzerland). Patients were not offered treatment if they had uncontrolled hypertension or recent myocardial infarction or cerebral vascular accident. All four patients

Correspondence to: *Smiljka Popović-Suić, MD*, University Department of Ophthalmology, Zagreb University Hospital Center, Kišpatićeva 12, HR-10000 Zagreb, Croatia

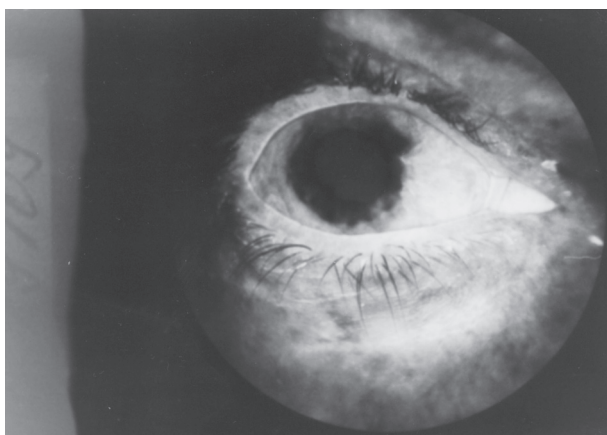


Fig. 1. Fluorescein iridography before intravitreal bevacizumab treatment: iris neovascularization.

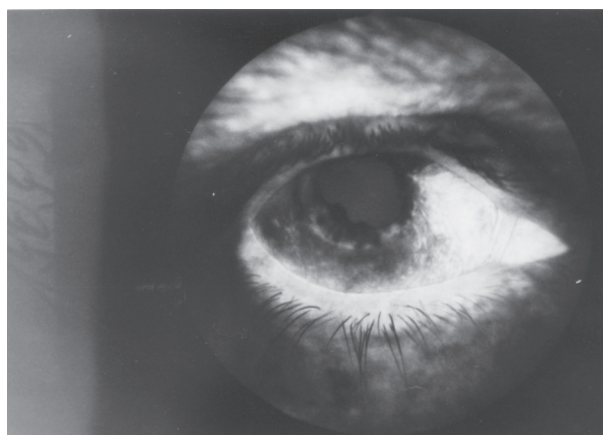


Fig. 2. Fluorescein iridography in the same patient one month after intravitreal bevacizumab treatment: disappearance of iris neovascularization.

signed a comprehensive consent form before administration of the drug.

Complete ophthalmologic examination and fluorescein angiography and iridography were performed before the treatment. Patients were instructed to administer topical antibiotics for 5 days after the injection. Biomicroscopy of the anterior segment and measurement of intraocular pressure were performed at 24 hours of the treatment. Follow up examination was performed at 1 month, including fluorescein angiography and iridography, and complete ophthalmologic examination. Neither local nor systemic side effects were noted.

## Results

All four patients were male, with neovascular glaucoma caused by central retinal vein occlusion. Their mean age was 64 (range, 55 to 72) years. None of our

patients had pre-existing glaucoma. The mean intraocular pressure before the treatment was 36.2 (range, 25 to 40) mm Hg. Visual acuity ranged from hand motions to counting fingers. Neovascularization of the iris and angle was found in all patients. All patients had ocular discomfort and pain in the affected eye, and all received topical antiglaucoma therapy (2-3 antiglaucoma drugs).

At 24 hours after the treatment, the mean intraocular pressure was 28.5 (range, 18 to 40) mm Hg. Three of four patients were free from pain and iris neovascularization almost disappeared. In one patient with circumferential peripheral anterior synechiae, pronounced neovascularization of the iris and angle, anterior chamber cells and flare, there was no pain relief and cyclophotocoagulation was performed.

At the end of the 1-month follow up, iris neovascularization documented by fluorescein angiography and iridography resolved completely in all patients. Visual

Table 1. Visual acuity (VA) before and 1 month after treatment; intraocular pressure (IOP) before, at 24 hours and at 1 month of treatment; iris neovascularization (IRIS) before, at 24 hours and at 1 month of treatment; and neovascularization of anterior chamber angle (Angle) before and at 1 month of treatment

Patient No.	VA	IOP	Iris	Angle
1	hand motion/counting fingers	40/32/20	+/-/-	+/-
2	light perception/0.1	35/30/18	+/-/-	+/-
3	light perception/0.1	25/30/18	+/-/-	+/-
4	light perception/hand motion	40/34/18	+ / + / -	+ / -

*Table 2. Pain and ocular discomfort before and at 1 month of treatment (Pain); number of antiglaucoma drugs before and at 1 month of treatment (Drugs, n); anterior chamber (AC) cells and flare before and at 1 month of treatment (AC); and need for cyclocryocoagulation (CY)*

Patient No.	Pain	Drugs (n)	AC	CY
1	+/-	3/1	-/-	-
2	+/-	2/1	-/-	-
3	+/-	3/1	-/-	-
4	+/-	3/1	+/-	+

acuity ranged from counting fingers to 0.1. The mean intraocular pressure controlled with only one antiglaucoma drug was 19.2 (range, 18 to 20) mm Hg. Data on all patients are summarized in Tables 1 and 2.

## Discussion and Conclusion

The use of bevacizumab has been reported in the treatment of macular degeneration, where intravenous administration of this agent produced a significant reduction in retinal thickening<sup>10</sup>. Systemic bevacizumab has also been reported to suppress choroidal neovascularization due to pathologic myopia<sup>11</sup>.

Much smaller doses administered intravitreally have a lower risk of systemic side effects and still are effective in patients with subfoveal choroidal neovascularization and macular edema<sup>4,6,12</sup>. These studies suggest that intravitreally administered bevacizumab effectively reduces neovascular activity and permeability in ocular tissue<sup>13</sup>.

Retinal hypoxia caused by central retinal vein occlusion has been implicated in the pathogenesis of neovascular glaucoma. Hypoxia causes increased expression of vascular endothelial growth factor, a potent inducer of the formation of abnormal blood vessels, iris and anterior chamber angle neovascularization, which leads to neovascular glaucoma<sup>1</sup>. A previous study suggests that intravitreal bevacizumab leads to rapid regression of iris and angle neovascularization within 48 hours in patients with neovascular glaucoma<sup>14</sup>. In our study, four patients with neovascular glaucoma caused by central retinal vein occlusion received intravitreal bevacizumab. After 24 hours, iris neovascularization disappeared in three patients, the mean intraocular pressure values were lower and patients were free from pain and discomfort in their

eyes. In one patient with pronounced iris congestion, the effect of bevacizumab was smaller but still noticeable. One month after the procedure, fluorescein angiography and iridography proved disappearance of iris neovascularization in all patients, and intraocular pressure values were within the normal range on only one antiglaucoma drug.

The shortcomings of this study were a small number of patients and limited follow up. Despite these limitations, this case series of four patients showed that intravitreally administered bevacizumab had at least a short-term biologic effect on iris and angle neovascularization.

## References

- FERRARA N. Vascular endothelial growth factor; basic science and clinical progress. *Endocr Rev* 2004;25:581-611.
- ADAMIS AP, SHIMA DT. The role of vascular endothelial growth factor in ocular health and disease. *Retina* 2005;25:111-8.
- HURWITZ H, FEHRENBACHER L, NOVOTNY W. Bevacizumab plus irinotecan, fluorouracil, and leucovorin for metastatic colorectal cancer. *N Engl J Med* 2004;350:2335-42.
- ROSENFELD PJ, FUNG AE, PULIAFITO CA. Optical coherence tomography findings after an intravitreal injection of bevacizumab for macular edema from central vein occlusion. *Ophthalmic Surg Lasers Imaging* 2005;36:336-9.
- QUAN DONG N, TATLIPINAR S, SHAH SM, HALLER J, QUINLAN E, SUNG J, ZIMMER GALLER I, CAMPOCHIARO P. Vascular endothelial growth factor is a critical stimulus for diabetic macular edema. *Am J Ophthalmol* 2006; 142:961-9.
- ROSENFELD PJ, MOSHFEGHI AA, PULIAFITO CA. Optical coherence tomography findings after an intravitreal injection of bevacizumab for neovascular age related macular degeneration. *Ophthalmic Surg Lasers Imaging* 2005;36:331-5.
- KAHOOK MY, SCHUMAN JS, NOECKER RJ. Intravitreal bevacizumab in patient with neovascular glaucoma. *Ophthalmic Surg Lasers Imaging* 2006;37:144-6.
- DAVIDOFF FH, MOUSE JG, DERICK RJ. Rapid improvement of rubeosis iridis from a single bevacizumab (Avastin) injection. *Retina* 2006;26:354-6.
- JASSLE GB, SZURMAN P, BARTZ-SCHMIDT KU. Recommendation for the implementation of intravitreal injection: statement of German Retina Society, the German Society of Ophthalmology and the German Professional Association of Ophthalmologists (BVA). *Klin Monatsbl Augenheilkd* 2005; 222:390-5.
- MICHELS S, ROSENFELD PJ, PULIAFITO CA. Systemic bevacizumab therapy for neovascular age related macular degeneration. Twelve week results of an uncontrolled open label clinical study. *Ophthalmology* 2005;112:1035-47.

11. NGUYEN QD, SHAH S, TATLIPINAR S. Bevacizumab suppressed choroidal neovascularisation caused by pathological myopia. *Br J Ophthalmol* 2005;89:1368-70.
12. AVERY R, PIERAMIC DJ, RABENA M, CASTELLARIN A, NASIR MA, GIUST MJ. Intravitreal bevacizumab (Avastin) for neovascular age related macular degeneration. *Ophthalmology* 2006;113:363-72.
13. BAKRI JS, SNYDER M, REID JM, PULIDO JS, SINGH JR. Pharmacokinetics of intravitreal bevacizumab (Avastin). *Am J Ophthalmol* 2007;114:855-9.
14. ILIEV ME, DOMIG D, WOLF-SCHNURRBURSCH U, WOLF S, SARRA GM. Intravitreal bevacizumab in the treatment of neovascular glaucoma. *Am J Ophthalmol* 2006; 42:1054-6.

#### Sažetak

### RANI UČINAK INTRAVITREALNOG BEVACIZUMABA (AVASTINA) ZBOG NEOVASKULARNOG GLAUKOMA

S. Popović-Suić i B. Šarić

Cilj ovoga rada bio je procijeniti rani odgovor na terapiju intravitrealnim bevacizumabom u 4 bolesnika s neovaskularnim glaukomom. Intravitrealna injekcija bevacizumaba (1,25 mg/0,5 mL) primijenjena je u 4 bolesnika s neovaskularnim glaukomom i izraženom kongestijom prednje sobice. Intravitrealni bevacizumab doveo je do znatne regresije neovaskularizacije prednjega očnog segmenta, što je dokumentirano fluoresceinskom angiografijom i iridografijom, te do ublažavanja simptoma kroz 24 sata. Ciklokriskoagulacija je provedena samo ako topikalna terapija nije reultirala dostatnom kontrolom tlaka. Kontrolni pregled je proveden nakon jednog mjeseca. Zaključuje se kako intravitrealni bevacizumab dovodi do brzog povlačenja neovaskularizacije irisa i kuta u ranom razdoblju praćenja. Potrebno je kontrolirano randomizirano ispitivanje kako bi se ispitalo pruža li intraokularno injektiranje bevacizumaba dugotrajnu korist kod bolesnika s neovaskularnim glaukomom.

Ključne riječi: *Neovaskularni glaukom; Bevacizumab*