

Aneurysmal Bone Cyst of the Cervical Spine – Case Report

Irina Bagić¹, Marko Kovačević^{1,2,3}, Vjenceslav Vrtarić¹, Gordan Reljac¹, Dario Mužević^{1,2,3}

¹Department of Neurosurgery, Osijek Clinical Hospital Center, Osijek, Croatia

²School of Medicine, Josip Juraj Strossmayer University, Osijek, Croatia

³School of Dental Medicine and Health Sciences, Josip Juraj Strossmayer University, Osijek, Croatia

ABSTRACT

Aneurysmal bone cyst (ABC) is a non-neoplastic locally destructive primary bone lesion mostly occurring within the first two decades of life with female predominance. Cervical spine ABCs are a very rare clinical entity with particularly demanding surgical resection limited by the involvement of nearby neurovascular structures and a risk for cervical spine instability. We present a case of a 17-year-old patient with a symptomatic ABC of the cervical spine who underwent surgical removal of the osseous lesion with good postoperative outcome. There are different therapeutic strategies for ABC management, but complete surgical removal of the cyst remains one of the most important predictors of favorable outcome, although it can be often limited, especially in the cervical region. Previously described lesions have a very high recurrence rate and therefore different additional methods, such as radiotherapy, embolization and sclerosation have been used in addition to surgical resection. Further studies are necessary for development of evidence-based treatment regimens for cervical spine ABCs in pediatric population.

Key words: aneurysmal bone cyst, resection, cervical spine tumor, neck pain

Introduction

Aneurysmal bone cyst (ABC) is a non-neoplastic locally destructive primary bone lesion mostly occurring within the first two decades of life with female predominance. Almost 30% of all ABCs occur in the spine with those in the cervical spine making only about 22%¹. Studies have shown that the potential mechanism for ABC formation may be associated with primary bone lesion of diverse origin resulting in secondary vascular lesion that causes erosion in the bone with development of osteoblastic and osteoclastic reaction². This expansion of the osseous elements inevitably causes cord compression, especially in the cervical spine, with one of the first symptoms being pain and in the advanced stages even neurological deficits and pathological fractures^{3,4}. Cervical ABCs treatment options remain controversial with no specific guidelines, mainly depending on institution-based experience. Depending on the case, current treatment options include preferably total surgical removal with or without fusion and preoperative embolization, selective injections of sclerosing agents, radiotherapy and cryotherapy^{1,5}. Recurrence rate for ABCs can be up to 30% and it can be reduced by supramarginal resection which is not always achiev-

able in the cervical spine^{6,7}. Hereby we describe a case of a 17-year-old boy who presented with ABC of the cervical spine and our diagnostic and surgical strategy.

Case Report

A 17-year-old male patient without any significant past medical history or cervical spine trauma presented with a one-year localized neck pain. Upon examination no neurological deficit was found. CT scans of the cervical spine demonstrated an expansive bone lesion involving the left side of the spinous processes, pedicles, laminae and bodies of C2 and C3 vertebrae with no evident spinal cord compression; findings were compatible with ABC (Figures 1a-c). Cervical TOF MRI angiography revealed hypoplastic left vertebral artery. Cervical MR images showed lobular expansive formation of predominantly bony structures of level CII-III on the left side, located in pedicles, spinous process and arches of lamina, and the body on the dorsal left side of CIII vertebra. It enters the spinal canal, extradurally, without compression of the cervical medulla spinalis. It extends extraosseously into the soft-tissue structures of the neck to the left at the level of the spinous

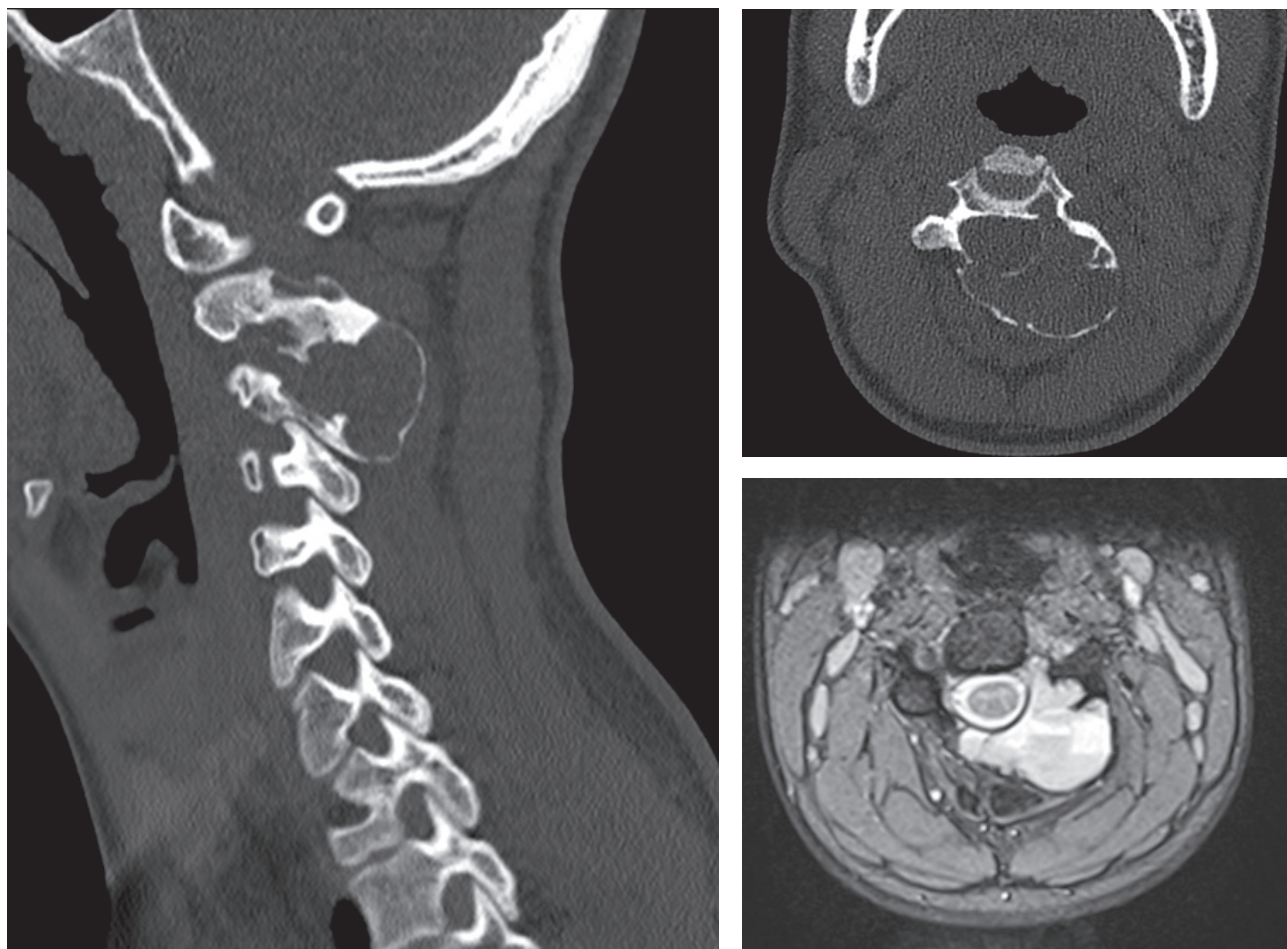


Fig. 1. a) Cervical spine CT scan in sagittal plane demonstrating aneurysmal bone cyst (ABC) of C2 and C3 vertebrae b) Cervical spine CT scan in axial plane presenting expansive lytic bone lesion c) Cervical spine MRI scan demonstrating typical appearance of lytic osseous lesion with intratumoral septa, with pockets of different stage bleeds.

process CIII. The lesion is LL 3.6 cm in diameter, AP 3 cm in diameter, CC 3.5 cm in diameter. The formation is predominantly T2 hyperintensity of the signal, with “fluid-fluid” levels, of intermediate intensity in the T1 measurement time. In the contrast study, there is more intense marginal opacification, and opacification of intratumoral septa. The lesion reduces lateral recess of CII-III level on the left, and neural foramina and compromises of C III and CIV roots on the left. Major bleeding during the procedure was estimated to be low in case of hypoplastic left vertebral artery injury and the possibility of vertebral sacrifice in case of running into major bleeding during the procedure was planned to be done intraoperatively by vascular clipping if needed.

Based on the clinical presentation and neuroradiological findings open surgical resection was indicated with the goal of subtotal or total resection. The location of the lesion mainly involved the posterior elements in the upper cervical spine which made the risk of post-surgical instability lower, which is why the decision was made not to immediately do posterior fusion of the cervical spine.

Patient was positioned prone using a head holder and a midline skin incision with bilateral subperiosteal muscle dissection was performed exposing expansive bone lesion that was then resected, accompanied by C3 laminectomy and adequate decompression of the neural structures. In the anterior column smaller part of the cyst was visualized microscopically in the lateral left dorsal part of C3 body where curettage and diathermy with monopolar cautery was done. High speed drilling was done in the margins of C2 lamina and the left facet joint that were affected. The lesion had intratumoral septa with pockets of different stage bleeds and there was no significant active bleeding during the resection. The blood loss encountered during the procedure was low. The histopathological findings confirmed an ABC with typical cavernous channels and osteoclastic and osteoblastic reaction. Early postoperative CT scan showed minimal residual bone lesions of C2 and C3 vertebrae, with some degree of kyphosis, as seen in Figures 1a and b.

The patient was discharged on the twelfth day after surgery without neurological deficits with his cervical

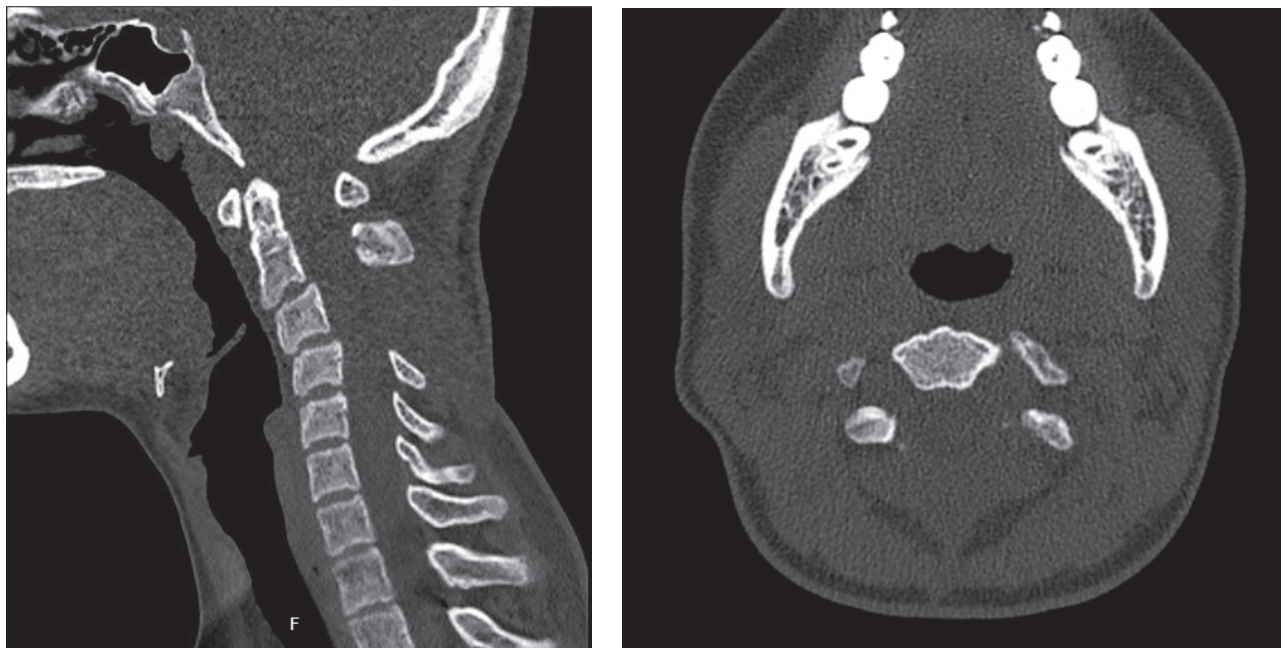


Fig. 2. a) Early postoperative cervical spine CT scan in sagittal plane after the resection of aneurysmal bone cyst (ABC) b) Cervical spine CT scan in axial plane demonstrating resection of bone lesion.

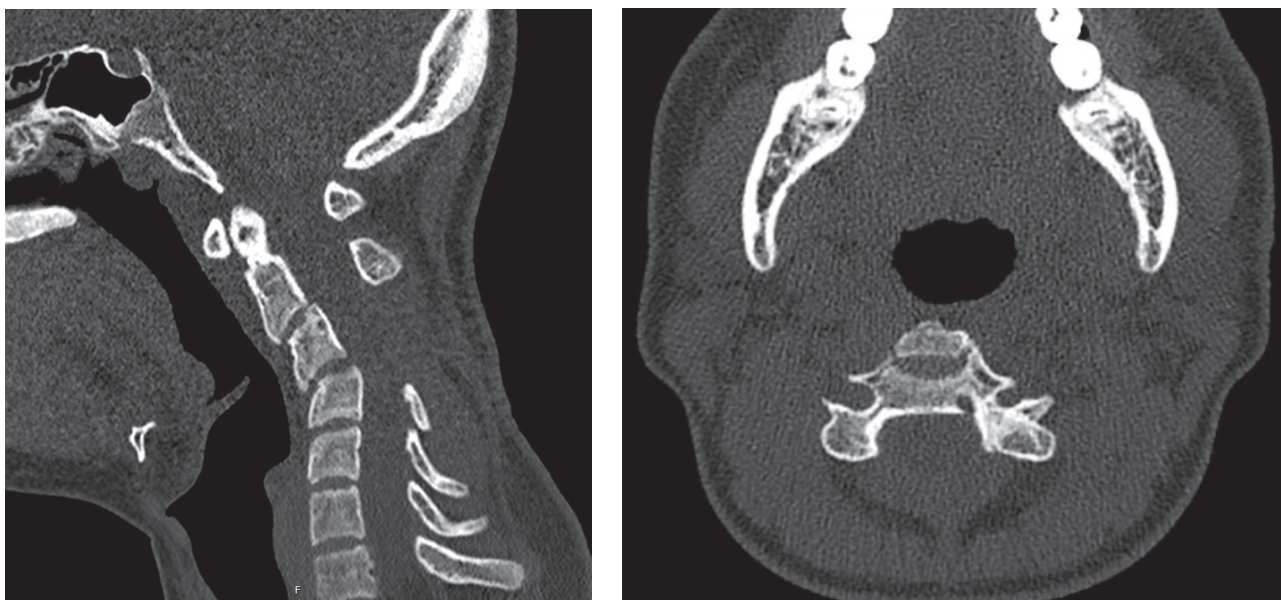

Fig. 3. a) Control CT scan after six months showed substantial progression of the cervical kyphosis and b) no residual cyst progression was seen in the left dorsal part of the C3 vertebra body.

spine immobilized in semi-rigid cervical collar because no cervical fusion was done. In the two-month clinical follow-up patient had good postoperative recovery without any symptoms and the cervical immobilization was removed. CT scans demonstrated no tumor recurrence or progression of the cervical kyphosis. Another control CT scan was

planned in a time period of 6 months after the operation and showed substantial progression of the cervical kyphosis with no residual cyst progression in the left dorsal part of the C3 vertebra body (Fig. 3). Patient had no symptoms but was considered to undergo anterior and posterior cervical fusion surgery concerning the spine stability.

Discussion

ABCs are described as benign bone lesions predominantly located in the metaphysis of the long bones and most of them express expansive and destructive growth affecting mainly pediatric population⁸. Cervical spine ABCs, though very rare, represent a great surgical challenge because of the close proximity or involvement of near neurovascular structures^{1–3}. Predominant predilection place of these lesions are posterior elements of the cervical spine mostly affecting one vertebrae with a great risk of vertebral artery injury⁹ although, our case demonstrated both anterior and posterior elements involvement of the two adjacent cervical vertebrae. Typical clinical presentation is neck pain, often without neurological deficits in the early stages, therefore detailed CT and MRI evaluation is necessary to make the diagnosis.

Even though the vast majority of these bone lesions can be successfully treated surgically there is a high recurrence rate, as high as 30%, mostly associated with subtotal surgical resection. However, total surgical resection should not compromise spinal stability or surrounding neurovascular structures, especially in regards to growing pediatric cervical spine^{2,3,10}. Previously described is in correlation with our presented case where there was evidence of minimal postoperative ABC residue in the anterior column, with no further growth in short six-month follow up period, but with significant spinal kyphosis progression. One of the most common postoperative deformities is postlaminectomy kyphosis that tends to progress during the adolescent growth and cervical spine instru-

mentation and fusion may be indicated, though some authors suggest that the preservation of facet joints is of the greatest importance for avoiding this complication¹⁰.

Some studies have shown a potential benefit of preoperative selective arterial embolization for blood loss control and occlusion of their arterial feeders, but also as a definitive treatment in some spinal ABC cases¹¹. Special care should be taken when using this method in patients with cervical spine aneurysmal lesions because there is a high risk of ischemic spinal cord damage¹². Regarding incomplete ABC resection, some authors consider radiotherapy as adjuvant therapy to be beneficial for the prophylaxis of tumor recurrence in patients with skeletal growth completion¹. Additionally, there are evidences in favor of sclerotherapy for treatment of spinal ABCs without compromised neural structures^{1,13}.

In regards to cervical spine ABCs interdisciplinary approach should be taken into consideration early in the course of the disease, though there is a high recurrence rate prognosis remains very good, especially after total surgical resection with or without fusion.

Conclusion

We described a rare case of a successfully treated cervical spine ABC and our therapeutic strategies; even though these lesions have high recurrence rate and could exemplify locally aggressive behavior treatment outcome is favorable. Furthermore, there is still a lack of evidence-based guidelines in ABC treatment and the need for further scientific and clinical research.

REFERENCES

1. RICHTER J, TSCHÖKE SK, GULOW J, EICHFELD U, WOJAN M, VON SALIS SOGLIO G, HEYDE CE, Patient Saf Surg, 5 (2011) 20. DOI: 10.1186/1754-9493-5-20. — 2. RAJASEKARAN S, AIYER S, SHETTY AP, KANNA R, MAHESWARAN A, Eur Spine J, 28 (2016) 270. DOI: 10.1007/s00586-016-4518-0. — 3. FRASSANITO P, D'ONOFRIO G, PENNISI G, MASSIMI L, TAMBURRINI G, MUTO M, CALDARELLI M, World Neurosurg, 126 (2019) 423. DOI: 10.1016/j.wneu.2019.02.246. — 4. PROTAS M, JONES LW, SARDI JP, FISAHN C, IWANAGA J, OSKOUIAN RJ, TUBBS RS, Pediatr Neurosurg, 52 (2017) 219. DOI: 10.1159/000475820. — 5. BORIANI S, LO SL, PUVANESARAJAH V, FISHER CG, VARGA PP, RHINES LD, GERMS-CHEID NM, LUZZATI A, CHOU D, REYNOLDS JJ, WILLIAMS RP, ZADNIK P, GROVES M, SCIUBBA DM, BETTEGOWDA C, GOKASLAN ZL, J Neurooncol, 120 (2014) 171. DOI: 10.1007/s11060-014-1540-0. — 6. SALUNKE P, CHANDRA BR, SURA S, AGGARWAL A, GARG R, J Neurosci Rural Pract, 3 (2012) 230. DOI: 10.4103/0976-3147.98270. — 7. JOAQUIM AF, GIACOMINI L, GHIZONI E, TEDESCHI H, J Neurosci Rural Pract, 5 (2014) 55. DOI: 10.4103/0976-3147.127874. — 8. MOHAIDAT ZM, AL-GHARAIBEH SR, ALJARARHIIH ON, NUSAIRAT MT, AL-OMARI AA, Adv Orthop, 4 (2019) 1. DOI: 10.1155/2019/2905671. — 9. SERTBAS I, KARATAY M, Turk Neurosurg, 30 (2020) 462. DOI: 10.5137/1019-5149.jtn.24614-18.2. — 10. SACCOMANNI B, Arch Orthop Trauma Surg, 128 (2007) 1145. DOI: 10.1007/s00402-007-0477-6. — 11. WANGQIN R, XU K, ROJAS H, RENZ, Interv Neuroradiol, 25 (2018) 330. DOI: 10.1177/1591019918810534. — 12. EHLERS LD, MCMORDIE J, LOOKIAN P, SURDELL D, PUC-CIONI M, World Neurosurg 139 (2020) 163. DOI: 10.1016/j.wneu.2020.04.005. — 13. DESAI SB, O'BRIEN C, SHAIKH R, ORBACH DB, PADUA H, Interv Neuroradiol, 25 (2019) 564. DOI: 10.1177/1591019919848130.

D. Mužević

*Department of Neurosurgery, Osijek Clinical Hospital Center, Josipa Huttlera 4, 31000 Osijek, Croatia
e-mail: dario.muzevic@mac.com*

ANEURIZMATSKE KOŠTANE CISTE CERVİKALNE KRALJEŠNICE – PRIKAZ SLUČAJA I PREGLED LITERATURE

SAŽETAK

Aneurizmatska koštana cista je ne-neoplastična, lokalno destruktivna primarna koštana lezija koja se najčešće javlja u prva dva desetljeća života pretežno zahvaćajući ženski spol. Aneurizmatske koštane ciste cervikalne kralješnice predstavljaju vrlo rijedak klinički entitet koji zahtijeva detaljnu kiruršku resekciju većim dijelom limitiranu okolnim neurovaskularnim strukturama i potencijalnim razvojem instabiliteta cervikalne kralješnice. Predstavljamo slučaj 17-godišnjeg bolesnika sa simptomatskom aneurizmatskom koštanom cistom cervikalne kralješnice kojemu je kirurški uklonjena koštana lezija uz zadovoljavajući poslijeoperacijski ishod. Postoje različite terapijske opcije za liječenje aneurizmatskih koštanih cisti, ali potpuna kirurška resekcija ostaje jedan od najvažnijih prognostičkih čimbenika povoljnog ishoda, iako često ograničena, posebno u cervikalnom području. Prethodno opisane lezije imaju vrlo visoku stopu recidiva te se uz kirurško liječenje, kao dodatne terapijske metode, primjenjuju i radioterapija, embolizacija i sklerozacija. Daljnja su istraživanja nužna za razvoj znanstveno utemeljenih terapijskih protokola za liječenje aneurizmatskih koštanih cisti u pedijatrijskoj populaciji.