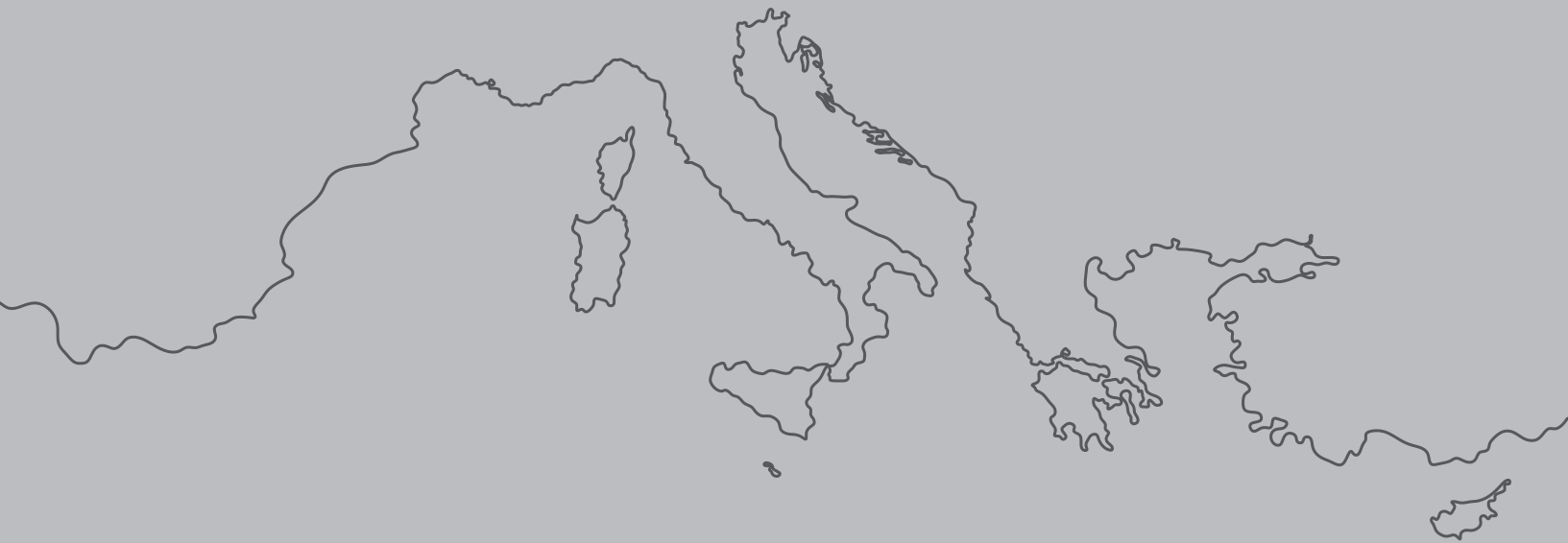

This Special Issue is published in tribute to the
Croatian Society of Orthodontics Congress
“Orthodontics – this time tomorrow”
that was planned for December 2020
but was canceled due to covid-19 pandemics.



*Responsibility for the contents of the special issue articles rests upon the authors
and not upon SEJODR, the Editors, or the Publisher*

Assessment of facial landmarks for bone asymmetry in geometric morphometric studies: A review

Ivana Rupić¹, Ivana Čuković-Bagić², Vladimir Ivković^{3,4}, Tomislav Lauc^{1,5,6}

¹ *Apolonija Dental Clinic, Zagreb, Croatia*

² *Department of Paediatric and Preventive Dentistry, School of Dental Medicine, University of Zagreb, Croatia*

³ *Department of Psychiatry, Massachusetts General Hospital, Charlestown, MA, United States*

⁴ *Department of Psychiatry, Harvard Medical School, Boston, MA, United States.*

⁵ *Study of Anthropology, Faculty of Social Sciences and Humanities, University of Zagreb, Croatia*

⁶ *School of Dental Medicine, University of Zagreb, Croatia*

ABSTRACT

Background: Anthropometrical points or landmarks are key for facial shape analysis using geometric morphometrics. In the early 1990s, Fred Bookstein created a classification system with landmarks type 1, type 2, type 3 based on anatomical landmark homology. However, thirty years later, a uniform directory index of landmarks that can be used for assessing facial asymmetry still does not exist. The criteria for selecting landmark points are not fully defined, making homology classification and landmarks prone to arbitrary interpretations. A literature review indicates that the authors of studies do not explain the reason for choosing exact points. Most of them also do not provide a clear definition of landmarks and landmarks classification, according to homology.

Objective: The review's objective was to assess, in an evidence-based manner, which landmarks on hard facial tissues can be recommended for facial asymmetry assessment using geometric morphometrics. This selection of landmarks can provide a better comparison to future studies and can have clinical relevance in orthodontic diagnostics.

Search methods: An electronic search of 9 databases up to March 2020 by two reviewers was conducted to identify relevant articles.

Selection criteria: Prospective randomized, non-randomized controlled trials and cross-sectional studies report facial asymmetry using three-dimensional images and geometric morphometric methods. The reasons for assessing facial asymmetry were not considered.

Data collection and analysis: The 23 selected studies were categorized according to the number and specification of the research subjects, types of three-dimensional images, the number of landmarks, and the craniofacial region of interest. All landmarks were extracted with the following data: name, abbreviation, and the author's definition of the location.

Results: The craniofacial system is divided into the neurobasicranial region, ethmomaxillary region and the mandible. Assessment of neurobasicranial asymmetry was conducted in 6 studies and 45 different landmarks were recorded, of which 11 were medial and 34 bilateral. Bregma and Lambda occur most frequently and according to homology, both belong to type 1 landmarks. Assessment of ethmomaxillary asymmetry was conducted in 21 studies and 68 different landmarks were recorded, of which 16 were medial and 52 bilateral. Nasion and Jugale occur most frequently and according to homology, Nasion belongs to type 1 landmarks and Jugale to type 2 landmarks.

Conclusion: The review provides an extensive cross-section of possible landmarks with the definition of the location and the possible location variation. The list of these landmarks should be observed through the classification of landmarks according to their homology and possible classification variations. The proper selection of landmarks in facial analyses of symmetry is of utmost importance and landmarks should be comparable among many studies. As a result of this study, the authors recommend using a specific number of high-value and comparable landmarks to be of great relevance for asymmetry analysis of facial structures.

Rupić I, Čuković-Bagić I, Ivković V, Lauc T. Assessment of facial landmarks for bone asymmetry in geometric morphometric studies: a review. *South Eur J Orthod Dentofac Res.* 2020;7(S1):6-16.

Corresponding Author:

Ivana Rupić

Apolonija Dental Clinic

Zagreb, Croatia

email: ivana.rupic@apolonija.hr

INTRODUCTION

Rationale

Facial asymmetry is defined as any deviation from the identical shape or size of two sides of the face and is one of the most common facial features. Asymmetry affects facial aesthetics^{1,2} and occlusal function³⁻⁵, so the assessment of facial asymmetry should be part of the regular facial clinical examination in dental medicine and particularly in orthodontics. Also, the assessment of asymmetry is used in biological anthropology for shape analysis of asymmetry in a study of evolution, especially for assessing developmental instability.⁶⁻⁸

The basis for morphometric analyses is anthropometric points or landmarks. Their characteristic is correspondence among specimens or objects in the sample, and if some of them are missing, their position can generally be reconstructed. Landmarks are used to measure the dimensions and interrelationships of individual anatomical structures.

Landmarks' correspondence is often referred to as homology and can be from the common evolutionary origin (i.e., taxic homology)⁹ or anatomical, developmental, or functional correspondence or equivalency (i.e., operational homology).¹⁰⁻¹³ In his fundamental publication from 1991¹⁴, Bookstein defined a classification system based on landmark position and homology that is still referent for their validation. Landmarks are categorized as types 1, 2, or 3 based on their structural and geometrical localisation.^{14,15}

Homology of type I landmarks has the strongest evidence, mostly in an anatomical or evolutionary sense. Their position is strict and recognizable, mostly at the juxtaposition of anatomical or histological structures. Type 2 and type 3 are landmarks on anatomical structures with a predominant geometric definition. Where the top of some structure or anatomical curvature can be determined accurately, then we consider landmark type 2. Type 3 is a landmark that is on the curvature or surface and their position is defined with another, more distant structure.¹⁴ Still, in many studies, there are undefined criteria for selecting landmarks and the classification of homology. This increases "arbitrarily" selected landmarks are prone to different interpretations. Searching the literature, most authors do not declare the reasons for choosing some landmarks, and most of them do not have a clearly defined classification of homology and the definition itself.

Thus, it is unclear if the results of facial asymmetry assessment performed in different studies can be compared with each other? The noted ambiguities in landmark definition can be avoided by adopting a uniform classification and definition of landmarks. Future facial asymmetry analyses should also choose landmarks that have been used in other studies to increase the external validity of their results. Therefore, there is a need to systematize landmarks used for assessments of facial asymmetry according to the criteria of homology and the frequency of landmark use

in scientific research. Also, summarizing the available literature in this field has a practical benefit for investigating facial asymmetry using geometric morphometrics.

Objectives

This review's objective was to assess which landmarks should be recommended as standard landmarks for facial asymmetry assessments using geometric morphometrics. The use of landmarks that are more commonly represented in the asymmetry analyses can provide a better comparison to the data from other similar studies. In different medical fields such as orthodontics or maxillofacial surgery, for estimation of facial asymmetry, it is of clinical importance to valorize the facial anthropometric point or morphometric landmarks that can be used with greater relevance. Therefore, a modified PRISMA review method was used to review anthropological studies with the methodology used in clinical medicine. This study's final intention was to implement anthropological research within a clinical application in the field of maxillofacial surgery, orthodontics, and esthetic medicine.

MATERIALS AND METHODS

Protocol and registration

This review was based on the guidelines provided by the PRISMA statement¹⁶ and the Cochrane Handbook for Systematic Reviews of Interventions (version 5.1.0)¹⁷ with adjustments in order to analyze anthropological studies and is available upon request.

Information sources and search

Electronic searches were conducted for studies published up to March 2020. The reference lists of the articles eligible for inclusion in this review were also manually reviewed. For every database, keyword and Medical Subject Headings (MeSH) terms were carefully chosen, while the search strategy was structured to fit the specific requirements of the respective database. Two authors (IR and TL) conducted the search strategy. Citations of articles published in journals, dissertations and conference proceedings were located from several electronic databases by a search strategy appropriately adjusted for each individual database (Table 1). No restrictions were applied concerning the publication year or status. Only English literature was included in the search.

Eligibility criteria and study selection

The eligibility criteria were predetermined (Table 2, 3 and Figure 1.). A study was considered eligible when assessing the face and skull's skeleton was done solely on three-dimensional recordings. Studies in which a human ancestor was taken as a control group were not considered. Some of the inclusion criteria were: participants of any age and a clearly defined list of landmarks names. After eliminating duplicates, the selection was made by considering the title and abstract separately by two authors (IR and TL). If any of the two authors selected some study based on the title and abstract, the study was included.

Table 1. The Electronic Databases Searched and the Search Strategy Used in the Review (as of March 25, 2020)

Databases of Published Trials	Search Strategy Used	Hits
MEDLINE searched via PubMed www.ncbi.nlm.nih.gov/sites/entrez	[(randomized controlled trial[pt] OR controlled clinical trial[pt] OR randomized controlled trials[mh] OR random allocation[mh] OR double-blind method[mh] OR single-blind method[mh] OR clinical trial[pt] OR clinical trials[mh]) OR ("clinical trial"[tw]) OR ((singl*[tw] OR doubl*[tw] OR trebl*[tw] OR tripl*[tw]) AND (mask*[tw] OR blind*[tw])) OR (placebos[mh] OR placebo*[tw] OR random*[tw] OR research design[mh:noexp] OR comparative study OR evaluation studies OR follow-up studies [mh] OR prospective studies[mh] OR control*[tw] OR prospectiv*[tw] OR volunteer*[tw])] AND [(face asymmetry*) OR (facial asymmetry*) OR (skull asymmetry*) AND [(hard tissue*) OR (bone) OR (skeletal)] AND [(geometric morphometrics*)] AND [(humans)]	16
EMBASE searched via ScienceDirect www.embase.com	[[(('phase-4-clinical-trial'/exp OR 'phase-4-clinical-trial' OR ('randomized-controltrial') OR ('randomization'/exp OR 'randomization') OR ('controlled-study'/exp OR 'controlled-study') OR ('multicenter-study'/exp OR 'multicenter-study') OR ('phase-3-clinical-trial'/exp OR 'phase-3-clinical-trial') OR ('double-blind-procedure'/exp OR 'double-blind-procedure') OR ('single-blind-procedure'/exp OR 'single-blindprocedure')) OR (random*:ab OR cross?over*:ab OR factorial*:ab OR placebo*:ab OR volunteer*:ab) OR (random*:ti OR cross over*:ti OR factorial*:ti OR placebo*:ti OR volunteer*:ti) OR ((singl* OR doubl* OR trebl* OR tripl*) AND near AND (blind*:ti OR mask*:ti)) OR ((singl* OR doubl* OR trebl* OR tripl*) AND near AND (blind*:ab OR mask*:ab))) NOT [(('animal'/exp OR 'animal') OR ('nonhuman'/exp OR 'nonhuman'))) NOT [(('animal'/exp OR 'animal') OR ('nonhuman'/exp OR 'nonhuman'))) AND ('human'/exp OR 'human'))] AND [(face asymmetry*) OR (facial asymmetry*) OR (skull asymmetry*) AND [(hard tissue*) OR (bone) OR (skeletal)] AND [(geometric morphometrics*)] AND [(humans)]	21
Cochrane Central Register of Controlled Trials searched via The Cochrane Library	[(face asymmetry*) OR (facial asymmetry*) OR (skull asymmetry*)] AND [(hard tissue*) OR (bone) OR (skeletal)] AND [(geometric morphometrics*)] AND [(humans)]	0
Google Scholar Beta www.scholar.google.com	[(face asymmetry*) OR (facial asymmetry*) OR (skull asymmetry*)] AND [(hard tissue*) OR (bone) OR (skeletal)] AND [(geometric morphometrics*)] AND [(humans)]	314
Databases of published trials Web of Science http://scientific.thomson.com/products/wos/	randomized controlled trial[pt] OR controlled clinical trial[pt] OR randomized controlled trials[mh] OR random allocation[mh] OR double-blind method[mh] OR single-blind method[mh] OR clinical trial[pt] OR clinical trials[mh]) OR ("clinical trial"[tw]) OR ((singl*[tw] OR doubl*[tw] OR trebl*[tw] OR tripl*[tw]) AND (mask*[tw] OR blind*[tw])) OR (placebos[mh] OR placebo*[tw] OR random*[tw] OR research design[mh:noexp] OR comparative study OR evaluation studies OR follow-up studies [mh] OR prospective studies[mh] OR control*[tw] OR prospectiv*[tw] OR volunteer*[tw]))] AND [(face asymmetry*) OR (facial asymmetry*) OR (skull asymmetry*) AND [(hard tissue*) OR (bone) OR (skeletal)] AND [(geometric morphometrics*)] AND [(humans)] Refined by: Subject Areas =ANTHROPOLOGY	46
Scopus www.scopus.com	[(face asymmetry*) OR (facial asymmetry*) OR (skull asymmetry*)] AND [(hard tissue*) OR (bone) OR (skeletal)] AND [(geometric morphometrics*)] AND [(humans)]	8
Windows Live Academic search live.com	("face asymmetry" OR "facial asymmetry" OR "skull asymmetry") and ("hard tissue" OR bone OR skeletal) AND ("geometric morphometrics") AND ((humans))	13
International Bibliography of Social and Cultural Anthropology via worldcat.org	("face asymmetry" OR "facial asymmetry" OR "skull asymmetry" and ("hard tissue" OR bone OR skeletal) AND ("geometric morphometrics") AND ((humans))	35
JSTOR via www.jstor.org	("face asymmetry" OR "facial asymmetry" OR "skull asymmetry") and ("hard tissue" OR bone OR skeletal) AND ("geometric morphometrics") AND ((humans)) Subject: Anthropology	31
Total		484

Table 2. The eligibility criteria inclusion and exclusion

Inclusion criteria	Exclusion criteria
Human participants of any age or gender	Animal studies Animal control group
Facial bone tissue asymmetry assessment using GM	Facial soft tissue or dental arch Sexual dimorphism Anatomical variation
A Control group is required	A Control group is not required
Anthropometric point/landmarks from 3D images	Two-dimensional digital images
Randomized controlled clinical trials (RCTs) Prospective controlled clinical trials (CCTs) Retrospective controlled cohort studies Cross-sectional surveys	Narrative reviews Systematic reviews Mini reviews Case-control observational studies Case series Case report The unsupported opinion of an expert Editor's choices Books' abstract Conference abstract Animal studies Books' chapter Dissertation Books

Table 3. Eligibility exclusion criteria used for the study selection

Reason for exclusion	Excluded articles based on title and abstract*	Excluded articles based on full text*
Facial soft tissue asymmetry assessment	16	30
Dental Arch asymmetry	-	1
Narrative review	-	1
Mini review	-	1
Systematic review	-	12
Case report	6	3
Assessment Homo florensensis face	8	2
Animal study	34	8
Book chapter	5	2
Two-dimensional digital image	25	2
Dissertation	2	4
Book	9	3
Sexual dimorphism	4	2
Anatomical variation of other parts of the body	19	10
Assessment of only tooth morphology	-	2
Assessment ears asymmetry	1	-
Evolution changes	5	3
Insufficient data about the analysis landmarks	-	6

*Additional list of excluded studies available upon request

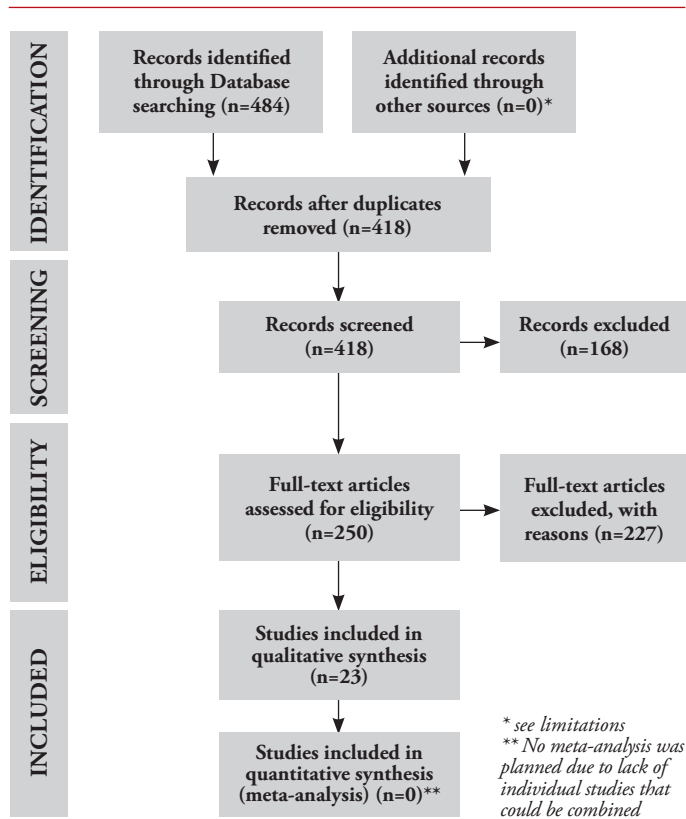


Figure 1. Flow diagram with the number of excluded studies¹⁶

Table 4. Characteristics of the studies included in this study. (ROI- region of interest, NBC – neurobasicranial region, EMC – ethmomaxillary region, MN – mandible, NR – not reported)

A/A Study	Setting	Characteristics of patients/ subjects	3D images	No of patients, objects	Number of landmarks	ROI	Conflict of interest
Starbuck et al., 2015. ¹⁸	University, Indianapolis	Children with bilateral cleft lip and palate	CBCT	30	20	EMC, MN	NR
Bigoni et al., 2013. ¹⁹	Faculty of Science, Czech	Adult crania	MicroScribe G2X contact digitizer	138	39	EMC	NR
Hartman et al., 2016. ²⁰	University, Iowa	Adult subjects geographically diverse	CT	55	26	NBC, EMC	NR
Ruskova et al., 2014. ²¹	Faculty of Science, Czech	Patients with unilateral complete cleft lip and palate	Laser scanner	58	4	EMC	NR
Schlager et al., 2015. ²²	University, Germany	Scans were taken in two hospitals	CT	534	9	EMC	NR
Chovalopoulou et al., 2017. ²³	Laboratory for Archaeological Science, Greece	Adult crania	Microscribe 3DX contact digitizer	173	77	NBC, EMC	NR
Ibrova et al., 2017. ²⁴	Faculty of Science, Czech	Early Medieval skeletal material	MicroScribe G2X digitizing system	193	20	MN	NR
Fuessinger et al., 2018. ²⁵	University, Freiburg	Adult crania	CT	131	4	EMC	NR
Ceuninck et al., 2019. ²⁶	University, Florida	Children and adolescents	CBCT	24	14	EMC	NR
Ridel et al., 2020. ²⁷	University, Pretoria	Adult South Africans	CBCT	10	42	NBC, EMC	NR
Jung et al., 2018. ²⁸	University, Buffalo, NY	Adult skull	MicroScribe G2X digitizing system	74	52	NBC, EMC	NR
Espinosa et al., 2019. ²⁹	Hospital, Santiago	Hospital patients	CT	60	16	MN	NR
Weisensee et al., 2018. ³⁰	Clemson University, USA	Undocumented border crossers	Microscribe 3DX digitizer	509	14	EMC	NR
Benazzi et al., 2011. ³¹	University, Austria	Skulls	CT	11	162	EMC	NR
Weisensee et al., 2013. ³²	Clemson University, USA	New Lisbon skeletal collection	Microscribe 3DX digitizer	392	31	NBC, EMC	NR
Katsube et al., 2019. ³³	University, Japan	Fetus 15 and 20 weeks of gestation	μCT	21	46	EMC, MN	NR
Nur et al., 2016. ³⁴	Yeditepe University, Turkey	Patients	CBCT	89	13	NBC, EMC, MN	NR
Nikkhan et al., 2013. ³⁵	University, France	Patient with Treacher-Collins syndrome	CT	39	96	EMC, MN	NR
Ridel et al., 2018. ³⁶	University, South Africa	Adult South Africans	CBCT	120	12	EMC	NR
Senck et al., 2013. ³⁷	University of Austria	Human skull	CT	25	614	EMC	NR
Ketoff et al., 2016. ³⁸	Hospital, France	Skull	CT	49	3	EMC	NR
Ahmad et al., 2018. ³⁹	University, Florida	Children	CT	52	23	EMC	NR
Fukase et al., 2015. ⁴⁰	University, Japan	Skull	CT	126	9	EMC	NR

In contrast, assessment of facial asymmetry using landmarks type 3 represents the most significant risk of bias. Therefore, each landmark from all studies are classified in type 1, 2 or 3. To minimize the risk of bias in defining the position of landmarks, the homology classification variation (VOC) category was also used in this review.

Table 5. Landmarks used in included studies

Study	Number of landmarks	Anatomical landmarks (Number)	Semilandmarks	Number of participants/subjects
Starbuck et al., 2015. ¹⁸	20	20	0	30
Bigoni et al., 2013. ¹⁹	39	39	0	138
Hartman et al., 2016. ²⁰	26	26	0	55
Ruskova et al., 2014. ²¹	3	3	0	58
Schlager et al., 2015. ²²	9	9	0	534
Chovalopoulou et al., 2017. ²³	77	77	0	173
Ibrova et al., 2017. ²⁴	20	20	0	193
Fuessinger et al., 2018. ²⁵	4	4	0	131
Ceuninck et al., 2019. ²⁶	14	14	0	24
Ridel et al., 2020. ²⁷	42	42	0	10
Jung et al., 2018. ²⁸	52	52	0	74
Espinosa et al., 2019. ²⁹	16	16	0	60
Weisensee et al., 2018. ³⁰	14	14	0	509
Benazzi et al., 2011. ³¹	157	11	146	162
Weisensee et al., 2013. ³²	31	31	0	392
Katsube et al., 2019. ³³	46	46	0	21
Nur et al., 2016. ³⁴	13	13	0	89
Nikkhan et al., 2013. ³⁵	96	96	0	39
Ridel et al., 2018. ³⁶	12	12	0	120
Senck et al., 2013. ³⁷	614	47	567	25
Ketoff et al., 2016. ³⁸	3	3	0	49
Ahmad et al., 2018. ³⁹	23	23	0	52
Fukase et al., 2015. ⁴⁰	9	9	0	126

Table 6. Semilandmarks used in included studies

Curve names	Semi-Landmarks identified on Curves Count	Frequency of occurrence
Alveolar right	9	1
Alveolar left	9	1
Lower zygomaticotemporal outline left	10	1
Orbital left	14	1
Orbital right	8	1
Upper zygomaticotemporal outline left	15	1
Temporal left	4	1
Temporal right	4	1

RESULTS

The craniofacial system is divided into neurobasicranial region, ethmomaxillary region and the mandible. The results present a list of landmarks distributed among three regions, mostly used in selected studies for three-dimensional assessment of craniofacial asymmetry using geometric morphometrics.

Landmarks without definition were considered as non-repeatable and were not included in the list. The column *Definition* represents the definition noted in the study, and the *Definition variation* represents all other possible variations of the definition of the selected point. Each landmark is classified according to the Bookstein classification.

Landmarks in neurobasicranial region

Assessment of neurobasicranial asymmetry was conducted in 6 studies and 45 different landmarks were recorded, of which 11 were medial and 34 bilateral. Bregma and Lambda occur most frequently and according to homology, both belong to type 1 landmarks (Table 7.).

Landmarks in ethmomaxillary region

Assessment of ethmomaxillary asymmetry was conducted in 21 studies and 67 different landmarks were recorded, of which 16 were medial and 52 bilateral. Nasion and Jugale occur most frequently and according to homology Nasion belongs to type 1 landmarks and Jugale to type 2 landmarks.

Landmarks in region mandible

Assessment of mandibular asymmetry was conducted in 6 studies and 41 different landmarks were recorded, of which 10 were medial and 31 bilateral. The Gonion and Condyle appear the most times/frequently and according to the homology, Gonion belongs to the type 3 landmarks and the Condyle to the type 2 landmarks (Table 9).

DISCUSSION

Summary of evidence

A large variety of landmarks is used in geometric morphometric research of facial asymmetry. When using geometric morphometrics to investigate facial asymmetry, all objects or individuals in the sample should have the same set of landmarks that correspond together with the same position relative to other landmarks.⁴² This exact position is of particular importance in symmetry analyses when using bilateral or medial (unilateral) landmarks.

As expected, the ethmomaxillary region has been the subject of most facial asymmetry studies with the widest variety of used landmarks. In all three regions, a variation of landmark types is present with predominant landmarks type 2. As type 1 landmarks are mostly defined at the juxtaposition of different anatomical structures or bones, they are more often registered among unilateral medial landmarks. For that reason, in the region of mandible landmarks type 1 are very rare.

Table 7. Landmarks in the neurobasicranial region (*Abb.* – abbreviation, *M/B* – midline or bilateral, *Definition* – definition of landmarks, *Class* – Bookstein's types or homology classification, *VOC* – a variation of homology classification, *FOC* – frequency of occurrence landmarks in included studies)

Landmarks	Abb	M/B	Definition	Class	VOC	FOC
Bregma	brg	M	Intersection of the sutura coronalis and sutura sagittalis in the midsagittal plane.	1	None	8
Lambda	lam	M	Intersection of the sutura sagittalis and lambdoidal sutura in the midsagittal plane.	1	None	8
Glabella	G, g, GB or GLB	M	The most prominent point between the supraorbital ridges in the midsagittal plane. The most anterior midline point on the frontal bone, usually above the frontonasal suture.	2	3	7
Basion	Bas, ba	M	Lowest midline point on the anterior margin of the foramen magnum. The most inferior posterior point in the sagittal plane on the anterior rim of the foramen magnum.	2	3	6
Asterion	ast	B	Intersection of the sutura lambdoidea, sutura parietomastoidea and sutura occipitomastoidea.	1	None	5
Porion	Po or P	B	Uppermost point on the margin of the external acoustic meatus.	3	2	5
Opisthocranium	ops	M	The midline ectocranial point at the farthest chord length from Glabella.	2	3	4
Opisthion	Op or o	M	The midpoint of the posterior margin of the foramen magnum in the midsagittal plane. The most posterior point, relative to the interspinosum line, on the border of the foramen magnum.	2	1,3	4
Auriculare	au	B	Intersection of the base of zygomatic arch and the midline of the opening of the meatus acusticus externus.	3	1	3
Caroticum mediale/Carotid canal	med	B	The most medial point on the margin of the foramen caroticum externum. The most medial point on the carotid canal.	3	None	3
Sphenion	sph	B	Intersection of the sutura coronalis, sutura sphenoparietalis, and sutura sphenofrontalis.	1	3	3
Suture line ZT	ZT	B	Midpoint of the zygomaticotemporal suture.	3	None	3
Stephanion	None	B	The point where the coronal suture crosses the (inferior) temporal line.	2	1	3
Carotid canal (lat)	lat	B	The most lateral point on the carotid canal.	3	None	2
Coronale	cor	B	One of the two most widely separated points on the sutura coronalis at the poles of the greatest frontal diameter.	3	None	2
Crotaphion	cro	B	Intersection of the sutura sphenosquamosa, sutura sphenoparietalis and sutura squamosa.	1	None	2
Entomion	ent	B	The point, where the sutura squamosa passes into sutura parietomastoidea.	1	None	2
Foramen ovale	pos	B	The most posterior point on the foramen ovale.	3	None	2
Foraminolaterale	fl	B	The most lateral point on the margin of the foramen magnum.	3	None	2
Hormion	hor	M	Intersection of the midsagittal plane and the line where the base of the vomer meets os sphenoidale. The junction of the posterior border of the lateral pterygoid plate with the lower border of the posterior cranial base.	1	None	2
Krotaphion	kro	B	The most posterior extent of the sphenoparietal suture.	1	None	2
Occipitocondylion anterior	Occ ant	B	The most anterior point on the margin of the condylus occipitalis.	3	None	2
Occipitocondylion laterale	Occ lat	B	The most lateral point on the margin of the condylus occipitalis.	3	None	2
Ovale mediale	om	B	The most medial point on the margin of the foramen ovale.	3	None	2
Sphenomaxillare	Sph sup	M	The most superior, lateral point of contact between the maxilla and the lateral pterygoid plate of the sphenoid.	3	None	2
Stenion	ste	B	The most medial point on sphenosquamosal sutures.	3	None	2
External palate length	Ex pl	B	The point on the inferior surface of the maxilla that denotes the most posterior point of the alveolar process.	3	None	1
Foramen magnum	fm	B	The most lateral point on the margin of the foramen magnum.	3	None	1
Foramen jugulare	fj	B	The most lateral point on the margin of the foramen jugulare.	3	None	1
Foramen ovale (ant)	Fo ant	B	The most anterior point on the foramen ovale.	3	None	1
Infratemporale	it	B	Intersection of the sutura sphenosquamosa and crista infratemporalis of the sphenoid bone.	1	None	1
Landmark x	x	B	Intersection of the sutura sphenozygomatica, sutura sphenofrontalis and sutura frontozygomatica.	1	None	1
Maxillonasofrontale	mnf	B	Intersection of the sutura frontonasalis, sutura frontomaxillaris and sutura nasomaxillaris.	1	None	1
Occipital protuberance	None	B	Most prominent part of the occipital bone at the posteroinferior part of the skull.	2	None	1
Occipitocondylion mediale	None	B	The most medial point on the margin of the condylus occipitalis.	3	None	1
Occipitocondylion posterior	None	B	The most posterior point on the margin of the condylus occipitalis.	3	None	1
Petrosal	pt	B	The most anterior point of the petrous element of the temporal bone.	2	None	1
Piriform aperture	ap	B	Apex of the nasal aperture.	2	None	1
Piriform curvature	cp	B	Most infero-lateral point of the piriform aperture.	3	None	1
Sela	S or s	M	Center of the hypophyseal fossa.	3	None	1
Spinale	sp	B	The most medial point on the margin of the foramen spinosum.	3	None	1
Staurion	sta	M	The point of intersection of the median and transverse palatine sutures.	3	None	1
Staphylion	sph	M	The point where the interpalatal suture intersects a line joining the deepest indentation of the posterior Palate.	2	1	1
Styloid foramen	sf	B	The most anterior, inferior point on the styloid foramen.	2	None	1
Supramastoid crest-squamous suture intersection	None	B	Point at which the frontozygomatic suture intersects the inner orbital rim.	1	None	1

Table 8. Landmarks in the etiomaxillary region (*Abb.* – abbreviation, *M/B* – midline or bilateral, *Definition* – definition of landmarks, *Class* – Bookstein's types or homology classification, *VOC* – variation of homology classification, *FOC* – frequency of occurrence landmarks in included studies).

Landmarks	Abb	M/B	Definition	Class	VOC	FOC
Nasion	n or NA	M	Superior midline intersection of the nasal bones. The middle of the sutura nasofrontalis in the midsagittal plane.	1	None	17
Jugale/jugulare	ju or J	B	The point in the depth of the notch between the temporal and frontal processes of the zygomatic bone. The point at the union of the processus frontalis and processus temporalis of the os zygomaticus.	2	None	12
Alare	al or alar	B	Instrumentally determined as the most lateral point on the nasal aperture in a transverse plane.	3	None	10
Rhinion	rhi or R	M	The anterior tip of the nasal bones. The most anterior inferior point on the tips of the nasal bone as seen from norma lateralis.	2	None	10
Zygomaxillare	ZM	B	The most inferior point of the zygomaticomaxillary suture. A craniometric point located externally at the lowest extent of the zygomaticomaxillary suture.	1	2	10
Ectoconchion	ecco	B	The most lateral point on the lateral orbital margin.	2	1, 3	8
Prosthion	pr or pro	M	Median point between the central incisors on the anterior most margin. The most anterior point on the maxillary alveolar process in the midline.	1	2	8
Anterior nasal spine	ans	M	The anterior most pointed projection of the intermaxillary suture. A pointed projection at the anterior extremity of the intermaxillary suture; the tip.	2	None	7
Frontomalare orbitale	frontorbit	B	Intersection of the sutura frontozygomatica and the lateral margin of the orbit. Relating to the frontal and zygomatic bones.	2	1,3	7
Frontomalare temporale	frontotemp	B	The most posterior/lateral point on the sutura frontozygomatica. The most anterior point of the linea temporalis on the os frontalis.	2	1,3	7
Ectomalare	ect	B	Positioned at the most lateral point on the lateral surface of the alveolar crest. Found along the second molar on the maxilla.	3	2	6
Zygotemporale superior/ zygomatic arch	za	B	The most superior point on the sutura Zygomaticotemporalis. Most anterior, lateral, and midpoint of the zygomaticomaxillary suture on the zygomatic arch.	2	None	6
Mastoidale	mast	B	The most inferior point on the processus mastoideus.	2	1	5
Maxillofrontale	mf	B	Intersection of sutura frontomaxillaris and the Anterior lacrimal crest. Estimated by the point on the suture closest to the point where the orbital rim flattens. Intersection of the sutura frontomaxillaris and the medial margin of the orbit.	1	None	5
Nasospinale	ns	M	Intersection of the substance/chord inferior margins of the apertura piriformis and the midsagittal plane. The point of intersection of a line uniting the lowest points on the margin of each nasal opening with the midsagittal plane.	1	2	5
Orbitale	or or orb	B	Most inferior point on the inferior orbital rim. Usually falls along the lateral half of the orbital margin. The lowest point on the lower edge of the cranial orbit.	3	1,2	5
Zygotemporale inferior	zyti	B	The most inferior point on the sutura Zygomaticotemporalis. Lowest point of the zygomaticotemporal suture, at the top of the zygomatic tubercle.	2	None	5
A point /subspinale	A or ss	M	The deepest point seen in the profile view below the anterior nasal spine (orthodontic point A). The most posterior point on the curvature from the anterior nasal spine to the crest of the maxillary alveolar process.	3	None	4
Infraorbitale	ib	B	The most lateral point on the margin of the foramen infraorbitale.	2	None	4
Apertion	Aper	B	The most lateral point on the nasal aperture.	3	None	3
Articular eminence/Articulare eminence/Articulare	Ar	B	Point posterior to the inferior point of the tubercle of the zygoma. The points intersection of the dorsal contours of the process articularis mandibulae and os temporalis.	2	None	3
Endoconchion	enco	B	The most medial point on the medial orbital margin.	3	None	3
Frontale	fle	B	The point of medial most constriction of the frontal bone superior to the lateral orbital rim.	1	None	3
Dacryon	dac	B	Point where frontolacrimal and lacrimomaxillary sutures intersect.	1	None	3
Infra M1	Im1	B	The point located on the alveolar process at the level of the middle of the first lower molar.	1	None	3
Labrale Superius	ls	M	The midline point at the most anterior edge of the superior alveolar ridge of the maxillae, centered between the maxillary central incisors at the level of the cementum–enamel junction.	3	None	3
Mid-Infraorbital	mio	B	Centered lower part of the margin of the orbit.	3	None	3
Mid-Supraorbital	mso	B	The centered upper part of the orbital margin.	3	None	3
Nariale	nar	B	Beginning of the transition of the lower border of the apertura nasalis into the structure of the nasospinale.	3	None	3
Nasale inferius	nlhi	B	Most inferior point on nasal aperture.	2	None	3
Zygoorbitale	zo	B	Intersection of the orbital margin and the zygomaticomaxillary suture.	1	None	3
Zygomatiko-frontale (zygo)	zygo	B	Intersection of zygomaticomaxillary suture at orbital margin.	1	None	3
Canine	cn	B	Mesial to C, alveolar border.	3	None	2
Incisivon	incs	M	The most posterior inferior point on the incisive fossa.	2	None	2
Lateral border nasal aperture	lbna	B	The most lateral point on the lateral border of the nasal aperture.	3	None	2
Palatomaxillare	plmx	M	The point of intersection of the palatine and the maxillary bones.	1	None	2
Subconchion	Sub co	B	Intersection of the inferior margin of the orbit and normal to the line mf–ec.	1	None	2
Supraconchion	Supra co	B	Intersection of the superior margin of the orbit and normal to the line mf–ec.	1	None	2
Akantion	ak	M	Most anterior midline point of the nasal spine.	3	None	1
Alveolon	alv	M	The point where the interpalatal suture intersects the line joining the posterior margins of the alveolar Proces.	3	None	1
C/P3	None	B	The most inferior external point between the maxillary canine and the first pre-molar.	3	None	1
Foramen incisivum	fi	M	The most anterior points of the bone ridge of foramen incisivum.	1	None	1
Foramen infraorbitale	finfra	B	The most anterior points of the bone ridge of foramen infraorbitale.	1	None	1
Foramen palatinum majus	fpm	B	The most anterior points of the bone ridge of foramen palatinum majus.	1	None	1
FRED	None	B	The point of intersection of the frontozygomatic, zygomaticosphenoid and sphenofrontal sutures.	1	None	1
Frontomalare anterior	fma	B	Most lateral point on fronto-malar suture.	2	None	1
Incisive fossa	-	B	Just below incisor teeth; most concave depression incisive fossa.	3	None	1

Table 8. *Cont'd*

Landmarks	Abb	M/B	Definition	Class	VOC	FOC
Labrale Inferius	ll	M	The midline point at the most inferior edge of the inferior alveolar ridge of the mandible, centered between the mandibular central incisors at the level of the cementum–enamel junction.	3	None	1
Mastoidale (ant)	Mst ant	B	The anterior point of intersection of the mastoid process and the external tympanic plate.	2	None	1
Mastoidale (post)	Mst post	B	The posterior point of intersection of the mastoid process and the digastric groove.	2	None	1
Max maxillary curve	None	B	The point in the depth of the notch between the zygomaxillary suture and the alveolar process.	3	None	1
Mid nasal	mn	M	Midline point on the internasal suture midway between Nasion and Rhinion.	3	None	1
Nasomaxillare	nm	B	Most inferior point of the nasomaxillary suture on the nasal aperture.	3	None	1
Nasomaxillofrontale	nmf	B	Point at the intersection of the frontal, maxillary, and nasal bones.	1	None	1
Orbitale (sup)	O sup	B	The most superior midpoint of the orbital margin.	3	None	1
Orbitolateral corner	O lat	B	Point on the inner orbital rim where the lower margin of the orbit meets the lateral margin of the orbit.	3	None	1
Posterior nasal spine	PNS	M	The most posterior point at the sagittal plane on the bony hard palate.	2	None	1
Submaxillare curvature	csm	B	Most supero-medial point on the maxillary inflexion between the zygomaxillare and the ectomolar.	2	None	1
Supra canine	sc	B	Point on the superior alveolar ridge superior to the crown of the maxillary canine.	3	None	1
Supra M1	sm1	B	The point located on the alveolar process at the level of the middle of the first upper molar.	3	None	1
Supra M2	sm2	B	The point located on the most lateral portion of the alveolar process at the level of the middle of the second upper molar or if missing or not fully erupted then where the second molar would be.	1	None	3
Supraorbital notch	None	B	Point of greatest concavity on the supraorbital notch.	1	None	3
Suture line ZT inferior line	None	B	Most inferior point of the zygomaticotemporal suture.	2	None	1
Suture line ZT superior	None	B	Most superior point of the zygomaticotemporal suture.	2	None	1
Zygion	zyg	B	Most lateral point on zygomatic arch.	2	None	1
Zygomatic arch	Zyg arch	B	Midpoint between M1 and O1.	3	None	1

Neurobasicranial region

The most common bilateral landmarks used in the assessment of asymmetry were Asterion (type 1) and Porion (type 3)—reported in 5 studies, followed by Auriculare (type 3), Caroticum mediale/Carotid canal (type 3), Sphenion (type 1), Suture line ZT (type 3), and Stephanion (type 2)—reported in 3 studies. The most common medial landmarks were Bregma (type 1) and Lambda (type 1)—reported in 8 studies, followed by Glabella (type 3)—reported in 7 studies, Basion (type 2)—reported in 6 studies, and finally, Opisthocranium (type 2) and Opisthion (type 2)—reported in 4 studies. The neurobasicranial regional landmarks of Bookstein type 1 used in more than two studies included Asterion and Sphenion as bilateral and Bregma and Lambda as medial landmarks.

Ethmomaxillary region

The most common bilateral landmarks used in the assessment of asymmetry were Jugale (type 2)—reported in 12 studies, Alare (type 3) and Zygomaxillare (type 2)—reported in 10, Ectoconchion (type 3)—reported in 8, Frontomalare orbitale (type 2), Frontomalare temporale (type 2) and Frontotemporale (type 1)—reported in 7, Ectomolare (type 3) and Zygotemporale superior (type 2)—reported in 6, Mastoidale (type 2), Maxillofrontale (type 1), Orbitale (type 3) and Zygotemporale inferior (type 2)—reported in 5, Infraorbitale (type 2) in 4, Apertion (type 3), Articular eminence (type 2), Endoconchion

(type 3), Frontale (type 1), Dacryon (type 1), Infra M1 (type 1), Mid-Infraorbital (type 3), Mid-Supraorbital (type 3), Nariale (type 3), Nasale inferius (type 2), Zygoorbitale (type 1), Zygomatico-frontale (type 1)—reported in 3 studies.

The most common medial landmarks were Nasion (type 1)—reported in 17 studies, Rhinion (type 2)—reported in 10, Prosthion (type 3)—reported in 8, Anterior nasal spine (type 2)—reported in 7, Nasospinale (type 3)—reported in 5, A point/subspinale (type 3)—reported in 4, and Labrale Superius (type 3)—reported in 3 studies. Finally, Bookstein type 1 landmarks belonging to the ethmomaxillary region of the midface neurobasicranial that were used in more than 2 studies included Frontotemporale, Maxillofrontale, Frontale, Dacryon, Infra M1, Zygoorbitale and Zygomatico-frontale (bilateral) and Nasion as a medial landmark.

Region mandible

The most common bilateral landmarks used in the assessment of asymmetry were Gonion lateralis (type 2)—reported in 5 studies, Condyle (type 2)—reported in 4, and Coronion (type 2), Mental foramen (type 2)—reported in 3 studies. The most common medial landmarks were Mentum (type 3) and Pogonion (type 3)—reported in 3 studies. The type 1 landmarks used to assess mandibular asymmetry included bilateral Hypoglossal foramen—reported in two studies, and bilateral Root of sigmoid notch—reported in one study.

Table 9. Landmarks in region mandible Abb. – abbreviation, M/B – midline or bilateral, Definition – definition of landmarks, Class – Bookstein's types or homology classification, VOC – a variation of homology classification, FOC – frequency of occurrence landmarks in included studies).

Landmarks	Abb	M/B	Definition	Class	VOC	FOC
Gonion/gonion lateralis	Gon/ Golot	B	Point located on the jawline at the level of the angle between the posterior and the inferior borders of the mandible. The most lateral external point of junction of the horizontal and ascending rami of the lower jaw.	3	None	5
Condyle/Condylion	Co/CO/Cd	B	Uppermost point of condyle. The most posterior superior point on the condyle of the mandible.	2	None	4
Coronion/coronoid process	CP	B	Most superior point on coronoid process. The most superior point of the outlines of the coronoid process.	2	None	3
Mental foramen	MF	B	Most anterior point of mental foramen.	2	None	3
Menton	Me	M	Most inferior point of the mandibular symphysis. Most inferior points on the symphysis in the median plane.	3	None	3
Pogonion	Po, Pog or P	M	The most anterior midline point on the mental eminence of the mandible. Most anterior projection of bone on mental symphysis.	3	None	3
Gnathion	GN or Gn	M	Most inferior midline point on symphysis. The most anterior inferior points of the chin.	3	None	2
Hypoglossal foramen	None	B	The most superior, anterior point on the edge of the hypoglossal canal.	1	None	2
Infradentale	Id	M	Midline point at the superior tip of the septum between mandibular central incisors. The most anterior-superior points on the labial crest on the mandibular alveolar process.	3	None	2
Mandibular notch	None	B	Most concave point of mandibular notch.	3	None	2
Mental protuberance/Menton	Pm	B	Most lateral end of mental protuberance. Point above pogonion at top of crest of the symphysis or at a point of recess of the anterior symphyseal curvature – also may be called suprapogonion.	2	None	2
Oblique line of the mandible	None	B	Point on oblique line (external oblique ridge) at the vestibular tissue of the second molar.	3	None	2
Postalverion/posterior alveolar	None	B	Most posterior point situated in the labial surface behind the most posterior erupted tooth or crypt of tooth.	3	None	2
Ramus anterior	None	B	Junction of anterior border of ramus and alveolus.	3	None	2
Antegonion	Ag	B	Deepest point of the concavity between the mandibular corpus and the ramus junction.	3	None	1
Condylion medialis	Co med	B	Point where mandibular notch intersects condyle.	3	None	1
Condylion lateralis	Co lat	B	Most lateral point on mandibular condyle.	3	None	1
First molar/lower molar mesial contact	LMC	B	Mesial to M1, alveolar border. The mesial contact of the mandibular first molar.	3	None	1
Genion	Ge	M	Most superior aspect of mental spine. The most inward and everted point on the profile curvature of the symphysis of the mandible.	3	None	1
Gonion inferius	Goinf	B	Most inferior point between the mandibular corpus and the ramus junction.	3	None	1
Gonion posterius	Gopost	B	Most posterior point between the mandibular corpus and the ramus junction.	3	None	1
Incisurale	None	B	Most inferior point on mandibular notch.	3	None	1
Interdentale inferius	None	M	Junction between the lower two incisors.	3	None	1
Lingulare	None	B	Highest positioned point of the lingula of the mandible on the inner side of the mandibular ramus.	3	None	1
Mandibular border 1	None	B	Point at lower border of the body of the mandible, on the line passing through coronoid tip parallel the line linking the gonion and the mandibular notch.	3	None	1
Mandibular border 2	None	B	Point at lower border of the body of the mandible, at half distance between the menton and mandibular border.	3	None	1
Mandibular foramen	MF	B	Most concave point of the medial border of the mandibular foramen. The most superior point of the outline of the mandibular foramen.	3	None	1
Mental eminence canine	None	B	Most concave portion of the canine eminence.	3	None	1
Mental spines	None	M	Superior end between upper mental spines.	2	None	1
Mental tubercle	None	B	Most superior aspect of the triangular eminence.	2	None	1
Mentale	None	B	Anteromedial edge of mental foramen.	2	None	1
Mentolabial sulcus	mls	M	The deepest midline point in the groove superior to the mental eminence.	3	None	1
Point B (supramentale)	B	M	Most concave point on the alveolar process below the apex of the roots of the 2 central incisors. On a line perpendicular to FH, point B is the most posterior point in the concavity between the chin and mandibular alveolar process.	2	None	1
Posterior anterior ramus	par	B	The most posterior point along the curved anterior margin of the ascending ramus.	3	None	1
Postgonion	None	B	Most posterior external point on the mandibular branch above the point gonion.	3	None	1
Pregonion	None	B	Most external point at the border of mandibular angle and mandibular body before the point gonion.	3	None	1
Ramus posterior	None	B	Point at posterior border of the mandibular ramus, on the line passing through mental spines and mandibular foramen.	3	None	1
Root of sigmoid process	None	B	Point where mandibular notch intersects condyle.	1	None	1
Supramentale	None	M	Deepest point at the mandibular symphysis curvature between the infradentale and pogonion landmarks.	3	None	1
M3	None	B	Mesial to the third molar, alveolar border.	3	None	1

Limitations

One of the limitations of this systematic review is that it includes a relatively small number of studies that deal with the three-dimensional assessment of whole-face asymmetry. The preponderance of identified studies investigates the asymmetry of only one part of the face. The smaller the anatomical region

of the facial skeleton on which the asymmetry is determined implies the more extensive and more diverse the list of used landmarks in terms of homology. That means that landmarks of a lower degree of homology in such studies are considered in asymmetry assessment. Wärmlander⁴¹ stresses that landmarks should be chosen to comprehensively represent the morphology

of the region or features of interest and that landmark placement must be reliable and repeatable. This leads to the next limitation of this review: The reported positions of the same landmarks used in different studies often vary, wherein most studies do not provide a rationale for choosing the specific landmark positions. Also, we notice that individual landmarks do not have a clear definition of their position in some studies.^{33,37,43} These discrepancies limit comparisons between individual landmarks with the same name among different studies.

Finally, the limitation of this review is that it does not include other sources than nine databases, selection criteria and studies published in English. Trial registries, grey literature sources, hand searching, backward search including references of included studies, forward search in citation databases, and search for conference abstracts were not included and can be recognized as a potential publication bias.

CONCLUSION

The selection and definition of craniofacial hard tissue landmarks is one of the most important tasks in designing morphometric studies assessing facial asymmetry. This review provides an extensive cross-section of possible landmarks with respective definitions of their locations and the possible location variations. Our analysis showed that a relatively small number of landmarks were represented in a larger number of studies. In the region of neurobasicranium bilateral landmarks Asterion and Porion and unilateral Bregma, Lambda, Glabella and

Basion are reported as most often used. In the region of ethmomaxillary complex bilateral Jugale, Alare, Zygomaxillare, Ectoconchion, Frontomolare orbitale, Frontomolare temporale and Frontotemporale are the most frequently used in researches. Unilateral landmark Nasion is the most represented landmark. Other most common medial landmarks of the middle face are Rhinion, Prosthion and Anterior nasal spine. The most common landmarks in the mandible are Gonion lateralis and Condyle as medial, and Menton and Pogonion as bilateral landmarks.

The proper selection of landmarks in facial analyses of symmetry is of utmost importance and landmarks should be comparable among many studies. Also, landmarks should be observed according to their homology, as well as possible variations of the classification. As a result of this study, authors can recommend that using the distinct number of high-value and comparable landmarks is of great relevance for asymmetry analysis of facial structures.

ACKNOWLEDGEMENT

All landmarks, abbreviations and definitions used in tables 7-9 are from references 18-41.

The Information sources and search of this protocol/review is based on a standard template used by Cochrane (Cochrane Handbook for Systematic Reviews of Interventions 5.1.0.).

CONFLICT OF INTEREST

The authors of the present article declare no conflicts of interest.

REFERENCES

1. Olivieri P, Uribe FA, Quereshy FA. Aesthetic Facial Surgery and Orthodontics: Common Goals. *Oral Maxillofac Surg Clin North Am.* 2020;32(1):153-65.
2. Thiesen G, Gribel BF, Freitas MP. Facial asymmetry: a current review. *Dental Press J Orthod.* 2015;20(6):110-25.
3. Corruccini RS, Potter RH. Genetic analysis of occlusal variation in twins. *Am J Orthod.* 1980;78:140-54.
4. Sahu A, Lall R, Nezam S, Singh R, Kumar SB, Ayub FB. Comparative Assessment of Facial Asymmetry in Malocclusion using Posteroanterior View. *J Contemp Dent Pract.* 2018;19(6):712-18.
5. Castelo PM, Pereira LJ, Andrade AS, Marquezin MC, Gavião MB. Evaluation of facial asymmetry and masticatory muscle thickness in children with normal occlusion and functional posterior crossbite. *Minerva Stomatol.* 2010;59(7-8):423-30.
6. Parsons PA. Fluctuating asymmetry: A biological monitor of environmental and genomic stress. *Heredity (Edinb).* 1992;68:361-4.
7. Gangestad SW, Thornhill R. Individual differences in developmental precision and fluctuating asymmetry: a model and its implication. *J Evol Biol.* 1999;12:402-16.
8. Polak M. Developmental instability, causes and consequences. 1st ed. Oxford: Oxford University Press; 2003.
9. Smith GR. Homology in morphometrics and phylogenetics. In: Rohlf FJ and Bookstein FL. *Proceedings of the Michigan Morphometrics Workshop.* Ann Arbor, MI: The University of Michigan Museum of Zoology; 1990.
10. Roth VL. On three-dimensional morphometrics, and on the identification of landmark points. In: Marcus L, Bello E, Valdecasas AG. *Advances in morphometrics.* Madrid, Spain: Museo Nacional de Ciencias Naturales; 1993.
11. Lele SR, Richtsmeier JT. *An invariant approach to statistical analysis of shapes.* 1st edition. Boca Raton: Chapman & Hall/CRC; 2001.
12. Zelditch M, Swiderski D, Sheets H. *Geometric morphometrics for biologists: A primer.* 2nd ed. New York: Elsevier Academic Press; 2012.
13. Shearer BM, Cooke SB, Halenar LB, Reber SL, Plummer JE, Delson E. et al. Evaluating causes of error in landmark-based data collection using scanners. *PLoS One.* 2017;12(11):e0187452.
14. Bookstein FL. *Morphometric tools for landmark data.* 1st ed. Cambridge: Cambridge University Press; 1991.
15. Bookstein FL. Landmark methods for forms without landmarks: morphometrics of group differences in outline shape. *Med Image Anal.* 1997;1(3):225-43.
16. Moher D, Liberati A, Tetzlaff J, Altman DG; PRISMA Group. Preferred reporting items for systematic reviews and meta-analyses: the PRISMA statement. *PLoS Med.* 2009;6(7):e1000097.
17. Higgins JPT, Green S, editors. *Cochrane handbook for systematic review of interventions (version 5.1.0, updated March 2011).* The Cochrane Collaboration; 2011. Available at: www-cochrane-handbook.org.
18. Starbuck JM, Ghoneima A, Kula K. Bilateral cleft lip and palate: A morphometric analysis of facial skeletal form using cone beam computed tomography. *Clin Anat.* 2015;28(5):584-92.
19. Bigoni L, Krajiček V, Sládek V, Velemínský P, Velemínská J. Skull shape asymmetry and the socioeconomic structure of an early medieval central European society. *Am J Phys Anthropol.* 2013;150(3):349-64.
20. Hartman C, Holton N, Miller S, Yokley T, Marshall S, Southard T. Nasal Septal Deviation and Facial Skeletal Asymmetries. *Anat Rec (Hoboken).* 2016;299(3):295-306.
21. Rusková H, Bejdová S, Peterka M, Krajiček V, Velemínská J. 3-D shape analysis of palatal surface in patients with unilateral complete cleft lip and palate. *J Craniomaxillofac Surg.* 2014;42(5):e140-7.
22. Schlager S, Rüdell A. Analysis of the human osseous nasal shape-population differences and sexual dimorphism. *Am J Phys Anthropol.* 2015;157(4):571-81.
23. Chovalopoulou ME, Papageorgopoulou C, Bertasos A. Cranium asymmetry in a modern Greek population sample of known age and sex. *Int J Legal Med.* 2017;131(3):803-812.
24. Ibrová A, Dupej J, Stránská P, Velemínský P, Poláček L, Velemínská J. Facial skeleton asymmetry and its relationship to mastication in the Early Medieval period (Great Moravian Empire, Mikulčice, 9th-10th century). *Arch Oral Biol.* 2017;84:64-73.
25. Fuessinger MA, Schwarz S, Cornelius CP, Metzger MC, Ellis E 3rd, Probst F et al. Planning of skull reconstruction based on a statistical shape model combined with geometric morphometrics. *Int J Comput Assist Radiol Surg.* 2018;13(4):519-529.
26. Ceuninck K, Starbuck JM. A morphometric analysis of developmental instability in children born with unilateral cleft lip and palate. *Clin Anat.* 2019;32(2):206-211.
27. Ridel AF, Demeter F, Galland M, L'abbé EN, Vandermeulen D, Oertlé AC. Automatic landmarking as a convenient prerequisite for geometric morphometrics. Validation on cone beam computed tomography (CBCT)- based shape analysis of the nasal complex. *Forensic Sci Int.* 2020;306:95-105.
28. Jung H, von Cramon-Taubadel N. Comparison of cranial fluctuating asymmetry between normal and pathological specimens from a modern Thai skeletal group. *Homo.* 2018;69(4):188-97.
29. Espinosa S, Rabanal C, Toro-Ibacache V. Morphometric Characterization of Asymmetric Mandibles Due to Condylar Hyperactivity. *J Oral Maxillofac Surg.* 2019;77(5):1056-1067.
30. Weisensee KE, Spradley MK. Craniofacial asymmetry as a marker of socioeconomic status among undocumented Mexican immigrants in the United States. *Econ Hum Biol.* 2018;29:122-127.
31. Benazzi S, Senck S. Comparing 3-dimensional virtual methods for reconstruction in craniomaxillofacial surgery. *J Oral Maxillofac Surg.* 2011;69(4):1184-94.
32. Weisensee EK. Assessing the Relationship Between Fluctuating Asymmetry and Cause of Death in Skeletal Remains: A Test of the Developmental Origins of Health and Disease Hypothesis. *Am J Hum Biol.* 2013;25:411-17.
33. Katsube M, Rolfe SM, Bortolussi SR, Yamaguchi Y, Richman JM, Yamada S et al. Analysis of facial skeletal asymmetry during foetal development using μ CT imaging. *Orthod Craniofac Res.* 2019;22 Suppl 1(Suppl 1):199-206.
34. Nur RB, Çakan DG, Arun T. Evaluation of facial hard and soft tissue asymmetry using cone-beam computed tomography. *Am J Orthod Dentofac Orthop.* 2016;149(2):225-37.
35. Nikkhah D, Ponniah A, Ruff C, Dunaway D. Planning surgical reconstruction in Treacher-Collins syndrome using virtual simulation. *Plast Reconstr Surg.* 2013;132(5):790e-805e.
36. Ridel AF, Demeter F, Liebenberg J, L'Abbe' EN, Vandermeulen D, Oertlé AC. Skeletal dimensions as predictors for the shape of the nose in a South African sample: A cone-beam computed tomography (CBCT) study. *Forensic Sci Int.* 2018;289:18-26.
37. Senck S, Coquerelle M, Weber GW, Benazzi S. Virtual reconstruction of very large skull defects featuring partly and completely missing midsagittal planes. *Anat Rec (Hoboken).* 2013;296(5):745-58.
38. Ketoff S, Girinon F, Schlager S, Friess M, Schouman T, Rouch P et al. Zygomatic bone shape in intentional cranial deformations: a model for the study of the interactions between skull growth and facial morphology. *J Anat.* 2017;230(4):524-531.
39. Ahmad Y, Starbuck JM. Disruption of symmetry: A quantitative assessment of facial skeleton anatomy in children born with unilateral cleft lip and palate. *Clin Anat.* 2018;31(8):1129-1136.
40. Fukase H, Ito T, Ishida H. Geographic variation in nasal cavity form among three human groups from the Japanese Archipelago: Ecogeographic and functional implications. *Am J Hum Biol.* 2016;28(3):343-51.
41. Wärmlländer SKTS, Garvin H, Guyomarc'h P, Petaros A, Sholts SB. Landmark Typology in Applied Morphometrics Studies: What's the Point? *Anat Rec (Hoboken).* 2019;302(7):1144-1153.
42. O'Higgins P. Quantitative approaches to the study of craniofacial growth and evolution: Advances in morphometric techniques. In: O'Higgins P, Cohn M. *Development, growth, and evolution: Implications for the study of the hominid skeleton.* London, UK: Academic Press; 2000.
43. Rusková H, Bejdová S, Peterka M, Krajiček V, Velemínská J. 3-D shape analysis of palatal surface in patients with unilateral complete cleft lip and palate. *J Craniomaxillofac Surg.* 2014;42(5):e140-7.