

Department of Obstetrics and Gynecology, Elias Emergency University Hospital;  
\* Department of Obstetrics and Gynecology, Filantropia Maternity Hospital, Bucharest, Romania

## **CONGENITAL CYSTIC ADENOMATOID MALFORMATION KONGENITALNA CISTIČNA ADENOMATOIDNA MALFORMACIJA**

*Radu Vlădăreanu, Dimitrie Pelinescu-Onciul,\* Mona Zvâncă, Doina Mihăilescu*

*Review*

*Key words:* congenital cystic adenomatoid malformation, prenatal diagnosis, ultrasound, fetal therapy

**SUMMARY.** Cystic adenomatoid lung malformation (CCAM) is a rare disease, with a prevalence 1/25 000 to 1/35 000 pregnancies, a developmental abnormality arising from an overgrowth of the terminal respiratory bronchioles. Prenatal diagnosis is based on the ultrasonographic demonstration of a hyperechogenic pulmonary tumor, which is microcystic or macrocystic. The disease may be associated with a mediastinal shift, hydrops fetalis or polyhydramnios. The outcome is bad in bilateral cases, in those with pulmonary hypoplasia and with fetal hydrops. In unilateral and isolated cases the prognosis may be good. Spontaneous resolution occurs prenatally only in the third trimester of pregnancy. Three cases of CCAM are presented. The case of type I was diagnosed at 28 weeks and regression occurred in the third trimester, at 36 weeks of gestation. The prenatal and postnatal pictures of a case of the lung type II and of a case of CCAM type III with echogenic appearance of a uniformly solid mass, are presented too.

*Pregled*

*Ključne riječi:* prirođena cistična adenomatoidna malformacija pluća, prenatalna dijagnostika, ultrazvuk, fetalna terapija

**SAŽETAK.** Cistična adenomatoidna malformacija pluća (CACM) je rijetka bolest s pojavnošću od 1/25 000 do 1/35 000 trudnoća, razvojna pogreška koja nastaje preraštanjem terminalnih respiratornih mjehurića. Prenatalna dijagnoza se zasniva na ultrazvučnom prikazu hiperehogenog tumora pluća, koji može biti mikrocističan i makrocističan. Pri bolesti može nastati pomak medijastinuma, fetalni hidrops ili polihidramnios. Ishod je loš u bilateralnim slučajevima, u onima s hipoplazijom pluća i fetalnim hidropsom. U jednostranim i izoliranim slučajevima prognoza može biti dobra. Spontani nestanak se zbiva u trećem tromjesečju trudnoće. Prikazana su tri ploda s CCAM. Tip 1 bolesti je bio dijagnosticiran u fetusa s 28 tjedana i regresija je nastupila s 36 tjedana. Prikazane su prenatalne i postnatalne slike slučaja s ultrazvučnim nalazom jednako mjerno solidne mase s tipom II i s tipom III bolesti.

### **Introduction**

Congenital cystic adenomatoid malformation (CCAM) of the lung is a developmental abnormality arising from an overgrowth of the terminal respiratory bronchioles. Prenatal diagnosis is based on the ultrasonographic demonstration of a hyperechogenic pulmonary tumor, which is microcystic or macrocystic. Both microcystic and macrocystic disease may be associated with mediastinal shift, hydrops fetalis or polyhydramnios. Prognostic features for poor outcome include bilateral disease, or unilateral with major lung compression causing pulmonary hypoplasia, and development of hydrops fetalis irrespective of the type of the lesion. Isolated unilateral cystic adenomatoid malformation without hydrops is associated with a good prognosis. Prenatal treatment is almost exclusively surgical. Procedures are lobar resection or thoraco-amniotic shunt. Symptom-free cysts undergo conservative treatment and serial ultrasonographic follow-up. Spontaneous resolution occurs prenatally only in the 3-rd trimester of pregnancy. Postnatal management is more comfortable: segmental or lobar resection.

The congenital cystic adenomatoid abnormality is a hamartomatous lesion arising from abnormal embryo-

genesis during the first trimester of pregnancy. Excessive growth of adenomatoid tissue in terminal bronchioles area consequently suppresses bronchiolar and alveolar development<sup>1</sup>; the result is a lack of normal alveolar structure of the pulmonary air space. The distal displastic lung tissue is secondary to bronchiolar atresia, regarded as the primary abnormality.<sup>2</sup>

In 98% of cases the lesions are unilateral and confined in 95% of cases to a single lobe (*Figures 1, 2, 3*). The middle lobe is the most protected. Extrapulmonary lesions are quite rare; a single intraabdominal, suprarenal case was mentioned in the literature.<sup>2</sup>

The prevalence of the disease is still uncertain: it is considered to be somewhere between 1/25 000 and 1/35 000 pregnancies, but most of the symptom-free, microcystic cases were probably subdiagnosed until recently.<sup>3</sup>

CCAM is the most frequent lung abnormality. At least 25% of cases, considerably more if we consider also the subclinical cases diagnosed using recent techniques.<sup>3</sup> The risk for recurrence in subsequent pregnancies is practically absent (sporadic disease). The dependence on race, maternal age or genetic/family history is still undocumented, as well as the vague predilec-

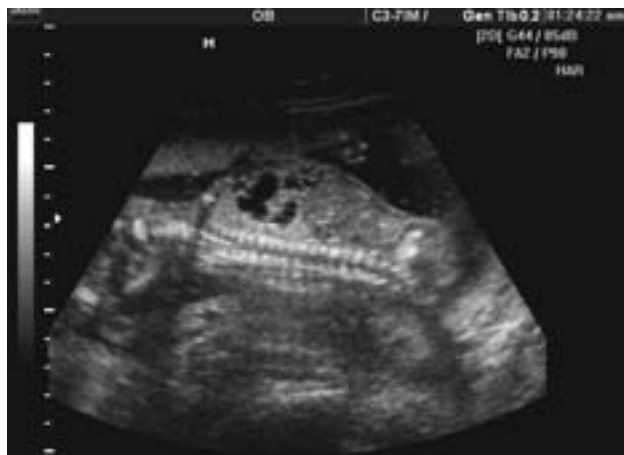

Figure 1. CCAM, a case diagnosed at 24 weeks, showing numerous cystic lesions in the lower right pulmonary lobe. Axial view

Slika 1. Slučaj dijagnosticiran s 24 tjedana, prikazane su brojne cistične tvorbe u desnom donjem plućnom režnju. Aksijalni ultrazvučni presjek

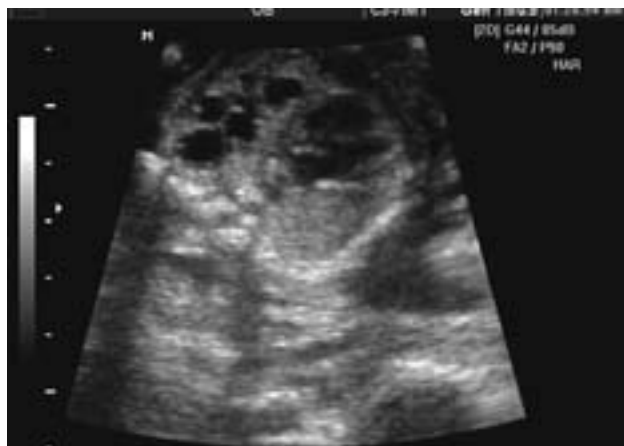


Figure 2. CCAM, a case diagnosed at 24 weeks, showing numerous cystic lesions in the lower right pulmonary lobe. Transverse 4 chamber view. A minor degree of mediastinal shift is associated

Slika 2. Slučaj dijagnosticiran s 24 tjedna, prikazane su brojne cistične tvorbe u desnom donjem plućnom režnju. Poprečni ultrazvučni presjek kroz 4 srčane komore. Pomak medijastinuma manjeg stupnja

tion for male sex. In about 10% of cases, CCAM is associated with other abnormalities and fetal malformations: trisomy 18, renal agenesis, congenital diaphragmatic hernia, heart defect.<sup>3</sup>

## Diagnosis

In 1979, Stocker classified CCAM according to cystic size and distribution, also trying to establish a prognostic relationship. This is now infirmed (see prognostic groups and criteria in CCAM):

- CCAM type I (50% of cases): single/multiple cysts, with large diameters (2–10 cms), air-filled or fluid-filled and with variable wall thickness; excellent prognosis (Fig. 4, 5).
- CCAM type II (40% of cases): multiple, medium-diameter (0.5–2 cm), thin walled cysts (Fig. 1, 2);

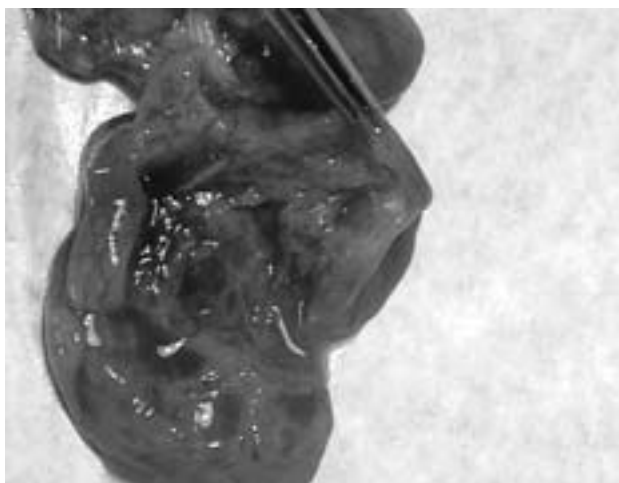
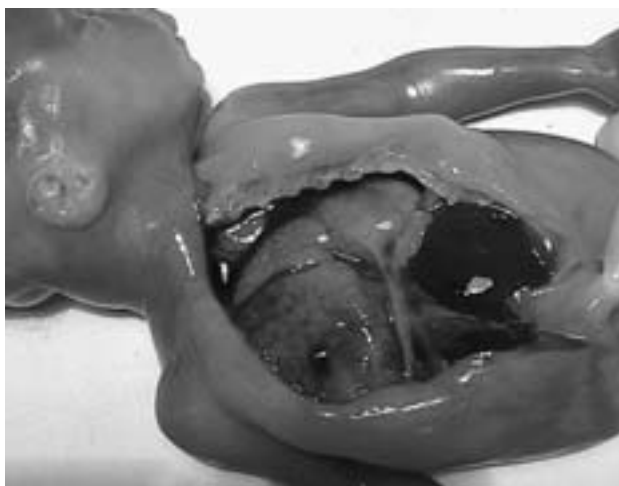

Figure 3. Postabortum aspect of CCAM of the lower right pulmonary lobe in a 24 weeks fetus. Up: The right pulmonary lobe is occupying a large part of thorax. Down: Macroscopic aspect of the dissected lung

Slika 3. Desni donji plućni režanj u fetusa od 24 tjedna nakon pobačaja. Gore: desni plućni režanj zauzima veliki dio prsišta. Dolje: makroskopski izgled diseciranih pluća

poor prognosis only if associated with other congenital abnormalities. Otherwise the mediastinal shift is small and the respiratory distress is mild.<sup>4</sup>

- CCAM type III (10% of cases): multiple microcysts (smaller than 0.5 cm), with echographic appearance of a uniformly solid mass, mostly located in the left lower lobe; bad prognosis due to constant association with pulmonary hypoplasia and hydrops fetalis.<sup>5–7</sup>

Recent trends are towards a simplified ultrasonographic classification as microcystic (40%) and macrocystic disease (60%). Both forms can be associated with mediastinal shift, compression and hydrops fetalis, but even with the most up-to-date imaging techniques, very small microcystic lesions are still difficult to detect.

A specific CCAM feature is reduced local vascularization associated with increased cell proliferation. Cystic vascularization derives from pulmonary circulation and communicates with the bronchial tree (differen-

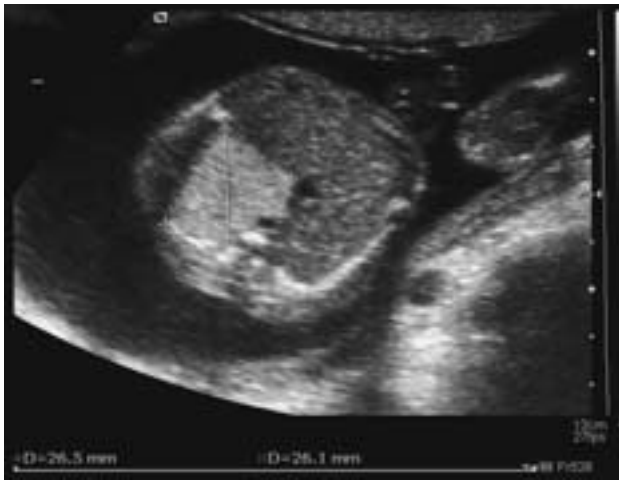

Figure 4. CCAM, a case diagnosed at 28 weeks showing a cyst of 26 mm. Transverse view

Slika 4. Ultrazvučna slika CCAM u fetusa od 28 tjedana. Vidi se cista od 26 mm. Poprečni presjek

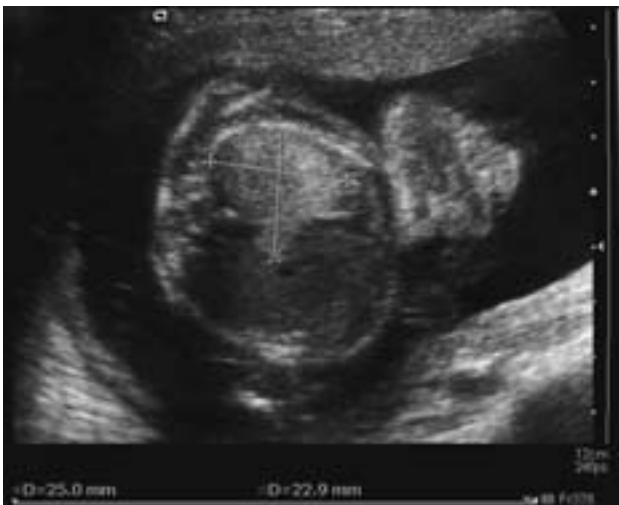

Figure 5. CCAM, transverse view of the lower part of thorax at 28 weeks fetus

Slika 5. CCAM, poprečni ultrazvučni presjek donjeg dijela prsišta u fetusa od 28 tjedana

tial diagnosis with pulmonary sequestration). Cystic walls contain mucous metaplastic cells, stem mesenchymal cells and differentiated rough muscle fibers, poorly organized, as well as ectopic neural tissue, as shown by the presence of neuron-specific enolase and glial fibrillar acid protein (typical for astrocytes). The glandular part is also important: nodular aggregates of mucoid cells, almost identical to mucous cells in bronchiolo-alveolar carcinoma and hyperplastic polyps of the colon. These are enough observations to support the hypothesis of dysregulated paracrine growth of mature cells and extracellular matrix as a cause for CCAM. The glandular part of the lesions has a potential for malignant evolution.<sup>5</sup>

Prenatal diagnosis is incidental in most of the cases by routine ultrasound.<sup>8</sup> Sonographically, CCAM appears as

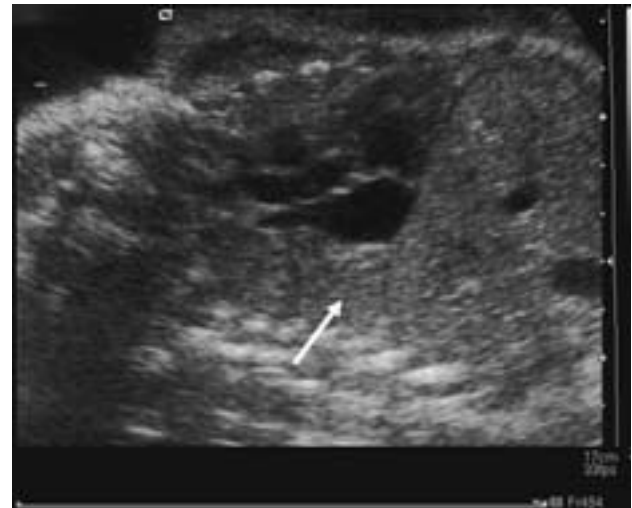

Figure 6. Regression of the lesion in the lower left pulmonary lobe at 36 weeks of gestation

Slika 6. Regresija lezije donjeg lijevog plućnog režnja s 36 tjedana trudnoće

solid or mixed cystic and solid (microcystic) noncompressible chest masses in the fetus. CCAM can be very large and contains large cysts (Fig. 4), and just like any chest mass, they have potential to compress the developing lungs and cause pulmonary hypoplasia and hydrops. Sonographic diagnosis of a CCAM is often made at 16 to 22 weeks, and early diagnosis is favored by large size and presence of macrocysts.<sup>9</sup> A positive diagnosis makes the premises for weekly serial ultrasounds, once a week, then once every 2 to 4 weeks, as an assessment tool for the cystic evolution.

MRI remains the method of election for differential diagnosis with other congenital lung anomalies (congenital lobar emphysema, pulmonary sequestration, bronchogenic cyst). MRI allows early diagnosis of lethal complications – severe mediastinal shift, with compression of lung tissue. The same techniques remain useful for the postnatal diagnosis, too. On ultrasound, lung masses are glandular or bronchiolar structures, sometimes associated with endogenous lipid areas. Hypodensities are microcysts associated with normal lung tissue. The computed tomography demonstrates non-infected lesions as air-filled, thin-walled masses; infected lesions show a more complex appearance, due to the presence of fluid and inflammatory tissue.<sup>10</sup>

The differential diagnosis excludes all lung and mediastinal tumors and cavities: congenital diaphragmatic hernia (CDH), pulmonary sequestration, staphylococcal pneumatoceles, cavitary pneumonia, congenital lobar emphysema, airway atresia, bronchogenic cyst, pericardial cyst, mediastinal teratoma, etc.

The various clinical features are produced by lung compression and mediastinal shift. Compression on heart and inferior vena cava decreases venous return and cardiac output and leads to fetal hydrops, sometimes mirrored by maternal preeclampsia. Esophageal compression is responsible for polyhydramnios. Intrauterine

growth restriction could induce fetal demise or premature birth (large cysts, no surgical resection). Some cases undergo spontaneous *in utero* resolution (differential diagnosis with CDH). Other are symptom-free postnatal (in stable, non-growing cystic lesions).<sup>11,12</sup> Partial regression of the lung cystic mass is encountered in about 50–70% of cases (recent studies based on serial ultrasounds) (Fig. 6).<sup>3,13</sup>

Although the classic opinion on early postnatal period emphasized the high percentage of cases with respiratory distress, induced by hydrops, premature delivery, pulmonary hypoplasia, spontaneous pneumothorax, recent studies demonstrate excellent neonatal prognosis for stable lesions, with surgical or even conservative treatment.<sup>14–16</sup> Later on, recurrent lung infections are common and important prognostic indicator.

Some cases evolve through malignancy: 25% of pleuro-pulmonary blastoma is found in children with CCAM.

Recent information focus on the following prognostic factors: cystic size (irrespective of echostructure), bilaterality, degree of mediastinal shift, presence or absence of polyhydramnios and hydrops, association with other malformations. Based on these factors, fetal CCAM is classified in several prognostic groups: good, undetermined and poor. For example, a fetus with a small, stable CCAM with little mediastinal shift has an excellent prognosis. This optimism is attributable to three important observations in fetuses with CCAM. First, it is extremely rare for a small unilateral CCAM, with only mild cardiomeastinal shift, to cause hydrops. Second, it is very rare for a lesion that is small when first identified to progress sufficiently in gestation to cause hydrops or significant pulmonary hypoplasia. Third, in the absence of concomitant abnormalities, empiric survival rates of fetuses with small masses approach 100%.<sup>9</sup> Calvert et al.<sup>15</sup> reported that, in a period of 10 years, among 28 cases of CCAM, five pregnancies were terminated, 23 pregnancies continued and resulted in 2 neonatal deaths and 21 surviving babies. Lerullo et al.<sup>16</sup> reported an overall survival rate of 88%. As more fetuses with CCAM are studied, it has become clear that the majority of masses detected remain stable or regress in size (close to 100% if no associated malformations). Unfortunately, regression may not occur until the third trimester, and those lesions that will regress are not yet predictable on the basis of midgestation sonogram.<sup>17,18</sup> So, it is recommended that all fetuses be monitored carefully.

The presence of hydrops (100% mortality) and severity of mediastinal shift are correlated with the size of the lesion.<sup>19</sup> Very large lesions cause more mediastinal shift and are more likely to cause hydrops. Four CCAM cases with *in-utero* resolution of hydrops fetalis after prenatal betamethasone therapy with good clinical outcome have been reported in literature. The mechanism is speculated to be the effect of corticosteroid in improving lung maturation.<sup>20,21</sup>

The initial rapport between dimensions of CCAM and thorax does not impact upon the vital and functional

prognosis.<sup>6,7</sup> Early antenatal diagnosis, made possible by modern imaging techniques, allows early interventions on children population asymptomatic at birth.<sup>22</sup>

## Fetal therapy

Prenatal treatment is almost exclusively surgical and may be delayed until partial delivery, when the fetus still has placental circulatory support (EXIT = *ex utero* *intra-partum* treatment).<sup>23</sup>

Candidates for fetal surgery are less than 32 weeks gestational age, hydrops fetalis,<sup>18</sup> placentomegaly and/or an onset of maternal preeclampsia. Fetuses older than 32 weeks allow delivery by cesarean section and postnatal surgery. There is no surgical intervention less than 28 weeks, unless fetal heart failure, but not associated with preeclampsia.

Except for lobar resection, a thoraco-amniotic shunt for mediastinal compression relief is also a possibility. This procedure is quite rare, due to a high rate of complications and it was indicated only to those cases complicated by major polyhydramnios or hydrops.<sup>13,24</sup> Symptom-free cysts undergo conservative treatment and serial ultrasonographic follow-up. Maternal digitalisation is sometimes efficient in hydrops correction. Serial amniocentesis can be performed for polyhydramnios. Irrespective of which fetal procedure was applied, we must emphasize that no method is a cure for maternal pre/eclampsia.<sup>12,25–27</sup>

Postnatal management is more comfortable: segmental or lobar resection may be performed through endoscopic techniques or thoracotomy, depending on clinical forms. More recent techniques focus on non-anatomic resection, fragments of lung tissue having a surprisingly high ability of expansion and functional recovery until the age of 9. Most authors prefer surgical cure for asymptomatic cases, due to the risk for malignancy. If no complications arise, optimal age for surgical intervention is somewhere between 3 and 6 months. A rather rare technique, with uncertain results, is vascular embolisation of the cyst.<sup>25,26</sup>

As a rule, symptomatic newborns undergo surgical procedures after a firm computer tomography (CT) diagnosis was obtained<sup>23</sup>, while symptom-free babies, irrespective of radiological aspects, are discharged with a follow-up CT scan at the age of 3 months.<sup>25</sup> Interventions performed after the first month of life demonstrate a better outcome compared to early neonatal surgery.<sup>28</sup>

Postoperative complications in fetal surgery are important: premature delivery or premature rupture of membranes. Postnatal outcome includes pneumothorax, pleural effusions, portal vein thrombosis or pulmonary hemorrhage, requiring a second intervention. It has already been mentioned the risk for malignancies (rhabdomyosarcoma, broncho-alveolar carcinoma)<sup>29,30</sup> and infections (recurrent pneumonia).<sup>4, 11, 27</sup> Spontaneous resolution occurs only prenatal, in the 3-rd trimester of pregnancy.<sup>17</sup> Constant improvement in accuracy for the pre-

natally diagnosis allows both a strict selection of cases for in utero interventions and optimal timing for postnatal surgery; thus, postoperative complications and the period of hospitalization are decreased.

## References

1. Imai Y, Mark EJ. Cystic adenomatoid change is common to various forms of cystic lung diseases of children. *Arch Pathol Lab Med* 2002;126(8):934–40.
2. Cha I, Adzick NS, Harisson MR, Finbeiner WE. Fetal congenital cystic adenomatoid malformation of the lung: a clinicopathologic study of eleven cases. *Am J Surg Pathol* 1997;21(5):537–44.
3. Bromley B, Parad R, Estoff JA. Fetal lung masses: prenatal course and outcome. *J Ultrasound Med* 1995;14:927.
4. Laberge JM, Flageole H, Pugash D, et al. Outcome of the prenatally diagnosed congenital cystic adenomatoid malformation; a canadian experience. *Fetal Diagn Ther* 2001;16(3):178–86.
5. Wang NS, Chen MF, Chen FF. The glandular component in congenital cystic adenomatoid malformation of the lung. *Respirology* 1999;4(2):147–53.
6. Roggin KK, Breuer CK, Carr SR, et al. The unpredictable character of congenital cystic lung lesions. *J Pediatr Surg* 1999;9(6):364–8.
7. Pinter A, Kalman A, Karsza L, Verebely T, Szemledy F. Long-term outcome of congenital cystic adenomatoid malformation. *Pediatr Surg Int* 1999;15(5–6):332–5.
8. Pumberger W, Hormann M, Deutinger J, Bernaschek G, Bistricky E, Horcher E. Longitudinal observation of antenatally detected congenital lung malformations (CLM): natural history, clinical outcome and long-term follow-up. *Eur J Cardiothorac Surg* 2003;24(5):703–11.
9. Callen P et al. *Ultrasonography in Obstetrics and Gynecology*. 4<sup>th</sup> ed. Philadelphia, Pennsylvania, USA: Saunders 2000: 438–442.
10. Mahle WT, Rychik J, Tian ZY, et al. Echocardiographic evaluation of the fetus with congenital cystic adenomatoid malformation. *Ultrasound Obstet Gynecol* 2000;16(7):620–4.
11. Bunduki V, Ruano R, daSilva MM, et al. Prognostic factors associated with congenital cystic adenomatoid malformation of the lung. *Prenat Diagn* 2000;20(6):459–64.
12. Marshall KW, Blane CE, Teitelbaum DH, van Leeuwen K. Congenital cystic adenomatoid malformation; impact of prenatal diagnosis and changing strategies in the treatment of the asymptomatic patient. *Am J Roentgenol* 2000;175(6):1551–4.
13. Dommergues M, Louis-Sylvestre C, Mandelbrot I. CCAM: when is active fetal therapy indicated? *Am J Obstet Gynecol* 1997;177:953–8.
14. Kawamura M, Itoh H, Yamada S, Yura S, Katsuya S, Kosaka K, Tatsumi K. Spontaneous regression of CCAM: longitudinal examinations by MRI. *Congenit Anom (Kyoto)* 2005;45(4):157–60.
15. Calvert JK, Boyd PA, Chamberlain PC, Syed S, Lak-hoo K. Outcome of antenatally suspected CCAM of the lung: 10 years' experience 1991–2001. *Arch Dis Child Fetal Neonatal Ed* 2006;91(1):F26–8.
16. Ierullo AM, Ganapathy R, Crowley S, Craxford L, Bhide A, Thilaganathan B. Neonatal outcome of antenatally diagnosed CCAM. *Ultrasound Obstet Gynecol* 2005;26(2):150–3.
17. Higby K, Melendez BA, Heiman HS. Spontaneous resolution of nonimmune hydrops in a fetus with a cystic adenomatoid malformation. *Pediatr Dev Pathol* 1999;2(5):454–63.
18. Miller JA, Corteville JE, Langer JC. CCAM in the fetus: natural history and predictors of outcome. *J Pediatr Surg* 1996;31(6):805–8.
19. De Santis M, Masini L, Noia G, Cavaliere AF, Oliva N, Caruso A. CCAM: antenatal ultrasound findings and fetal-neonatal outcome. Fifteen years of experience. *Fetal Diagn Ther* 2000;15(4):246–50.
20. Leung WC, Ngai C, Lam TP, Chan KL, Lao TT, Tang MH. Unexpected intrauterine death following resolution of hydrops fetalis after betamethasone treatment in a fetus with a large cystic adenomatoid malformation of the lung. *Ultrasound Obstet Gynecol* 2005;25(6):610–2.
21. Tsao K, Hawgood S, Vu L, et al. Resolution of hydrops fetalis in CCAM after prenatal steroid therapy. *J Pediatr Surg* 2003;38(3):508–10.
22. Gornall AS, Budd JL, Draper ES, Konje JC, Kurinczuk JJ. CCAM: accuracy of prenatal diagnosis, prevalence and outcome in a general population. *Prenat Diagn* 2003;23(12):997–1002.
23. Davenport M, Warne SA, Cacciaguerra S, Patel S, Greenough A, Nicolaides K. Current outcome of antenatally diagnosed cystic lung disease. *J Pediatr Surg* 2004;39(4):549–56.
24. Asabe K, Oka Y, Shirakusa T. Fetal case of CCAM of the lung: fetal therapy and a review of the published reports in Japan. *Congenit Anom (Kyoto)* 2005;45(3):96–101.
25. Waszak P, Claris O, Lapillone A, et al. Cystic adenomatoid malformation of the lung: neonatal management of 21 cases. *Pediatr Surg Int* 1999;15(5–6):326–31.
26. Bagolan P, Nahom A, Giorlandino C et al. Congenital cystic adenomatoid malformation of the lung: clinical evolution and management. *Eur J Pediatr* 1999;158(11):879–82.
27. Keidar S, Ben-Sira L, Weinberg M, Jaffa AJ, Silbiger A, Vinograd I. The postnatal management of congenital cystic adenomatoid malformation. *Isr Med Assoc J* 2001;3(4):258–61.
28. Butterworth SA, Blair GK. Postnatal spontaneous resolution of CCAM. *J Pediatr Surg* 2005;40(5):832–4.
29. Federici S, Domenichelli V, Tani G, et al. Pleuropulmonary blastoma in congenital cystic adenomatoid malformation: report of a case. *Eur J Pediatr Surg* 2001;11(3):196–9.
30. Ozcan C, Celik A, Ural Z, Veral A, Kandiloglu G, Balik E. Primary pulmonary rhabdomyosarcoma arising within cystic adenomatoid malformation: a case report. *J Pediatr Surg* 2001;36(7):1062–5.

*Paper received:* 3. 12. 2006.; *accepted:* 7. 03. 2007.

*Address for correspondence:* Associate Professor Radu Vlădăreanu M.D. PhD, Chief of Obstetrics and Gynecology Department, Carol Davila Medical School, Elias University Emergency Hospital, 17, Marasti Blvd, SE 1, 020322, Bucharest, Romania, E-mail: vladaresanu@gmail.com