

Prenatal Diagnosis Centre, Dept. Pediatrics, Obstetrics and Reproductive Medicine,  
Siena University, Centre for Fetal and Perinatal Medicine,\*  
Dept. Genetics, Perinatal Medicine and Gynecology, Galliera Hospital, Genoa, Italy\*\*

## ULTRASOUND EXAMINATION OF PRIMARY AND SECONDARY PALATE ULTRAZVUČNI PREGLED PRIMARNOG I SEKUNDARNOG NEPCA

*Giovanni Centini,\* Lucia Rosignoli,\* Mario Lituania\*\**

*Review*

*Key words:* cleft lip, cleft palate, 3-D ultrasound, prenatal diagnosis

**SUMMARY.** The new 3-4D technologies offer a particular and precise study of some anatomical parts otherwise difficult or impossible to visualize with the traditional 2-D technique. The study of the secondary palate, hard and soft palate of the uvula, in the last two years gained much attention by the researchers because the 3-D ultrasound allows visualizing the secondary palate. Based on the personal experience, the authors illustrate the scan technique of the secondary palate by 3-D ultrasound in sagittal, coronal and axial plane (multiplanar view) with 3D reconstruction, introducing some new possibilities of 3D scan like *Tomographic Ultrasound Imaging* (TUI) technique. Comparing different technical methods, authors are convinced that most useful is depiction of the palate in the 3-D axial and sagittal plane beginning from the first trimester of pregnancy, but the best results are achieved between the 18 and 25 weeks of gestation. The time needed to render the 3-D image is usually few minutes. The quality of the scan depends, as for the any other 3-D scan, on the fetal position and maternal weight. The association of the facial and palate clefting with chromosomopathies and genetic syndromes which is difficult to depict by 2-D ultrasound, will prompt the investigators to visualize the secondary palate by 3-D scan from the first trimester of pregnancy.

*Pregled*

*Ključne riječi:* rascjep usne, rascjep nepca, 3-D ultrazvuk, prenatalna dijagnoza

**SAŽETAK.** Nove ultrazvučne 3-4/D tehnologije nude posebno i precizno izučavanje nekih anatomskih dijelova, koje je inače teško ili nemoguće vidjeti tradicionalnom 2-D tehnikom. Istraživanje sekundarnog nepca, onoga tvrdoga, te mekoga nepca – uvule u posljednje dvije godine je usmjerilo pozornost istraživača, jer 3-D ultrazvuk omogućuje viđenje sekundarnog nepca. Autori na temelju vlastita iskustva prikazuju način snimanja sekundarnog nepca 3-D ultrazvukom, rekonstrukcijom sagitalne, koronarne i aksijalne ravnine, uvodeći nove mogućnosti ultrazvučne tehnike – tomografsko ultrazvučno snimanje (*Tomographic Ultrasound Imaging* – TUI). Uspoređujući razne metode tehnike autori vjeruju da je najkorisnije otkrivanje nepca u 3-D aksijalnoj i sagitalnoj ravnini, već u prvom tromjesečju, a najbolji je uspjeh otkrivanja s 18–25 tjedana trudnoće. Vrijeme potrebno da se postigne 3-D slika je obično nekoliko minuta. Kvaliteta slike ovisi, kao za bilo koju drugu 3-D sliku, o položaju fetusa i o pretilosti trudnice. Povezanost rascjepa lica i nepca s kromosopatijama i nasljednim sindromima, koje je teško otkriti 2-D ultrazvukom, omogućuje pretraživaču da pomoću 3-D tehnike vidi sekundarno nepce od prvog tromjesečja trudnoće.

### Introduction

Development of 3-D and 4-D ultrasonography enabled better prenatal detection of many malformations among which is detection of malformations of primary and secondary palate.<sup>1–9</sup> Facial clefting accounts for 13% of all congenital malformations.<sup>10</sup> Malformation of the lip and palate may be isolated or associated with other malformations and/or sequences of malformations or syndromes, often connected with chromosomopathies.<sup>10</sup> Typical facial clefting, including isolated cleft lip, cleft lip and cleft palate or isolated cleft palate have prevalence between 6,4 to 9,1/10.000 births, respectively. Cleft lip accounts for 36% of all lip and palate malformations and the prevalence of isolated orofacial clefts accounts for 61,7% of total facial cleftings recorded at birth.<sup>11–13</sup> In 45 to 47% of cases the defect affects the palate only.<sup>11,14</sup> From the epidemiological point of view, isolated malformations of the palate are associated with other malformations in about 18% of patients, while in 27,2% they are associated with syndromes.<sup>11</sup>

Cleft lip and cleft palate is isolated in 70 to 79% of cases and in another 21 to 29% it is part of a syndrome or associated with other malformations.<sup>12,15–19</sup> Chmait in 2006 reported 45 cases of cleft lip and cleft palate diagnosed by 2-D and 3D-4D ultrasound, 21,6% of which were diagnosed as isolated, later not detected by prenatal ultrasound follow up.<sup>20</sup>

The report of EUROSCAN 2000 showed that the sensitivity of the ultrasound was 27% for cleft lip and cleft palate, 17% for isolated forms of cleft lip and 7% for isolated cleft palate.<sup>21</sup> Other reports indicate a detection rate of up to 73% for cleft lip by 2-D scan performed after 20 weeks of pregnancy,<sup>22–24</sup> although in some reports the ultrasound detection sensitivity of isolated cleft of the palate was 0%.<sup>25</sup> The prevalence of this malformation and especially the high incidence of associations with other malformations have prompted researchers to improve ultrasonographic definition of the secondary palate. Usually prenatal karyotyping should be offered in all cases of cleft lip/palate detected by 2-D and 3-D

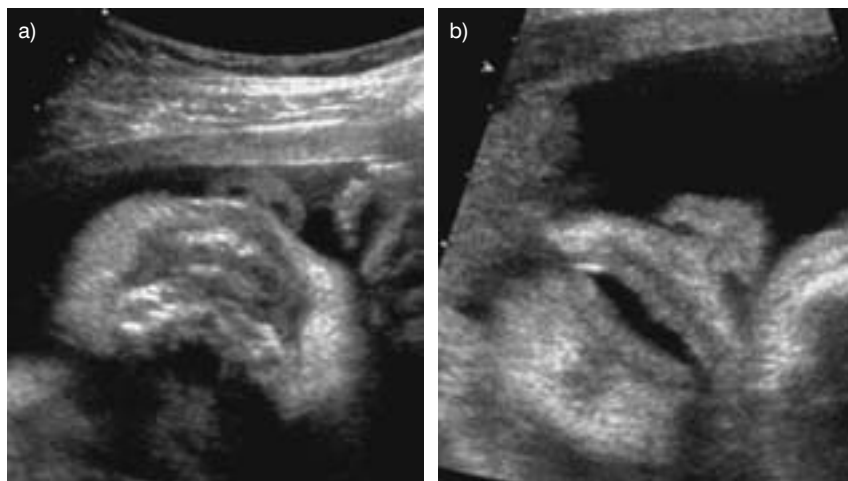


Figure 1. 2D ultrasound depiction of the primary palate in coronal oblique section (a). Depiction of the lips is easier if they are opened (b)  
 Slika 1. Dvodimenzionalni ultrazvučni prikaz primarnoga nepca u koronarnom kosom presjeku (a). Usne je lakše prikazati ako su otvorene (b)

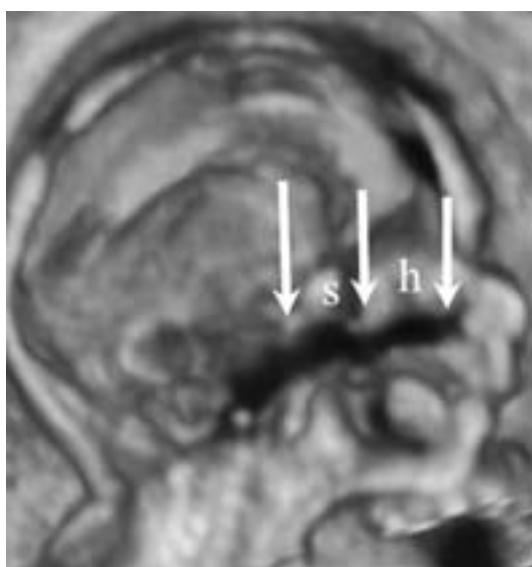


Figure 2. 3D scan of the secondary palate in the sagittal section (arrows showing hard (h) and soft (s) palate with the uvula).  
 Slika 2. Trodimenzionalni prikaz sekundarnog nepca u sagitalnom presjeku (strelice pokazuju tvrdo (h) i meko (s) nepce s uvulom).

ultrasound, because of the increased risk of aneuploidy. Patients should be informed that some malformations which can not be detected by ultrasound can be present at birth in babies with different forms of clefts.<sup>15,26,27</sup>

The MRI is ancillary to ultrasound. Indeed the MRI can allow a better staging of the lesion, but the experiences are old and now we are waiting the results in diagnosing of cleft lip-palate by new 3D techniques. Very important: it is impossible to make a screening by MRI.<sup>8,17,19,24</sup>

### Depiction of the palate by ultrasound

The primary palate includes the lips and jaw, nasal bone which is the most easily detected part of the anatomy by 2-D scan (Figure 1). According to many investigators, it is important to visualise the lips, jaw and the root of the nose in oblique coronal scan, scrolling up-

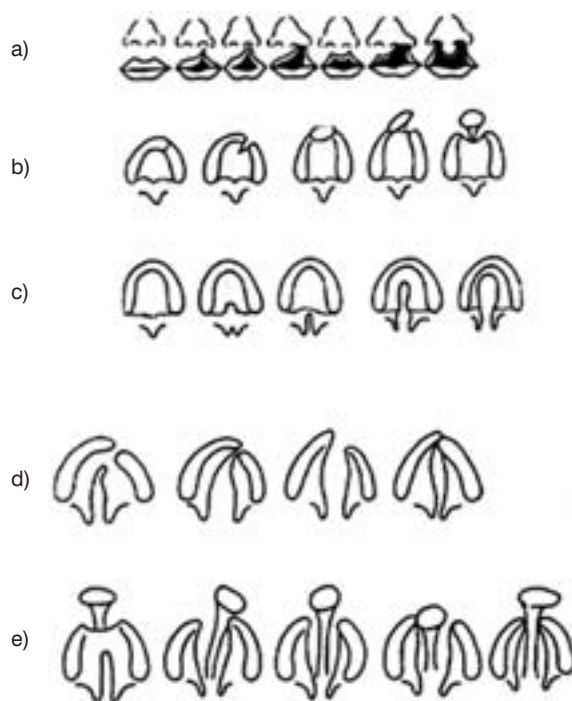


Figure 3. Scheme showing possibilities of facial clefts (Berkowitz, 2006).<sup>3</sup> a and b: cleft lip; c to e: cleft palate starting with cleft uvula and primary palate (c) finishing with severe form of the complete cleft of the primary and secondary palate (e).  
 Slika 3. Shematski prikaz mogućnosti rascjepa lica (Berkowitz, 2006.).<sup>3</sup> a i b rascjep usne; c do e rascjep nepca koji započinje rascjepom uvule i primarnog nepca (c), a završava potpunim rascjepom primarnog i sekundarnog nepca (e).

wards during the routine second trimester scan. Those investigators who use 3-D consider oblique coronal scan of fetal face as a part of the routine. The secondary palate consists of hard palate, which runs behind and horizontally of the incisive foramen and soft palate or velum, which curves downwards and backwards from the posterior part of the hard palate and ends in the uvula. Usually the clefting of the secondary palate is always in midline and results from failure of the palatine processes to elevate and grow (Figure 2).

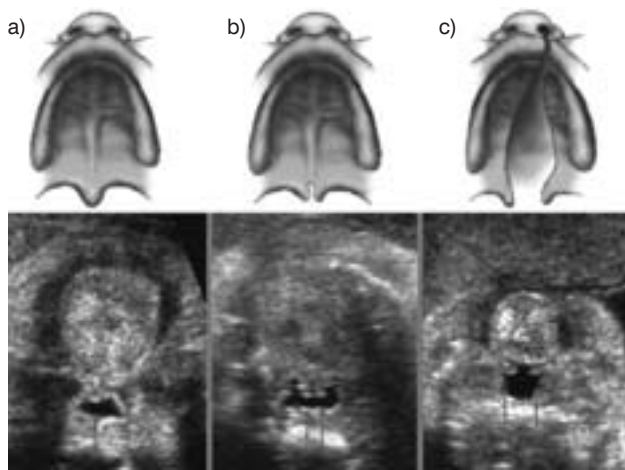


Figure 4. Drawing and 2D ultrasound image of cleft uvula always associated with cleft palate. a) normal finding b) cleft uvula c) cleft uvula and palate

Slika 4. Crtež i dvodimenzionalni ultrazvučni prikaz rascjepa uvule koji je uvijek povezan s rascjepom nepca. a) normalan nalaz b) rascjep uvule c) rascjep uvule i nepca

Clefting of the secondary palate starts from uvula and soft palate, but isolated cleft of the soft palate with intact hard palate is also possible (Figure 3).<sup>28</sup> The shadowing of the maxilla made visualization and the diagnosis of clefts of the secondary palate difficult but not impossible. Sherer et al.<sup>29</sup> stated that visualization of the secondary palate is not difficult by 2-D scan in axial plane, but they did not report any case of defects of secondary palate. The new 3-D volume probe enables multiplanar view and surface rendering, offering more possibilities for detection of the clefting of the primary and secondary palate.<sup>3,4,30-34</sup> By 3-D ultrasound it is possible to visualize the alveolus and maxilla by axial scan and secondary palate by coronal scan scrolling from the front to back in coronal plane.<sup>7</sup>

With this method of depiction there is the problem of the maxillary shadow. Campbell overcomes this problem by rotating the face through 180° and scrolling from back to front.<sup>35</sup> This technique, described as 'reverse

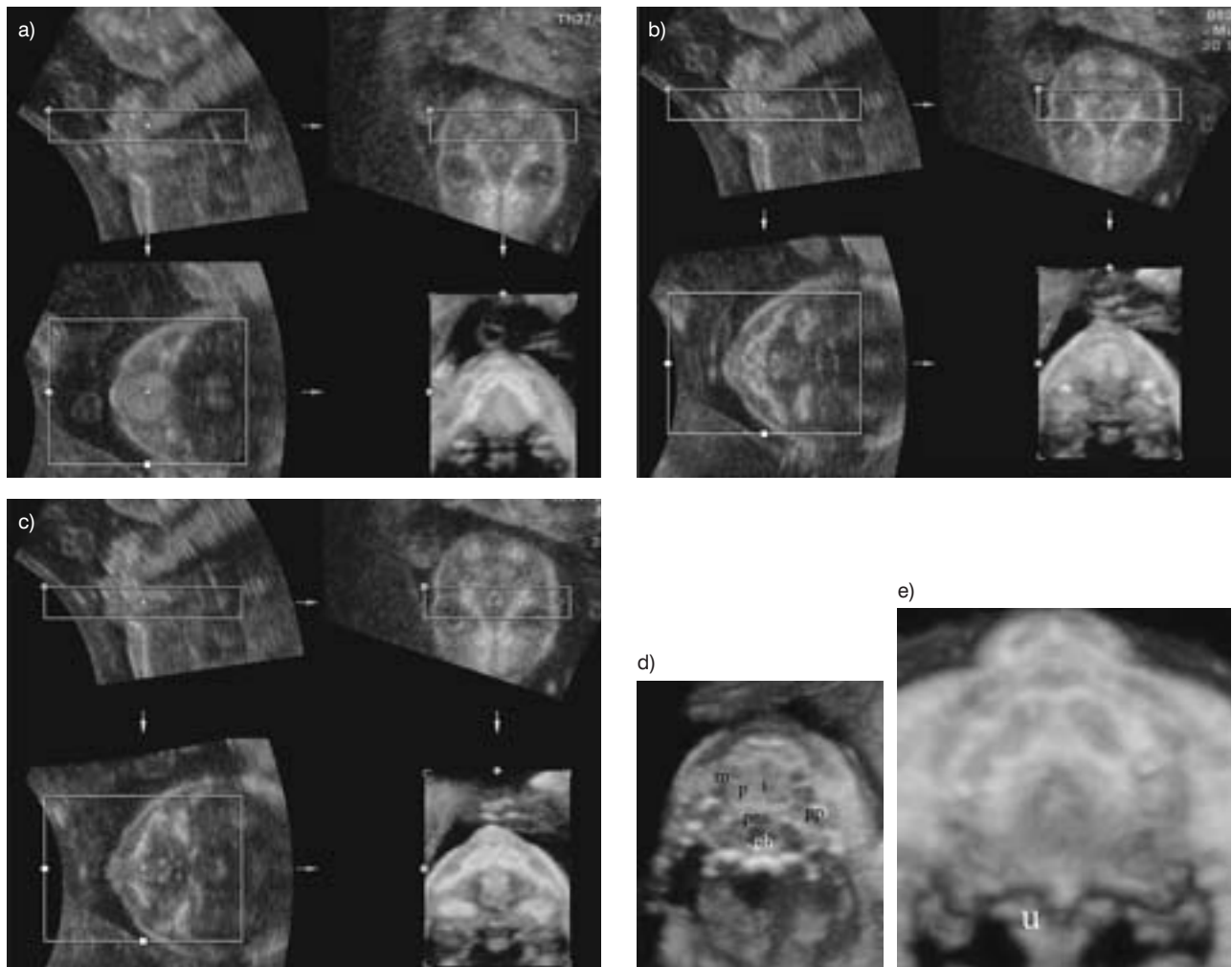


Figure 5. 3D multiplanar view and surface rendering of secondary palate; axial plane with sagittal inverted scan: (a) mandibula; (b) tongue; (c) maxilla; (d) 3D depiction of secondary palate in axial plane – minimum mode: a = alveolar ridge, m = maxilla, i = interpalatal suture, p = palatine process, pns = posterior nasal spine, pp = pterygoid process, u = uvula; (e) depiction of the uvula (u).

Slika 5. Trodimenzionalni multiplanarni i površinski prikaz sekundarnog nepca u aksijalnom i sagitalnom obrnutom prikazu: a) mandibula; b) jezik; c) maksila; d) trodimenzionalni prikaz sekundarnog nepca u aksijalnoj ravnini – minimalni mod: a = alveolarni greben, m = maksila, i = međunepčana udubina, p = nepčani nastavak, pns = stražnji nosni nastavak, pp = pterigidni nastavak, u = uvula; e) prikaz uvule (u)



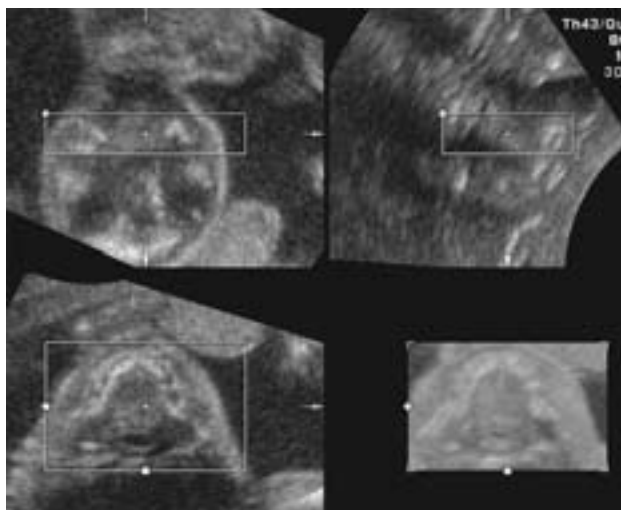


Figure 6. 3D multiplanar view and surface rendering of the secondary palate. Slika 6. Trodimenzionalni multiplanarni i površinski prikaz sekundarnog nepca.

face view', eliminating the shadowing of the maxilla, offers the possibility of a good visualization of the hard palate, but not of the soft palate. Platt et al.<sup>6</sup> found a different technique to visualize the soft palate in axial 3-D plane (multiplanar and surface rendering) with inverted image to avoid the shadowing of the maxilla and using a little acoustic box scrolling from the chin to the nose ('flipped-face view'). Platt et al.<sup>6</sup> used a sagittal scan for depiction of the mandible, the tongue, the maxilla; the alveolar ridge and the secondary complete palate are systematically seen and offers a good mode to diagnosing the clefts of the primary and secondary palate. Faure et al.<sup>5</sup> proposed the same technique of Platt in coronal scan, stating that they were able to visualize the palate in all 100 low-risk fetuses between 17 and 23 weeks of gesta-

tion, with normal anatomy after delivery. Pilu and Segata<sup>36</sup> described a new multiplanar approach to study the secondary palate using TUI (Tomography Ultrasound Imaging). To avoid the shadowing of the alveolar ridge, the authors used a scan with an angle of 45° and obtained a satisfactory visualization in 10 out of 15 fetuses between 19 and 28 weeks of gestation.

There are many possibilities to study systematically the primary and the secondary palate by 2-D ultrasound, but 3-D is better method offering a lot of different possibilities. It is reasonable to say that a golden standard is to have experience with all techniques, specially in cases with doubtful diagnosis of facial clefting, or when is needed to define exactly the exact anatomy of the lesion. Campbell<sup>2</sup> proposed screening of secondary palate in the first trimester depicting it in the axial plane by 3-D rendering. He stated that it was easy to visualize the secondary palate detecting delta sign (Figure 10) from 11 to 14 weeks. Performing 3-D ultrasonography in the second trimester (from 19 to 22 weeks) is associated with increased detection rate of facial clefts (Figure 11).

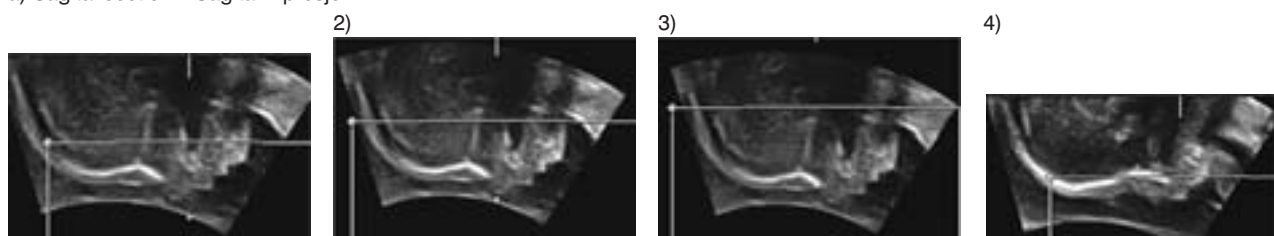
### Secondary palate

The scheme of Berkowitz (Figure 3) illustrates that the uvula is always involved in cleft palate and could simplify detection, but in practice it is difficult to detect this small anatomical part either with 2-D or 3/4-D ultrasound.

### Two dimensional ultrasonography

Two-dimensional scans can be used to study the hard and the soft parts of the secondary palate and for detection of the uvula (Figure 4). However, it is necessary that the fetal head should be in a good position, possibly

a) Sagittal section – Sagitalni presjek



b) Coronal section (reverse mode) – Koronarni presjek (obrnuti prikaz)

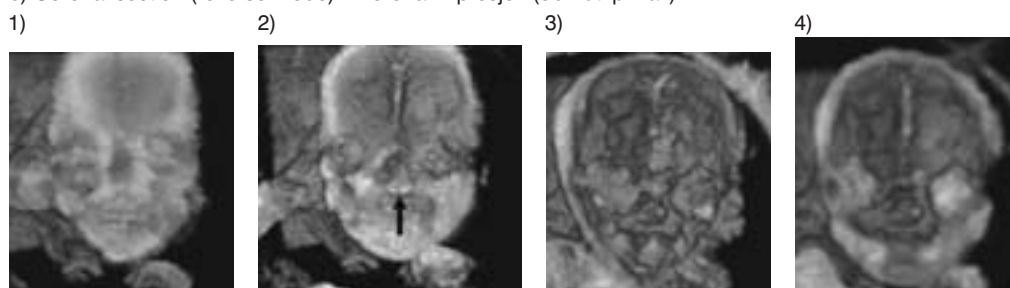


Figure 7. 3D multiplanar view and surface rendering of the secondary palate (reverse mode) in sagittal and coronal sections. Slika 7. Trodimenzionalni multiplanarni i površinski prikaz sekundarnog nepca (obrnuti prikaz) u sagitalnom i konarnom presjeku.

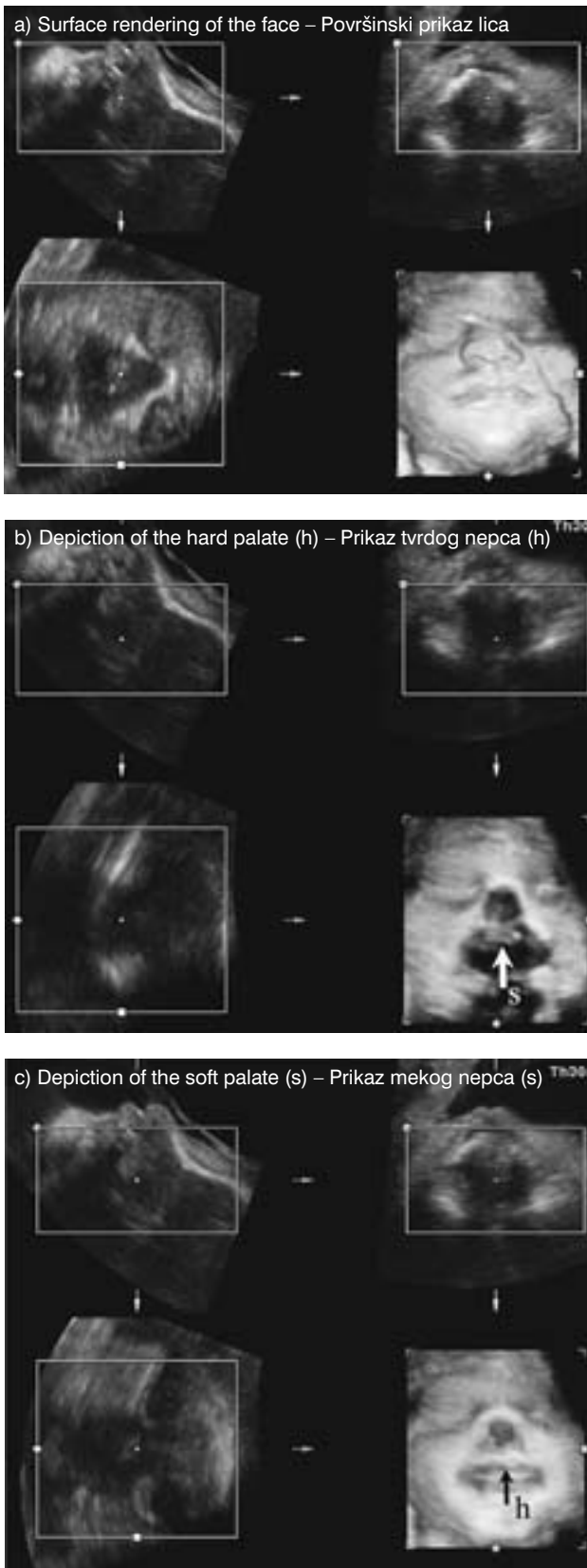


Figure 8. 3D multiplanar view and surface rendering of the secondary palate in the coronal section (scrolling from the frontal plane backwards).  
Slika 8. 3D multiplanarni i površinski prikaz sekundarnog nepca u koronarnom presjeku (od sprijeda prema straga)

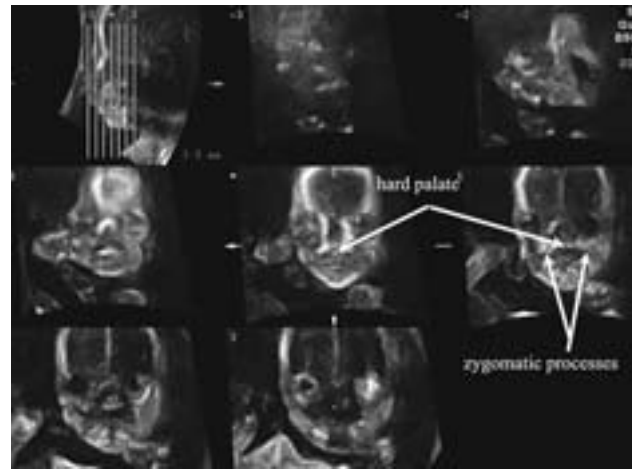


Figure 9. Tomographic Ultrasound Imaging (TUI) of the secondary palate in the coronal plane.

Slika 9. Tomografski ultrazvučni prikaz (TUP) sekundarnog nepca u koronarnoj ravnini.

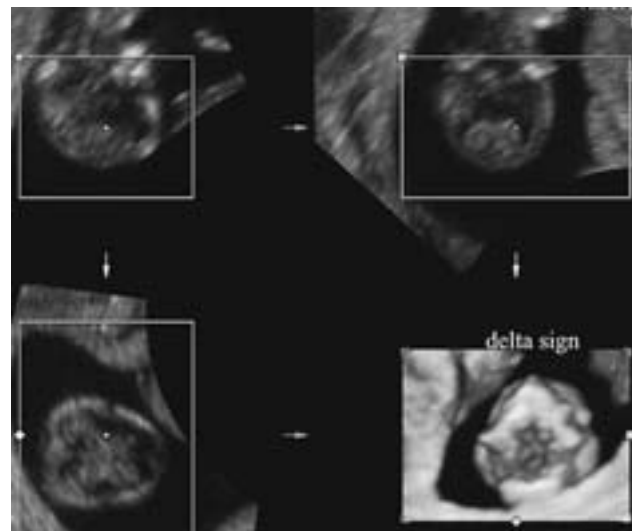


Figure 10. 3D multiplanar view of the maxilla (delta sign) and the hard palate at 12 weeks of gestation.

Slika 10. Multiplanarni trodimenzionalni prikaz maksile (delta znak) i tvrdoga nepca s 12 tjedana trudnoće.

with the lips slightly apart. A routine check of the secondary palate is therefore impossible in practice and it may take an hour or two to obtain a reliable result. This type of study is therefore only feasible when there is a diagnosis of facial cleft.

### 3-4 dimensional ultrasonography

Three-dimensional scans have better possibility to depict cleft of the palate, because a volume can be retrieved and saved, while the »off-line« analysis enables an infinite number of scanning planes. Various methods have been proposed:

- axial surface rendering plane with a small box (»flipped-face view«) and inverted scan to avoid

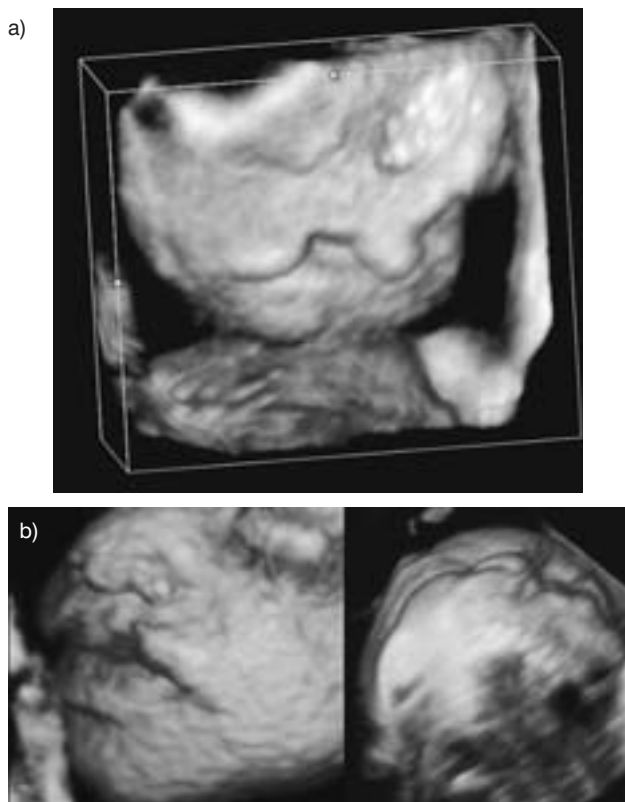


Figure 11. Cleft lip associated with holoprosencephaly diagnosed by 3D ultrasound at 14 (a) and 21 (b) weeks of gestation. a) cleft lip and cleft alveolar ridge at 14 weeks (vaginal probe); b) cleft lip – surface rendering of the face at 21 weeks

Slika 11. Rascjep usne udružen s holoprosencefalijom dijagnosticiran 3D ultrazvukom s 14 tjedana i s 21 tjedan. a) rascijepljena usna s rascijepljenim alveolarnim grebenom s 14 tjedana (vaginalna sonda); b) rascijepljena usna – površinski prikaz lica s 21 tjedan

maxillary shadow (scrolling upwards) by sagittal (Figure 5) or coronal scan (Figure 6)

- coronal surface rendering plane, reverse-face (scrolling forwards) (Figure 7) or front face (scrolling backwards) scan (Figure 8)
- tomographic ultrasound imaging (TUI) sagittal scan at the angle of 45° (Figure 9).

## Conclusion

Detection of facial clefts should be routinely included in the anomaly screening scan at 20 weeks of gestation. If there are problems or any doubts concerning the existence of cleft palate or lip, than 3-D ultrasound can be useful with all its possibilities and »off-line« analysis. Nowadays it would seem reasonable to propose study of the hard and soft palate by 3-D ultrasound only in cases with suspected or confirmed diagnosis of facial clefting and in cases with a positive family history.

*Special acknowledgement to Gabriele Centini.*

## References

1. Benacerraf BR, Sadow PM, Barnewolt CE, Estroff JA, Benson C. Cleft of the secondary palate without cleft lip diag-

nosed with three-dimensional ultrasound and magnetic resonance imaging in a fetus with Fryns' syndrome. *Ultrasound Obstet Gynecol* 2006;27(5):566–70.

2. Campbell S. Prenatal ultrasound examination of the secondary palate. *Ultrasound Obstet Gynecol* 2007;29(2):124–7.

3. Centini G, Rosignoli L, Faldini E, Voltolini C, Tonni G. Comparison between three different methods of scan to visualize the secondary fetal palate by three-dimensional ultrasonography. 17th World Congress on Ultrasound in Obstetrics and Gynecology. Florence: ISUOG 2007.

4. Centini G, Rosignoli L, Faldini E. L'ecografia del primo e secondo trimestre in 3D. *Diagnosi Prenatale*. Ed. Paletto. 2006: 82–104.

5. Faure JM, Captier G, Baumler M, Boulout P. Sonographic assessment of normal fetal palate using three-dimensional imaging: a new technique. *Ultrasound Obstet Gynecol* 2007; 29(2):159–65.

6. Platt LD, Devore GR, Pretorius DH. Improving cleft palate/cleft lip antenatal diagnosis by 3-dimensional sonography: the »flipped face« view. *J Ultrasound Med* 2006;25:1423–30.

7. Rotten D, Levallant JM. Two- and three-dimensional sonographic assessment of the fetal face. 2. Analysis of cleft lip, alveolus and palate. *Ultrasound Obstet Gynecol*. 2004;24:402–11.

8. Tonni G, Panteghini M, Pattacini P, De Felice C, Centini G, Ventura A. Integrating 3D sonography with targeted MRI in the prenatal diagnosis of posterior cleft lip. *J Diagn Med Sonography* 2006;22:367–71.

9. Tonni G, Centini G, Rosignoli L. Prenatal screening for fetal face and clefting in a prospective study on low-risk population: can 3-4 dimensional ultrasound enhance visualization and detection rate? *Oral Pathol Radiol Endodont* 2005;100:420–6.

10. Gorlin RJ, Cervenka J, Pruzansky S. Facial clefting and its syndromes. *Birth Defects Orig Artic Ser* 1971;7(7):3–49.

11. Calzolari E, Bianchi F, Rubini M, Ritvanen A, Neville AJ. Epidemiology of cleft palate in Europe: implications for genetic research. *Cleft Palate Craniofac J* 2004;41(3):244–9.

12. Calzolari E, Pierini A, Astolfi G, Bianchi F, Neville AJ, Rivieri F. Associated anomalies in multi-malformed infants with cleft lip and palate: An epidemiologic study of nearly 6 million births in 23 EUROCAT registries. *Am J Med Genet* 2007; 143(6):528–37.

13. Tolarova MM, Cervenka J. Classification and birth prevalence of orofacial clefts. *Am J Med Genet* 1998;75(2):126–37.

14. Stoll C, Alembik Y, Dott BM, Roth MP. Associated malformations in cases with oral clefts. *Cleft Palate Craniofac J* 2000;37(1):41–7.

15. Milerad J, Larson O, Ph DD, Hagberg C, Ideberg M. Associated malformations in infants with cleft lip and palate: a prospective, population-based study. *Pediatrics* 1997;100(2Pt1):180–6.

16. Walker SJ, Ball RH, Babcock CJ, Feldkamp MM. Prevalence of aneuploidy and additional anatomic abnormalities in fetuses and neonates with cleft lip with or without cleft palate: a population-based study in Utah. *J Ultrasound Med* 2001;20(11): 1175–80.

17. Ghi T, Tani G, Savelli L, Colleoni GG, Pilu G, Bovicelli L. Prenatal imaging of facial clefts by magnetic resonance imaging with emphasis on the posterior palate. *Prenat Diagn* 2003;23(12):970–5.

18. Guven MA, Ceylaner S, Prefumo F, Uzel M. Prenatal sonographic findings in a case of Varadi-Papp syndrome. *Prenat Diagn* 2004;24(12):989–91.



19. Kazan-Tannus JF, Levine D, McKenzie C, et al. Real-time magnetic resonance imaging aids prenatal diagnosis of isolated cleft palate. *J Ultrasound Med* 2005;24(11):1533–40.
20. Chmait R, Pretorius D, Moore T, Hull A, James G, Nelson T, Jones M. Prenatal detection of associated anomalies in fetuses diagnosed with cleft lip with or without cleft palate in utero. *Ultrasound Obstet Gynecol* 2006;27(2):173–6.
21. Clementi M, Tenconi R, Bianchi F, Stoll C. Evaluation of prenatal diagnosis of cleft lip with or without cleft palate and cleft palate by ultrasound: experience from 20 European registries. EUROSCAN study group. *Prenat Diagn* 2000;20(11):870–5.
22. Turnbull C, Lees M, Chitty LS. Prenatal sonographic diagnosis of Malpuech syndrome. *Prenat Diagn* 2006;26(12):1121–3.
23. Sohan, K, Freer M, Mercer N, Soothill P, Kyle P. Prenatal detection of facial clefts. *Fetal Diagn Ther* 2001;16(4):196–9.
24. Smith AS, Estroff JS, Barnewolt CE, Mulliken JB, Levine D. Prenatal diagnosis of cleft lip and cleft palate using MRI. *Am J Roentgenol* 2004;183(1):229–35.
25. Hanikeri M, Savundra J, Gillett D, Walters M, McBain W. Antenatal transabdominal ultrasound detection of cleft lip and palate in Western Australia from 1996 to 2003. *Cleft Palate Craniofac J* 2006;43(1):61–6.
26. Walker ShJ, Ball RH, Babcook CJ, Feldkamp MM. Prevalence of aneuploidy and additional anatomic abnormalities in fetuses and neonates with cleft lip with or without cleft palate. *J Ultrasound Med* 2001;20:1175–80.
27. Mulliken JB, Benacerraf BR. Prenatal diagnosis of cleft lip: what the sonologist needs to tell the surgeon. *J Ultrasound Med* 2001;20(11):1159–64.
28. Berkowitz S. Cleft lip and palate: Diagnosis and management. Berlin: Springer-Verlag, 2006.
29. Sherer DM, Sokolovski M, Santoso PG, Dalloul M, Abulafia O. Nomograms of sonographic measurements throughout gestation of the fetal hard palate width, length and area. *Ultrasound Obstet Gynecol* 2004;24:35–41.
30. Pretorius DH, Nelson TR. Fetal face visualization using three-dimensional ultrasonography. *J Ultrasound Med* 1995;14:349–56.
31. Lee W, Kirk JS, Shaheen KW, Romero R, Hodges AN, Comstock CH. Fetal cleft lip and palate detection by three-dimensional ultrasonography. *Ultrasound Obstet Gynecol* 2000;16:314–20.
32. Johnson DD, Pretorius DH, Budorick NE, et al. Fetal lip and primary palate: three-dimensional versus two-dimensional US. *Radiol* 2000;217:236–9.
33. Shipp TD, Mulliken JB, Bromley B, Benacerraf B. Three-dimensional prenatal diagnosis of frontonasal malformation and unilateral cleft lip/palate. *Ultrasound Obstet Gynecol* 2002;20:290–3.
34. Chmait R, Pretorius D, Jones M, Hull A, James G, Nelson T, Moore T. Prenatal evaluation of facial clefts with two-dimensional and adjunctive three-dimensional ultrasonography: a prospective trial. *Am J Obstet Gynecol* 2002;187:946–9.
35. Campbell S, Lees C, Moscoso G, Hall P. Ultrasound antenatal diagnosis of cleft palate by a new technique: the 3D »reverse face« view. *Ultrasound Obstet Gynecol* 2005;25(1):12–8.
36. Pilu G, Segata M. A novel technique for visualization of the normal and cleft fetal secondary palate: angled insonation and three-dimensional ultrasound. *Ultrasound Obstet Gynecol* 2007;29(2):166–9.

Članak primljen: 24. 07. 2007.; prihvaćen: 15. 12. 2007.

Address for correspondence: Prof. G. Centini, MD, Prenatal Diagnosis Unit, Policlinico. University of Siena, Viale Bracci 1, 53 100 Siena Italy. E-mail: centini@unisi.it



**VIJESTI  
NEWS**

**10<sup>th</sup> EUROPEAN CONGRESS OF ENDOCRINOLOGY**  
**Berlin, 3–7 May 2008**

**Organizer:** European Society of Endocrinology (ESE) with German Society of Endocrinology (DGE)

**Selected topics** (*plenary lectures, symposia, »meet the experts«*): HRT in women – a never ending story • Estrogens and cardiovascular disease • Contraception in the new millennium • New insights in PCOS • An underestimated hormone: Prolactin • How to prevent osteoporosis • Gene/Environment interactions in autoimmune endocrine disease • Is there a crisis in male reproduction • Protein modifications/Proteomics • New treatment approaches for type 2 diabetes mellitus • Let's get older – lessons to learn from centenarians • Central regulation of appetite and body weight – the role of peripheral signals • Androgen therapy of aging male • Stem cell and regeneration • New therapeutic options in diabetes • Too early-too late: The timing of puberty • When and why do we wake up – the endocrine regulation of sleeps in humans

**Hotel accommodation:** possible in 24 hotels, price per night 109\*<sup>3</sup> to 230\*<sup>5</sup> €.

See: *INTERPLAN AG*: [www.interplan.de](http://www.interplan.de); e-mail: [ece@interplan.de](mailto:ece@interplan.de)

**Registration fees:** *ESE non-members*: before 15<sup>th</sup> Febr. 2008 605 €, after 15<sup>th</sup> Febr. 705 €, on-site 750 €. Fellows/students: 300, 370, 400 €. *Special economic package* before 15<sup>th</sup> February 2008: 750 €, which includes bed & breakfast accommodation and lunches for 4 nights. See: [www.ece2008.com](http://www.ece2008.com)

**All information:** [www.ece2008.com](http://www.ece2008.com)