

The influence of Theranekron® on glucose-6-phosphate dehydrogenase activity in rat ovaries, intact and with ischemia-reperfusion injury

Tolunay Kozlu¹, Fatma Güler², Pınar Peker Akalın^{3*}, Filiz Kazak³, Yaşar Ergün⁴, and Erdoğan Aslan⁵

¹Department of Histology and Embryology, Faculty of Veterinary Medicine, Hatay Mustafa Kemal University, Hatay, Turkey

²Institute of Health Sciences, Hatay Mustafa Kemal University, Hatay, Turkey

³Department of Biochemistry, Faculty of Veterinary Medicine, Hatay Mustafa Kemal University, Hatay, Turkey

⁴Department of Obstetrics and Gynecology, Faculty of Veterinary Medicine, Hatay Mustafa Kemal University, Hatay, Turkey

⁵Department of Obstetrics and Gynecology, Private Medicabil Hospital, Bursa, Turkey

KOZLU, T., F. GÜLER, P. PEKER AKALIN, F. KAZAK, Y. ERGÜN, E. ASLAN: The influence of Theranekron® on glucose-6-phosphate dehydrogenase activity in rat ovaries, intact and with ischemia-reperfusion injury. Vet. arhiv 91, 81-88, 2021.

ABSTRACT

The effect of Theranekron® on rat ovaries was evaluated in healthy and ischemia-reperfusion injury models. The rats were divided into four groups: group 1: control, group 2: Theranekron® (single dose of 0.3 mg/kg intraperitoneally), group 3: torsion + detorsion, and group 4: torsion + detorsion + Theranekron® (single dose 0,3 mg/kg, intraperitoneally). The ovaries were homogenized by sonication before the analysis and supernatant glucose-6-phosphate dehydrogenase activity, reduced nicotinamide adenine dinucleotide phosphate, reduced glutathione and total protein levels were evaluated spectrophotometrically. Ovary tissues were histologically examined. In group 2, glucose-6-phosphate dehydrogenase activity was significantly reduced ($P < 0.01$) compared to the control group and an increased number of atretic follicles, and hyperaemic and haemorrhagic regions were seen histologically; in group 3, although glucose-6-phosphate dehydrogenase activity was not changed, intense hyperaemia and hemorrhage was observed in the veins of the medulla region and in the cortex. Group 4 showed a decrease in glucose-6-phosphate dehydrogenase activity compared to the control group ($P < 0.01$). Histologically, when compared to group 3, group 4 showed fewer atretic follicles and decreased hyperaemia and hemorrhage in the ovaries, excluding the medulla region. There were no significant differences regarding reduced glutathione and reduced nicotinamide adenine dinucleotide phosphate levels between the groups. The Theranekron® dose applied had some negative effects, such as reduced glucose-6-phosphate dehydrogenase activity, an increased number of atretic follicles, and hyperemia in the corpus luteum and medulla region in intact rat ovaries. Although it reduced glucose-6-phosphate dehydrogenase activity, Theranekron® may have had slight remedial effects on rat ovaries with ischemia-reperfusion injury.

Key words: Theranekron®; ovary; ischemia-reperfusion; glucose-6-phosphate dehydrogenase; rat

*Corresponding author:

Pınar Peker Akalın, Department of Biochemistry, Faculty of Veterinary Medicine, Hatay Mustafa Kemal University, Hatay, Turkey, Phone: +90 326 221 33 17 ext: 11531; Fax: +90 326 221 33 20; E-mail: ppakalin@mku.edu.tr

Introduction

Ovaries, in humans and mammals, are complex endocrine and exocrine organs that show structural and functional changes during the reproductive cycle (SAHINARSLAN, 2009). It has been reported that the incidence of ovarian torsion among emergency gynecological cases is 2.7% (HIBBARD, 1985; OELSNER and SHASHAR, 2006). The rotation of certain parts or all of the ovary around the vasculature axis of this organ is described as ovarian torsion, eventually leading to ischemia, which is an insufficient supply of blood to an organ, usually due to a blocked artery (PARASHAR and UPPAL, 2011). Although complete arterial obstruction does not generally occur during torsion, histopathological findings, such as congestion, adnexal edema, ischemia and necrosis, have been reported (OELSNER and SHASHAR, 2006). In recent years, the preferred treatment method for ovarian torsion is detorsion by surgical intervention. However, mechanical detorsion and consequent reperfusion of the ovary may have systemic and local consequences due to the fact that restoration of blood flow to the organ, once compromised by ischemia, leads to more severe damage to the tissue than ischemia-induced damage (TASKIN et al., 1998; YAZICI et al., 2007). Furthermore, during the detorsion process, an excess amount of molecular oxygen is supplied to the tissues, and abundant amounts of reactive oxygen species (ROS) are produced, that provoke tissue damage (CADIRCI et al., 2010; ERGUN et al., 2010). An antioxidant enzyme, glucose-6-phosphate dehydrogenase (G6PD), regulates the pentose phosphate metabolic pathway that supplies reducing agents, by maintaining the level of the co-enzyme reduced nicotinamide adenine dinucleotide phosphate (NADPH). Glucose-6-phosphate dehydrogenase reduces nicotinamide adenine dinucleotide phosphate (NADP⁺) to NADPH, while oxidizing glucose-6-phosphate. The NADPH in turn maintains the level of reduced glutathione (rGSH) in the cell, which protects cells against oxidative damage (SALATI and AMIR-AHMADI, 2001). It is reported that some antioxidants, such as superoxide dismutase, catalase and glutathione (GSH), are reduced in ischemia-reperfusion injury in rat ovaries (SOYMAN et al., 2017).

Theranekron® (Richter Pharma, Wels, Austria) is a homeopathic remedy prepared from the poison of Cuban Tarantulas (*Tarentula cubensis*). Although the mechanism of action of Theranekron® is not well defined, it is assumed to stimulate the defense mechanisms of the body leading to amelioration of such inflammatory lesions (DAY, 1998). It is reported that Theranekron® has therapeutic properties in uterine involution (KACAR et al., 2007), mammary tumors (GULTEKIN and VURAL, 2007) and peritoneal wound healing (ADIB-HASHEMI et al., 2016), in animals.

We aimed to investigate the possible remedial effects of Theranekron® in ovarian torsion-detorsion, in which there is a markedly extensive inflammatory response during ischemia-reperfusion (ERGUN et al., 2010; BOSTANCI et al., 2016). Therefore, we designed a study in a rat model, to investigate the acute effects of Theranekron® on intact ovaries and those with induced ischemia-reperfusion injury. To our knowledge, this is the first study to investigate the effects of Theranekron® on the activity of G6PD and levels of NADPH and rGSH, also by describing histological structures in healthy rats and with ischemia-reperfusion injury.

Materials and methods

Animals. In this study, 38 female, non-pregnant, Wistar Albino rats (8-9 weeks-old, 200-250 g/body weight) were used. The animals were housed in polypropylene cages under standard temperature (25 ± 2 °C), laboratory humidity (45 ± 5%), and 12 h light/dark cycle conditions, and were provided with food and water ad libitum for 7 days before the experiment. The study was approved by the Experimental Animals Ethics Committee (Year 2013 - No: 12/4) of Hatay Mustafa Kemal University. All experiments were performed in compliance with international guidelines on the ethical use of animals. Theranekron® was purchased from Richter Pharma, Wels, Austria. The animals were anesthetized with xylazine hydrochloride (7 mg/kg, The Romper, Bayer Pharmaceutical, Germany) and ketamine hydrochloride (60 mg/kg, Ketan's, Eczacıbaşı, Pharmaceutical, Turkey) before the surgical treatment (LEBOVIC et al., 2004). To perform the ovarian torsion in the experimental groups Clip Turcica, a malleable, aluminum device

that facilitates holding and release of the adnexa during a period of experimental ovarian ischemia and reperfusion, was used (HASCALIK et al., 2005, ERGUN et al., 2010).

On the basis of the experimental treatment, the animals were divided into four groups. Group 1 (Control): Rats whose ovaries were removed under anesthesia without being subject to any treatment. Group 2 (Theranekron®): Rats whose ovaries were removed three hours later after a single dose of Theranekron® (0.3 mg/kg, intraperitoneal) administered under anesthesia. Group 3 (Torsion-detorsion): Rats whose ovaries were torsioned

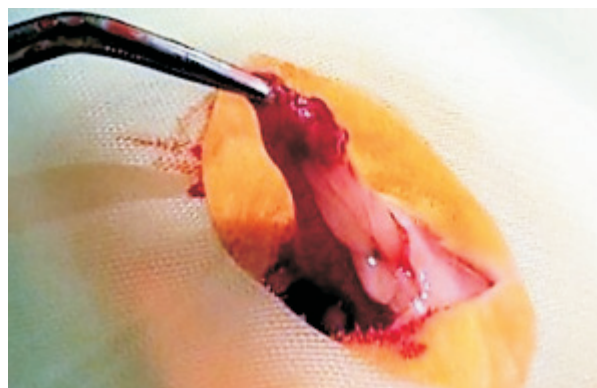


Fig. 1. Torsion-detorsion process by Clip Turcica (Ergün et al., 2010).

Table 1. Experimental design

Group	n	Theranekron® Dose	Theranekron® Duration Time	Torsion Duration Time	Detorsion Duration Time
Group 1	8	-	-	-	-
Group 2	10	0.3 mg/kg	3 hours	-	-
Group 3	10	-	-	3 hours	3 hours
Group 4	10	0.3 mg/kg	3 hours	3 hours	3 hours

Biochemical analysis. The ovaries were dissected, cleaned in ice-cold saline (0.9%, w/v), pat dried on filter paper, weighed, and stored at -86° C in aluminum foil until analysis. Before analysis, the ovaries were sliced in 2 mL transparent, polyethylene tubes (1.5 cm in diameter, 6 cm in length) and sonicated on ice in phosphate buffered solution on a continuous basis, by SONIC vibra cells (Bandelin Sonopuls HD 2070, Germany) 5 times for 10 seconds, a with 30 second cooling period between (AKALIN PEKER et al., 2016). The homogenate was centrifuged at 13000g 15 min/+4° C, and the supernatant was used for spectrophotometrical (UV 2100 UV-VIS Recording Spectrophotometer Shimadzu, Japan) analysis of G6PD activity, rGSH and total protein levels. Supernatant NADPH levels were determined by an ELISA reader (BioTek Instruments, µQuant, U.S.A), with a microplate (Greiner bio-one Italia, Cellstar, Italy).

Determination of glucose-6-phosphate dehydrogenase activity. The G6PD activity was determined spectrophotometrically at 25° C, as

described by BEUTLER (1971). Briefly, the enzyme sample was added to the 1mL of (final volume) incubation mixture containing 100 µL 1 M Tris-HCl-EDTA (pH 8.0) + 100 µL 0,1 mol/L MgCl₂, 100 µL 2 mM NADP⁺ and 100 µL 6 mM glucose-6 phosphate, distilled water and the supernatant. The activity measurement was monitored by the increase in absorption at 340 nm due to the reduction of NADP⁺. Results are presented as IU/g protein.

Determination of reduced glutathione levels. rGSH levels were analyzed according to ELLMAN's (1959) method. It is a kinetic method based on the principle of the reduction of 5.5'-dithiobis (2-nitrobenzoic) acid to trinitrobenzoat by glutathione. The optical density of the reduced disulphide compound absorbance can be measured by spectrophotometry at 412 nm. Results are presented as µmol/g protein.

Determination of NADPH levels. NADPH levels in the supernatants were determined colorimetrically using a commercial kit (MAK038, Sigma-Aldrich, Germany). The reaction principle is based on the colorimetric analysis of the reduction

in the formazan dye by NADPH at 565 nm, which is synthesized enzymatically in the pentose phosphate pathway. Results are presented as $\mu\text{mol/g}$ protein.

Determination of protein levels. Quantitative protein determination was obtained by absorbance measurement at 595 nm according to Bradford, with bovine serum albumin as a standard (BRADFORD, 1979). Results are presented as mg/wet tissue.

Histological analysis. Tissue samples were fixed rapidly with 10% buffered formaldehyde following macroscopic evaluation. Tissue samples were then passed through an alcohol and xylene series

for dehydration and fixation, following a standard protocol, and 4-5 μm paraffin block sections were stained with Crossman's modified triple stain (MULISCH and WELSCH, 2010) and examined under a CX21 Olympus binocular light microscope (Olympus corporation, Japan).

Statistical analysis. All the biochemical values were expressed as mean \pm standard error. The results of the groups were analyzed by ANOVA, with a posthoc Duncan test (SPSS for Windows, release 23.0). A difference of $P < 0.05$ was considered significant.

Results

Biochemical findings. G6PD activity was significantly lower ($P < 0.01$) in group 2 compared to group 1. Group 4 showed non-significantly lower G6PD activity compared to group 3 ($P > 0.05$), but significantly lower activity compared to group 1

($P < 0.01$). Regarding total protein levels, there was a significant increase in total protein levels in group 4 when compared to group 2 ($P < 0.05$). There were no significant changes in rGSH and NADPH levels between the groups (Table 2).

Table 2. The effects of Theranekron® on G6PD, NADPH, rGSH and total protein levels in rat ovaries, intact and with ischemia-reperfusion injury (Mean \pm SE)

Groups	n	G6PD U/g protein	rGSH $\mu\text{mol/g}$ protein	NADPH $\mu\text{mol/g}$ protein	Total Protein mg/wet tissue
Group 1	8	685.11 \pm 93.79 ^a	26.58 \pm 2.59	3.95 \pm 0.89	3.46 \pm 0.33 ^{ab}
Group 2	10	317.65 \pm 61.01 ^b	23.76 \pm 2.25	2.64 \pm 0.25	3.18 \pm 0.26 ^a
Group 3	10	391.76 \pm 98.90 ^{ab}	20.13 \pm 2.95	2.61 \pm 0.15	3.59 \pm 0.29 ^{ab}
Group 4	10	156.48 \pm 29.89 ^b	21.86 \pm 2.72	3.94 \pm 0.25	4.63 \pm 0.62 ^b
P		$P < 0.01$	-	-	$P < 0.05$

Means within rows without common superscripts differ significantly (^{a,b} $P < 0.05$). Group 1 - Control, Group 2 - Theranekron®, Group 3 - Torsion-Detorsion, Group 4 - Torsion-Detorsion + Theranekron® groups

Histological findings. The ovarian sections, germinative epithelium, follicles, corpus luteum and vascular structures in the medulla region taken from the control group demonstrated organ specific histological structures (Fig. 2). In group 2, the tissue integrity was maintained and there was no sign of germinative epithelium degradation. An increased number of atretic follicles and hyperemia of the medulla region were observed. In the cortical area, hemorrhage of the corpus luteum and hyperemia in corpus luteum veins was detected. Moreover, when compared to control group, an increase in interstitial cells was observed (Fig. 3).

In group 3, in general, there was no change in tissue integrity. However, local degeneration was observed in the structure of the germinative epithelium compared to the control and Theranekron® groups. Intense hyperemia and hemorrhage were observed in the veins of the medulla region, on the follicles surrounding the cortex, in the interstitium and the corpus luteum. When compared to the control group, similar to the Theranekron® group, an increase in the number of atretic follicles was observed in group 3 (Fig. 4). In group 4, when compared with group 3, similar findings were observed of preservation of tissue

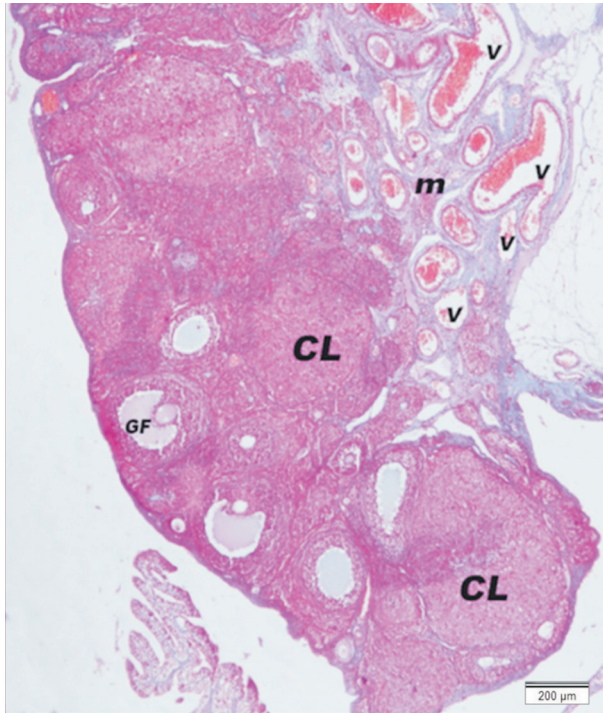


Fig. 2. Triple staining method of rat ovarian section from the control group; CL - corpus luteum, v -vessel, GF - graaf follicle, m - medulla, v - vein

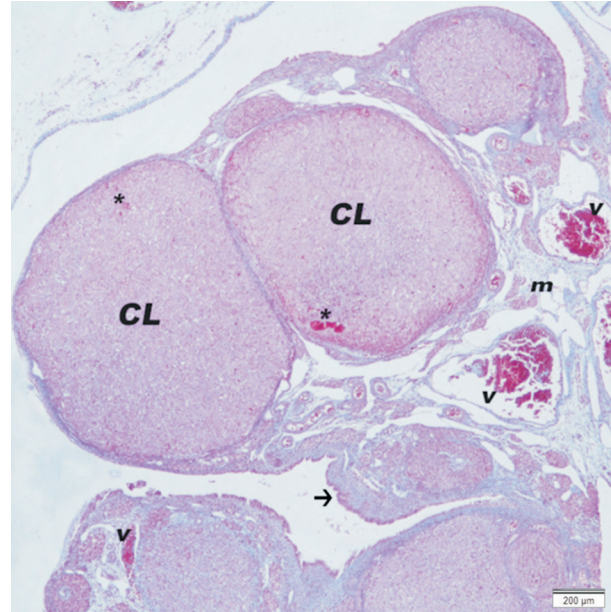


Fig. 3. Triple staining method of rat ovarian section from Group 2 (Theranekron®). CL - Corpus Luteum; hyperemia, m - medulla; hyperemia in the veins of the medulla region, v - vein,*; arrow - germinal epithelium.

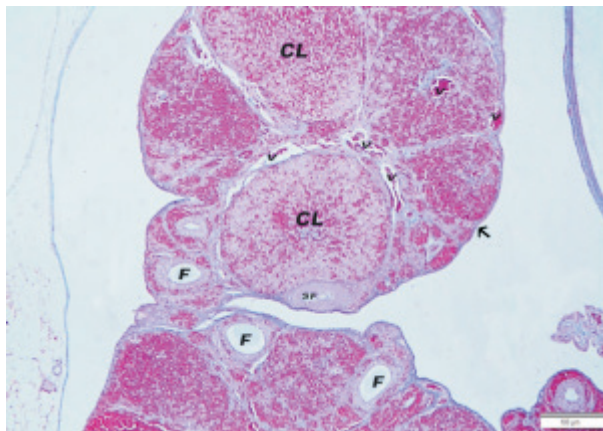


Fig. 4. Triple staining method of rat ovarian section from Group 3 (Torsion-Detorsion). CL - Corpus Luteum; hemorrhage, SF - secondary follicle, F - follicle; increased number of atretic follicles, v - vein; intense hyperemia and hemorrhage in the veins of the medulla region, arrow - germinal epithelium; local degeneration.

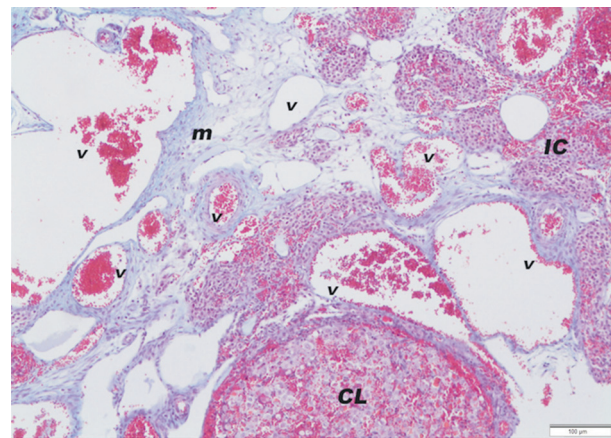


Fig. 5. Triple staining method of rat ovarian section from Group 4 (Torsion - Detorsion + Theranekron®). CL - corpus luteum; hemorrhage, m - medulla; hyperemia and hemorrhage in the veins of the medulla region, v - vein; hyperemia, IC - intersitital cells.

integrity. However, fewer atretic follicles were observed. Generally, there was a slight reduction in hyperemia and hemorrhage, except in the medulla in comparison with the regions mentioned in group 3, but the intensity of hyperemia in the medulla was at the same level as in group 3. At the same time, a slight decrease in degeneration and the amount of connective tissue in interstitial regions was present (Fig. 5).

Discussion

Theranekron® is a homeopathic remedy for the treatment of lesions in the mouth, hoof and endometrium in veterinary medicine (STAMPA, 1986; ORYAN et al., 2012; DOLAPCIOGLU et al., 2013; ADIB-HASHEMI et al., 2016). However, our literature search did not reveal any study regarding the effects of Theranekron® on healthy tissues. Only the unchanged serum aspartate amino transferase and gamma-glutamyl transferase activities suggested that Theranekron® did not have any adverse effects on the liver in healthy horses (SARDARI et al., 2011). In this study, Theranekron® administration to healthy rats significantly decreased ovarian G6PD activity and caused hemorrhage and hyperemia in the corpus luteum and in the veins of the medulla region, histologically. Biochemical and histological results suggested that Theranekron® may have some degenerative effects on intact rat ovaries and no anabolic effects.

Ovarian torsion, a gynecological syndrome that occurs mostly in adolescent girls and women before menopause (HIBBARD, 1985; OELSNER and SHASHAR, 2006), will cause venous obstruction, bleeding and eventually necrosis of the ovarian tissues. Even though the traditional treatment has been oophorectomy for these cases, recent literature contains cases of conservative therapy based on detorsion of the twisted adnexa, which has become popular (TASKIN et al., 1998; YAZICI et al., 2007). However, recirculation of the ovary after detorsion causes a pathophysiological event known as “reperfusion injury”. During reperfusion injury, systemic and local consequences due to the restoration of blood flow and excess amounts of ROS, lead to severe tissue damage (CADIRCI et al., 2010; ERGUN et al., 2010). Thus, in this

study, we investigated the remedial effects of Theranekron®, which is a homeopathic remedy, on ischemia-reperfusion injury induced in rat ovaries. Our histological findings in the torsion-detorsion group, such as intense hyperemia and hemorrhages in the medulla and cortex, and structures of the corpus luteum, were compatible with the result of BOSTANCI et al., (2016), who showed extensive vascular congestion, hemorrhage, and edema in torsion-detorsion injury in rat ovaries. However, antioxidants, such as G6PD activity, NADPH and rGSH levels, were not changed. On the other hand, oxidative stress may be increased in ischemia-reperfusion injury, in that lipid peroxidation (LPO) and/or malondialdehyde (MDA) levels increased after torsion-detorsion in rat ovaries (ERGUN et al., 2010). These findings suggest that, increased LPO/MDA levels in torsion-detorsion may be related to other antioxidants rather than G6PD, NADPH and rGSH, and possibly lead to tissue degeneration.

In the study, Theranekron® reduced G6PD activity not only in intact ovaries but also in ischemia-reperfusion injury. Also, in these animals, NADPH levels were unchanged despite the G6PD activity reduced by Theranekron®. ROSA et al. (2012), suggested that reduced G6PD and unchanged 6-phosphogluconate dehydrogenase (6PGD) activity would impair NADPH production in rat brain cells, but they did not determine NADPH levels. Hence, we speculate that cells have other NADPH producing enzymes, such as 6PGD, cytoplasmic isocitrate dehydrogenase, or malic enzyme (FLINT and DENTON, 1970) to maintain oxidative balance. Given the preserved NADPH and rGSH levels and from the histological findings (fewer atretic follicles, a slight reduction in hyperemia and hemorrhage except in the medulla region, and a slight decrease in degeneration and the amount of connective tissue in interstitial regions), we may argue that ovary tissues may be slightly protected by the Theranekron® dose applied in the torsion-detorsion process. However, detailed experimental studies are needed to elucidate the optimum remedial dose of Theranekron® for ischemia-reperfusion injury in rat ovaries.

Conclusion

Biochemical and histological findings in rat ovaries with intact and ischemia-reperfusion injury showed that, the Theranekron® dose applied may have some degenerative effects on intact ovaries, and may have some remedial effects on ischemia-reperfusion injury in ovaries. Detailed experimental studies are needed to elucidate the optimum remedial dose of Theranekron® on ischemia-reperfusion injury in rat ovaries.

Conflict of interests

All authors declare no conflict of interests regarding the content of the paper

Acknowledgements

This study was produced by the Hatay Mustafa Kemal University Scientific Research Projects Unit as part of a thesis study supported by Project number 12241.

References

- ADIB-HASHEMI, F., F. FARAHMAND, S. F. HESARI, B. REZAKHANIHA, E. FALLAH, A. F. FAYYAZ, M. DADPAY (2016): Retraction note: Anti-inflammatory and protective investigations on the effects of Theranekron® "an alcoholic extract of the *Tarantula cubensis*" on wound healing of peritoneal in the rat: an *in vivo* comparative study. *Diagn. Pathol.* 11, 118.
DOI: 10.1186/s13000-016-0575-2
- AKALIN PEKER, P., N. BAŞPINAR, K. ÇOYAN, M. N. BUCAK, Ş. GÜNGÖR, C. ÖZTÜRK (2016): Effects of ultrasonication on damaged spermatozoa and mitochondrial activity rate. *Turk. J. Vet. Anim. Sci.* 40, 195-199.
DOI: 10.3906/vet-1507-18
- BEUTLER, E. (1971): Red cell metabolism: A Manual of Biochemical Methods. Acad Press, London, UK, pp. 68-70.
- BOSTANCI, M. S., M. BAKACAK, F. INANÇ, F., A. YAYLALI, S. SERIN, R. ATTAR, Ö. KIZILKALE YILDIRIM, G. YILDIRIM (2016): The protective effect of G-CSF on experimental ischemia/reperfusion injury in rat ovary. *Arch. Gynecol. Obstet.* 293, 89-95.
DOI: 10.1007/s00404-015-3878-8
- BRADFORD, M. M. (1979): A rapid and sensitive method for the quantitation of microgram quantities of protein utilizing the principle of protein-dye binding. *Anal. Biochem.* 72, 248-254.
DOI: 10.1006/abio.1976.9999
- CADIRCI, E., A. ORAL, F. ODABASOĞLU, C. KILIC, K. COSKUN, Z. HALICI, H. SULEYMAN, N. O. KELES, B. UNAL (2010): Atorvastatin reduces tissue damage in rat ovaries subjected to torsion and detorsion: biochemical and histopathologic evaluation. *Naunyn Schmiedebergs Arch. Pharmacol.* 381, 455-466.
DOI: 10.1007/s00210-010-0504-y
- DAY, C. (1998): Complementary and alternative veterinary medicine Veterinary homeopathy: principles and practice. (Schoen, A. M., G.W. Suzan, Eds), 1st ed., Mosby, U.S.A. pp. 485-513.
- DOLAPCIOĞLU, K., G. DOGRUER, S. OZSOY, Y. ERGUN, S. CIFTCI, O. SOYLU KARAPINAR, E. ASLAN (2013): Theranekron® for treatment of endometriosis in a rat model compared with medroxyprogesterone acetate and leuprolide acetate. *Eur. J. Obstet. Gynecol. Reprod. Biol.* 170, 206-210.
DOI: 10.1016/j.ejogrb.2013.05.026
- ELLMAN, G. (1959): Tissue sulphhydryl groups. *Arch. Biochem. Biophys.* 82, 70-77.
DOI: 10.1016/0003-9861(59)90090-6
- ERGUN, Y., A. KOC, K. DOLAPCIOĞLU, Y. AKAYDIN, G. DOGRUER, T. KONTAS, T. KOZLU, E. ASLAN (2010): The protective effect of erythropoietin and dimethylsulfoxide on ischemia-reperfusion injury in rat ovary. *Eur. J. Obstet. Gynecol. Reprod. Biol.* 152, 186-190.
DOI: 10.1016/j.ejogrb.2010.05.025
- FLINT, A. P. F., R. M. DENTON (1970): The role of nicotinamide-adenine dinucleotide phosphate-dependent malate dehydrogenase and isocitrate dehydrogenase in the supply of reduced nicotinamide-adenine dinucleotide phosphate for steroidogenesis in the superovulated rat ovary. *Biochem. J.* 117, 73-83.
DOI: 10.1042/bj1170073
- GULTEKIN, N., M. R. VURAL (2007): The effect of *Tarantula cubensis* extract applied in pre and postoperative period of canine mammary tumours. *J. Ist. Vet. Sci.* 2, 13-23.
- HASCALIK, S., O. CELIK, Y. TURKOZ, B. MIZRAK (2005): Clip Turcica: A new apparatus for experimental ovarian ischemia and reperfusion model in rats. *Fertil. Steril.* 84, 219-220.
- HIBBARD, L. T. (1985) Adnexal torsion. *Am. J. Obstet. Gynecol.* 152, 456-461.
DOI: 10.1016/j.fertnstert.2005.03.024
- KACAR, C., A. K. ZONTURLU, H. ORAL, S. YILDIZ, U.C. ARI (2007): The effects of Theranekron® application on uterus involution and vaginal effluence in cows early puerperal period. *Kafkas Univ. Vet. Fak. Derg.* 13, 11-15. (In Turkish).
- LEBOVIC, D. I., M. KIR, C. L. CASEY (2004): Peroxisome proliferator-activated receptor-gamma induces regression of endometrial explants in a rat model of endometriosis. *Fertil. Steril.* 82, 1008-1013.
DOI: 10.1016/j.fertnstert.2004.02.148
- MULISCH, M., U. WELSCH (2010): Romei's Microscopic Technology, 18th ed., Spectrum Akademischer Verlag Heidelberg, Germany.

- OELSNER, G., D. SHASHAR (2006): Adnexal torsion. Clin. Obstet. Gynecol. 49, 459-463.
DOI: 10.1097/00003081-200609000-00006
- ORYAN, A., A. MOSHIRI, A. R. RAAYAT (2012): Novel application of Theranekron® enhanced the structural and functional performance of the tenotomized tendon in rabbits. Cells Tissues Organs 196, 442-455.
DOI: 10.1159/000337860
- PARASHAR, U., T. UPPAL (2011): Ovarian torsion is an infrequent, but important, cause of acute abdomino-pelvic pain in women. O and G Magazine. 13, 34-35.
- ROSA, A. P., C. E. DIAS JACQUES, T. B. MORAES, C.M.D. WANNMACHER, A.M.O. DUTRA, C. S. DUTRA-FILHO (2012): Phenylpyruvic acid decreases glucose-6-phosphate dehydrogenase activity in rat brain. Cell Mol. Neurobiol. 32, 1113-1118.
DOI: 10.1007/s10571-012-9834-2
- SALATI, L., M. B. AMIR-AHMADI (2001): Dietary regulation of expression of glucose-6-phosphate dehydrogenase. Annu. Rev. Nutr. 21, 121-140.
DOI: 10.1146/annurev.nutr.21.1.121
- SARDARI, K., M. MOHRI, S. SABZEVARI, B. FATHI (2011): Effects of the Theranekron® “an alcoholic extract of the *Tarantula cubensis*” on hematology and serum biochemical properties in horses. Iranian Vet. Sci. Tech. 3, 9-16.
DOI: 10.22067/VETERINARY.V3I2.17858
- SOYMAN, Z., S. KELEKÇI, V. SAL, O. ŞEVKET, N. BAYINDIR, H. UZUN (2017) Effects of apigenin on experimental ischemia/reperfusion injury in the rat ovary. Balkan Med. J., 34, 444-449.
DOI: 10.4274/balkanmedj.2016.1386
- STAMPA, S. (1986): A field trial comparing the efficacy of sulphamonomethoxine, penicillin and tarantula poison in the treatment of pododermatitis circumspecta of cattle. J. S. Afr. Vet. Assoc. 57, 91-93.
- SAHINARSLAN, N. (2009): Investigation of the effects of nitric oxide on the development of the rat ovary in the light and electron microscopic level. Thesis (Master). İstanbul University, İstanbul, Turkey (in Turkish).
- TASKIN, O., M. BIRINCIÖGLU, A. AYDIN, A. BUHUR, F. BURAK, I. YILMAZ, J. M. WHEELER (1998): The effects of twisted ischaemic adnexa managed by detorsion on ovarian viability and histology: an ischaemia-reperfusion rodent model. Hum. Reprod. 13, 2823-2827.
DOI: 10.1093/humrep/13.10.2823
- YAZICI, G., O. ERDEM, B. CIMEN, M. ARSLAN, B. TASDELEN, I. CINEL (2007): Genistein attenuates post ischemic ovarian injury in a rat adnexal torsion-detorsion model. Fertil. Steril. 87, 391-396.
DOI: 10.1016/j.fertnstert.2006.06.056

Received: 25 September 2019

Accepted: 7 July 2020

KOZLU, T., F. GÜLER, P. PEKER AKALIN, F. KAZAK, Y. ERGÜN, E. ASLAN: Utjecaj Theranekrona® na aktivnost glukoza-6-fosfat dehidrogenaze u neoštećenim jajnicima štakora i jajnicima štakora s ishemijsko-reperfuzijskom ozljedom. Vet. arhiv 91, 81-88, 2021.

SAŽETAK

Učinak Theranekrona® na jajnike štakora procijenjen je u zdravih jedinki i onih s ishemijsko-reperfuzijskom ozljedom. Štakori su podijeljeni u četiri skupine: prva je skupina bila kontrolna, druga je skupina dobivala Theranekron® (pojedinačna doza od 0,3 mg/kg intraperitonealno), treća je skupina imala torziju i detorziju, a četvrta je skupina imala torziju i detorziju i primala je Theranekron® (pojedinačna doza od 0,3 mg/kg intraperitonealno). Jajnici su homogenizirani sonikacijom prije analize te je spektrofotometrijom istražena aktivnost supernatant glukoza-6-fosfat dehidrogenaze, smanjenje nikotinamid-adenin-dinukleotid-fosfata, smanjenje glutaciona i razina ukupnih proteina. Histološki je analizirano tkivo jajnika. U drugoj skupini aktivnost glukoza-6-fosfat dehidrogenaze bila je znakovito smanjena ($P < 0,01$) u usporedbi s kontrolnom skupinom. Histološki, ustanovljen povećan broj atretnih folikula te hiperemičnih i hemoragičnih područja. U trećoj skupini, iako aktivnost glukoza-6-fosfat dehidrogenaze nije bila promijenjena, u venama medularne regije i korteksu uočena je jaka hiperemija i hemoragija. Četvrta skupina pokazala je smanjenu aktivnost glukoza-6-fosfat dehidrogenaze u usporedbi s kontrolnom skupinom ($P < 0,01$). U usporedbi s trećom skupinom, četvrta skupina pokazala je manje atretnih folikula i smanjenu hiperemiju i hemoragiju u jajnicima, osim medularne regije. Nije bilo znakovite razlike s obzirom na smanjene razine glutaciona i nikotinamid-adenin-dinukleotid-fosfata među skupinama. Primijenjena doza Theranekrona® imala je neke negativne učinke poput smanjene aktivnosti glukoza-6-fosfat dehidrogenaze, povećanog broja atretnih folikula te hiperemije u žutom tijelu i medularnoj regiji intaktnih jajnika štakora. Iako je smanjio aktivnost glukoza-6-fosfat dehidrogenaze, Theranekron® bi mogao imati i neznatne terapijske učinke na jajnike štakora s ishemijsko-reperfuzijskom ozljedom.

Ključne riječi: Theranekron®; jajnik; ishemijsko-reperfuzija; glukoza-6-fosfat dehidrogenaza; štakor