

# Nova generacija CT uređaja za oslikavanje koronarne bolesti srca – implikacije za buduće pružanje usluga

## New-generation Computed Tomography Scanners for Coronary Artery Disease Imaging – Implications for Future Service Provision

**Petar Medaković<sup>1\*</sup>**

**Zrinka Biloglav<sup>2</sup>**

<sup>1</sup>Specijalna bolnica Agram, Zagreb, Hrvatska

<sup>2</sup>Škola narodnog zdravlja "Andrija Štampar", Medicinski fakultet Zagreb, Sveučilište u Zagrebu, Zagreb, Hrvatska

<sup>1</sup>Special Hospital Agram, Zagreb, Croatia,

<sup>2</sup>School of Public Health Andrija Štampar, University of Zagreb School of Medicine, Zagreb, Croatia

**RECEIVED:**  
February 28, 2021

**UPDATED:**  
March 8, 2021

**ACCEPTED:**  
March 21, 2021



**SAŽETAK:** Europsko kardiološko društvo (ESC) izdalo je 2019. godine Smjernice za dijagnostiku i liječenje kroničnoga koronarnog sindroma, koje uključuju nove preporuke za MSCT koronarografiju. Nove ESC smjernice promaknule su MSCT koronarografiju u pretragu klase I, što podrazumijeva da je MSCT koronarografija ili neinvazivno funkcionalno oslikavanje preporučena pretraga za ishemijsku miokarda i prvi test kojim se dijagnosticira koronarna bolest srca (CAD) u simptomatskih bolesnika u kojih se opstruktivna CAD ne može isključiti na temelju kliničke procjene. Bolesnike zahtjevne za snimanje, kao što su primjerice oni s opsežnim koronarnim kalcifikacijama (>400 Agatstonovih jedinica), povišenom (>65/min) ili nepravilnom frekvencijom srca, preteli i oni koji ne mogu zadržati dah, već je prije prepoznao Nacionalni institut za izvrsnost zdravlja i skrbi (NICE) na starijim generacijama uređaja. U takvih pacijenata NICE, za razliku od ESC smjernica preporučuje uporabu uređaja nove generacije ili čak neke specifične modele. Usprkos razlikama u preporukama NICE-a i ESC-a iskusan klinički tim sastavljen od inženjera radiologije, radiologa i kardiologa i u bolesnika zahtjevnih za snimanje na CT uređajima nove generacije može dobiti dobru kvalitetu slike. Kada se uzme u obzir opterećenje čimbenicima kardiovaskularnog rizika i Smjernice ESC-a iz 2019. godine, možemo očekivati porast upućivanja bolesnika na MSCT koronarografiju na nacionalnoj razini, što je slučaj i u drugim zemljama sa sličnim kardiovaskularnim opterećenjem usprkos opaženim varijacijama u kliničkoj praksi. Brojne javne bolnice kupile su uređaje koji ispunjavaju tehničke smjernice Društva za kardiovaskularnu kompjutoriziranu tomografiju (SCCT), međutim, oni nisu namijenjeni za kardiovaskularno oslikavanje niti preporučeni za bolesnike zahtjevne za snimanje. Za takve bolesnike CT uređaji trebali bi sadržavati tehnologiju s dvjema rendgenskim cijevima s dvama snažnim strujnim generatorima koji osiguravaju dobru temporalnu rezoluciju i dugačak niz detektora u z-smjeru kako bi se osigurala visoka prostorna razlučivost i volumska pokrivenost. Za dobru kvalitetu slika potrebno je pripremiti bolesnika i prilagoditi protokol snimanja prema njegovim obilježjima. Samo na takav način, u skladu s nedavnim kliničkim smjernicama, bolesnici mogu imati dobit od ove radiološke pretrage visoke tehnološke razine.

**SUMMARY:** The European Society of Cardiology (ESC) published guidelines for the diagnosis and management of chronic coronary syndromes in 2019 that included new recommendations for coronary computed tomography angiography (CCTA). The new ESC guidelines promoted CCTA as a Class I examination, which means that CCTA or non-invasive functional imaging is recommended or indicated for myocardial ischemia as the initial test for diagnosing CAD in symptomatic patients in whom obstructive CAD cannot be excluded by clinical assessment alone. Patients who are difficult to scan, such as those with extensive coronary calcifications (>400 Agatston Units), increased (>65 bpm) or irregular heart rate, or those who are obese (body mass index >30) and unable to hold their breath, have been already identified by the National Institute for Health and Care Excellence (NICE) in earlier scanner generations. For these patients, NICE recommends the new generation of scanners or even particular scanner models, as opposed to the ESC guidelines which do not recommend CCTA. In spite of differences between ESC and NICE recommendations, an experienced clinical team consisting of a radiographer, radiologist, and cardiologist can obtain good image quality from new-generation CT scanners, even from patients who are difficult to scan. Considering the burden of risk factors and the 2019 ESC guidelines, referrals to CCTA are expected to rise at the national level, as they have in other countries with a similar cardiovascular burden, although clinical practice may vary. Numerous public hospitals have purchased scanners that fulfil SCCT technical guidelines, but these are neither cardiac-dedicated nor recommended for patients who are difficult to scan. CT scanners for these patients should feature dual-source technology with two powerful current generators in order to provide good temporal resolution; they should also have a long z-detector array in order to ensure high spatial resolution and volume coverage. Good image quality requires appropriate patient preparation and the adjustment of scan protocols to individual patient characteristics. This is the only way patients can benefit from this high-tech radiological procedure, according to recent clinical guidelines.

**KLJUČNE RIJEČI:** koronarna bolest srca, MSCT koronarografija, smjernice.

**KEYWORDS:** coronary artery disease, coronary computed tomography angiography, guidelines.

**CITATION:** *Cardiol Croat.* 2021;16(5-6):208-14. | <https://doi.org/10.15836/ccar2021.208>

**\*ADDRESS FOR CORRESPONDENCE:** Petar Medaković, Specijalna bolnica Agram, Trnjanska cesta 108, HR-10000 Zagreb, Croatia. / Phone: +385-1-5497 215 / E-mail: [eranio@gmx.at](mailto:eranio@gmx.at)

**ORCID:** Petar Medaković, <https://orcid.org/0000-0002-7173-8286> • Zrinka Biloglav, <https://orcid.org/0000-0002-3245-001X>

**TO CITE THIS ARTICLE:** Medaković P, Biloglav Z. New-generation Computed Tomography Scanners for Coronary Artery Disease Imaging – Implications for Future Service Provision. *Cardiol Croat.* 2021;16(5-6):208-14 | <https://doi.org/10.15836/ccar2021.208>

**TO LINK TO THIS ARTICLE:** <https://doi.org/10.15836/ccar2021.208>

Europsko kardiološko društvo (ESC) izdalo je 2019. godine Smjernice za dijagnostiku i liječenje kod kroničnog koronarnog sindroma, što uključuje nove preporuke za MSCT koronarografiju.<sup>1</sup> U ovom ćemo članku razmotriti novu ulogu MSCT koronarografije u dijagnostičkom algoritmu koronarne bolesti srca (CAD) i poteškoćama koje se pojavljuju pri njezinoj primjeni u sustavu zdravstvene zaštite. Osim toga, detaljno smo opisali bolesnike zahtjevne za snimanje poput onih s opsežnim koronarnim kalcifikacijama, povišenom ili nepravilnom srčanom frekvencijom i pretile.

Premda CAD ima heterogenu morfologiju, u praksi i dalje dominira bivarijatna klinička percepcija kardiovaskularnog kontinuuma, koja razlikuje akutni koronarni sindrom od kroničnoga.<sup>1</sup> Implementacija MSCT koronarografije u kliničku praksu kao pouzdane dijagnostičke pretrage za isključenje CAD-a bila je prilično dinamična. Američko udruženje kardiologa (AHA) 2012. godine uvrstilo je MSCT koronarografiju u svoje smjernice, uz preporuku da je treba uzeti u obzir (klasa II. a) u bolesnika s niskom i srednjom vjerojatnošću za CAD koji nisu kadri vježbati, kao i u onih koji imaju neuvjeren test opterećenja, uredan test opterećenja uz neprekidne simptome te u onih koji se ne mogu podvrgnuti stres ehokardiografiji ili nuklearnom medicinskom oslikavanju perfuzije miokarda.<sup>2</sup> Smjernice ESC-a iz 2013. godine nalažu da MSCT koronarografiju treba razmotriti (klasa II. a) kao test prve linije u bolesnika s niskom i srednjom vjerojatnošću i pri sumnji na CAD.<sup>3</sup> Štoviše, ESC ju je 2015. godine preporučio kao pretragu klase II. a, čak i u bolesnika s akutnom boli u prsištu bez promjena u elektrokardiogramu ili povišenih enzima.<sup>4</sup> U konačnici je 2017. godine Nacionalni institut za izvrsnost zdravlja i skrbi (NICE) MSCT koronarografiju preporučio kao pretragu prve linije u simptomatskih bolesnika sa sumnjom na CAD neovisno o procijenjenoj vjerojatnosti.<sup>5</sup> Nove Smjernice ESC-a promaknule su MSCT koronarografiju u pretragu klase I., što znači da je neinvazivno funkcionalno oslikavanje preporučeno kod ishemije miokarda, kao početna pretraga za dijagnosticiranje CAD-a u simptomatskih bolesnika u kojih opstruktivnu koronarnu bolest nije moguće isključiti na temelju kliničke procjene.<sup>1</sup>

Brojni preduvjeti moraju biti ispunjeni da bi se ova izrazito zahtjevna CT pretraga implementirala u kliničku praksu. Bolesnike zahtjevne za snimanje, kao što su primjerice oni s opsežnim koronarnim kalcifikacijama (>400 Agatstonovih jedinica), povišenom (>65/min) ili nepravilnom frekvencijom srca, pretili i oni koji ne mogu zadržati dah, NICE je kao takve prepoznao već prije pri snimanju na uređajima starije generacije. Za razliku od Smjernica ESC-a koje ne preporučuju MSCT koronarografiju, NICE za navedene bolesnike preporučuje uporabu uređaja nove generacije ili čak neke specifične modele.<sup>6</sup> NICE je također definirao potrebne tehničke parametre modela uređaja za pouzdano snimanje MSCT koronarografije koji su zahtjevniji od smjernica Društva za kardiovaskularnu kompjutoriziranu tomografiju (SCCT) čiji je minimalni uvjet 64-slojni CT uređaj s brzim rotacijskim vremenom kućišta ( $\leq 350$  ms)<sup>7</sup> Usprkos razlikama između preporuka NICE-a i ESC-a, iskusan klinički tim sastavljen od inženjera radiologije, radiologa i kardiologa može dobiti dobru kvalitetu slike na CT uređajima nove generacije, čak i u bolesnika zahtjevnih za snimanje. Budući da idealan namjenski CT uređaj za kardiovaskularno oslikavanje još uvijek nije dostupan, za specifične skupine bolesnika proizvođači se koriste različitim tehnološkim rješenjima.

The European Society of Cardiology (ESC) published guidelines for the diagnosis and management of chronic coronary syndromes in 2019, including new recommendations for coronary computed tomography angiography (CCTA).<sup>1</sup> We shall discuss the new role of CCTA in the diagnostic work-up of coronary artery disease (CAD) and potential difficulties with its implementation in the health care system. We shall also describe and present difficult-to-scan patients in detail, such as those with extensive coronary calcifications, increased or irregular heart rate, or those who are obese.

Although CAD has heterogeneous morphology, a bivariant clinical perception of cardiovascular continuum according to which acute coronary syndromes are differentiated from chronic coronary syndromes is still dominant.<sup>1</sup> The implementation of CCTA in clinical practice as an accurate diagnostic procedure for ruling out CAD has been quite dynamic. The American Heart Association (AHA) implemented CCTA in its guidelines in 2012 and recommended that it should be considered (Class IIa) for patients with low-intermediate pre-test likelihood for CAD who are unable to exercise, as well as for those with inconclusive stress test, normal stress test but ongoing symptoms, and those unable to undergo stress echocardiography or nuclear medicine myocardial perfusion imaging.<sup>2</sup> The ESC guidelines issued in 2013 stated that CCTA should be considered (Class IIa) as a first-line test in patients with low to intermediate pre-test probability and suspected CAD.<sup>3</sup> Moreover, ESC recommended it in 2015 as a Class IIa examination even for patients with acute chest pain but without ECG changes or elevated enzymes.<sup>4</sup> Finally, in 2017, the National Institute for Health and Care Excellence (NICE) recommended CCTA as a first-line examination for symptomatic patients with suspected CAD regardless of pre-test probability.<sup>5</sup> The new ESC guidelines promoted CCTA as a Class I examination, which means that CCTA or non-invasive functional imaging is recommended or indicated for myocardial ischemia as the initial test for diagnosing CAD in symptomatic patients in whom obstructive CAD cannot be excluded by clinical assessment alone.<sup>1</sup>

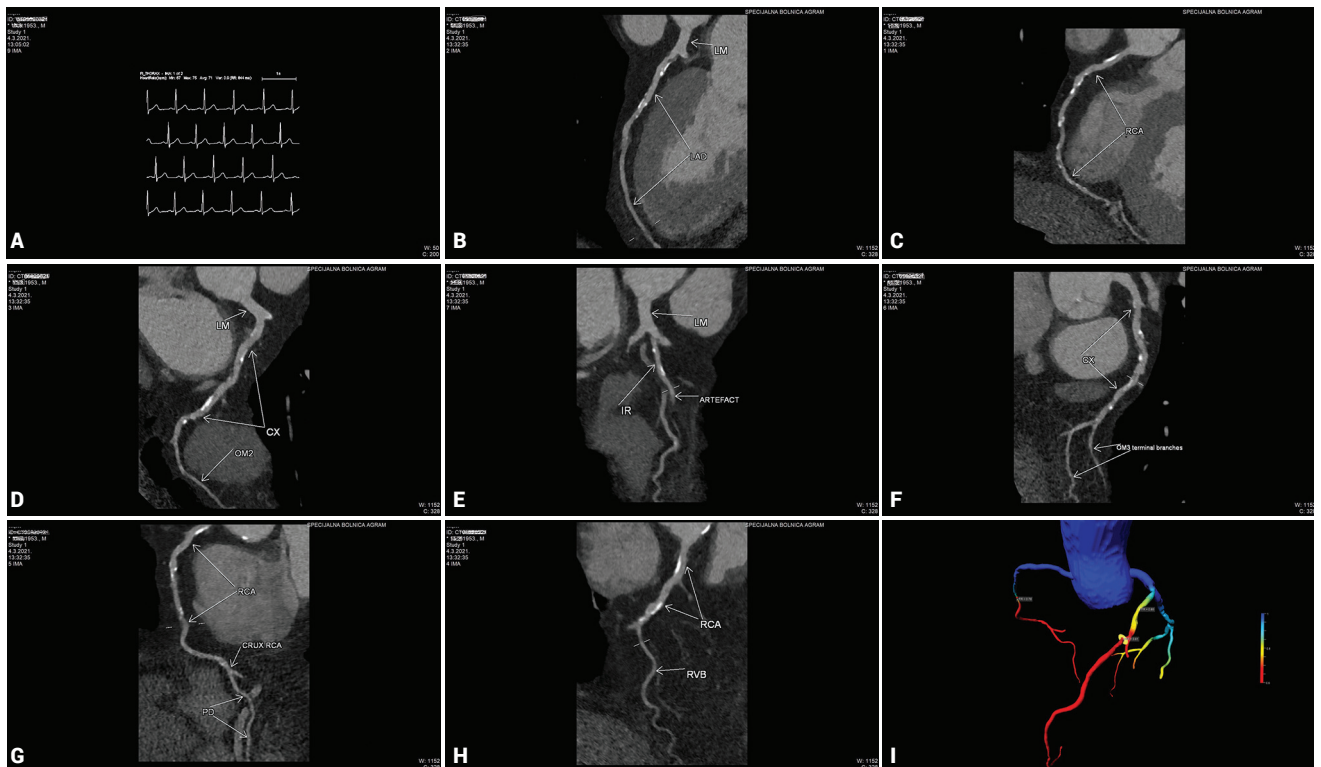
Numerous prerequisites must be fulfilled to clinically implement this highly demanding CT examination. Patients who are difficult to scan, such as those with extensive coronary calcifications (>400 Agatston Units), increased (>65 bpm) or irregular heart rate, or those who are obese (body mass index >30) and unable to hold their breath, have been already identified by NICE in earlier scanner generations. For these patients, NICE recommends the new generation of scanners or even particular scanner models, as opposed to the ESC guidelines which do not recommend CCTA.<sup>6</sup> NICE also defines the required technical capabilities of scanner models for accurate CCTA acquisition; these are more demanding than the Society of Cardiovascular Computed Tomography (SCCT) guidelines, in which the minimum requirement is a 64-slice scanner with fast gantry rotation time ( $\leq 350$  ms).<sup>7</sup> In spite of these differences between ESC and NICE recommendations, an experienced clinical team consisting of a radiographer, radiologist, and cardiologist can obtain good image quality from new-generation CT scanners, even from patients who are difficult to scan. Since an ideal cardiac-dedicated CT scanner is not yet available, manufacturers use different technological solutions for specific patient groups.

U bolesnika s visokim koronarnim kalcijским opterećenjem i stentovima za pouzdano razlikovanje malih stupnjeva koronarnih stenoza najvažnija je visoka prostorna razlučivost u trima dimenzijama (izovoxel). Kod 64-slojna i višeslojnih CT uređaja prostorna razlučivost u z-smjeru povećana je zahvaljujući unaprijeđenoj dimenziji detektora u z-smjeru, čime se postiže visoka izovoxel rezolucija, međutim, željena izovoxel prostorna razlučivost od  $\leq 0,1$  mm trenutačno nije dostupna. Prostorna razlučivost presudna je za smanjenje dvaju artefakata oslikavanja prisutnih u koronarnih bolesnika s kalcifikatima: tzv. *blooming* artefakata i parcijalnog volumnog efekta. Zato je pri investiranju u novi CT uređaj važno poznavati z-dimenzije svakoga reda detektora i ukupnu volumnu pokrivenost u z-smjeru te je li u uređaj ugrađeno jedinstveno hardversko rješenje koje omogućuje akviziciju preklapajućih slojeva, tzv. *z-flying focal spot*<sup>8</sup> (slika 1 i slika 2).

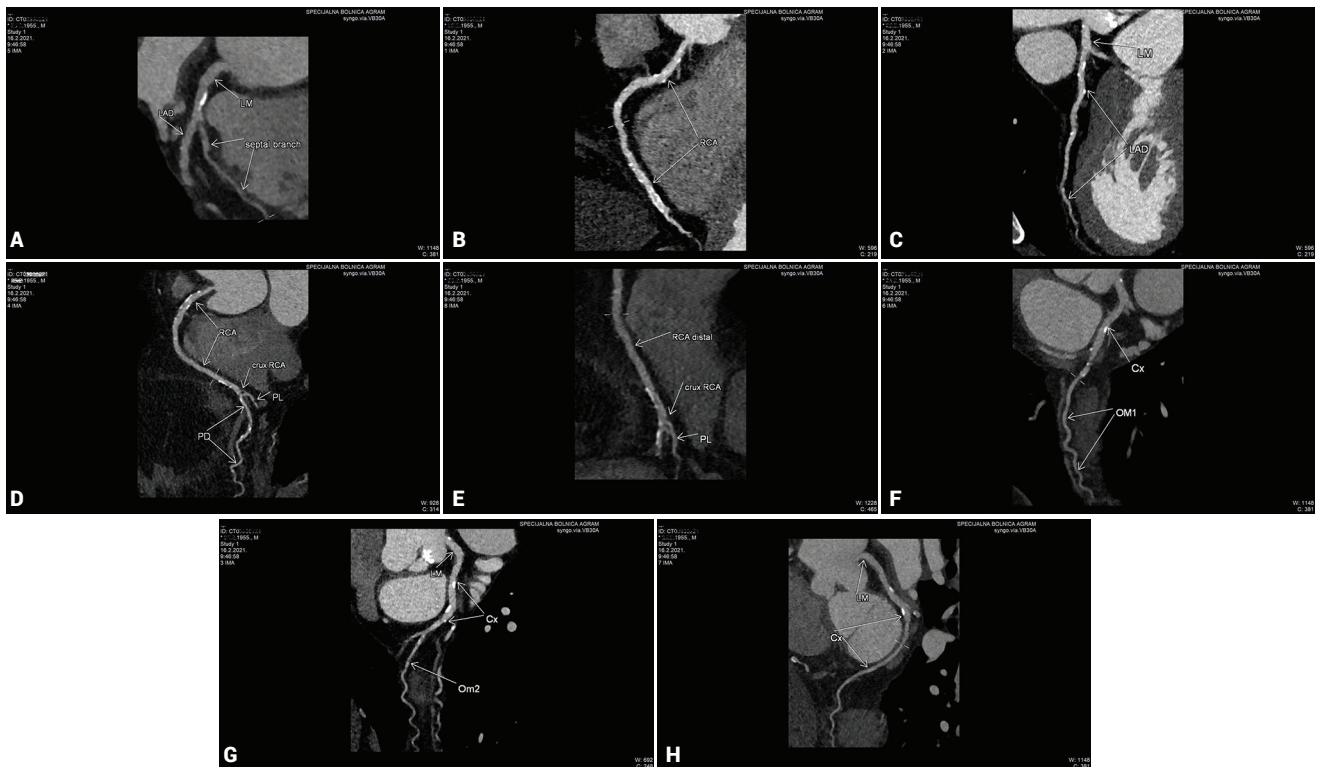
Bolesnici s visokim i/ili nepravilnim otkucajima srca još su jedan izazov za koji treba dobra temporalna rezolucija koja smanjuje artefakte pomicanja koronarnih arterija. Temporalna rezolucija počiva na rotacijskom vremenu kućišta i proizvođači su za njegovo unaprjeđenje razvili nekoliko rješenja. Kod uređaja s jednom cijevi samo polovica (180°) rotacije rendgenske cijevi može se iskoristiti za brzu akviziciju podataka kojom se sprječavaju artefakti pomicanja, dok se kod ure-

For patients with high coronary calcium burden or stents, high spatial resolution in three dimensions (isovoxel) is of the utmost importance to accurately differentiate small coronary stenosis grades. Although 64-slice or higher scanners have improved z-direction spatial resolution resulting from improved detector z-dimension in order to achieve high isovoxel resolution, the desired isovoxel spatial resolution of  $\leq 0.1$ mm is currently not available. Spatial resolution is crucial to reducing two imaging artefacts in calcified patients – blooming artefacts and partial volume effect. Therefore, when investing in new scanner, it is important to know the z-dimension of each detector row and the overall z-dimension coverage, as well as whether or not it includes a *z-flying focal spot*, a unique hardware solution that enables the acquisition of overlapping slices (Figure 1, Figure 2).<sup>8</sup>

Patients with high or/and irregular heart rate represent another challenge that requires good temporal resolution in order to reduce coronary motion artefacts. Temporal resolution rests on gantry rotation time, and manufacturers have therefore developed several solutions to improve it. Only half (180°) of the tube rotation can be utilized for fast data acquisition in order to prevent motion artefacts with single-source scanners; with dual-source scanners, only one fourth (90°) can be utilized. Currently, only one manufacturer provides such



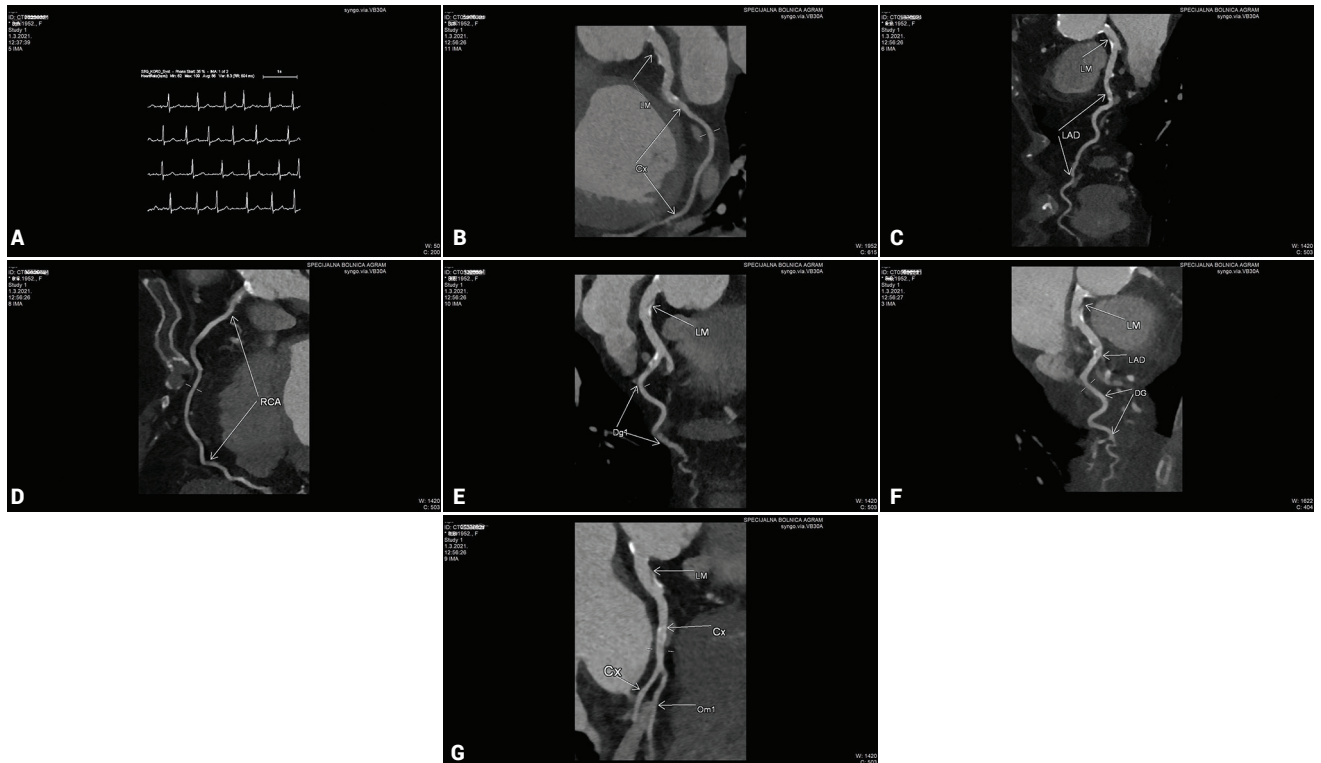
**FIGURE 1.** Male patient, 67 years old, with hypertension and obesity (body mass index 37.4 kg/m<sup>2</sup>; chest/waist circumference 129/122 cm). After intravenous application of four doses of metoprolol, heart frequency remained variable with average rate 71 bpm (A). Longer calcifications were found in proximal segments of the right coronary artery (RCA) and the left anterior descending artery (LAD), but despite the latter the image quality of three major epicardial vessels allowed accurate analysis (B, C, D). Despite minor motion artefacts in some segments, even terminal branches of major vessels are clearly visible (E, F, G, H). Computed tomography fractional flow reserve (CT-FFR) revealed hemodynamically significant stenosis of mid RCA (FFR=0.78) and LAD (FFR=0.80) (I).



**FIGURE 2.** Male patient, 65 years old, with a heart rate of 60 bpm after intravenous application of metoprolol, with obesity (body mass index 34.2 kg/m<sup>2</sup>; chest/waist circumference 104/101 cm). Major epicardial vessels have segmentally longer calcifications but without major “blooming” artefacts (the left main artery and the right coronary artery) (A, B, C). Although images of side and even terminal branches of major epicardial vessels are slightly grainy, they still allow accurate analysis (D, E, F, G, H). Coronary computed tomography angiography revealed non-obstructive coronary artery disease.

đaja s dvjema rendgenskim cijevima može iskoristiti samo četvrtina (90°) rotacije. Trenutačno samo jedan proizvođač nudi tehnologiju s dvjema rendgenskim cijevima. Ona omogućuje temporalnu rezoluciju od 66 ms, za razliku od većine trenutačno dostupnih CT uređaja s jednom cijevi i temporalnom rezolucijom od 100 ms do 250 ms, što je prikladnije za bolesnike sa stabilnom frekvencijom srca  $\leq 65/\text{min}$ .<sup>8</sup> Za one s nepravilnim otkucajima srca potpuna pokrivenost srčane anatomije dugim nizom detektora u z-smjeru ( $>12$  cm) omogućuje akviziciju u jednom otkucaju srca. Trenutačno nekoliko proizvođača nudi takva rješenja. Dugi niz detektora važna je tehnološka prednost pri snimanju bolesnika s koronarnim umetcima. Neki proizvođači primjenjuju fazno pomicanje stola za dobivanje snimki bez artefakata, dok se kod CT uređaja s dvjema rendgenskim cijevima primjenjuje brzo i kontinuirano pomicanje stola, koje omogućuje snimanje s visokim **pitchom** u jednom otkucaju srca. Samo se jedan proizvođač koristi akvizicijom snimaka za MSCT koronarografiju u jednom otkucaju srca s pomoću stacionarnog stola, koja uz nižu dozu zračenja ( $\leq 1$  mSv) dopušta manje artefakata zbog pomicanja srca i disanja. Osim spomenutih tehnoloških rješenja, dodatni ključni preduvjeti za dobru kvalitetu slike u bolesnika s aritmijom ( $\geq 65/\text{min}$ ), uz kraće zadržavanje daha, jesu primjena beta-blokatora i izbor najbolje faze srčanog ciklusa za rekonstrukciju slika (**slika 3**).

dual-source technology. It allows a temporal resolution of 66 ms, while the majority of currently available single-source CT scanners enable temporal resolutions between 100 and 250 ms, thus making them more suitable for patients with a stable heart rate  $\leq 65$  bpm.<sup>8</sup> For patients with irregular heart rate, full coverage of the cardiac anatomy with long z-detector array ( $>12$  cm) enables CCTA acquisition in a single heartbeat. Currently, several manufacturers provide such a solution. A long detector array is also an important technical advantage for scanning patients with coronary grafts. Some vendors use table movement in phases to obtain artefact-free images, while dual-source CT scanners use fast and continuous table movement to enable high-pitch scanning in a single heartbeat. Only one vendor utilizes stationary table image acquisition for single-heartbeat CCTA, which permits less cardiac motion and breath-hold artefacts along with a lower radiation dose ( $\leq 1$  mSv). Together with these technological solutions, which enable a shorter breath hold, the key prerequisites for good image quality in arrhythmic patients ( $\geq 65$  bpm) are the application of beta-blockers and the selection of the best heart cycle phase for image reconstruction (**Figure 3**).



**FIGURE 3.** Female patient, 68 years old, with atrial fibrillation, variable and high average heart frequency of 86 bpm, and voluminous breasts (chest circumference 104 cm) (A). Despite the latter, the image quality of great epicardial vessels allows accurate analysis (B, C, D). Side branches of three major epicardial vessels are clearly presented (E, F, G). Detailed lumen analysis reveals significant ostial stenosis of the right coronary artery (D).

Snimanje bolesnika s velikim prsištem, promjerice voluminoznim dojka, i pretilih iziskuje veću dozu ionizirajućega zračenja i rezultira zrnatijim snimkama zbog povećane produkcije „buke“. Međutim, pri snimanju visokom strujom (>500 mA) i sniženim naponom na cijevi (<120 V) kvaliteta je snimki prihvatljiva čak i pri nižoj dozi ionizirajućega zračenja. Snažan je generator važan tehnološki preduvjet za primjenu struje visoke jačine na rendgenskoj cijevi, što se uvijek ne razmatra pri kupnji novoga CT uređaja. Treba naglasiti da CT uređaji s dvjema rendgenskim cijevima daju mnogo bolju kvalitetu snimaka u usporedbi s uređajima s jednom rendgenskom cijevi.<sup>9-11</sup> CT uređaji za bolesnike zahtjevnije za snimanje trebali bi sadržavati tehnologiju snimanja s dvjema rendgenskim cijevima s dvjema snažnim generatorima struje, koji bi omogućili dobru temporalnu rezoluciju, te također dugi niz detektora u z-smjeru za visoku prostornu razlučivost i volumsku pokrivenost. Dobra kvaliteta slika također zahtijeva odgovarajuću pripremu bolesnika i prilagodbu protokola snimanja njegovim obilježjima (slike 1, 2 i 3).

Tijekom proteklog desetljeća gotovo je polovica CT uređaja u Republici Hrvatskoj zastarjela i bila neprimjenjiva za MSCT koronarografiju.<sup>12</sup> Premda je nedavno dosta javnih bolnica kupilo CT uređaje koji ispunjavaju tehničke SCCT smjernice, oni nisu namijenjeni kardiovaskularnom oslikavanju ni preporučeni bolesnicima zahtjevnijima za snimanje. Takva raspoloživost tehničkih resursa može utjecati na dijagnostički postupnik obrade koronarnih bolesnika jer nezadovoljavaju-

Scanning obese patients and those with a large chest (e.g. voluminous breasts) requires a higher radiation dose and results in grainy images due to high noise production; however, scanning with a high X-ray tube current (>500 mA) and reduced tube voltage (<120 kV) provides sufficient image quality along with a lower radiation dose. A powerful generator is an important technological prerequisite for high X-ray tube current, a consideration that is not always taken into account when purchasing a new CT scanner. Additionally, dual-source scanners provide superior CCTA image quality compared with single-source scanners.<sup>9-11</sup> CT scanners for difficult-to-scan patients should feature dual-source technology with two powerful current generators in order to provide good temporal resolution; they should also have a long z-detector array in order to ensure high spatial resolution and volume coverage. Good image quality requires appropriate patient preparation and the adjustment of scan protocols to individual patient characteristics. (Figures 1, 2 and 3)

For the past decade, nearly half of the CT scanners in Croatia have been outdated and unsuitable for CCTA.<sup>12</sup> Recently, numerous public hospitals have purchased scanners that fulfil SCCT technical guidelines, but these are neither cardiac-dedicated nor recommended for difficult-to-scan patients. The availability of technical resources could influence the diagnostic work-up of patients with CAD, since unsatisfactory image quality can facilitate downstream indications for invasive coronary angiography (ICA) and increase potential

ća kvaliteta slike na MSCT koronarografiji može povećati indiciranje i potencijalno prekomjerno korištenje invazivne koronarografije. Ranijim istraživanjem potvrđeno je upućivanje bolesnika na invazivnu umjesto na MSCT koronarografiju, što može pridonijeti činjenici da je Republika Hrvatska po učestalosti primjene invazivne koronarografije na drugom mjestu u Europi.<sup>13,14</sup> Zbog svega navedenoga MSCT koronarografiju treba promatrati kao „vratara“ za invazivnu koronarografiju, osobito u bolesnika s niskim i umjerenim rizikom za CAD, a nove Smjernice ESC-a potvrđuju već prije naglašenu potrebu za implementacijom takve kliničke prakse.<sup>15-17</sup> Veliko opterećenje opće populacije CAD-om u Republici Hrvatskoj može se objasniti visokom prevalencijom čimbenika kardiovaskularnog rizika, kao što su primjerice prekomjerna tjelesna težina ili pretilost (57,4 %), pušenje (33 %) i arterijska hipertenzija u 50 % muškaraca i 44 % žena.<sup>18-21</sup> Izgledna je sličnost prevalencije fibrilacije atrija europskoj od 1 do 3 %.<sup>22,23</sup> Uzimajući u obzir opterećenje čimbenicima rizika i Smjernice ESC-a iz 2019. godine, očekujemo povećanje broja bolesnika upućenih na MSCT koronarografiju na nacionalnoj razini, što je, unatoč opaženim razlikama u kliničkoj praksi, slučaj i u drugim zemljama sa sličnim kardiovaskularnim opterećenjem. Usprkos istraživanju isplativosti CT uređaja nove generacije provedenom među bolesnicima zahtjevnima za snimanje u Velikoj Britaniji, kod njih ESC još ne preporučuje MSCT koronarografiju.<sup>24</sup> Javne bolnice u svijetu ulažu dodatne napore kako bi osigurale dostatan broj MSCT koronarografija i nadoknadile manjak educiranih inženjera i specijalista radiologije te nedostatak CT uređaja nove generacije namijenjenih za kardiovaskularno oslikavanje. U tome je smislu predsjednica Sekcije za radiologiju srca Hrvatskoga društva radiologa (doc. dr. sc. Maja Hrabak Paar) naglasila ograničenja ljudskih resursa, potrebu za edukacijom specijaliziranih radiologije iz područja kardiovaskularnog oslikavanja i administrativnog priznavanja III. razine edukacije kao formalne uže specijalizacije.<sup>25</sup>

## Zaključak

Nadamo se da će u bližoj budućnosti tvorcima zdravstvenih politika i donositeljima odluka razviti sveobuhvatan i ekonomski opravdan plan za implementaciju CT uređaja namijenjenih za kardiovaskularno oslikavanje u zdravstveni sustav. U skladu s recentnim kliničkim smjernicama, samo na takav način bolesnici mogu imati koristi od ove radiološke pretrage visoke tehnološke razine.

overuse. A previous study has confirmed patient referral for ICA instead of CCTA, which may contribute to Croatia's ICA utilization rate being the second highest in Europe.<sup>13,14</sup> CCTA should be perceived as a gatekeeper for ICA, especially in low-intermediate risk patients; new ESC guidelines confirm the previously emphasized need to implement this clinical practice.<sup>15-17</sup> The high burden of CAD in Croatia can be explained through the high overall prevalence of risk factors: overweight or obesity (57.4%), smoking (33%), and hypertension in 50% of men and 44% of women.<sup>18-21</sup> Atrial fibrillation is most likely similar to the European prevalence of 1-3%.<sup>22,23</sup> Considering the burden of risk factors and the 2019 ESC guidelines, referrals to CCTA are expected to rise at the national level, just as in other countries with a similar cardiovascular burden, although clinical practice may vary. Despite the proven cost-effectiveness of new-generation CT scanners for difficult-to-scan patients in Great Britain, ESC does not yet recommend CCTA for these patients.<sup>24</sup> Public hospitals worldwide are struggling to provide sufficient CCTA services to make up for the shortage in educated radiographers and radiologists, as well as for the lack of new-generation cardiac-dedicated CT scanners. The president of the Cardiac Section of the Croatian Society of Radiology (Assist Prof Dr Maja Hrabak Paar) has emphasized existing constraints in human resources, the need to educate radiology residents in cardiac imaging, and the administrative recognition of Level III education as an official subspecialisation.<sup>25</sup>

## Conclusion

It is hoped that policy and decision makers will develop a comprehensive, economically justifiable plan to implement cardiac dedicated CT scanners in the near future. This is the only way patients can benefit from this high-tech radiological procedure, according to recent clinical guidelines.

## LITERATURE

1. Knuuti J, Wijns W, Saraste A, Capodanno D, Barbato E, Funck-Brentano C, et al; ESC Scientific Document Group. 2019 ESC Guidelines for the diagnosis and management of chronic coronary syndromes. *Eur Heart J*. 2020 Jan 14;41(3):407-477. <https://doi.org/10.1093/eurheartj/ehz425>
2. Fihn SD, Gardin JM, Abrams J, Berra K, Blankenship JC, Dallas AP, et al; American College of Cardiology Foundation. 2012 ACCF/AHA/ACP/AATS/PCNA/SCAI/STS guideline for the diagnosis and management of patients with stable ischemic heart disease: executive summary: a report of the American College of Cardiology Foundation/American Heart Association task force on practice guidelines, and the American College of Physicians, American Association for Thoracic Surgery, Preventive Cardiovascular Nurses Association, Society for Cardiovascular Angiography and Interventions, and Society of Thoracic Surgeons. *Circulation*. 2012 Dec 18;126(25):3097-137. <https://doi.org/10.1161/CIR.0b013e3182776f83>
3. Task Force Members, Montalescot G, Sechtem U, Achenbach S, Andreotti F, Arden C, Budaj A, et al. 2013 ESC guidelines on the management of stable coronary artery disease: the Task Force on the management of stable coronary artery disease of the European Society of Cardiology. *Eur Heart J*. 2013 Oct;34(38):2949-3003. <http://doi.org/10.1093/eurheartj/ehz296>
4. Roffi M, Patrono C, Collet JP, Mueller C, Valgimigli M, Andreotti F, et al; ESC Scientific Document Group. 2015 ESC Guidelines for the management of acute coronary syndromes in patients presenting without persistent ST-segment elevation: Task Force for the Management of Acute Coronary Syndromes in Patients Presenting without Persistent ST-Segment Elevation of the European Society of Cardiology (ESC). *Eur Heart J*. 2016 Jan 14;37(3):267-315. <https://doi.org/10.1093/eurheartj/ehv320>
5. Moss AJ, Williams MC, Newby DE, Nicol ED. The Updated NICE Guidelines: Cardiac CT as the First-Line Test for Coronary Artery Disease. *Curr Cardiovasc Imaging Rep*. 2017;10(5):15. <https://doi.org/10.1007/s12410-017-9412-6>

6. National Institute for Health and Care Excellence (NICE). New generation cardiac CT scanners (Aquilion One, BrillianceCT, Discovery CT750HD and Somatom Definition Flash) for imaging in people with suspected or known coronary artery disease in whom imaging is difficult with earlier generation CT scanners. NICE diagnostics guidance [DG3] 2012. Available from: <http://www.nice.org.uk/guidance/DG3> (January 23, 2021).
7. Abbara S, Blanke P, Maroules CD, Cheezum M, Choi AD, Han BK, et al. SCCT guidelines for the performance and acquisition of coronary computed tomographic angiography: A report of the society of Cardiovascular Computed Tomography Guidelines Committee: Endorsed by the North American Society for Cardiovascular Imaging (NASCI). *J Cardiovasc Comput Tomogr*. 2016 Nov-Dec;10(6):435-449. <https://doi.org/10.1016/j.jcct.2016.10.002>
8. Lewis MA, Pascoal A, Keevil SF, Lewis CA. Selecting a CT scanner for cardiac imaging: the heart of the matter. *Br J Radiol*. 2016 Sep;89(1065):20160376. <https://doi.org/10.1259/bjr.20160376>
9. Donnino R, Jacobs JE, Doshi JV, Hecht EM, Kim DC, Babb JS, et al. Dual-source versus single-source cardiac CT angiography: comparison of diagnostic image quality. *AJR Am J Roentgenol*. 2009 Apr;192(4):1051-6. <https://doi.org/10.2214/AJR.08.1198>
10. Westwood ME, Raatz HD, Misso K, Burgers L, Redekop K, Lhachimi SK, et al. Systematic review of the accuracy of dual-source cardiac CT for detection of arterial stenosis in difficult to image patient groups. *Radiology*. 2013 May;267(2):387-95. <https://doi.org/10.1148/radiol.13121136>
11. Li M, Zhang GM, Zhao JS, Jiang ZW, Peng ZH, Jin ZT, Sun G. Diagnostic performance of dual-source CT coronary angiography with and without heart rate control: systematic review and meta-analysis. *Clin Radiol*. 2014 Feb;69(2):163-71. <https://doi.org/10.1016/j.crad.2013.09.008>
12. Pavlek IB, Brnic Z, Schmidt S, Krpan T, Kralik I. Old and outdated radiology equipment in Croatia-radiation safety and economic consequences. *Insights Imaging*. 2016 Apr;7(2):283-4. <https://doi.org/10.1007/s13244-016-0464-y>
13. Jukić M, Pavić L, Cerkez Habek J, Medaković P, Delić Brkljčić D, Brkljčić B. Influence of coronary computed tomography-angiography on patient management. *Croat Med J*. 2012 Feb 15;53(1):4-10. <https://doi.org/10.3325/cmj.2012.53.4>
14. Eurostat. Cardiovascular diseases statistics. Cardiovascular healthcare. Available from: [https://ec.europa.eu/eurostat/statistics-explained/index.php/Cardiovascular\\_diseases\\_statistics#Cardiovascular\\_healthcare](https://ec.europa.eu/eurostat/statistics-explained/index.php/Cardiovascular_diseases_statistics#Cardiovascular_healthcare) (January 23, 2021).
15. van den Hoogen IJ, van Rosendaal AR, Lin FY, Bax JJ, Shaw LJ, Min JK. Coronary Computed Tomography Angiography as a Gatekeeper to Coronary Revascularization: Emphasizing Atherosclerosis Findings Beyond Stenosis. *Curr Cardiovasc Imaging Rep*. 2019 Jun;12(6):24. <https://doi.org/10.1007/s12410-019-9497-1>
16. Medakovic P, Biloglav Z, Padjen I, Pristas I, Jukic M, Zuvela F, et al. Quantification of coronary atherosclerotic burden with coronary computed tomography angiography: adapted Leaman score in Croatian patients. *Int J Cardiovasc Imaging*. 2018 Oct;34(10):1647-1655. <https://doi.org/10.1007/s10554-018-1376-3>
17. Abubakr MO, Roobottom CA, Morgan-Hughes GJ. 001 Appropriate use of down-stream invasive coronary angiography (ICA) following computed tomographic coronary angiography (CTCA) is still a work in progress. *Heart* 2016;102:A1. <https://doi.org/10.1136/heartjnl-2016-309680.1>
18. Roth GA, Johnson C, Abajobir A, Abd-Allah F, Abera SF, Abyu G, et al. Global, Regional, and National Burden of Cardiovascular Diseases for 10 Causes, 1990 to 2015. *J Am Coll Cardiol*. 2017 Jul 4;70(1):1-25. <https://doi.org/10.1016/j.jacc.2017.04.052>
19. Overweight and obesity - BMI statistics. Available from: [http://ec.europa.eu/eurostat/statistics-explained/index.php/Overweight\\_and\\_obesity\\_-\\_BMI\\_statistics](http://ec.europa.eu/eurostat/statistics-explained/index.php/Overweight_and_obesity_-_BMI_statistics) (December 12, 2019).
20. European Commission. Special Eurobarometer 429. Attitudes of Europeans towards tobacco and electronic cigarettes. Available from: [http://ec.europa.eu/public\\_opinion/archives/ebs/ebs\\_429\\_en.pdf](http://ec.europa.eu/public_opinion/archives/ebs/ebs_429_en.pdf) (January 26, 2020).
21. Kern J, Strnad M, Coric T, Vuletic S. Cardiovascular risk factors in Croatia: struggling to provide the evidence for developing policy recommendations. *BMJ*. 2005 Jul 23;331(7510):208-10. <https://doi.org/10.1136/bmj.331.7510.208>
22. Camm AJ, Lip GY, De Caterina R, Savelieva I, Atar D, Hohnloser SH, et al; ESC Committee for Practice Guidelines (CPG). 2012 focused update of the ESC Guidelines for the management of atrial fibrillation: an update of the 2010 ESC Guidelines for the management of atrial fibrillation. Developed with the special contribution of the European Heart Rhythm Association. *Eur Heart J*. 2012 Nov;33(21):2719-47. <https://doi.org/10.1093/eurheartj/ehs253>
23. Chugh SS, Havmoeller R, Narayanan K, Singh D, Rienstra M, Benjamin EJ, et al. Worldwide epidemiology of atrial fibrillation: a Global Burden of Disease 2010 Study. *Circulation*. 2014 Feb 25;129(8):837-47. <https://doi.org/10.1161/CIRCULATIONAHA.113.005119>
24. Westwood M, Al M, Burgers L, Redekop K, Lhachimi S, Armstrong N, et al. A systematic review and economic evaluation of new-generation computed tomography scanners for imaging in coronary artery disease and congenital heart disease: Somatom Definition Flash, Aquilion ONE, Brilliance iCT and Discovery CT750 HD. *Health Technol Assess*. 2013;17(9):1-243. <https://doi.org/10.3310/hta17090>
25. Interview on Cardiac Imaging Croatia / Dr. Maja Hrabak Paar. Available from: [http://www.radiologija.org/wp-content/uploads/2018/10/Croatia\\_Hrabak-Paar-Maja\\_Cardiac-imaging\\_IDOR2018.pdf](http://www.radiologija.org/wp-content/uploads/2018/10/Croatia_Hrabak-Paar-Maja_Cardiac-imaging_IDOR2018.pdf) (January 23, 2021).