

# Giant Cell Arteritis: How to Diagnose? – A Case Report

Marija Glasnović<sup>1</sup>, Ivica Bošnjak<sup>1</sup>, Aleksandar Včev<sup>1</sup>, Ivan Soldo<sup>2</sup>, Elizabeta Horvatić<sup>3</sup>, Dražen Bedeković<sup>1</sup>, Ksenija Marjanović<sup>4</sup>, Valentina Hečimović<sup>5</sup> and Anamarija Soldo<sup>6</sup>

<sup>1</sup> Department of Internal Medicine, School of Medicine, University »J. J. Strossmayer«, Osijek, Croatia

<sup>2</sup> Department of Infectology, School of Medicine, University »J. J. Strossmayer«, Osijek, Croatia

<sup>3</sup> Department of Pathology and Cytology, General Hospital »Tomislav Bardek«, Koprivnica, Croatia

<sup>4</sup> Department of Pathology, School of Medicine, University »J. J. Strossmayer«, Osijek, Croatia

<sup>5</sup> General Practice, Health Center Osijek, Osijek, Croatia

<sup>6</sup> School of Medicine, University »J. J. Strossmayer«, Osijek, Croatia

## ABSTRACT

*We present a case of 77 years old male with suspected giant cell arteritis. With anamnesis, physical examination, immunological tests, Colour Doppler ultrasonography of superficial temporal artery and finally with patohistological analysis of temporal artery biopsy, we came to right diagnosis.*

**Key words:** temporal arteritis, Colour Doppler, patohistological analysis

## Introduction

Giant cell arteritis, also referred to as temporal arteritis, cranial arteritis and granulomatous arteritis, occur in people over the age of 50 years.<sup>1–4</sup> In many populations, it is one of the most frequent forms of vasculitis. Temporal arteritis is sometimes diagnosed clinically, but The American College of Rheumatology requires three of the following five criteria to be met to establish the diagnosis: age  $\geq 50$  years, new onset of localized headache, temporal artery tenderness or decreased pulse, erythrocyte sedimentation rate  $\geq 50$  mm per hour, and histologic findings.<sup>5</sup> Duplex ultrasonography of the temporal arteries also can be used in the diagnosis of temporal arteritis.<sup>6</sup>

## Case Report

A seventyseven years old man who suffered heart attack 23 years ago, regularly checked by cardiologist, came to our ambulance because of health problems which were present during last three months. Leading symptoms were severe headache, fever, intensive perspiration and scalp pain, together with thickened and nodular both temporal arteries. His eyelids were swollen, and on one occasion patient had sudden onset of blindness and ischemic

claudication of the jaw particularly during chewing, and because of it his molar was extracted, but pain remained present after extraction. Treatment with non-steroid anti-inflammatory drugs (NSAID) was unsuccessful. Patient had significant loss of appetite, weight loss about 12 kg, and significant muscle atrophy. Because of high erythrocyte sedimentation rate (ESR) and high C-reactive protein (CRP) values, patient was examined by infectologist, and later by neurologist, he received high doses of antibiotics and analgetics, but treatment was unsuccessful. After 2.5 months since first onset of symptoms patient came to our ambulance, and after careful examination we have established working diagnosis of giant cell arteritis. Because of poor general health condition we have immediately started therapy with prednisone 60 mg/day, without diagnostic test results.

Laboratory findings were: ESR 74 mm/h, CRP 43 U/mL, normochromic, normocytic anaemia, antinuclear factor (ANF) 1 : 320, cytoplasmatic fluorescent type, rheuma factor (RF) latex 133 U/mL, WaaleRose (WR) 96 IU/mL, p-ANCA 0.4 U/mL, c-ANCA 0.2 U/mL, LA 1.40, aCL: IgG 91.2 U/mL, aCL IgA 29.9 U/mL, aCL IgM 17.8 U/mL. Serology tests for *Borelia Burgdorferi* were nega-

tive, and serology tests for Epstein-Barr virus (EBV) and cytomegalo virus (CMV) pointed to earlier contact, without clinical disease manifestation. Figures 1 and 2 showing pathohistological findings of surgically obtained sample of right temporal artery (diameter 0.3–0.4 cm, length 4 cm) with significant proliferation of subintimal layer with severe lumen narrowing, and in tunica media are present granulomatous nodules composed of epithelioid cells and multinuclear giant cells enlargement 200 and 400 times.

Color doppler ultrasonography showed in left superficial temporal artery wall minimal hyperechogenic atheromatous plaques, with satisfactory flow speed and normal spectral curves. Ultrasonography of right superficial temporal artery showed severe hyperechogenic artery wall thickening with significant lumen occlusion. Spectral curves showed increased vascular resistance in entire arterial segment.

Pathohistology findings and Color Doppler ultrasonography confirmed our working diagnosis of giant cell arteritis. Upon confirmation we continued initial therapy, and patient was discharged from hospital in good general health condition and with normal laboratory

findings. Control examinations, after 30 and 60 days didn't showed any significant changes in patients health condition.

## Discussion

Giant cell arteritis, is the most common steroid-sensitive arteritis of large-sized arteries, associated with local and systemic inflammatory signs<sup>7</sup>. Examples of those local manifestations include sudden headache onset, sudden blindness, temporal artery irregularity, ischemic jaw claudication, scalp necrosis. Systemic manifestations include fever, anorexia, weight loss, and polymyalgia rheumatica syndrome. Based on established clinical criteria, it is possible to differentiate temporal arteritis from other forms of vasculitis; sensitivity and specificity of those criteria are 93.5% and 91.2%, but when used in clinical practice on individual patient, it is difficult to assess their diagnostic value<sup>8</sup>. Clinical manifestations of temporal arteritis could be very diverse among patients. According to reports, sudden headache onset is most common single symptom, but most of adult population doesn't have temporal arteritis<sup>9,10</sup>. However, temporal artery irregularity, ischemic jaw claudication, scalp necrosis, and sudden blindness are suggestive symptoms of temporal arteritis, but they are not always present. Constitutional symptoms are nonspecific, but they can point out way to correct diagnosis. Presence of polymyalgia rheumatica syndrome significantly suggest diagnosis of temporal arteritis, because almost 40% patients with temporal arteritis have polymyalgia rheumatica syndrome, and many patients with polymyalgia rheumatica syndrome have occult temporal arteritis confirmed by biopsy<sup>11,12</sup>. However, routine biopsy isn't advisable for all patients with polymyalgia rheumatica syndrome because if polymyalgia rheumatica is treated correctly, number of complications is relatively small<sup>13</sup>.

Importance of early diagnosis is very significant. Complications, such as blindness, could be avoided by early establishment of correct diagnosis, and usage of suitable therapy. Unilateral blindness in association with temporal arteritis is mostly permanent, and without proper treatment patient will develop bilateral blindness within several weeks. Proper treatment, although it is not proven, could reduce risk of developing aneurysm and dissection of large sized arteries, including aorta and its large branches<sup>14</sup>. Golden standard for temporal arteritis diagnosis is biopsy and pathohistological analysis of temporal artery<sup>15</sup>.

Diagnostic procedures alone, without pathohistological verification are insufficient for confirmation or exclusion of temporal arteritis, once suspected. Published sensitivity for unilateral temporal artery biopsy is approximately 90%, and sensitivity for bilateral temporal artery biopsy is insignificantly higher<sup>16</sup>. Numerous disadvantages of biopsy could be reduced by obtaining sample from a affected side, resecting long arterial segment, and by careful examination of serial cuts in short intervals<sup>17,18</sup>. It is crucial to recognise other forms of arteritis

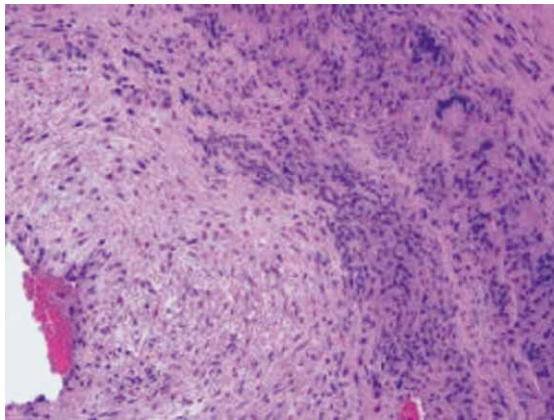


Fig. 1 Patohistological findings of surigacly obtained sample of right temporal artery hemalaun-eosin staining.

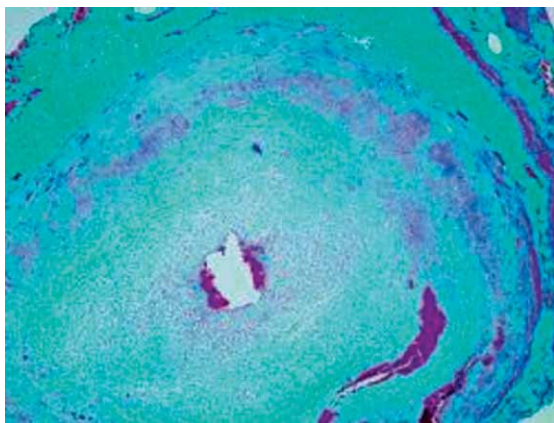


Fig. 2 Patohistological findings of surigacly obtained sample of right temporal artery Mallory's staining.

that could affect temporal artery: polyarteritis nodosa, Curg-Strauss syndrome, Wegener's granulomatosis<sup>19</sup>. According to available evidence and clinical experience, unilateral biopsy of affected side is sufficient for diagnosis, reserving bilateral biopsy only for patients with constant and high suspicion for disease.

However, immediate bilateral biopsy increase sensitivity<sup>16</sup>.

Although, even bilateral temporal artery biopsy isn't perfectly sensitive, it is sensible to treat patient with just clinical suspicion for temporal arteritis, even with negative unilateral or bilateral biopsy, but this applies only for patients with high clinical suspicion and if other possible diseases are excluded. Nevertheless temporal artery biopsy has only slight risk for complications development (<0.5%), such as bleeding, scar, infection, poor wound healing, facial nerve injury, and stroke<sup>20,21</sup>, some patients refuses invasive way of treatment. In that case alternative is Color Duplex ultrasonography<sup>22</sup>.

In one study of the 30 patients with temporal arteritis, 73 percent had a hypoechoic halo around the perfused lumen that disappeared with treatment<sup>23</sup>. That halo might be a sign of fluid in the artery wall. Indeed, edema has been described in temporal arteritis<sup>24</sup>, although it is difficult to document histologically. Ultrasonography identifies a different aspect of the disease (edema) than histologic analysis (cell infiltrates), yet both types of find-

ings may be sign of arteritis<sup>23</sup>. In three studies of 30 to 59 patients with temporal arteritis, Doppler ultrasonography identified abnormalities in 77 to 90 percent of the patients<sup>25–27</sup>. In contrast to conventional Doppler ultrasonography, duplex ultrasonography can distinguish between aplasia and occlusion of the vessel because of the imaging capabilities of the B-mode ultrasound. The superficial temporal artery was found to have an abnormal course in 0 to 8 percent of cadavers<sup>28–30</sup>. Stenosis or occlusion may also occur in persons without temporal arteritis, although they are less common. Continuous-wave Doppler ultrasonography identified abnormalities in 9 to 18 percent of control subjects<sup>18,25</sup> and in 20 to 24 percent patients with negative histologic findings who were suspected of having temporal arteritis<sup>31,25,27</sup>. Duplex ultrasonography of the temporal arteries can be used in the diagnosis of giant cell arteritis and polymyalgia rheumatica as follows. Patient with typical clinical findings and halo on ultrasonography might be treated without a biopsy, unless is a reason to suspect to another vasculitis.

Patient who have only stenoses or occlusion or no abnormalities on ultrasonography should still undergo biopsy. Patients with clinical symptoms of polymyalgia rheumatica who have no signs of giant cell arteritis but with abnormal findings on ultrasonography, should undergo biopsy and be treated with corticosteroids to prevent the blindness, at least until the biopsy results are known.

## REFERENCES

- GILMOUR JR, J Pathol Bacteriol, 53 (1941) 263. — 2. HOTRON BT, MAGATH GT, BROWN GE, Proc Staff Meet Mayo Clin 7 (1982) 700. — 3. KILBOURNE ED, WOLFF HH, Ann Intern Med, 24 (1946) 1. — 4. McMILAN GC, Arch Patolog 49 (1950) 63. — 5. HUNDER GG, BLOCH DA, MICHEL BA, AREND WP, CALABRESE LH, FAUCI AS, Arthritis Rheum 33 (1990) 1135. — 6. SCHMIDT WA, KRAFT HE, VORPAHL K, VÖLKER L, GROMNICA-IHLE EJ, N Engl J Med 19 (1997) 1336. — 7. LEVIN M, WARD TN, Curr Pain Headache Rep 9 (2005) 259. — 8. RAO JK, ALLEN NB, PINCUS T, Ann Intern Med 129 (1998) 345. — 9. SMETANA GW, SHMERLING RH, JAMA, 287 (2002) 92. — 10. YOUNG BR, COOK BR Jr, BARTLEY GB, Mayo Clin Proc, 79 (2004) 483. — 11. MYKLEBUST G, GRAN JT, Br J Rheumatol, 35 (1996) 1161. — 12. HEALEY LA, Baillieres Clin Rheumatol 5 (1991) 847. — 13. KYLE V, HAZLEMAN BL, Ann Rheum Dis 52 (1993) 847. — 14. BONGARTZ T, MATTESON EL, Curr Opin Rheumatol 18 (2006) 10. — 15. HAZLEMAN BL, Polymyalgia rheumatica and giant cell. In: HOCHBERG MC, SILMAN AJ, SMOLEN JS, WEINBLATT ME, WEISMAN MH (Eds) Rheumatology 3rd ed. (Philadelphia, Mosby, 2003). — 16. BOYEV LV, MILLER NR, GREEN WR, Am J Ophthalmol, 128 (1999) 211. — 17. POLLER DN, van WYK Q, JEFFREY MJ, J Clin Pathol, 53 (2000) 137. — 18. TAYLOR GJEVRE R, VO M, SHUKLA D, RESCH L, J Rheumatol 32 (2005) 1279. — 19. GENEREAU T, LORTHOLARY O, POTTIER MA, MICHON-PASTUREL U, PONGE T, DE WAZIÈRES B, Arthritis Rheum 42 (1999) 2674. — 20. BHATI MT, GOLDSTEIN MH, Dermatol Surg 27 (2001) 15. — 21. SCOTT KR, TSE DT, KRONISH JW, Ophthalmic Surg 22 (1991) 519. — 22. SCHMIDT WA, KRAFT WE, VÖLKER L, VORPAHL K, GROMNICA-IHLE EJ, Lancet 345 (1995) 866. — 23. SCHMIDT WA, KRAFT HE, VORPAHL K, VÖLKER L, GROMNICA-IHLE EJ, N Engl J Med 227 (1997) 1385. — 24. ASHTON-KEY M, GALLAGHER PJ, Baillieres Clin Rheumatol 5 (1991) 387. — 25. DANY F, LIOZON F, CHAUMONT P, CHASTANG A, LACROIX P, CATANZANO R, J Mal Vasc 14 (1989) 104. — 26. VINKIER L, HATRON PY, GADENNE C, CATTEAU MH, GOSSET D, DEVULDER B, J Mal Vasc 14 (1989) 116. — 27. PUÉCHAL X, CHAUVÉAU M, MENKÈS CJ, Lancet 345 (1995) 437. — 28. STOCK ALL, COLLINS HP, DAVIDSON TM, Head Neck Surg 2 (1980) 466. — 29. MARRANO SR, FISCHER DW, GAINES C, SONNTAG H, Neurosurgery 6 (1985) 786. — 30. LIEB WE, FLAHARTY P, HO A, SERGOTT RC, Acta Ophthalmol Suppl 204 (1992) 50. — 31. WILLIAMSON TH, BAXTER G, PAUL R, DUTTON GR, Br J Ophthalmol 76 (1992) 690.

M. Glasnović

Clinic of Internal Medicine, School of Medicine, University »J. J. Strossmayer« Osijek, Huttlerova 4,  
31000 Osijek, Croatia  
e-mail: glasnovic.marija@kbo.hr

## **TEMPORALNI ARTERITIS: KAKO DO DIJAGNOZE? – PRIKAZ SLUČAJA**

### **S A Ž E T A K**

Prikazujemo slučaj 77 godina starog muškarca sa sumnjom na temporalni arteritis. Anamnezom, kliničkim pregledom, imunološkim testovima, Color Doppler ultrazvukom i konačno histološkom analizom uzorka temporalne arterije postavili smo točnu dijagnozu.