

Department of Obstetrics and Gynecology, University Clinical Center,\* Medical Faculty;  
Institute of pathology,\*\* Medical Faculty, Skopje, R. Macedonia

## **MASSIVE EDEMA OF OVARY – CASE REPORT**

### **MASIVNI EDEM OVARIJA – PRIKAZ BOLESNICE**

**Vasil N. Iliev,\* Klementina K. Kuzeska,\* Saso D. Stojcevski,\* Milco S. Ristovski\*\***

*Case report*

**Key words:** massive ovarian edema, ovarian tumor, ovarian torsion

**SUMMARY.** Massive ovarian edema is characterized by enlargement of ovaries with edema fluid. The patients are young (age below 21), with abdominal pain. This uncommon entity usually leads to over-treatment in children and adolescents. A frozen operative section is essential. A case of massive ovarian edema in a 16-year-old female that urgently necessitated an operative intervention is described.

*Prikaz bolesnice*

**Ključne riječi:** masivni edem ovarija, ovarijalni tumor, torzija ovarija

**SAŽETAK.** Masivni ovarijalni edem je karakteriziran povećanjem jajnika s edemom. Pacijentice su mlade životne dobi (mlade od 21 godinu) s abdominalnom boli. Ovakav neuobičajeni nalaz obično dovodi u djece i adolescentica do prekomjernog postupka. Tijekom zahvata nužna je hitna biopsija. Prikazan je slučaj 16 godišnje bolesnice u koje je bila nužna hitna operacijska intervencija.

The patient P.M., aged 16, was hospitalized at Department of Obstetrics and Gynecology, because of a pain in the lowest right side abdomen, with moderate intensity. The pain began a few days ago, and progressed in intensity with vomiting. On exam patient is conscious, oriented, afebrile and contactable, with regular vital parameters. The abdomen was soft on palpation, with pain sensitivity on right iliac quadrant. The external genitalia were regular morphologically. The gynecological exam was not performed because virginity of the patient. On rectal exam, a strongly painful subfixated tumor formation sized a child head was found. On ultrasound, a tumor formation on the right ovary was found, sized 140×90 mm. There was also an evident solid part 70×90 mm and a cystic part 57×65 mm, presented in a forced position (subtorsion), and evident fluid in Douglass space. Laboratory analyses were normal, including the tumor marker (Ca-125=23.5 u/ml).

Pfannenstiell incision was performed and an ovarian tumor of the right side was evident, with dimension of child head, and bizarre outlook, in torsion, with solid and cystic part (*Figure 1*). The cystic part was filled with mucin-like contents. Some abdominal fluid was taken out for cytological analysis. Right oophorectomy and left ovarian resection were performed. The intact tumor was extirpated. The extirpated material was sent to extempore histologic-pathological analysis. As soon as the response was for a benign tumor, the operation was finished.

Histologic-pathological analysis reported that it was a mass of 300 g weight and 17 cm length. The cyst had a thin and smooth wall, filled with pale and yellow translucent fluid. The rest of the ovary was with monotonous

structure, presented with edematous, spread and gelatinous stromal changes, and with small follicular cysts. The periphery was presented by a zone of ovarian hemorrhagic changes. The histological analysis showed hypocellular edematous stromal changes all around the follicles or follicular cysts, and focuses of fibromatous stroma with luteinisation (*Figure 2*). In the part with hemorrhagic focuses coagulation necrosis appeared. Contra-lateral ovary had regular structure. Cytological analysis of abdominal fluid showed that it belonged in the first classification group. Definitively, histologic-pathological analyses showed an entity called *massive ovarian edema*.

From clinical symptoms/findings/signs specific for massive ovarian edema, following was present in our case:

- Ovarian enlargement (present)
- Unilateral (present)
- Age below 21 year (present)
- Torsion (present)
- Androgenic symptoms (not present)
- Hypocellular stroma and/or fibrous proliferation (present)
- Preservation of follicles (present)

Massive edema of ovary is characterized by enlargement of one or two ovaries due to accumulation of edema fluid.<sup>1</sup> The patients are young (average age below 21) and most of them present with abdominal pain. Some patients have menstrual abnormality, evidence of hyperandrogenism or both. The ovarian enlargement is

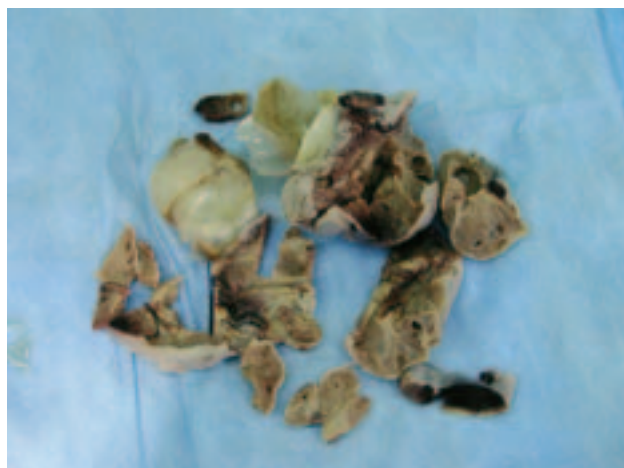

Figure 1. Macroscopic appearance of dissected right ovary of the patient: yellowish solid and cystic particles may be seen

Slika 1. Makroskopski izgled rascijepljenog desnog jajnika bolesnice: vide se žučkasti solidni i cistični dijelovi

unilateral in 90% of cases. In approximately half the cases there is torsion of the ovarian pedicle. Grossly the enlarged ovary rang from 5 to 35 cms in greatest dimension, and on section appears gelatinous. Microscopic examination shows edematous, hypocellular stroma surrounding the follicles. Small focuses of fibromatous stroma may be seen. Luteinized stromal cells are encountered in 40% of cases, and are probably responsible for the androgenic manifestation that occur in about 25% of cases.

The cause of massive edema of ovary is unclear. It has been attributed to intermittent torsion of the ovarian pedicle and interference with its lymphatic drainage. An-

Paper received: 26. 02. 2006.; accepted: 7. 05. 2006.

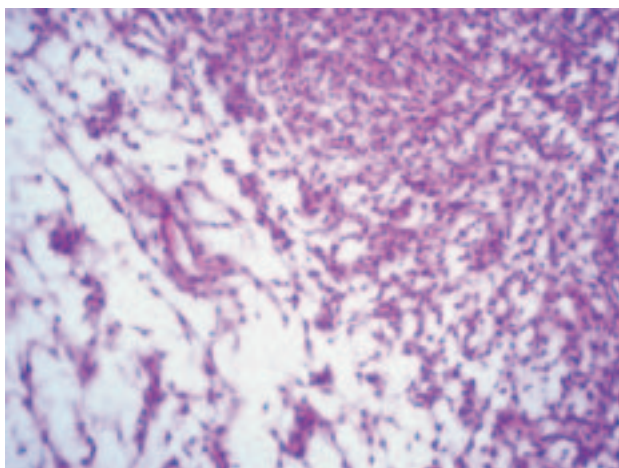


Figure 2. Microscopic picture: fibromatous edematous stroma of the ovary

Slika 2. Mikroskopski izgled: vidi se fibromatozna edematozna stroma jajnika

other possible explanation is primary stromal proliferation (fibromatosis) with secondary edema resulting from torsion of an ovary enlarged by this lesion. It has been proposed two ends in spectrum of the same disorder.<sup>2</sup>

A patient was dismissed in good health and regular local status.

## References

1. Yilmaz Y, Turk Ylmaz Z, Sonmez K et al. Massive ovarian oedema in adolescents Acta Chir Belg 2005;105(1):106–9.
2. Prat J. »Pathology of the ovary« Philadelphia – London: W.B. Saunders 2004;25–7.

Address for correspondence: Vasil N. Iliev, Dept. Ob & Gyn, Medical Faculty, Vodnjanska 17, Skopje 1000, R. Macedonia, e-mail: viliev@ukim.edu.mk

## VIJESTI NEWS



U prigodi 40. obljetnice osnutka Hrvatska liga protiv raka  
u suradnji s KB »Sestre milosrdnice« iz Zagreba  
priređuje

Znanstveni simpozij s međunarodnim sudjelovanjem

### DIJAGNOSTIKA I LIJEČENJE RAKA DOJKE I VRATA MATERNICE

6. i 7. listopada 2006. u Zagrebu u Hotelu Westin



POKROVITELJI: Ministarstvo zdravstva Republike Hrvatske  
Hrvatski liječnički zbor i Europsko društvo ginekoloških onkologa

ORGANIZATOR: Hrvatska liga protiv raka

SUORGANIZATORI: KB »Sestre milosrdnice« i O-Tours

PREDSJEDNIK ORGANIZACIJSKOG ODBORA: dr. sci. Damir Eljuga

KOTIZACIJA: sudionici 1000,00 kuna, a 1200,00 na licu mjesta,  
za umirovljenike, specijalizante i medicinske sestre 500,00 kuna.

OBAVIJESTI I PRIJAVE: Sanja Suhić, O-tours, Gajeva 6, Zagreb,  
tel. 492 1720, 483 1007, faks: 481 010, mob 098/980 57 14,  
e-mail: sanja.suhic@otours.hr, web: www.hlpr.hr