

Marmara University School of Medicine, Fetal Medicine Unit, Istanbul

## **PRENATAL DIAGNOSTICS OF FETAL ABNORMALITIES BY ULTRASOUND AND COLOR DOPPLER**

### **PRENATALNA DIJAGNOSTIKA FETALNIH ANOMALIJA ULTRAZVUKOM I KOLOR DOPLEROM**

*Alin Başgül Yigiter, Zehra Nese Kavak*

*Review*

*Key words:* prenatal diagnosis, fetal abnormalities, ultrasound, color Doppler

**SUMMARY.** There is no doubt that ultrasound provides many clinical advantages. It is shown that ultrasound enables the earlier detection of fetal malformations. Professionals expect from routine ultrasound objective information that cannot usually be obtained by clinical procedures. Parents seek reassurance about the absence of fetal congenital anomalies and overall fetal health. Therefore, people view routine ultrasound as a part of obstetrical care, capable of filling important gaps by delivering much key information for improving obstetrical practice. Fetal anomalies screening requires higher education and qualifications than usual obstetrical ultrasound. In this paper we are summarizing the fetal anomalies that can be detected and evaluated by ultrasound and color Doppler by presenting some examples of our original cases with fetal abnormality. Progressive improvements in ultrasound equipment have permitted within the field of prenatal diagnosis of structural fetal anomalies to obtain a very high sensitivity and specificity, with utilization of high resolution equipment and an expert ultrasonographer in fetal dysmorphology.

*Pregled*

*Ključne riječi:* prenatalna dijagnostika, fetalne anomalije, ultrazvuk, kolor dopler

**SAŽETAK.** Nema sumnje da ultrazvuk pruža mnoge kliničke prednosti. Poznato je da ultrazvuk omogućuje ranije otkrivanje fetalnih malformacija. Stručnjaci očekuju iz rutinske ultrazvučne dijagnostike informacije koje obično ne mogu dobiti kliničkim pregledima. Roditelji traže sigurnost o nepostojanju fetalnih kongenitalnih anomalija te o općenitom zdravlju ploda. Zato ljudi promatraju ultrazvuk kao dio porođničarske skrbi, koji može ispuniti dijagnostičku prazninu i poboljšati porođničarsku praksu. Probir fetalnih anomalija zahtijeva višu edukaciju i kvalifikacije nego uobičajeni opstetrički ultrazvuk. U ovome članku sažeto prikazujemo fetalne anomalije, koje mogu biti otkrivene i prosuđene ultrazvukom i kolor doplerom, prikazujući neke primjere naših originalnih slučajeva fetalnih anomalija. Progresivna poboljšanja ultrazvučne opreme, rabeći opremu s visokom rezolucijom, dozvoljavaju ultrasoničaru ekspertu fetalne morfologije postići, u području prenatalne dijagnoze strukturalnih fetalnih anomalija, vrlo visoku osjetljivost i specifičnost.

## **Introduction**

During the last 25 years, the development of increasingly sophisticated equipments (digital techniques, grey scales, color Doppler and 3D and 4D sonography) enabled the diagnosis of a growing number of malformations so that it is now possible to diagnose about 80% of congenital abnormalities with reliable structural images.<sup>1-4</sup>

There is no doubt that ultrasound provides many clinical advantages. The Cochrane database confirms that ultrasound enables the earlier detection of fetal malformations.<sup>2,5</sup> Professionals expect from routine ultrasound objective information that can not usually be obtained by clinical procedures.<sup>6</sup> Parents seek reassurance about the absence of fetal congenital anomalies and overall fetal health. Therefore, people view routine ultrasound as a part of obstetrical care, capable of filling important gaps by delivering much key information for improving obstetrical practice.<sup>7</sup> Fetal anomalies screening (FAS) requires higher education and qualifications than obstetrical ultrasound.<sup>8</sup> In most European countries approximately 98% of pregnant women are examined by ultra-

sound, frequently two to three times (usually once per trimester). Detection rate of congenital anomalies is about 28% in private practice and hospitals, 60 to 80% in Ob/Gyn's ultrasound labs.<sup>9-11</sup> While congenital defects constitute 3% of all births, monogenic disorders and chromosomal syndromes constitute 1.4% and 0.6% of all births respectively.<sup>12</sup> Progressive improvements in ultrasound equipment within the field of prenatal diagnosis of structural fetal anomalies have permitted to obtain a sensitivity range of 90 to 95 percent and specificity range of 95 to 100 percent, with utilization of high definition equipment and an expert ultrasonographer in fetal dysmorphology.<sup>13-15</sup>

## **Fetal central nervous system**

Accurate prenatal diagnosis of central nervous system (CNS) abnormalities is essential in counselling parents, as they are the most common developmental abnormalities causing considerable mortality.<sup>16</sup> Advanced sonography combined with methodology of approaching the fetal brain has improved the assessment of fetal intra-

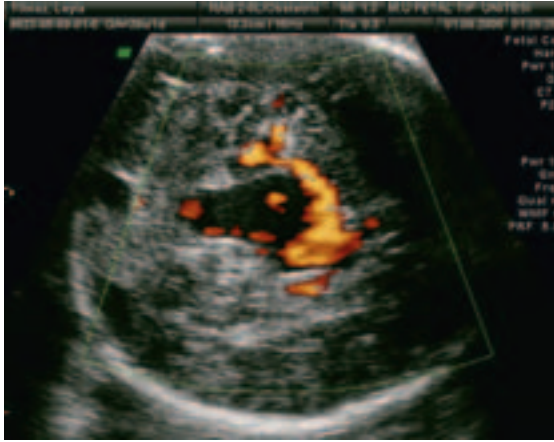

Figure 1. Vein of Galen aneurysm in a 39 weeks' fetus. Axial view at the level of the third ventricle. The large black area is the vein of Galen aneurysm. Power Doppler evaluation shows the feeding arteries.

Slika 1. Aneurizma Galenove vene u fetusa s 39 tjedana trudnoće. Aksijalni presjek na razini treće komore. Veliko crno polje je aneurizma. Osnovni dopler prikazuje arterije koje uštrcavaju.

cranial structure and diagnosis of the prenatal brain abnormalities.<sup>17,18</sup> Prenatal assessment of the fetal central

nervous system is very important as anomalies in this region often determine survival, physical appearance and function in society.<sup>2,18</sup>

Many malformations of the CNS and fetal neural axis can be detected easily and reliably:<sup>18–22</sup> agenesis of corpus callosum, anencephaly, arachnoid cyst, cranial tumors, craniosynostosis, Dandy-Walker malformations, ventriculomegaly, hydrocephalus, diastematomyelia, encephalocele, vein of Galen malformation (Fig. 1), holoprosencephaly (Fig. 2), hydrancephaly, iniencephaly, intracranial hemorrhage, microcephaly, spina bifida, meningocele, Arnold-Chiari malformation (Fig. 3) and teratomas.<sup>16,18–24</sup> Recently it has been shown that during pregnancy the multiplanar neurosonographic examination of the fetus enables superb visualization of brain anatomy. The examination may be performed using a transvaginal or a transfundal approach and it is indicated in patients at high risk for CNS anomalies or in those with a suspicious finding during a routine examination.<sup>24</sup> Recent remarkable development of 3D and 4D ultrasound will produce more accurate evaluation of the brain morphology.<sup>3,17</sup>

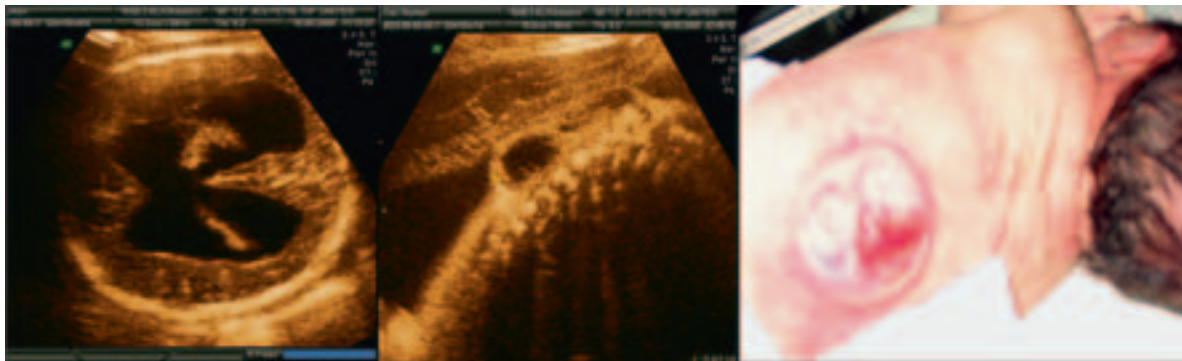


Figure 2. Lobar holoprosencephaly associated with lumbar meningomyelocele in a fetus at 39 weeks. Left: Transverse section of the head showing lobar holoprosencephaly with interrupted septum. Middle: longitudinal section of the lumbar myelomeningocele. The newborn (right).

Slika 2. Lobarna holoprosencefalija te lumbalna meningomijelocela u fetusa s 39 tjedana trudnoće. Lijevo: poprečni presjek glavicice s holoprosencefalijom s prekinutim septumom. Sredina: uzdužni presjek lumbalne meningomijelocela. Desno: novorođenče.

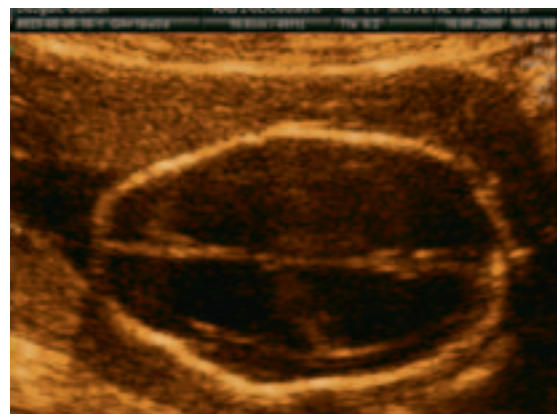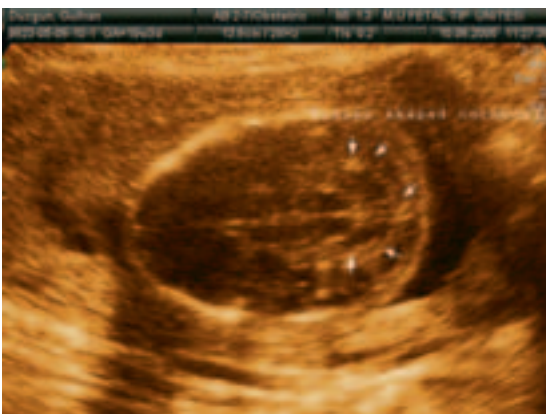


Figure 3. Arnold-Chiari malformation in a fetus with thoracolumbar meningomyelocele at 19 weeks' of gestation. The cerebellum forms a »banana« shape and there is no visible cisterna magna (left), the anterior aspect of the skull is flattened, so the skull assumes a »lemon« shape (right).

Slika 3. Arnold-Chiarijeva malformacija fetusa s torakolumbalnom meningomijelocelom s 19 tjedana trudnoće. Mali mozak ima oblik »banane«, cisterna magna se ne vidi (lijevo), prednji izgled lubanja je splošten tako da lubanja poprma oblik »limuna« (desno).

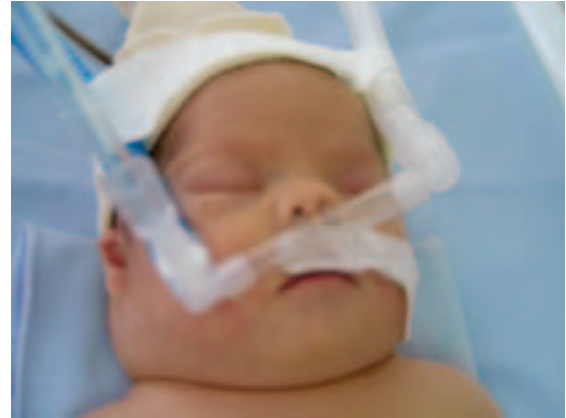
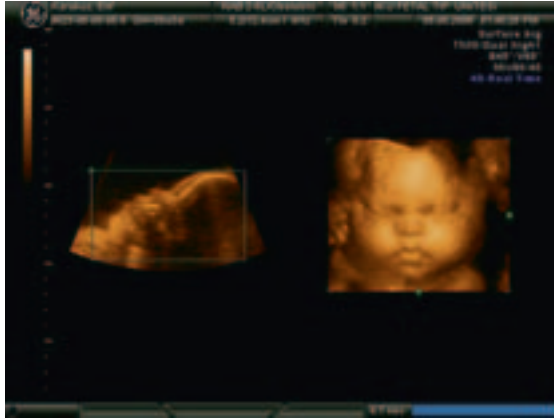
Figure 4. Down's Syndrome at 30 weeks' of gestation. Fetal profile by 2D (left) and 3D view (right). The baby after birth (right).  
Slika 4. Downov sindrom s 30 tjedana trudnoće. Fetalni profil u 2D (lijevo) i 3D (desno) tehnici. Dijete nakon rođenja (sasvim desno).

### Face and neck abnormalities

It is now possible to make prenatal identification of fetal face and neck malformation with great precision by means of different ultrasonographic proceedings; 2D, 3D or 4D.<sup>2,3,17,23</sup> Some examples are flat face (Fig. 4), cleft lip and palate (Fig. 5), ocular abnormalities, nasal malformations, ear malformations, micrognathia, facial asymmetry, retrognathia, nuchal translucency and nuchal fold, and various types of cystic lesions and tumors in the neck.<sup>1,2</sup> Among the most frequent fetal facial and

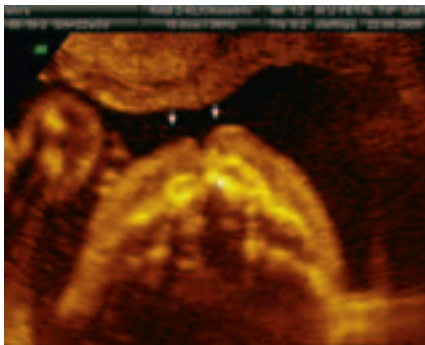


Figure 5. Unilateral cleft lip and palate at 22 weeks' of gestation. Transverse section of 2D US shows full thickness.

Slika 5. Jednostrani rascjep usne i nepca s 22 tjedna trudnoće. Poprečni presjek u 2D UZ slici.

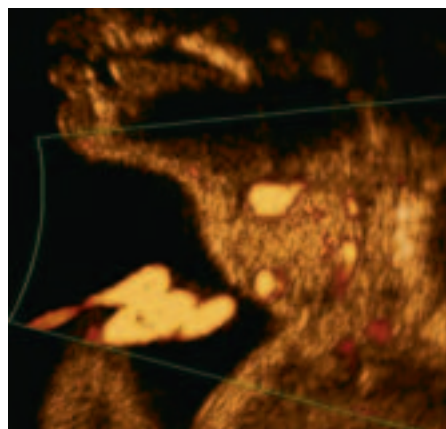
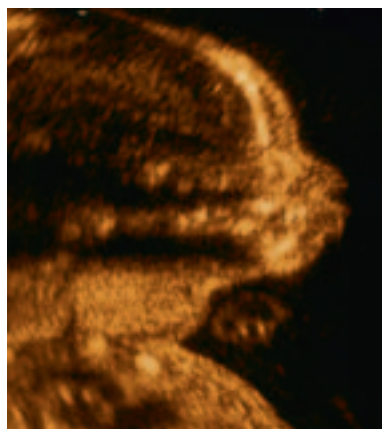


Figure 6. Fetal goiter at 24 weeks by 2D (left) and power Doppler (right) ultrasound imaging.

Slika 6. Fetalna guša s 24 tjedna trudnoće u 2D slici (lijevo) i osnaženim doplerom (desno).

neck anomalies are: cystic hygroma (septated and non septated), teratomas, hemangiomas, fetal goiter (Fig. 6) and thyroid enlargement.<sup>2,7</sup>

### Fetal thoracic abnormalities

The most frequent thoracic anomalies that can be reliably diagnosed by ultrasound (excluding cardiac malformations) are: congenital diaphragmatic hernia (protrusion of the abdominal organs into the thoracic cavity through a diaphragmatic defect), congenital cystic adenomatoid malformation (Fig. 7) (the most common of the isolated lung malformations in which a large part of the lung is occupied by cyst of variable size and aspect), pleural effusions (Fig. 8), sequestration of the lungs. Esophageal atresia, tracheal atresia, tracheoesophageal fistula can also be evaluated by ultrasound.<sup>2,23,25–26</sup> Stover et al.<sup>27</sup> has recently shown high degree of accuracy in 45 prenatal ultrasound examinations for depicting fetal cystic lung lesions. Klam et al.<sup>28</sup> has proved successful prediction of outcome in primary fetal hydrothorax by serial ultrasound studies.

### Gastrointestinal system malformations

The most frequent anomalies that can be detected by ultrasound are; gastroschisis (Fig. 9), omphalocele (Fig.

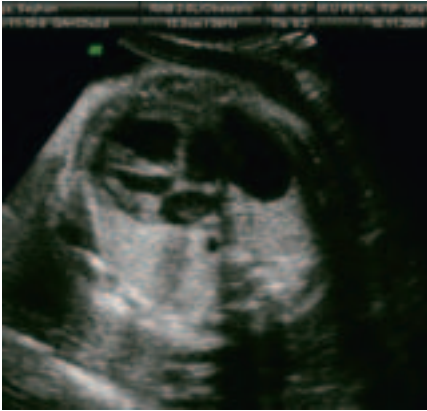

Figure 7. Congenital cystic adenomatoid malformation of the lungs.  
Transverse view: macrocystic type.  
Slika 7. Urođena cistična adenomatoidna malformacija pluća. Poprečni presjek: makrocistični tip.

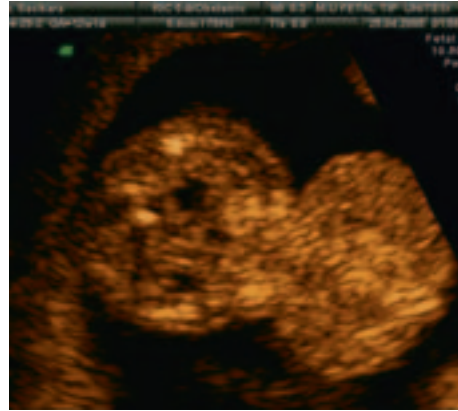

Figure 10. Omphalocele at 12<sup>th</sup> gestational weeks. Transverse section shows the omphalocele containing liver with bilateral mild hydronephrosis in the same fetus.  
Slika 10. Omfalocela s 12 tjedana.  
Poprečni presjek prikazuje omfalocelu koja sadrži jetra te obostranu blagu hidronefrozu u istoga fetusa.

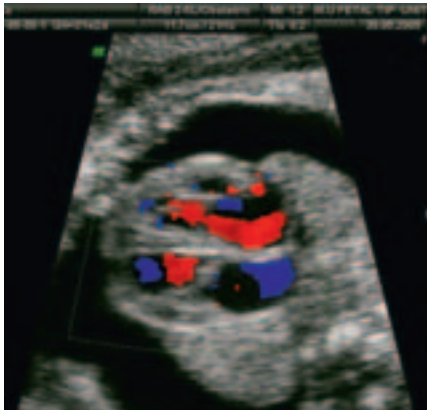


Figure 8. Pleural effusion. Transverse image of the fetal thorax. Bilateral effusion and hydrops.  
Slika 8. Pleuralni izljev. Poprečna slika fetalnog toraksa. Obostrani izljev i hidrops.

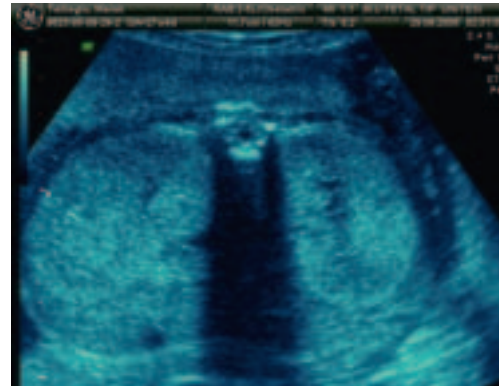


Figure 11. Infantile polycystic kidney at 27<sup>th</sup> gestational weeks. Transverse section shows bilateral large kidneys with almost the same echogenicity as the remainder of abdomen.  
Slika 11. Infantilni policistični bubrege s 27 tjedana trudnoće. Poprečni presjek prikazuje obostrane velike bubrege gotovo iste ehogenosti kao ostatak abdomena.

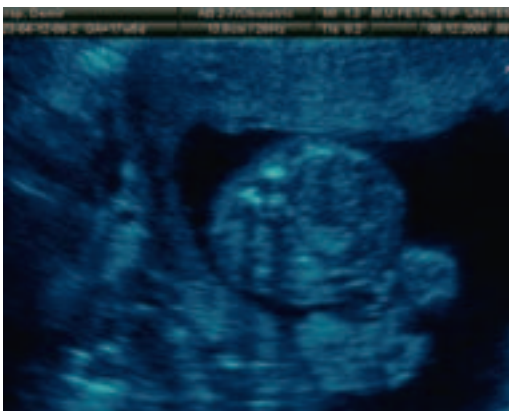

Figure 9. Gastroschisis at 19<sup>th</sup> gestational weeks. Transverse section shows the loops of bowel protruding through a defect in the abdominal wall without a covering membrane.  
Slika 9. Gastroschiza s 19 tjedana trudnoće.  
Poprečni presjek prikazuje vijuge crijeva bez pokrovne opne, potisnute kroz defekt trbušne stijenke.

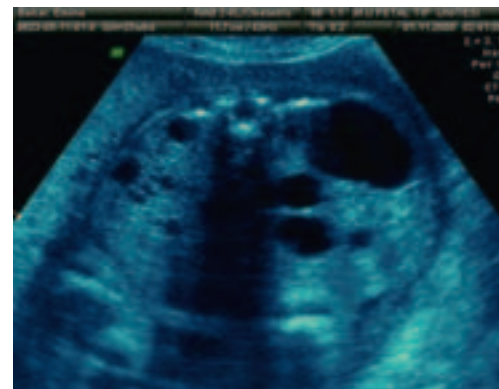


Figure 12. Multicystic dysplastic kidney disease. The kidney(s) appear(s) enlarged with multiple cysts which are variable in size, noncommunicating, most randomly positioned but sometimes peripheral. The size of the kidneys are proportional to the number of visible cysts.  
Slika 12. Multicistična displazija bubrega.  
Bubreg je povećan s brojnim cistama različite veličine koje nisu povezane, nasumce su smještene i djelomice periferne. Veličina bubrega je srazmjerna broju vidljivih cista.

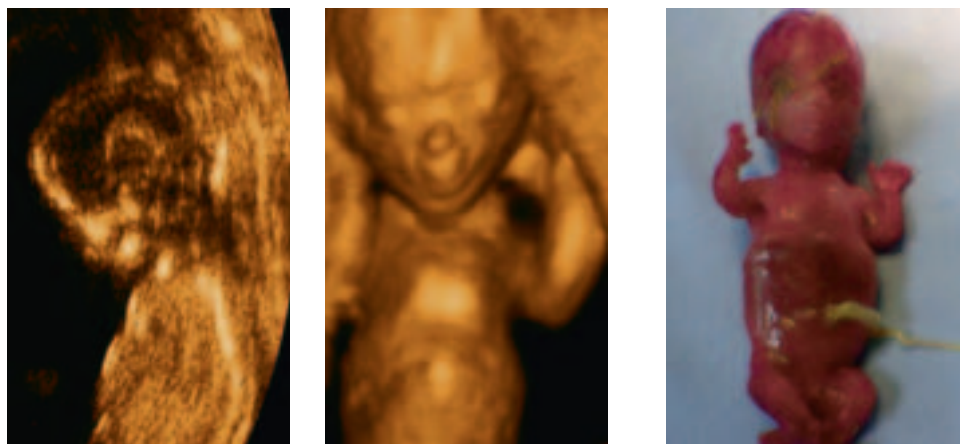


Figure 13. Thanatophoric dysplasia at 16 weeks. Left: 2D sagittal scan shows the narrow chest. Middle: 3D view. Right: the baby after abortion  
Slika 13. Tanatoforična displazija sa 16 tjedana. Lijevo: uzdužna 2D slika pokazuje uska prsa. Sredina: 3D izgled. Desno: plod nakon pobačaja.

10), congenital diaphragmatic hernia, intraabdominal and intrathoracic masses, their composition and vascularity, duodenal atresia, intestinal obstructions.<sup>2,29</sup> Omphalocele is a ventral defect in which the abdominal cavity (bowel loops, stomach, liver etc) is herniated into a sac.<sup>2</sup> A prenatal sonographic diagnosis could be useful to evaluate the abdominal ring and serial ultrasound examinations are recommended to detect promptly ominous signs of hepatic and bowel damage. Color Doppler may be useful to assess the anatomy of the abdominal vessels and their relationships with the herniated organs.<sup>30</sup> It is by ultrasound examination also possible to identify characteristics of the fetal omphalocele, to predict the outcome of the fetuses with a potentially good prognosis and favorable outcome and those who are likely to have a fatal outcome.<sup>31</sup> Gastroschisis consists in a paraumbilical defect of the abdominal wall, probably as a consequence of a very early occlusion on the right

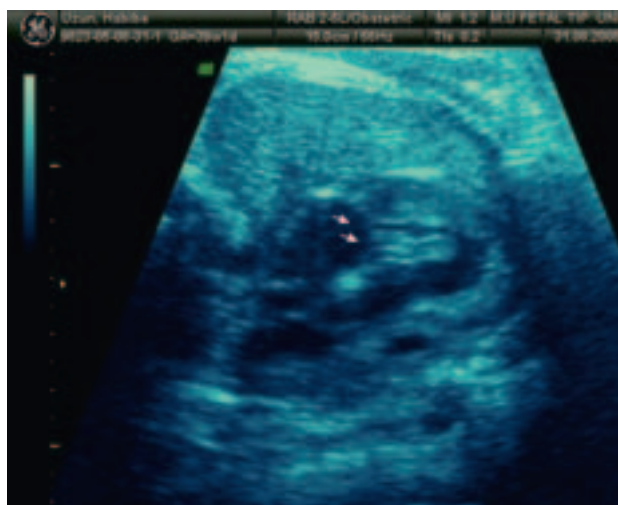


Figure 15. Hypoplastic left ventricle by 2D US at 39 weeks of gestation.  
Slika 15. Hipoplastična lijeva klijetka. 2D UZ u 39 tjednu trudnoće.

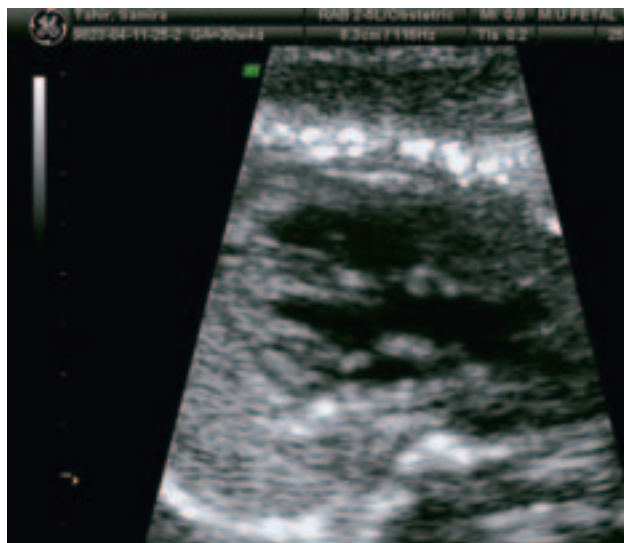


Figure 14. Overriding aorta in a fetus with Fallot tetralogy at 30 weeks of gestation. 2D US.

Slika 14. Aorta koja »jaše« u fetusa s tetralogijom Fallot s 30 tjedana trudnoće. 2D UZ.

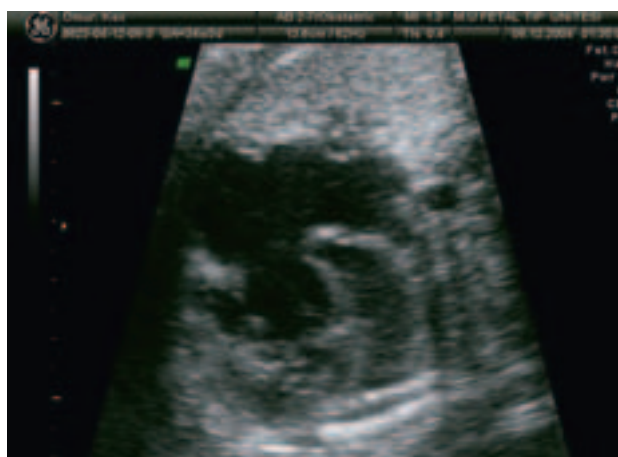

Figure 16. Ebstein's anomaly in the third trimester. Note the marked tricuspid valve displacement. The hinge point of the septal leaflet of the tricuspid valve is displaced from the crux.

Slika 16. Ebsteinova anomalija u trećem tromjesečju. Pozor na odmak trikuspidalnog zaliska. Hvatište septalnog listića trikuspidalnog zaliska je odmaknuto od ležišta.

umbilical or omphalomesenteric vessel. Through this defect the abdominal organs protrude into the amniotic fluid, without a covering membrane. The sonographic examination shows as »cauliflower-shaped« mass or free-floating loops of bowel.<sup>2</sup> Many authors have underlined the importance of the ultrasound in prenatal diagnosis of the malformation to predict the size and localization of the defect, complications of the gastroschisis anomaly, like intrauterine growth retardation and bowel dilatation and rupture.<sup>32</sup>

## Genitourinary system malformations

Evaluation of the fetal bladder and kidneys is routine practice in obstetric sonography.<sup>2,33</sup> Fetal genitalia are also routinely evaluated since the parents frequently ask the fetal gender.<sup>34</sup> Urinary malformations are relatively uncommon.<sup>2,34</sup> The incidence of urinary malformations is found to be 0.65% in a prospective antenatal ultrasound study.<sup>2,35</sup>

The fetal kidney can be visualized ultrasonically as early as 9.5 weeks in optimal circumstances. Kidneys are readily seen at the 12<sup>th</sup> gestational week by abdominal sonography and a week earlier by transvaginal sonography.<sup>33</sup> The urinary tract abnormalities are easily recognized as they are invariably accompanied by fluid filled masses in fetal abdomen.<sup>33</sup> Urinary malformations are suspected if there are following features: decreased amniotic fluid, dilatation of the urinary tract (renal pelvicalyceal dilatation, ureteral or urethral dilatation), presence of a renal cyst, change in the size, shape and echogenicity of the kidney, absence of failure to visualize the fetal bladder and any other fetal malformation detected.<sup>2</sup>

The most frequent genitourinary malformations that can be recognized by ultrasound are: renal agenesis, renal dysgenesis (infantile polycystic kidney disease; Potter type I (*Fig. 11*), multicystic dysplastic kidney disease (MDKD; Potter type II, *Fig. 12*), adult polycystic kidney disease (ADPKD; Potter type III), cystic renal dysplasia (CRD Potter type IV), abnormally distended fetal bladder (megacystis) due to posterior urethral valve, urethral agenesis or stricture, persistence of cloaca and megacystis-microcolon-hypospadias syndrome, bladder extrophy, ureteropelvic junction obstruction, pyelectasis, megaureter, vesicoureteral reflux, horseshoe kidney and empty renal fossa, renal duplication anomalies, tumors of the kidney, adrenal gland tumor, congenital adrenal neuroblastoma, sacrococcygeal teratoma.<sup>1,2,13,33–35</sup>

Genital anomalies that are recognizable by ultrasound are: fetal ovarian cysts, hydrocolpos and hydrometrocolpos in the case of female fetus, fetal hydrocele, ambiguous genitalia, hypospadias in the case of male genitals.<sup>2,34</sup>

## Skeletal abnormalities

The fetal skeleton can be visualized by ultrasound very early, however, only a small proportion of skeletal

malformations can be identified in the early second trimester.<sup>2</sup> During the scan it is very important to focus biometry of the long bone, grade of bone density, fractures or bowing of the bones, fetal spine, appearance and number of digits and fetal movements.<sup>36</sup> Numerous abnormalities of skeleton can be detected by ultrasound, some of which are; achondrogenesis, achondroplasia, limb deficiencies, alterations of the hands and feet, thanatophoric dysplasia (*Fig. 13*), osteogenesis imperfecta, arthrogyposis, camptomelic dysplasia.<sup>2,36,37</sup>

## Cardiac malformations

Major congenital heart defects (CHD) are the most common severe congenital malformations, with an incidence of about 5 in 1000 live births.<sup>38</sup> CHDs are responsible for nearly half of all neonatal and infant deaths due to congenital anomalies.<sup>2</sup> Their incidence is six times greater than chromosomal abnormalities and four times greater than neural tube defects. The majority of the fetuses with CHD occurs in the pregnancies with no identifiable risk factors. Therefore there is wide agreement that cardiac ultrasound screening should be introduced as an integral part of the routine scan especially between 20<sup>th</sup> to 23<sup>rd</sup> gestational weeks.<sup>2,38,39</sup> Recently early fetal echocardiography has been started to be done successfully by using high-frequency transvaginal ultrasound probes between 13 to 16 weeks of gestation.<sup>40</sup>

By cardiac scan intact four chamber visualization the detection of 40% of anomalies may be achieved and the additional visualization of the outflow tracts and of great arteries increases the rate up to 60 to 70% in general low-risk population.<sup>38</sup> Color and pulsed Doppler are particularly useful to confirm normal inflow to the ventricles and to detect turbulent flow or jets suggesting valve regurgitation. Color Doppler helps confirming presence of intact septum and it helps in diagnosing the atrial and ventricular septal defects. It is also useful to better visualization of the outflow tracts confirming antegrade flow through the semilunar valves and great arteries and makes the examination of aortic and ductal arches easier. Color Doppler is also useful in identifying systemic and pulmonary venous return.<sup>2,38–41</sup>

The most frequent fetal heart anomalies diagnosed at routine echocardiography are: ventricular septal defects, atrial septal defects, abnormal venoatrial connections, tricuspid atresia or dysplasia, atrioventricular septal defects, single ventricle, aortic atresia, aortic stenosis, tetralogy of Fallot (*Fig. 14*), hypoplastic left heart (*Fig. 15*), pulmonary atresia and stenosis, transposition of great arteries, truncus arteriosus, double outlet right ventricle, aortic arch anomalies, Ebstein's anomaly (*Fig. 16*), isomerism, myocardopathy, complex cardiac defects.<sup>2,39</sup>

## Conclusion

The development of increasingly sophisticated equipments enables the ultrasonic diagnosis of about 80 per cent of fetal structural anomalies. The high definition

equipment has the diagnostic sensitivity up to 90–95 percent and the specificity up to 95–100 percent.

To obtain the above achievements the high education and skills of examiners is needed, higher than usual ultrasonic gynecological education.

## References

1. Kurjak A, Kirkinen P, Latin V, Rajhvajn B. Diagnosis and assessment of fetal malformation and abnormalities by ultrasound. *J Perinat Med*. 1980;8:219–35.
2. Carrera JM, Torrents M, Munog A, et al. Prenatal diagnosis of congenital defects. In Kurjak A, Carrera JM (eds): *Donald School Atlas of Clinical Application of Ultrasound in Obstetrics and Gynecology*. New Delhi: Jaypee Brothers 2006;166–239.
3. Kurjak A. 3D ultrasound and perinatal medicine. *J Perinat Med* 2002;30:5–7.
4. Leung KY, Ngai CS, Chan BC, Leung WC, Lee CP, Tang MH. Three-dimensional extended imaging: a new display modality for three-dimensional ultrasound examination. *Ultrasound Obstet Gynecol* 2005;26(3):244–51.
5. Kurjak A, Chervenak FA. Ultrasound in Perinatal Medicine: Editorial. *Ultr Rev Obst Gynecol* 2001;1:193–4.
6. Carrera JM. Fetal ultrasonography: The first 40 years: Editorial. *Ultr Rev Obst Gynecol* 2004;4:193–4.
7. Levi S, Hyjazi Y, Schaapst JP, Defoort P, Coulon R, Buekens P. Sensitivity and specificity of routine antenatal screening for congenital anomalies by ultrasound: the Belgian Multicentric Study. *Ultrasound Obstet Gynecol* 1991;1:102–10.
8. Levi S. Routine ultrasound screening of congenital anomalies. An overview of the European experience. *Ann N Y Acad Sci* 1998;18;847:86–98.
9. Zimmer EZ, Avraham Z, Sujoy P, Goldstein I, Bronshtein M. The influence of prenatal ultrasound on the prevalence of congenital anomalies at birth. *Prenat Diagn* 1997;17:623–8.
10. Grandjean H, Larroque D, Levi S. Sensitivity of routine ultrasound screening of pregnancies in the Eurofetus database. The Eurofetus Team. *Ann N Y Acad Sci* 1998;18;847:118–24.
11. Levi S. Ultrasound in prenatal diagnosis: polemics around routine ultrasound screening for second trimester fetal malformations. 2002;22:285–95.
12. Grandjean H, Larroque D, Levi S. Detection of chromosomal abnormalities, an outcome of ultrasound screening. The Eurofetus Team. 1998;18;847:136–40.
13. Lys F, De Wals P, Borlee-Grimee I, Billiet A, Vincotte-Mols M, Levi S. Evaluation of routine ultrasound examination for the prenatal diagnosis of malformation. *Eur J Obstet Gynecol Reprod Biol* 1989;30:101–9.
14. Kurjak A, Bekavac I. Perinatal problems in developing countries: lessons learned and future challenges. *J Perinat Med*. 2001;29:179–87.
15. Bronshtein M, Zimmer EZ, Blumenfeld Z. Early sonographic detection of fetal anomalies. In: Kurjak A. (ed.). *Textbook of Perinatal Medicine*. London: Parthenon Publishing 1998; 263–80.
16. Patel TR, Bannister CM, Thorne J. A study of prenatal ultrasound and postnatal magnetic imaging in the diagnosis of central nervous system abnormalities. *Eur J Pediatr Surg* 2003; 13:18–22.
17. Kurjak A, Veccek N, Hafner T, Bozek T, Funduk-Kurjak B, Ujevic B. Prenatal diagnosis: what does four-dimensional ultrasound add? *J Perinat Med* 2002;30:57–62.
18. Johnson ML, Dunne MG, Mack LA, Rashbaum CL. Evaluation of fetal intracranial anatomy by static and real-time ultrasound. *J Clin Ultrasound* 1980;8:311–8.
19. Chervenak FA, Berkowitz RL, Romero R, et al. The diagnosis of fetal hydrocephalus. *Am J Obstet Gynecol* 1983; 147:703–16.
20. Chervenak FA, Isaacson G, Mahoney MJ, Berkowitz RL, Tortora M, Hobbins JC. Diagnosis and management of fetal cephalocele. *Obstet Gynecol* 1984;64:86–91.
21. Chervenak FA, Duncan C, Ment LR, Tortora M, McClure M, Hobbins JC. Perinatal management of meningomyelocele. *Obstet Gynecol* 1984;63:376–80.
22. Chervenak FA, Isaacson G, Mahoney MJ, Tortora M, Mesologites T, Hobbins JC. The obstetric significance of holoprosencephaly. *Obstet Gynecol* 1984;63:115–21.
23. Chervenak FA, Isaacson G, Blakemore KJ et al. Fetal cystic hygroma. Cause and natural history 1983;309:822–5.
24. Malinger G, Lev D, Lerman-Sagie T. Normal and abnormal fetal brain development during the third trimester as demonstrated by neurosonography. *Eur J Radiol* 2006;57:226–32.
25. Papp Z. Ultrasound examination of the fetal thorax. In Kurjak A, Chervenak FA (eds). *Textbook of Ultrasound in Obstetrics and Gynecology*. New Delhi: Jaypee Brothers 2004; 272–9.
26. Ruano R. Recent advances in sonographic imaging of fetal thoracic structures. *Expert Rev Med Devices* 2005;2:217–22.
27. Stover B, Mau H, Scheer I, Bassir C et al. Congenital cystic lung malformations. *Rofa* 2006;178:432–7.
28. Klam S, Bigras JL, Hudon L. Predicting outcome in primary fetal hydrothorax. *Fetal Diagn Ther* 2005;20:366–70.
29. D'Addario V, Di Cagno L, Tamburo R. Malformations of the gastrointestinal system. In: Kurjak A, Chervenak FA (eds). *Textbook of Ultrasound in Obstetrics and Gynecology*. New Delhi: Jaypee Brothers 2004;290–7.
30. Pelizzo G, Maso G, Dell'Oste C, et al. Giant omphaloceles with a small abdominal defect: prenatal diagnosis and neonatal management. *Ultrasound Obstet Gynecol* 2005;26:786–8.
31. Brantberg A, Blaas HG, Haugen SE, Eik-Nes SH. Characteristics and outcome of 90 cases of fetal omphalocele. *Ultrasound Obstet Gynecol* 2005;26:527–37.
32. Hwang PJ, Kousseff BG. Omphalocele and gastroschisis: an 18-year review study. *Genet Med* 2004;6:232–6.
33. Kurjak A, Kirkinen P, Latin V, Ivankovic D. Ultrasonic assessment of fetal kidney function in normal and complicated pregnancies. *Am J Obstet Gynecol* 1981;141:266–70.
34. Kurjak A, Latin V, Mandruzzo G, D'Addario V, Rajhvajn B. Ultrasound diagnosis and perinatal management of fetal genito-urinary abnormalities. *J Perinat Med* 1984;12:291–312.
35. Livera LN, Brookfield DS, Egginton JA, Hawnaur JM. Antenatal ultrasonography to detect fetal renal abnormalities: a prospective screening programme. *BMJ* 1989;298(6685):1421–3.
36. Bronshtein M, Keret D, Deutsch M, Liberson A, Bar Chava. Transvaginal sonographic detection of skeletal anomalies.

lies in the first and early second trimesters. *Prenat Diagn* 1993; 13:597–601.

37. Chervenak FA, Isaacson G, Lorber J. Anomalies of the fetal head, neck and spine: ultrasound, diagnosis and management. Philadelphia: WB Saunders 1988;17–36.

38. Allan LD. Fetal cardiology. *Curr Opin Obstet Gynecol* 1996;8:142–7.

39. Todros T. Prenatal diagnosis and management of fetal cardiovascular malformations. *Curr Opin Obstet Gynecol* 2000; 12:105–9.

40. Haak MC, Twisk JW, Van Vugt JM. How successful is fetal echocardiographic examination in the first trimester of pregnancy? *Ultrasound Obstet Gynecol* 2002;20:9–13.

41. Campbell S. Isolated major congenital heart disease (Opinion). *Ultrasound Obstet Gynecol* 2001;17:370–9.

*Paper received:* 12. 04. 2006; *accepted:* 19. 07. 2006.

*Address for correspondence:* Alin Başıgöl Yigiter, Abide-i Hürriyet Caddesi, No: 144, Ruyam Palas Apartmanı, Kat: 3, D: 10, 34381, Şişli, Istanbul, Turkey; E-mail: alinbasgul@hotmail.com

## VIJESTI NEWS

### XXVIII. ALPE-ADRIA MEETING OF PERINATAL MEDICINE

Varaždin, 6. – 8. listopada 2006.

#### 1. tema – 1<sup>st</sup> topic. Ethics and forensic problems in perinatology

**Obstetric introducing lecture:** Uwe Lang, Graz. **Pediatric introducing lecture:** Janez Babnik, Ljubljana. **Obstetric invited lectures:** Dietmar Schlembach, Martin Häusler, Philipp Klaritsch, Graz: Neural tube defects detected beyond fetal viability – the problems of fetocid; Ante Dražančić, Zagreb: Ethics and forensic problems in obstetrics; Vajda György, Szeged: Ethics and forensic problems in perinatology. Obstetric aspects; Yoram I. Meir, Gianpaolo Mandruzzato, Trieste and Bassano del Grappa: Malpractice in pregnancy care and childbirth: Modern controversial issues in Italy?; Vasilij Cerar, Ljubljana: The role of ethical committee in decision making in the cases of fetal anomaly. **Pediatric invited lectures:** Bernd Urlesberger, Graz: Neonatal care at the threshold of viability; Milan Stanojević, Zagreb: Ethical and legal issues of treatment in NICU; Márta Katona, Szeged: Ethics and forensic problems in perinatology. Pediatric aspects; Pierpaolo Provedani, Trieste: Decision making in very preterm delivery; Janez Primožič, Ljubljana: Role of parents in decision making in ICU.

#### 2. tema – 2<sup>nd</sup> topic. Immune diseases in perinatal medicine

**Obstetric introducing lecture:** Zoltán Novák, Szeged. **Pediatric introducing lecture:** Sergio Demarini, Trieste. **Obstetric invited lectures:** Philipp Klaritsch, Martin Häusler, Dietmar Schlembach, Graz: Autoimmune diseases in pregnancy – Selected cases; Josip Đelmiš, Vito Starčević, Zagreb: Immune diseases and pregnancy; Gyula Mészáros, Szeged: Immune diseases in perinatal medicine – Obstetric aspects; Gianpaolo Maso, Trieste: Trombophilia and outcome of pregnancy; Tanja Premru-Sršen, Barbara Šajina Stritar, Matija Tomšič Ambrožič, Ljubljana: Management of pregnancy in women with antiphospholipid syndrome. **Pediatric invited lectures:** Ingrid Marschitz, Graz: Neonatal immunology; Emilija Juretić, Zagreb: Lymphocyte subpopulations in newborns; Hajnalka Orvos, Szeged: Immune diseases in perinatology. Pediatric aspects; Fabio Uxa, Trieste: Neonatal effects of maternal autoimmune diseases; Irena Stucin Gantar, Helena Mole, Janez Babnik, Tadej Avčin, Ljubljana: Infants of mothers with antiphospholipid syndrome.

**Special lecture.** Asim Kurjak, Zagreb: Recent advances in fetal neurology.

#### Free communications.

#### Informations.

Sastanak će se održati u Varaždinu u hotelu »Turist« – The meeting will be held in Varaždin at the hotel »Turist«.

■ **Smještaj** sudionika je predviđen u istome hotelu ili u hotelu LaGus na Varaždin Bregu, 10 minuta kolima do konferencijske dvorane. Cijena noćenja s doručkom je od 200 do 300 Kn dnevno – The **accomodation** of participants will be at a same hotel or at Hotel LaGus at Varaždin Breg, 10 minutes by car to conference theatre. The hotel price per night with breakfast per person is 30–40 €. ■ **Kotizacija** za sudjelovanje nije predviđena – The **participation fee** for the meeting is not previewed ■ **Sastanak je bodovan** od Hrvatske liječničke komore s po 8 bodova za sudionike – **The meeting will be scored** by Croatian Medical Chamber ■ Predavanja će prije sastanka biti tiskana u **knjizi sažetaka**. **Pozvana predavanja** mogu biti napisana na najviše 3 stranice formata A4, ukupno 150 redaka napisanih slovima »Times New Roman«. **Slobodna priopćenja** mogu imati najviše 1 stranicu, odnosno 50 redaka – The papers will be printed before meeting in the **Book of Abstracts**. The **invited lectures** should be written at the most on 3 pages of the format A4, altogether 150 lines »Times New Roman« letter types. The **free communications** should have at most 1 page i.e. 50 lines ■ **Napisane sažetke** valja poslati do 1. kolovoza – The **written abstracts** should be sent before August 1<sup>st</sup> to the address: Prof. Ante Dražančić, Department of Gynecology & Obstetrics, University Medical School, Petrova 13, 10 000 Zagreb, or Fax: +385 1 4633 512; or E-mail: ejuretic@vip.hr. ■ **Lokalni organizacijski odbor – Local organizing Committee:** General Hospital Varaždin, Dept. Gyn. & Obstet., Head Dr. Ivan Pižeta, Meštrovićeva b.b., 42 000 Varaždin; E-mail: sasa.jukic@zg.t-com.hr.